

# A very rare presentation of reoperation combined both old Monteggia fracture and secondary distal radioulnar joint dislocation in adult

## A case report

Yanchao Zhang, MD, Wan'an Xiao, MD, PhD, Jianjun Li, MD, PhD\*

### Abstract

**Rationale:** The old Monteggia fracture is an uncommon lesion pattern in adult, which may lead to the potential complications such as recurrent dislocation of the radial head, heterotopic ossification of the elbow, nerve palsy, malunion of the ulna, and residual forearm deformity. However, the secondary distal radioulnar joint (DRUJ) dislocation is rarely reported in the similar lesion. Here we present a unique reoperation of old Monteggia fracture combined with secondary DRUJ disruption after the initial operation failure.

**Patient concerns:** A 38-year-old male presented to our hospital outpatient office complaining of left elbow stiffness and ongoing wrist dysfunction with a history of injury to the left forearm caused by a forklift accident that occurred 5 months previously.

**Diagnosis and interventions:** At the local hospital, the patient underwent successively fasciotomy and decompression, ulnar open reduction, and internal fixation due to osteofascial compartment syndrome and a misdiagnosed ulnar fracture. Upon examination, the secondary dorsal dislocation of the DRUJ was obvious both clinically and radiographically. We performed a revision surgery called ulnar osteotomy, radioulnar ligament repair, and temporary fixation of the DRUJ with a Kirschner wire.

**Outcomes:** The patient received a satisfactory result without observed redislocation and relapse according to the 1-year follow-up.

**Lessons:** Considering the notoriously poor outcomes, the importance of early recognition and accurate treatment should be emphasized repeatedly in similar lesions. Paying close and continuous attention to the clinical and radiographic examinations of the elbow and wrist joint is necessary to avoid misdiagnosis and missed diagnosis.

**Abbreviations:** CT = computed tomography, DRUJ = distal radioulnar joint, ORIF = open reduction and internal fixation, ROM = range of motion, TFCC = triangular fibrocartilage complex.

**Keywords:** adult, distal radioulnar joint dislocation, missed diagnosis, old Monteggia fracture, radial head disruption

## 1. Introduction

The Monteggia injury was originally defined by Giovanni Monteggia in 1814, and a comprehensive revision of this lesion

Editor: N/A.

Written informed consent was obtained from the patient for publication of this case report and any accompanying images. A copy of the consent form is available for review by the Editor of this journal.

Natural Science Foundation of the Department of Science and Technology of Liaoning Province (201602836).

The authors have no funding and conflicts of interest to disclose.

Department of Orthopedics, Shengjing Hospital of China Medical University, Shenyang, China.

\* Correspondence: Wan'an Xiao, Department of Orthopedics, Shengjing Hospital of China Medical University, No. 36 Sanhao St, Heping District, Shenyang, 110004, China (e-mail: cmuxwa@foxmail.com).

Copyright © 2019 the Author(s). Published by Wolters Kluwer Health, Inc. This is an open access article distributed under the terms of the Creative Commons Attribution-Non Commercial License 4.0 (CCBY-NC), where it is permissible to download, share, remix, transform, and buildup the work provided it is properly cited. The work cannot be used commercially without permission from the journal.

Medicine (2019) 98:16(e15310)

Received: 30 November 2018 / Received in final form: 15 March 2019 /

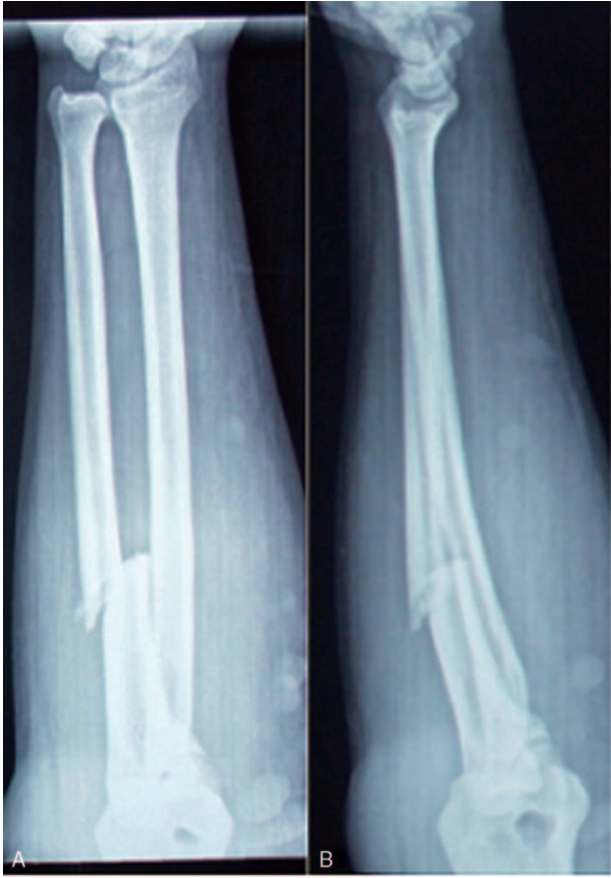Accepted: 25 March 2019

<http://dx.doi.org/10.1097/MD.00000000000015310>

pattern was described by Bado and Jupiter as the “disruption of proximal radioulnar joint with a concomitant fracture involvement of both the radius and ulna.”<sup>[1]</sup> And the old Monteggia fracture is defined as the persistent dislocation of the radial head for least 4 weeks after injury, which is always caused by the misdiagnosis or postoperative dislocation.<sup>[2,3]</sup> Numerous studies have been reported on the potential complications of Monteggia fracture, such as recurrent dislocation of the radial head, heterotopic ossification of the elbow, nerve palsy, malunion of the ulna, and residual forearm deformity.<sup>[4,5]</sup> However, to our knowledge, none of the reported cases in the orthopaedic literature refer to the injury sustained in our patient. Herein, we report a misdiagnosed case in which the patient underwent successively osteofascial compartment syndrome open decompression, ulnar open reduction and internal fixation (ORIF), as well as reoperation of old Monteggia fracture combined with secondary distal radioulnar joint (DRUJ) disruption. The purpose of this article is to investigate the cause of the extremely rare complication of old Monteggia fracture and to avoid potential pitfalls in the treatment of similar complex cases.

## 2. Case presentation

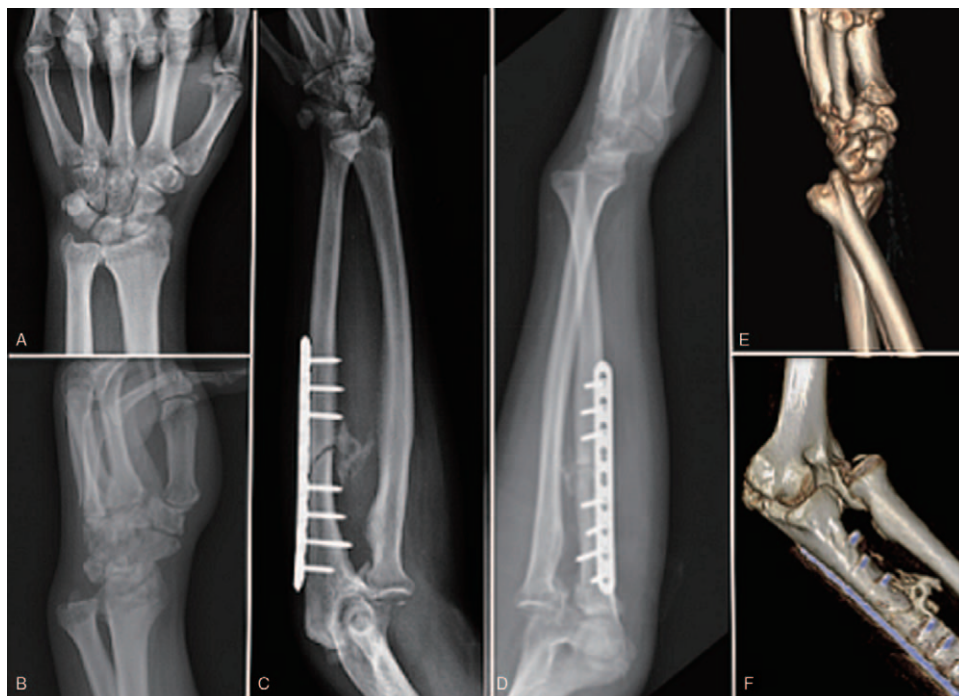
A 38-year-old male presented to our hospital outpatient office complaining of left elbow stiffness and ongoing wrist dysfunction with a history of injury to the left forearm caused by a forklift



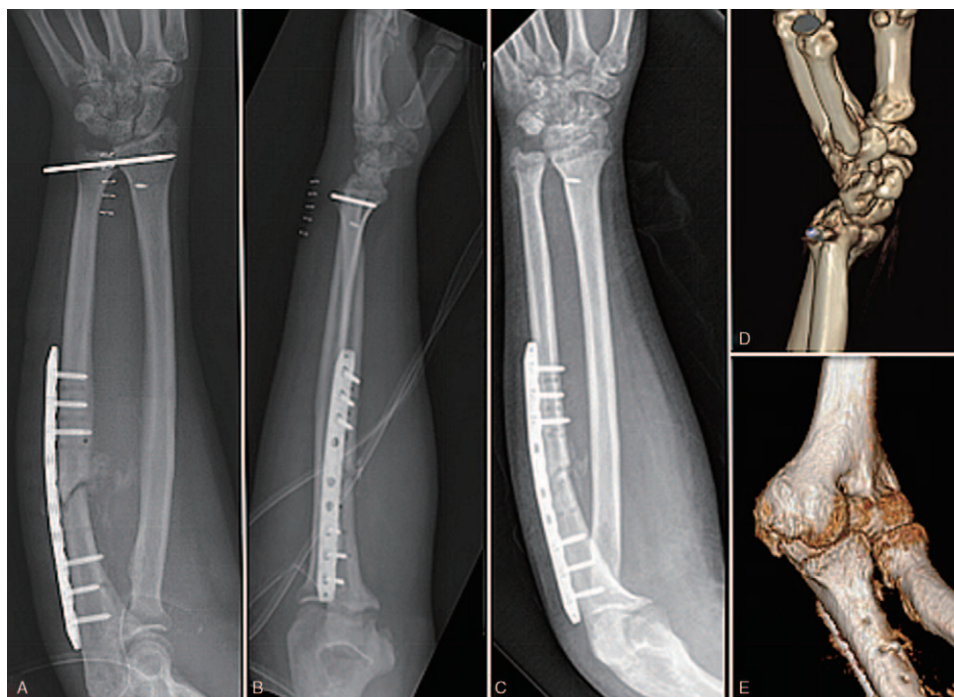
**Figure 1.** AP (A) and lateral (B) radiographs of the left forearm reveal dislocation of radial head with a concomitant fracture of the third proximal ulna. There is no concomitant dislocation of DRUJ in the initial presentation.

accident that occurred 5 months previously. Tracing back to the patient's initial record at the local hospital, the patient underwent fasciotomy and decompression of the forearm on the same day of the accident due to osteofascial compartment syndrome. Two months after the accident, he was misdiagnosed with a simple ulnar fracture and another operation called ulnar ORIF was performed without treatment of the dislocation of the radial head. Radiography demonstrated dislocation of the radial head with a concomitant fracture of the third proximal ulna upon initial presentation at the local hospital (Fig. 1A and B). In view of the extreme dissatisfaction with the recovery effect, the patient came to our hospital for further treatment. Upon examination, the patient was right-hand dominant with pain and deformity of the left elbow and the ulnar side of the wrist. Two old scars were visible on the left forearm, but no distal neurovascular deficits were noted. However, the piano-key test and the table-top test were positive according to the physical examination. Moreover, he was nearly disabled, with an extremely limited range of motion (ROM) of the left elbow and wrist compared with the contralateral extremity. According to the reexamination of wrist radiography, the secondary dorsal dislocation of the DRUJ was obvious both clinically and radiographically (Fig. 2A and B). Advanced computed tomography (CT) also confirmed the same diagnosis (Fig. 2E).

The patient underwent a revision operation for definitive reconstruction under general anaesthesia in a supine position, with the arm laid across the chest under a tourniquet. First, using the Boyd posterior-lateral elbow approach, the ulnar plate was removed. Heterotopic ossification and the callus were debrided. Capsulotomy and tenolysis were performed. Then, the radial head was reduced through reposition of the intact annular ligament and provisionally fixed with a 2.0-mm transcapsular Kirschner wire. Second, the ulnar transverse osteotomy and autologous bone graft with the callus were performed around the



**Figure 2.** Radiographs (C, D, and F) of left forearm demonstrating persistent dislocation of radial head. AP (A) and lateral (B) radiographs of the left wrist reveal secondary dislocation of DRUJ. 3D reconstruction CT (E) of the left wrist confirm secondary dorsal dislocation of DRUJ.



**Figure 3.** Immediate postoperative AP (A) and lateral (B) radiographs of the left forearm showing the well-reduced DRUJ was immobilized with a 2.0-mm K-wire and the radioulnar ligament was repaired with an anchor. Three months postoperative radiograph showing the well formation of callus. And postoperative CT images show no dislocation of proximal and distal radioulnar joint.

fracture position. Then, ulnar fixation was accomplished by one locking compression plate with 6 lag screws, and removal of the temporary transcapsular Kirschner wire proceeded uneventfully. Finally, the DRUJ was immobilized with a 2.0-mm Kirschner wire, and the radioulnar ligament was repaired with an anchor (Fig. 3A and B). Postoperatively, the forearm was immobilized and rotated in supination by a long-arm cast for 4 weeks. The patient tolerated the surgical procedures well and made a satisfactory recovery during hospitalization. At 4 weeks, the patient was subjected to occupational therapy after removal of the cast and Kirschner wire. At 6 weeks, he was allowed to perform light activities. At 12 weeks, he was allowed to perform routine household work.

At the 4-week follow-up, the patient did not complain of pain at the elbow or the ulnar side of the wrist, and the deformity had also disappeared. At the 12-week follow-up, callus formation as well as no dislocation of the proximal and distal radioulnar joints was noted on the radiographic images (Fig. 3C–E). Furthermore, the ROM of the elbow and wrist was slightly improved compared with before the surgery. At the 1-year follow-up, the ROM of the elbow and wrist was significantly improved through continuous postoperative physiotherapy. Although redislocation and stiffness of joints are the major constraints of clinical prognosis, the patient still received a satisfactory result, with painless and improved movement (flexion 90°, extension 30°, pronation 50°, and supination 30°) of the forearm without observed redislocation and relapse (Fig. 4).

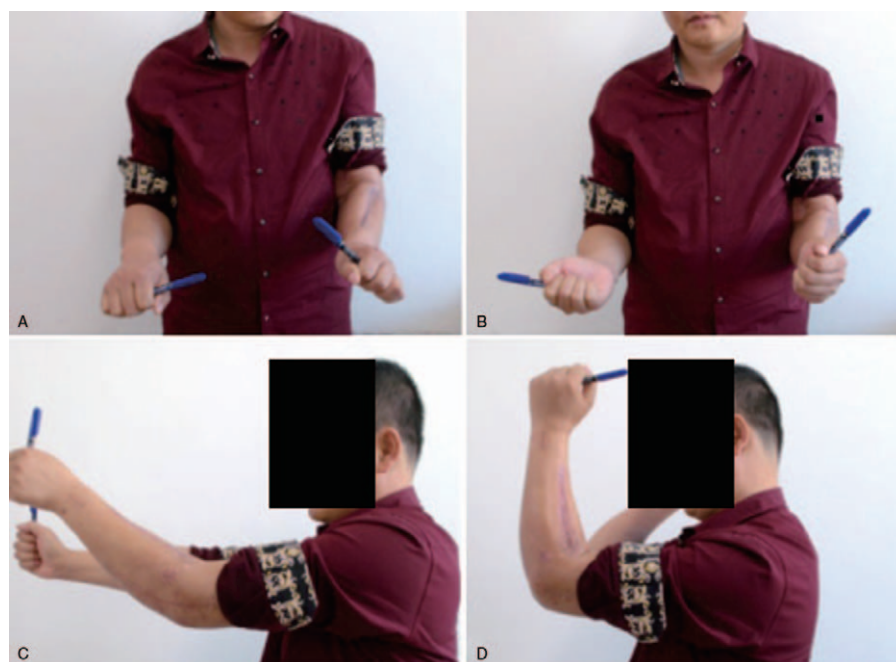### 3. Discussion

Transverse and longitudinal stability is necessary for the human forearm, which is viewed as a dynamic structural entirety.<sup>[6]</sup> To

accomplish accurate and remarkable tasks, the forearm bones must act as a single functional unit in consort with the interosseous membranes and ipsilateral radioulnar joints. Anatomical restoration and stable fixation are mandatory in the treatment of any forearm fracture, which should be treated in an equivalent manner as an intraarticular fracture.<sup>[7]</sup> Any injury to the complex three-dimensional unit may result in notoriously poor outcomes of forearm.

Persistent or recurrent dislocation of the radial head, as a common complication of old Monteggia fracture and as the main cause of initial operative failure, has been repeatedly reported by numerous authors.<sup>[8]</sup> During the initial presentation, the instantaneous Monteggia fracture might be treated as a simple ulnar fracture without treatment of the dislocation of the radial head. Missed Monteggia lesions result in ulnar malunion, contributing to the persistent dislocation or difficult restoration of the radial head that was caused by unsatisfactory reduction and fixation during the initial operation.<sup>[9]</sup> The pathological features of old Monteggia fracture mainly include ulnar shortening deformities, refractory radial head dislocation, interosseous membrane, and capsular contracture deformities and heterotopic ossification. These features interact with each other as causative factors of disabilities.<sup>[10]</sup> Presumably, the persistent dislocation of the radial head was due to the accumulation of the heterotopic ossification of the elbow over time, which is another reason to aggravate the persistent dislocation of the radial head. As described in our case, the missed diagnosis during the initial presentation, the malunion of the ulna, and the heterotopic ossification of the elbow as the contributing factors to persistent dislocation of the radial head is strongly suggestive.

Chronic dislocation of the DRUJ accounts for approximately 14.44% of total joint dislocation and 7% of forearm fracture.



**Figure 4.** At the 1-year follow-up, the patient demonstrating movement (flexion 90°, extension 30°, pronation 50°, and supination 30°) of the left forearm.

Biomechanical studies have consistently revealed that the major stabilizer of the DRUJ is the triangular fibrocartilage complex (TFCC), especially the triangular fibrocartilage and the dorsal and volar radioulnar ligaments.<sup>[11]</sup> The normal structure of the distal radioulnar joint, along with the proximal radioulnar joint, the forearm bones, and the interosseous membranes, is necessary for forearm longitudinal stability, and this structure is of great importance in pronosupination and load transmission over the forearm. Among these factors, the length of the radius and ulna represents the main stability factor.<sup>[12]</sup> Inadequate treatment or ulnar malunions and the persistent dislocation of the radial head caused by the failure of anatomic and stable reconstruction of the ulna represent the main sources of the notoriously poor outcomes. Moreover, fasciotomy and decompression may cause iatrogenic damage to the interosseous membrane, leading to chronic secondary dislocation of the DRUJ. Leung et al<sup>[13]</sup> proposed an unrecognized crisscross injury mechanism in which they hypothesized that the interosseous membrane might act as a pivot point between the radius and ulna based on the disruption of the proximal radioulnar joint with a concomitant dislocation of the DRUJ. In our case, the significant distinguishing feature from the Essex-Lopresti lesion was dorsal dislocation of the DRUJ combined with radial head anterior dislocation, but no proximal migration of the radius was revealed on X-ray radiographs. Considering the underlying cause of secondary dislocation of the DRUJ, we performed ulnar osteotomy around the fracture to restore the longitudinal height of the ulna, and we performed anatomical reconstruction of the radioulnar ligament with an anchor to tighten the transverse gap of the joint in our patient.

In summary, occult injuries of the proximal and distal joints are often neglected in forearm fractures. Paying close and continuous attention to the clinical and radiographic examinations of the elbow and wrist joint is necessary to avoid misdiagnosis and missed diagnosis.<sup>[14]</sup> Considering the notoriously poor outcomes, the importance of early recognition and accurate treatment

should be emphasized repeatedly in similar lesions. Moreover, ulnar osteotomy, radioulnar ligament repair, and temporary fixation of the DRUJ with a Kirschner wire should be considered as an effective strategy for anatomical reconstruction and stable fixation of the injury.

### Acknowledgments

The authors thank Wan-an Xiao and Jian-jun Li for their advice and expertise, and also thank American Journal Experts for English language editing. Special thanks to the patient for his time, effort, and consent for this case report.

### Author contributions

**Conceptualization:** Yanchao Zhang, Wan'an Xiao, Jianjun Li.

**Data curation:** Yanchao Zhang, Wan'an Xiao.

**Formal analysis:** Wan'an Xiao, Jianjun Li.

**Methodology:** Jianjun Li.

**Project administration:** Yanchao Zhang, Wan'an Xiao.

**Software:** Yanchao Zhang.

**Supervision:** Jianjun Li.

**Validation:** Jianjun Li.

**Visualization:** Yanchao Zhang, Wan'an Xiao.

**Writing – original draft:** Yanchao Zhang.

**Writing – review and editing:** Wan'an Xiao, Jianjun Li.

Jianjun Li orcid: 0000-0002-0883-673X.

### References

- [1] Rehim SA, Maynard MA, Sebastin SJ, et al. Monteggia fracture dislocations: a historical review. *J Hand Surg* 2014;39:1384.
- [2] Gennaro GLD, Martinelli A, Bettuzzi C, et al. Outcomes after surgical treatment of missed Monteggia fractures in children. *Musculoskeletal Surg* 2015;99:75–82.
- [3] Goyal T, Arora SS, Banerjee S, et al. Neglected Monteggia fracture dislocations in children: a systematic review. *J Pediatr Orthop B* 2015;24:191–9.

- [4] Cheung EV, Yao J. Monteggia fracture-dislocation associated with proximal and distal radioulnar joint instability. A case report. *J Bone Joint Surg Am* 2009;91:950–4.
- [5] Nishimura M, Itsubo T, Horii E, et al. Tardy ulnar nerve palsy caused by chronic radial head dislocation after Monteggia fracture: a report of two cases. *J Pediatr Orthop B* 2016;25:450–3.
- [6] Matthias R, Wright TW. Interosseous membrane of the forearm. *J Wrist Surg* 2016;1:188–93.
- [7] Schemitsch EH, Richards RR. The effect of malunion on functional outcome after plate fixation of fractures of both bones of the forearm in adults. *J Bone Joint Surg Am* 1992;74:1068.
- [8] Horii E, Nakamura R, Koh S, et al. Surgical treatment for chronic radial head dislocation. *J Bone Joint Surg Am* 2002;84:1183.
- [9] Hasler CC, Von LL, Hell AK. Open reduction, ulnar osteotomy and external fixation for chronic anterior dislocation of the head of the radius. *Bone Joint J* 2005;87:88–94.
- [10] Mehta SD. Missed Monteggia fracture. *J Bone Joint Surg Br* 1993;75:337.
- [11] Ward LD, Ambrose CG, Masson MV, et al. The role of the distal radioulnar ligaments, interosseous membrane, and joint capsule in distal radioulnar joint stability. *J Hand Surg* 2000;25:341–51.
- [12] Thomas BP, Sreekanth R. Distal radioulnar joint injuries. *Indian J Orthop* 2012;46:493.
- [13] Leung YF, Ip SPS, Ip WY, et al. The crisscross injury mechanism in forearm injuries. *Arch Orthop Trauma Surg* 2005;125:298.
- [14] Macintyre NR, Ilyas AM, Jupiter JB. Treatment of forearm fractures. *Acta Chir Orthop Traumatol Cech* 2009;76:7–14.