

# Complete remission of intractable bullous erythema multiforme with thalidomide therapy: A case series



Tian Ran Zhu, MD, Emily R. Nadelmann, BA, and Steven R. Cohen, MD, MPH  
Bronx, New York

**Key words:** erythema multiforme; oral mucocutaneous blistering disease; thalidomide.

## INTRODUCTION

Chronic bullous oral mucositis may exhibit clinicopathologic features of erythema multiforme (EM), lichen planus, drug hypersensitivity, and primary blistering disorders. Although this clinical amalgam is responsive to systemic corticosteroids, strategies to achieve a durable remission with steroid-sparing agents often fail. Thalidomide, a macrolide lactone, was developed in Europe during the 1950s as a sedative to alleviate morning sickness of pregnancy. It was later withdrawn from the market due to catastrophic teratogenicity.<sup>1</sup> However, the subsequent discovery of antiinflammatory and immunomodulatory effects thought to be mediated by tumor necrosis factor- $\alpha$  inhibition led the US Food and Drug Administration in 1997 to approve thalidomide for erythema nodosum leprosum under meticulous scrutiny.<sup>2</sup> Other off-label uses now include treatment of HIV-associated mucosal ulceration and aphthae associated with neutrophilic dermatoses, particularly Behcet disease and other intractable bullous oral mucous membrane disorders.<sup>2</sup> We present 3 patients with recalcitrant bullous EM of 1 to 10 years duration who experienced complete remissions on a daily regimen of thalidomide.

## CASE SERIES

### Case 1

A 19-year-old Hispanic woman with depression, recurrent urinary tract infections, tinea corporis, hyperhidrosis, and iatrogenic Cushing syndrome presented in 2011 with an 8-year history of recurrent EM affecting oropharynx, lips, palms, and soles. At

### Abbreviation used:

EM: erythema multiforme

her initial visit, there were vesicles, bullae, and dried crusted erosions involving the lips and oral mucous membranes, as well as generalized erythematous plaques on the upper torso and extremities, some of which were targetoid (Fig 1, A). Biopsy of a lesion from the dorsal surface of the tongue revealed necrotic keratinocytes, detachment of epithelium from the submucosa, and a perivascular and interstitial inflammatory infiltrate consistent with chronic bullous EM.

Complete remission was achieved with prednisone (1.0 mg/kg/day) after 2 weeks; however, tapering below 0.5 mg/kg led to recurrent disease. Failed steroid-sparing strategies during a period of 2 years included sequential trials for 8 to 12 weeks of oral methotrexate (15 mg weekly), azathioprine (50 mg 3 times daily), mycophenolate mofetil (500 mg 3 times daily), dapsone (75 mg daily), intravenous immunoglobulin G (2 g/kg divided into 4 daily doses, monthly), and rituximab (1000 mg at 0 and 2 weeks). Despite the absence of herpes simplex, valacyclovir (1 g daily) was administered prophylactically. The more extreme relapses causing dyspnea, dysphagia, and odynophagia required multiple hospitalizations.

After cycling through many therapies often effective in bullous EM, a decision to initiate thalidomide (200 mg daily) led to a durable and sustained

From the Division of Dermatology, Department of Medicine, Albert Einstein College of Medicine, Bronx.

Dr Zhu and Author Nadelmann contributed equally to this article. Funding sources: None.

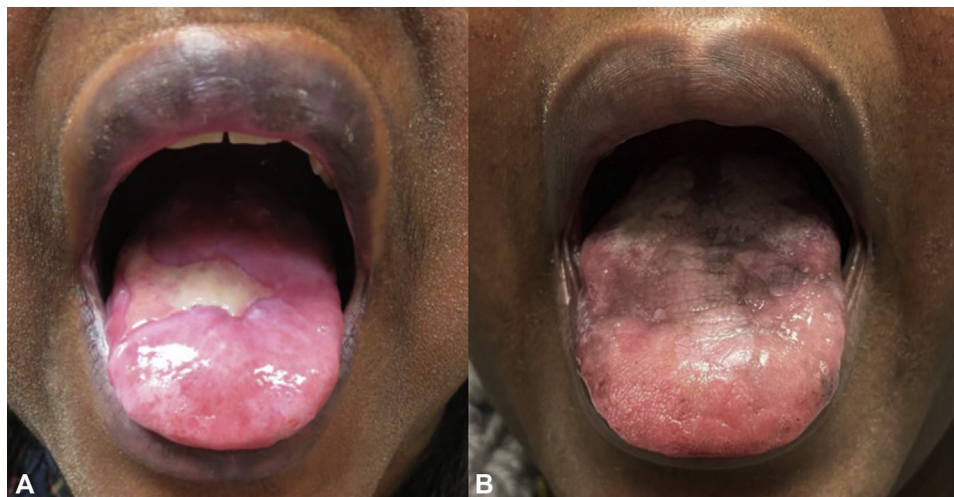IRB approval status: Not applicable.

Correspondence to: Steven R. Cohen, MD, MPH, Division of Dermatology, Department of Medicine, Montefiore Medical Center, 3411 Wayne Avenue, 2nd Floor, Suite Dermatology, Bronx, NY 10467. E-mail: [srcohen@montefiore.org](mailto:srcohen@montefiore.org).

JAAD Case Reports 2021;15:76-9.  
2352-5126

© 2021 by the American Academy of Dermatology, Inc. Published by Elsevier, Inc. This is an open access article under the CC BY-NC-ND license (<http://creativecommons.org/licenses/by-nc-nd/4.0/>).

<https://doi.org/10.1016/j.jidcr.2021.07.013>



**Fig 1.** Case 1: bullous erythema multiforme. **A**, Bulla and erosions on the dorsum of the tongue. **B**, Reepithelialization with hyperpigmentation following thalidomide therapy was observed.

remission of all disease (Fig 1, B). Prednisone, methotrexate, dapsone, and valacyclovir were gradually withdrawn during a period of 6 months. The patient has remained disease-free on thalidomide (200 mg daily), as a monotherapy during the ensuing 9 years. It is noteworthy that mild flares occurred on 2 separate occasions when the thalidomide dosage was lowered.

### Case 2

A 53-year-old Hispanic woman with a past medical history of depression, fibromyalgia, and osteoarthritis presented in 2012 with a 1-year history of EM characterized by multiple oral mucosal erosions and erythematous plaques on the upper extremities (Fig 2, A). Two biopsies confirmed the diagnosis of EM. There was no clear trigger for outbreaks (eg, herpes simplex virus, drug). Recurrent oral erosions, blisters, and targetoid plaques on the palms were unresponsive to prednisone (0.25 mg/kg daily), azathioprine (50 mg twice daily), and dapsone (100 mg daily). Complete remission was only achieved after 2 weeks of high-dose prednisone (1 mg/kg daily).

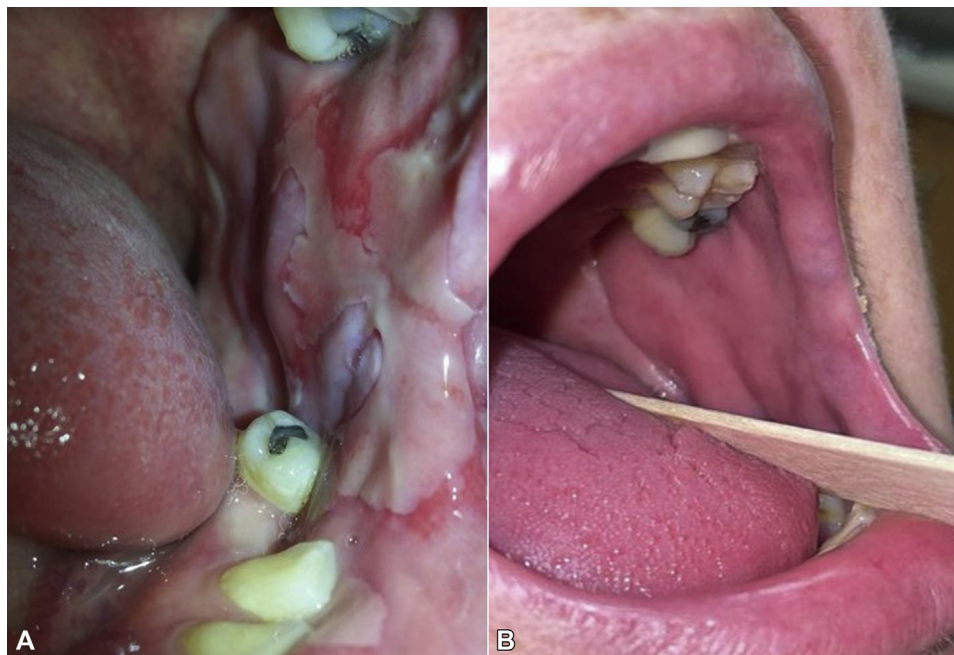
A steroid-sparing regimen of prednisone (0.25 mg/kg daily), methotrexate (15 mg weekly), dapsone (75 mg daily), and valacyclovir (500 mg daily) maintained the remission, but unpredictable flares required transient steroid increases during the next 2 years. In 2014, an insurance preauthorization was initiated for thalidomide. After more than 12 months, thalidomide coverage was finally approved. In early 2015, during a mild flare of oral blistering, thalidomide (200 mg daily) induced a

complete and durable remission within weeks (Fig 2, B). Upper extremity paresthesias in the first few months of treatment resolved spontaneously with ibuprofen and have not recurred. Adjunctive therapy with prednisone (10 mg daily), methotrexate (15 mg weekly), and dapsone (75 mg daily) was uneventfully discontinued.

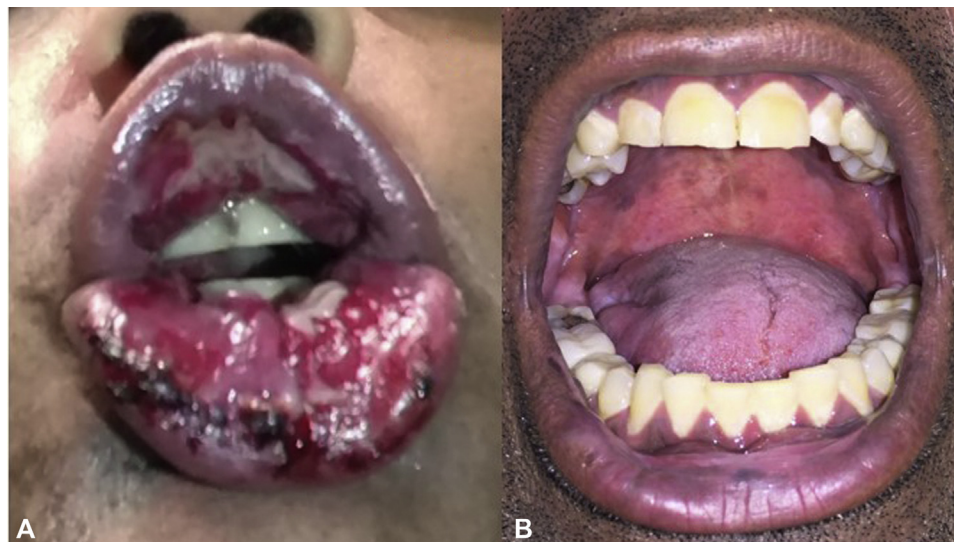### Case 3

A 40-year-old Caucasian man, who was a firefighter, presented with a 10-year history of blistering oral mucositis and targetoid erythematous plaques on the elbows, knees, hands, and feet. Other than extensive vitiligo, he was in good general health. On physical examination, the patient had oral erosions and crusting of the upper and lower labial mucosae, focal erosions on the buccal mucosae (Fig 3, A), and red to violaceous annular and targetoid plaques on the hands, legs, and feet.

Routine histopathology of a mucosal blister showed necrotic epithelium and a dense lymphoplasmacytic inflammatory cell infiltrate. Direct immunofluorescence was negative. The patient was given intramuscular triamcinolone 100 mg and intralesional triamcinolone 10 mg/mL for oral erosions. He was started on a regimen of prednisone (0.5 mg/kg daily) and methotrexate (7.5 mg weekly). After 4 weeks, a prednisone taper was associated with recurrent mucosal blisters, prompting initiation of hydroxychloroquine (200 mg twice daily) and rituximab infusions (1000 mg at 0 and 2 weeks). Recurrent oral blisters flared with every attempt to taper prednisone. After 8 months, thalidomide (200 mg daily) was initiated and resulted in a



**Fig 2.** Case 2: bullous erythema multiforme. **A**, Blisters and erosions on left buccal mucosa; **(B)** normal mucosa following thalidomide therapy.



**Fig 3.** Case 3: bullous erythema multiforme. **A**, Erosions and hemorrhagic crusts on lips and oral mucosa; **(B)** normal mucosa following thalidomide therapy.

complete and durable remission of mucosal and skin disease (Fig 3, B). Prednisone, methotrexate, and hydroxychloroquine were gradually withdrawn.

## DISCUSSION

EM is an uncommon immune-mediated disorder.<sup>3</sup> There are many potential triggers for EM, including herpes simplex virus, various medications, and alcohol. Although the disease is often self-limited, it may be recurrent, with a relapsing and remitting

course.<sup>4</sup> The pathogenic mechanism of EM is poorly understood but thought to involve a cell-mediated immune process directed against viral antigens deposited in lesional skin, involving release of interferon gamma and a subsequent recruitment of CD4<sup>+</sup> helper T cells. A number of studies suggest that tumor necrosis factor alpha is associated with drug-induced EM.<sup>5</sup>

We present 3 patients with chronic, intractable oral and cutaneous EM unrelated to infection, drugs,

or autoimmune phenomena. Although responsive to high-dose systemic corticosteroids, debilitating oral mucositis relapsed with steroid withdrawal in all cases, despite concomitant immunosuppressive therapies, biologic agents, and/or antimicrobials. The addition of thalidomide 200 mg daily not only cleared bullae, leading to reepithelialization of all mucosal and cutaneous surfaces, but also allowed discontinuation of adjunctive therapies and provided a durable and well-tolerated treatment.

Thalidomide was withdrawn from the market in 1961 after linkage to phocomelia in thousands of babies.<sup>6</sup> Although thalidomide was used to treat erythema nodosum leprosum in the mid-1960s, it was not approved by the Food and Drug Administration until 1997. Currently, thalidomide is considered 99% effective for erythema nodosum leprosum (type II) and a variety of off-label uses, including HIV-associated mucosal ulceration, aphthae associated with neutrophilic dermatoses, including Behcet disease as well as intractable bullous oral mucous membrane disorders, such as oral pemphigus vulgaris and cicatricial pemphigoid.<sup>7-9</sup>

Although thalidomide has antiinflammatory and immunomodulatory properties regarding several skin disorders, its precise mechanism of action remains unknown. Inhibition of lymphocyte and neutrophil chemotaxis, as well as inhibition of phagocytosis by neutrophils and macrophages appear to be important physiologic effects.<sup>10</sup> Thalidomide also decreases levels of proinflammatory cytokines, tumor necrosis factor alpha, and interferon gamma, which are both considered central to the development of EM.<sup>11</sup>

Thalidomide is contraindicated in pregnancy. A single dose during the first 21 to 36 days yields a 100% prevalence of birth defects.<sup>1</sup> Both males and females must be counseled to use 2 forms of contraception.<sup>12</sup> Dermatologic side effects include brittle fingernails, xerosis, pruritus, and red palms, whereas the more frequent constitutional side effects are sedation, constipation, and neurotoxicity with long-term therapy.<sup>13</sup>

Thalidomide, despite its early tragic setback, has emerged as an important therapy in many inflammatory dermatoses. Given the dramatic and complete remission of disease in our 3 patients,

we propose that thalidomide, through its anti-inflammatory and immunomodulatory properties, may serve as a novel therapeutic approach for intractable bullous EM and other mucosal blistering disorders.

#### Conflicts of interest

None disclosed.

#### REFERENCES

1. Vargesson N. Thalidomide-induced teratogenesis: history and mechanisms. *Birth Defects Res C Embryo Today*. 2015;105(2):140-156. <https://doi.org/10.1002/bdrc.21096>
2. Chen M, Doherty SD, Hsu S. Innovative uses of thalidomide. *Dermatol Clin*. 2010;28(3):577-586. <https://doi.org/10.1016/j.det.2010.03.003>
3. Siegel MA, Balciunas BA. Oral presentation and management of vesiculobullous disorders. *Semin Dermatol*. 1994;13(2):78-86.
4. Assier H, Bastuji-Garin S, Revuz J, Roujeau JC. Erythema multiforme with mucous membrane involvement and Stevens-Johnson syndrome are clinically different disorders with distinct causes. *Arch Dermatol*. 1995;131(5):539-543. <https://doi.org/10.1001/archderm.1995.01690170041005>
5. Paulino L, Hamblin DJ, Osondu N, Amini R. Variants of erythema multiforme: a case report and literature review. *Cureus*. 2018;10(10):e3459. <https://doi.org/10.7759/cureus.3459>
6. Franks ME, Macpherson GR, Figg WD. Thalidomide. *Lancet*. 2004;363(9423):1802-1811. [https://doi.org/10.1016/S0140-6736\(04\)16308-3](https://doi.org/10.1016/S0140-6736(04)16308-3)
7. Vaillant L, Samimi M. Aphthous ulcers and oral ulcerations. Article in French. *Presse Med*. 2016;45(2):215-226. <https://doi.org/10.1016/j.lpm.2016.01.005>
8. Zhang B, Mao X, Zhao W, Jin H, Li L. Successful treatment with thalidomide for pemphigus vulgaris. *Ther Adv Chronic Dis*. 2020;11:2040622320916023. <https://doi.org/10.1177/2040622320916023>
9. Duong DJ, Moxley RT III, Kellman RM, Pincus SH, Gaspari AA. Thalidomide therapy for cicatricial pemphigoid. *J Am Acad Dermatol*. 2002;47(suppl 2):S193-S195. <https://doi.org/10.1067/mj.2002.109255>
10. Ito T, Handa H. Molecular mechanisms of thalidomide and its derivatives. *Proc Jpn Acad Ser B Phys Biol Sci*. 2020;96(6):189-203. <https://doi.org/10.2183/pjab.96.016>
11. Saito Y, Nakamura R. Mechanisms of severe cutaneous adverse reactions and a new treatment strategy. Article in Japanese. *Yakugaku Zasshi*. 2019;139(12):1557-1562. <https://doi.org/10.1248/yakushi.19-00181-3>
12. Kim JH, Scialli AR. Thalidomide: the tragedy of birth defects and the effective treatment of disease. *Toxicol Sci*. 2011;122(1):1-6. <https://doi.org/10.1093/toxsci/kfr088>
13. Perri AJ III, Hsu S. A review of thalidomide's history and current dermatological applications. *Dermatol Online J*. 2003;9(3):5. <https://doi.org/10.5070/D35FK5W0QV>