



The Application of MEVEC 3D Doppler Ultrasound Technique for a New Classification of Morpho-Functional Phenotypes in Lower Limbs Venous Diseases

Aldo Innocente Galeandro¹, Cristina Galeandro², Pietro Scicchitano ³, Rosanna Clima⁴, Ilenia Annunziata Ritacco⁵, Massimiliano Dellisanti Fabiano Vilaridi¹, Egidio Di Ponzio¹, Annamaria Annichiarico¹, Francesco Ciciarello⁶, Vincenzo Contursi⁷, Angelika Elzbieta Wegierska³, Marco Matteo Ciccone ³

¹Unit of Technological Medical Research of the Parco Scientifico-Tecnologico, University of Bari "A. Moro", Bari, Italy; ²Section of Vascular Surgery, Department of Emergency and Organ Transplantation, University of Bari, Bari, Italy; ³Section of Cardiovascular Diseases, Department of Emergency and Organ Transplantation, University of Bari, Bari, Italy; ⁴BROWSer S.r.l. - Bioinformatics Resource for Omics Wide Services, Dipartimento di Bioscienze, Biotecnologie e Biofarmaceutica, University of Bari "A. Moro", Bari, Italy; ⁵Section of Cardiac Surgery, Department of Emergency and Organ Transplantation, University of Bari, Bari, Italy; ⁶Department of Cardiovascular, Respiratory, Geriatric and Morphologic Sciences of "Umberto I" Polyclinic of Rome, "Sapienza" University, Rome, Italy; ⁷Italian Society for Interdisciplinary Primary Care, Bari, Italy

Correspondence: Pietro Scicchitano, Section of Cardiovascular Diseases, Cardio-Thoracic Department, University of Bari "A. Moro", Piazza G. Cesare, Bari, I I – 70124, Italy, Email piero.sc@hotmail.it; pietro.sc.83@libero.it

Introduction: MEVEC 2.1 is a novel 3D mapping software dedicated to the evaluation of the venous vascular three of the lower limbs. It has already proven as a sensitive, specific, and accurate technique able to provide better morphologic and functional details of the lower limb venous system than standard reports. The aim of this study was to identify specific morpho-functional graphic phenotypes in lower limb venous diseases by means of MEVEC 2.1.

Materials: Three-hundred eleven consecutive outpatients underwent lower limb Doppler ultrasound examination by means of the MEVEC 2.1 technique. All of them showed at least one among these pathological findings: venous insufficiency, thrombosis, incompressibility, and/or incompetent.

Results: We tried to evaluate possible clusters among the different morpho-functional findings from the venous maps in order to outline reproducible phenotypes. Correlation indexes allowed us to provide a classification in morpho-functional phenotypes in order to standardize the data from examinations performed by different physicians. Twelve phenotypes had been proposed.

Conclusion: The study showed that the MEVEC 2.1 technique provides a standardized classification that allows physicians identifying phenotypes yielded by 3D mapping of the veins of the lower limbs.

Keywords: lower limb venous diseases, venous ultrasound, MEVEC, 3D mapping, venous mapping

Introduction

Chronic lower limb venous insufficiency is one of the most widespread diseases in industrialized countries, mainly affecting female gender (5:1 ratio compared to male).¹⁻³ Doppler ultrasound approach remains the best approach for the diagnosis of lower limb venous diseases, far away replacing phlebography for the final evaluation of venous, peripheral districts.^{4,5}

Venous Doppler ultra-sound performed with the use of MEVEC 2.1 software moves forward the ancient B-dimensional approach to lower limb diseases by performing a full evaluation of lower limb venous system by reporting the Venous Hemodynamic Map, an extremely complex and accurate examination.^{6,7} The reproducibility of the standard venous mapping is challenging.⁸⁻¹⁴ Independently from the CEAP classification, venous mapping of the lower limbs may carry out false-positive examinations.¹¹ Labropoulos and Leon¹⁴ outlined the difficulties in correctly

identifying the hemodynamic features of the venous drainage, as well as the representation of the anatomic variations of the whole venous tree of the lower limbs. Malgor and Labropoulos¹² rightly outlined one of the most important limitation of the ultrasound evaluation of the venous drainage of the lower limbs: the poor training course of physicians who often try to perform the examinations.

Different methods had been created in order to overcome the limitations of the Doppler ultrasound. For instance, invasive assessment of venous vascular tree had been proposed with the application of Intravascular ultrasound (IVUS).¹⁵ IVUS was considered during some peripheral venous interventions to better address the surgeon. Nevertheless, IVUS was not superior than venography but rather seemed to underestimate venous stenosis.¹⁵ For instance, IVUS is an invasive method and could not generally be applied in daily outpatient activities. Contrast imaging techniques might provide more reproducible approaches to venous disorders. Computed tomography (CT) venogram has been introduced for the evaluation of venous disorders.^{16,17} Lee et al¹⁷ identified a sensitivity of 98.2% and a specificity of 83.3% in the evaluation of great saphenous vein insufficiency by CT venogram as compared to duplex ultrasound. Indeed, the use of CT requires local expertise, increases the costs of national health system, prolongs waiting-list duration, and need contrast-agents which may impact on the overall health of patients. Recently, venous magnetic resonance imaging (MRI) has been applied for the ed (TRANCE) MRI, which is the best evolution of MRI as applied to venous diseases as it allows reassessment of venous disorders.^{18–20} The adoption of triggered angiography non-contrast enhances the productivity of the technique and reduces the need for higher operator skills.^{18,19} As per CT imaging, contrast and TRANCE-MRI still represent a health system problem: apart from local expertise, the need for identifying dedicated centres and devices, the use of CT/MRI for several diagnostic aims other than venous disorders, and the related waiting list might reduce the daily use of such techniques.

The MEVEC 2.1 software allows carrying out a 3D venous map built from Doppler ultra-sound examination, whose results are easily performed by any physician who has basic knowledge of venous diseases and venous hemodynamics as previously demonstrated by our group ([Supplementary Figures 1 and 2](#)).^{6,7} The final image is a 3D venous map able to clearly display the anatomy and pathology of the lower limb veins, thus providing novel approach to further treatments of the venous disorder.

The lack of standardized examination protocols¹² and the difficulties in the evaluation of any anatomic variation in venous tree¹⁴ forced us to try to develop a new classification of the main features of the venous diseases of the lower limbs by means of the MEVEC 2.1 software. Specifically, we tried to identify possible correlations among alterations in different venous districts of the lower limbs by means of MEVEC 2.1. The aim of this paper was to evaluate the presence of specific phenotype and recurrences of venous abnormalities by means of MEVEC 2.1 in order to develop a new 3D classification of venous disorders of the lower limbs.

Materials and Methods

Three-hundred eleven (227 [73%] females) outpatient individuals followed-up from Angiology Section of the Cardiovascular Diseases Department of University of Bari, Bari, Italy, were enrolled. Inclusion criteria were the presence of lower limbs' chronic venous diseases symptoms (stage C0-C6, CEAP classification) and age >18 years old. Exclusion criteria were: peripheral arterial diseases, ischemic heart disease, previous stroke, severe chronic inflammatory diseases, severe obesity (body mass index [BMI] ≥ 25).

The study had been approved by the Ethics Committee in agreement with Helsinki declaration. All patients expressed written informed consent to participate in the study.

All of the patients underwent a complete Doppler ultrasound evaluation of the lower limb venous system. An expert physician in venous mapping performed all of the examinations in order to reduce possible variation in technique. In fact, in order to reduce bias, only one experienced physician performed ultrasound evaluations. Repeated measurements were performed in order to calculate intraclass correlation coefficient (ICC, good if >0.80) for the evaluation of intraobserver variability.²¹ We obtained a good reproducibility of the MEVEC 2.1 as the analysis revealed an ICC of 0.90.

Patients were examined in a warm room with temperature ranging from 18°C to 22°C. Physicians adopted the MEVEC 2.1 protocol to specifically perform the examinations.^{6,7} In particular, the patient was in orthostatic position. The limb was usually divided into four parts, and the veins of each part are listed in standard order. Then, the morpho-

functional characteristics of the veins – insufficiency, thrombosis, incontinence, etc – are represented by pre-specified symbols, which are automatically included by the software on the vessel representation.^{6,7} The report is automatically generated and data sent to the Core laboratory.^{6,7} The 3D image will allow the possibility for a better identification of the main features of the venous disorder of the lower limbs, while providing a reproducible evaluation of the maps from both expert and non-expert physicians as previously demonstrated by our group.^{6,7}

All of the patients underwent the following maneuvers during the study: the Valsalva maneuver, which elicits reflux in pathological conditions; proximal and distal manual compression: venous reflux is detected after the release of the compression.

We considered 500 milliseconds as the cutoff value for reflux in the superficial veins, deep femoral veins, and deep calf veins; 1000 milliseconds as the reflux cutoff value for the femoropopliteal veins, while the outward flow in the perforating veins was considered abnormal at 350 milliseconds.²²

The overall duration of the examination was about half – an – hour, while the transmission of the information to the Core Lab software was immediate as well as the generation of the report.

The MEVEC version 2.1 software (Tecno Medical Innovation srl – Treviso) has already been tested at the Unit of Technological Medical Research of the Parco Scientifico-Tecnologico of the University of Bari “A. Moro”.^{6,7}

Statistical Analysis

The data were computed in the form of descriptive values to identify the most frequent hemodynamic characteristics of veins of the lower limbs of the patients, which were found in each analyzed section of the legs.

Inferential statistics was adopted for calculating the correlations among phenotypes and sections. We tried to evaluate any potential correlation among different phenotypes in different areas of the leg by transforming data in order to report the presence or absence of a specific phenotype in each analyzed section. The resulting data were therefore correlated between them and hierarchically clustered, calculating the correlation with the Ward method.²³ The analysis of clustering was performed in relation to gender type. We therefore obtained a correlation score ranging from –1 to 1: positive values represent two elements often coexistent in the same patient, while negative values show phenotypes which did not coexist.

Results

Twenty-nine sections were analyzed and descriptive statistics showed that the most frequent phenotypes in the two datasets (right and left) are flow and reflux (Figure 1).

The application of inferential statistics for the identification of clustered correlations among phenotypes and leg sections outlined the presence of 26 correlations of potential interest (Table 1).

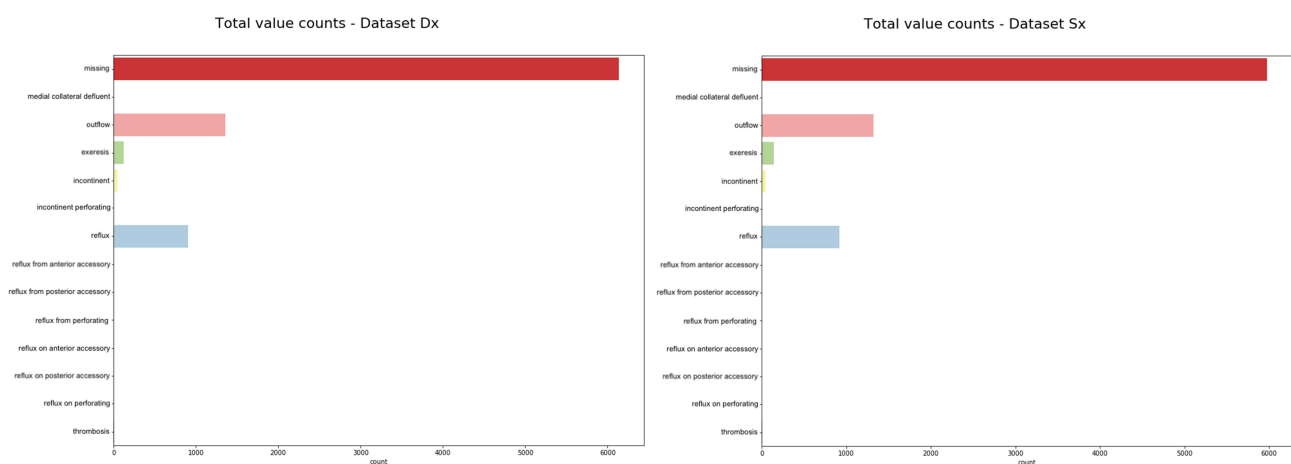


Figure 1 Phenotypes of lower limbs vascular venous alterations of both right and left legs as outlined by means of MEVEC 3D technique.

Table 1 Clustered Correlations Among Phenotypes and Leg Sections

Venous Hemodynamic Alterations Correlation	Correlation Coefficient (R)
2nd tract, III quartile: reflux from the lateral-collateral vein vs 2nd tract I quartile: reflux from the lateral-collateral vein	0.71
3rd tract I quartile: reflux from the medial-collateral vein vs 2nd tract II quartile: reflux from the lateral-collateral vein	0.5
3rd tract III quartile: reflux from the lateral-collateral vein vs 1st tract II quartile: reflux from the lateral-collateral vein	0.5
1st tract IV quartile: reflux from the perforating vein vs 1st tract I quartile: exeresis	0.58
1st tract I quartile: reflux vs 2nd tract I quartile: reflux from the lateral-collateral vein	0.5
1st tract I quartile: reflux vs 2nd tract III quartile: reflux from the lateral-collateral vein	0.71
3rd tract I quartile: reflux vs 2nd tract I quartile: reflux from the lateral-collateral	0.53
1st tract IV quartile: reflux from the lateral-collateral vein vs 3rd tract I quartile: reflux from the lateral-collateral vein	0.5
2nd tract I quartile: reflux from the medial-collateral vein vs 2nd tract IV quartile: reflux from the perforating vein	0.5
3rd tract III quartile: reflux from the lateral-collateral vein vs 2nd tract I quartile: reflux from the lateral-collateral vein	0.5
1st tract III quartile: reflux from the medial-collateral vein vs 2nd tract III quartile: reflux from the lateral-collateral vein	0.58
3rd tract IV quartile: reflux from the medial-collateral vein vs 2nd tract IV quartile: reflux from the lateral-collateral vein	0.71
1st tract I quartile: reflux from the medial-collateral vein vs 2nd tract III quartile: reflux from the lateral-collateral vein	0.71
3rd tract I quartile: deflux vs 2nd tract I quartile: reflux from the lateral-collateral vein	0.58
3rd tract I quartile: deflux vs 2nd tract I quartile: reflux from the medial-collateral vein	0.58
1st tract IV quartile: reflux from the lateral-collateral vein vs 3rd tract I quartile: reflux from the lateral-collateral vein	0.5
1st tract IV quartile: reflux from the medial-collateral vein vs 3rd tract III quartile: reflux	0.5
2nd tract IV quartile: reflux from the perforating vein vs 1st tract IV quartile: reflux	0.58
2nd tract IV quartile: reflux from the medial-collateral vein vs 3rd tract III quartile: reflux from the medial-collateral vein	0.58
2nd tract III quartile: reflux from the medial-collateral vein vs 3rd tract III quartile: reflux from the perforating vein	0.58
2nd tract III quartile: reflux vs 2nd tract IV quartile: deflux	0.53
1st tract IV quartile: reflux vs 2nd tract IV quartile: reflux from the medial-collateral vein	0.71
1st tract IV quartile: reflux from the lateral-collateral vein vs 2nd tract IV quartile: reflux	0.65
1st tract IV quartile: reflux from the medial-collateral vein vs 2nd tract IV quartile: reflux from the perforating vein	0.71
1st tract IV quartile: reflux from the perforating vein vs 2nd tract IV quartile: reflux from the lateral-collateral vein	0.71
1st tract IV quartile: reflux from the lateral-collateral vein vs 2nd tract III quartile: reflux from the perforating vein	0.5

According to these correlations, we derived 7 main different phenotypes subdivided into different subtypes (Figure 2). We named “phenotypes” cluster of venous disorders which were related each other after statistical inferences. The phenotypes are characterized by several alterations in the venous tree of the lower limbs taken together after statistical analysis in order to derive a reproducible predictive model of the venous tree of the lower limb.

A simplified flow chart (Figure 3) had been created in order to better delineate a possible use of the different phenotypes in clinical practice in order to better drive the decisions on the therapies for venous diseases.

Discussion

The standardization of Doppler ultrasound technique in evaluating venous vascular diseases is still a matter of debate.^{8–14} The introduction of MEVEC 2.1 and its validation improved the assessment of venous diseases in daily clinical practice by translating the ancient written data report on a 3D map able to better clarify the anatomic and physiopathological issues related to the assessment of venous diseases.^{6,7}

Indeed, the need for further simplification of the venous mapping technique forced our group to identify possible correlations among different phenotypes of vascular diseases. Therefore, we tried to demonstrate possible correlations among pathological venous characteristics of different regions of the inferior legs in order to identify phenotypes easy to be found during daily clinical practice.

Galeandro et al already observed that the 3D venous mapping by means of MEVEC 2.1 software was more reliable than the common written reports in evaluating patients with venous diseases.⁷

The study of the hemodynamics of the lower limb venous tree is hard to be performed, while the reproducibility of the several methods is a matter of debate.

The use of Doppler ultrasound for the assessment of venous hemodynamics is simplistic if not associated with the identification of the blood movement and the alterations in its flow.²⁴ Difficulties emerge when physicians try to translate

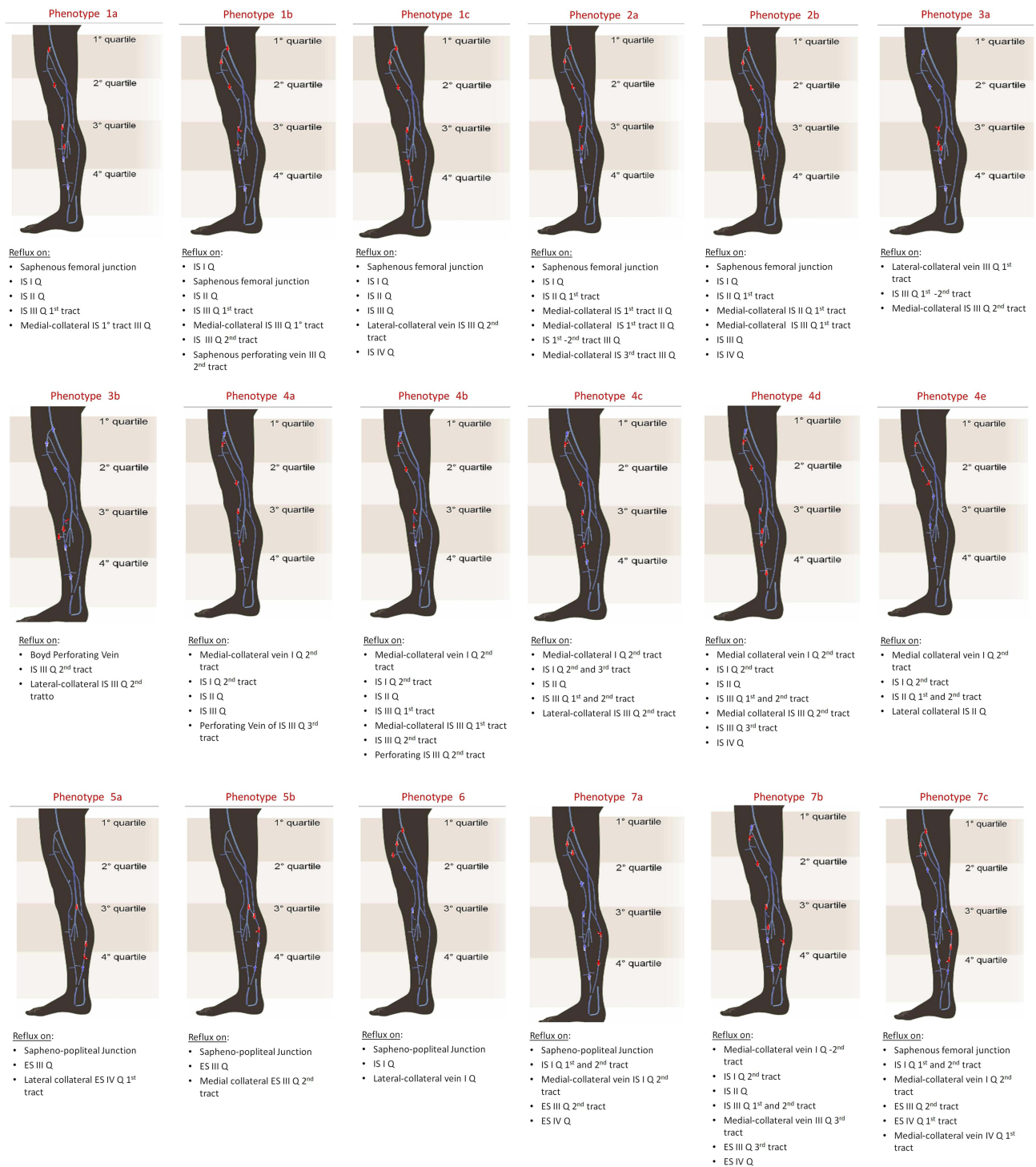

Figure 2 Classification of the main seven different phenotypes of vascular venous pattern in lower limbs and their subtypes.
Abbreviations: ES, external saphenous vein; IS, internal saphenous vein; Q, quartile.

their study on lower limbs hemodynamics on a biplane paper. The introduction of MEVEC 2.1 is rather able to overcome the impasse due to ancient technique and provide a 3D graphic scheme, which is useful for better understanding the anatomy and physiopathology of venous vascular system of the lower limbs.^{6,7}

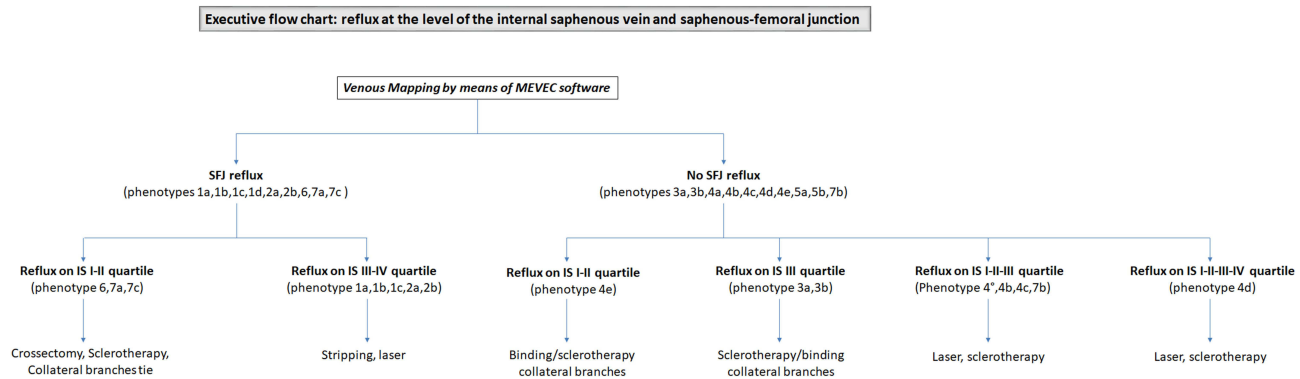


Figure 3 Simplified flow chart to better delineate a possible use of the different phenotypes in clinical practice in order to better drive the decisions on the therapies for venous diseases.

The MEVEC 2.1 software is effectively able to create a specific graphic scheme of the lower limb venous system (called *3D venous imaging*) by which spatial proportions are preserved among the three subsystems (superficial, deep and perforating veins).

The aim of the present study is to further develop the skills and the performances of the MEVEC 2.1. In particular, this study demonstrated correlations among patterns of alterations in hemodynamics of different venous vascular regions of the lower limbs in order to fasten the performance of venous mapping. We found 26 possible correlations among venous abnormalities within the four parts of the leg. Taking together and clinically summarizing those correlations which demonstrated the highest relationship, we derived 7 phenotypes and further subtypes (Figure 2).

The identification of these phenotypes can fasten the performance of venous mapping of the lower limbs: physicians might derive specific alterations in different regions of the venous vascular tree of the lower limbs after the identification of the first alteration into a dedicated district.

Therefore, physician involved in the reconstruction pathway of the venous map may use these phenotypes to directly predict alterations in venous hemodynamics of the lower limbs.

This is the first study attempting to identify a technique able to improve the visualization of the venous vascular tree of the lower limbs in healthy and pathological conditions, to provide a 3D map able to impact on a comprehensive evaluation of the venous diseases by considering both anatomy of the veins and their hemodynamics, and to increase the readability of the text even from physicians not expert in venous disorders.

The success in widening the comprehension of the venous maps to a wide range of physicians and the simplification in the report as outlined by the 3D reconstruction derived from MEVEC 2.1 include implications in terms of therapeutic management. In fact, the easy detection of venous disorders will improve the application of dedicated therapeutic protocols in order to prevent the progress of the venous disorders. Furthermore, the fast reproducibility of the technique will promote the reduction in waiting list for the comprehensive evaluation of the venous disorders.

Indeed, further and comprehensive clinical studies are needed in order to better validate MEVEC 2.1 and to definitely substitute the ancient and obsolete written report.

Conclusions

The MEVEC 2.1 software is a reliable tool able to provide 3D maps of the venous vascular tree of the lower limbs. The identification of 7 characteristic phenotypes can fasten the evaluation of the hemodynamics of the venous vascular system in lower limbs as they allowed the easy recognition of recurrent patterns of venous disorders.

Ethics Approval and Consent to Participate

The study protocol was approved by the ethic committee of University of Bari and was in agreement with the Helsinki Declaration. Informed consent was obtained from the patients and from the enrolled subjects.

Funding

There is no funding to report.

Disclosure

The authors certify that there is no conflict of interest in this work.

References

1. Fowkes FG, Evans CJ, Lee AJ. Prevalence and risk factors of chronic venous insufficiency. *Angiology*. 2001;52:S5–S15. doi:10.1177/0003319701052001S02
2. Carpentier PH, Maricq HR, Biro C, et al. Prevalence, risk factors, and clinical patterns of chronic venous disorders of lower limbs: a population-based study in France. *J Vasc Surg*. 2004;40:650–659. doi:10.1016/j.jvs.2004.07.025
3. Al Shammeri O, AlHamdan N, Al-Hothaly B, et al. Chronic venous insufficiency: prevalence and effect of compression stockings. *Int J Health Sci (Qassim)*. 2014;8:231–236. doi:10.12816/0023975
4. Do DD, Husmann M. Diagnosis of venous disease. *Herz*. 2007;32:10–17. doi:10.1007/s00059-007-2958-3
5. Müller-Lisse UL, Müller-Lisse GU, Holzknecht N, et al. Ultrasonography of veins. *Radiologe*. 1998;38:560–569. doi:10.1007/s001170050393
6. Galeandro AI, Quistelli G, Scicchitano P, et al. Doppler ultrasound venous mapping of the lower limbs. *Vasc Health Risk Manag*. 2012;8:59–64. doi:10.2147/VHRM.S27552
7. Galeandro AI, Scicchitano P, Zito A, et al. A three-dimensional electronic report of a venous echo color Doppler of the lower limbs: mEVeC[®]. *Vasc Health Risk Manag*. 2014;10:549–555. doi:10.2147/VHRM.S63068
8. Shortell CK. Meticulous evaluation of venous duplex imaging. *J Vasc Surg*. 2012;55:445. doi:10.1016/j.jvs.2011.08.037
9. Lurie F, Comerota A, Eklof B, et al. Multicenter assessment of venous reflux by duplex ultrasound. *J Vasc Surg*. 2012;55:437–445. doi:10.1016/j.jvs.2011.06.121
10. Nicolaides AN; Cardiovascular Disease Educational and Research Trust; European Society of Vascular Surgery; The International Angiology Scientific Activity Congress Organization; International Union of Angiology; Union Internationale de Phlebologie at the Abbaye des Vaux de Cernay. Investigation of chronic venous insufficiency: a consensus statement (France, March 5–9, 1997). *Circulation*. 2000;102:E126–E163. doi:10.1161/01.CIR.102.20.e126
11. Mahmutyazicioğlu K, Gündoğdu S, Ozdemir H, Savranlar A, Asil K. Venous reflux: measurement variability due to positional differences. *Tani Girisim Radyol*. 2003;9:471–475.
12. Malgor RD, Labropoulos N. Diagnosis of venous disease with duplex ultrasound. *Phlebology*. 2013;28:158–161. doi:10.1177/0268355513476653
13. Masuda EM, Kistner RL, Eklof B. Prospective study of duplex scanning for venous reflux: comparison of Valsalva and pneumatic cuff techniques in the reverse Trendelenburg and standing positions. *J Vasc Surg*. 1994;20:711–720. doi:10.1016/S0741-5214(94)70158-X
14. Labropoulos N, Leon LR. Duplex evaluation of venous insufficiency. *Semin Vasc Surg*. 2005;18:5–9. doi:10.1053/j.semvascsurg.2004.12.002
15. Saleem T, Raju S. Comparison of intravascular ultrasound and multidimensional contrast imaging modalities for characterization of chronic occlusive iliofemoral venous disease: a systematic review. *J Vasc Surg Venous Lymphat Disord*. 2021;9:1545–1556. doi:10.1016/j.jvsv.2021.03.022
16. Jayaraj A, Raju S. Three-dimensional computed tomography venogram enables accurate diagnosis and treatment of patients presenting with symptomatic chronic iliofemoral venous obstruction. *J Vasc Surg Venous Lymphat Disord*. 2021;9:73–80. doi:10.1016/j.jvsv.2020.07.012
17. Lee W, Chung JW, Yin YH, et al. Three-Dimensional CT venography of varicose veins of the lower extremity: image quality and comparison with Doppler sonography. *AJR Am J Roentgenol*. 2008;191:1186–1191. doi:10.2214/AJR.07.3471
18. Chen CW, Fang YF, Tseng YH, et al. A novel tool for a challenging disease: stasis leg ulcers assessed using qflow in triggered angiography noncontrast enhanced magnetic resonance imaging. *J Pers Med*. 2021;11:857. doi:10.3390/jpm11090857
19. Chen CW, Tseng YH, Wong MY, et al. Using non-contrast MRA to discriminate between obstructive and nonobstructive venous diseases of the legs. *Diagnostics (Basel)*. 2021;11:1392. doi:10.3390/diagnostics11081392
20. Xia Z, Gu H, Yuan Y, Xiang S, Zhang Z, Tao X. Value of Dynamic Contrast-Enhanced (DCE) MRI in predicting response to foam sclerotherapy of venous malformations. *J Magn Reson Imaging*. 2021;54:1108–1116. doi:10.1002/jmri.27657
21. Fleiss JL. *The Design and Analysis of Clinical Experiments*. New York, NY: Wiley; 1986:5–12.
22. Donati M, Gandolfo L, Palmeri S, et al. Role of echo-colour Doppler in the diagnostic work-up and surgical timing of chronic venous insufficiency. *Chir Ital*. 2006;58:337–345.
23. Ward JH. Hierarchical grouping to optimize an objective function. *J Am Stat Assoc*. 1963;58:236–244. doi:10.1080/01621459.1963.10500845
24. Lattimer CR, Rudolph PB, Recke A, et al. Comparison of four haemodynamic tests that quantify superficial venous insufficiency. *Eur J Vasc Endovasc Surg*. 2019;57:570–577. doi:10.1016/j.ejvs.2018.10.003

Vascular Health and Risk Management

Dovepress

Publish your work in this journal

Vascular Health and Risk Management is an international, peer-reviewed journal of therapeutics and risk management, focusing on concise rapid reporting of clinical studies on the processes involved in the maintenance of vascular health; the monitoring, prevention and treatment of vascular disease and its sequelae; and the involvement of metabolic disorders, particularly diabetes. This journal is indexed on PubMed Central and MedLine. The manuscript management system is completely online and includes a very quick and fair peer-review system, which is all easy to use. Visit <http://www.dovepress.com/testimonials.php> to read real quotes from published authors.

Submit your manuscript here: <https://www.dovepress.com/vascular-health-and-risk-management-journal>