

# Removal of giant spherical foreign body in the esophagus by double-forceps endoscope and double balloon

Journal of International Medical Research

48(8) 1–5

© The Author(s) 2020

Article reuse guidelines:

[sagepub.com/journals-permissions](https://sagepub.com/journals-permissions)

DOI: 10.1177/0300060520941332

[journals.sagepub.com/home/imr](https://journals.sagepub.com/home/imr)



Shan Yu\*, Xiaoming Wang\*  and Xin Chen

## Abstract

In patients with esophageal foreign bodies such as spherical or similarly shaped objects, a clamp or trap can easily fall off when the esophagus is physiologically narrow during removal of the foreign body by the endoscope. In the present case, a double-forceps-channel endoscope and double balloon were used to successfully remove a large spherical foreign body from the esophagus.

## Keywords

Foreign body, endoscopy, forceps, double balloon, guide wire, esophagus

Date received: 3 February 2020; accepted: 19 June 2020

## Introduction

The presence of a foreign body in the upper gastrointestinal tract is one of the most common disorders of the digestive system. The types of foreign bodies in the digestive tract are complex, and giant spherical foreign bodies are rare. With the development of digestive tract endoscopes, endoscopy has become the first-choice treatment for the upper gastrointestinal tract. We herein report a case of a giant spherical foreign body that had become incarcerated in the upper esophageal segment. After trying

various instruments and methods, a double-forceps endoscope and double balloon were used to successfully achieve complete removal of the foreign body. This case

---

Department of Gastroenterology, Panzihua Central Hospital, Panzihua, Sichuan Province, China

\*These authors contributed equally to this work.

### Corresponding author:

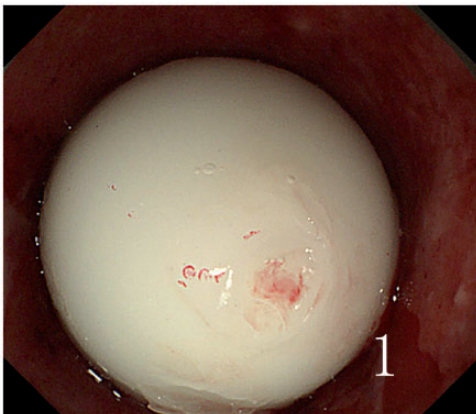Xiaoming Wang, Department of Gastroenterology, Panzihua Central Hospital, No. 34 Yikang Street, Panzihua, Sichuan Province 617067, China.  
Email: 714262144@qq.com



report illustrates a new method with which to remove giant spherical foreign bodies, and we hope that it will assist doctors who encounter this situation in clinical practice.

## Case report

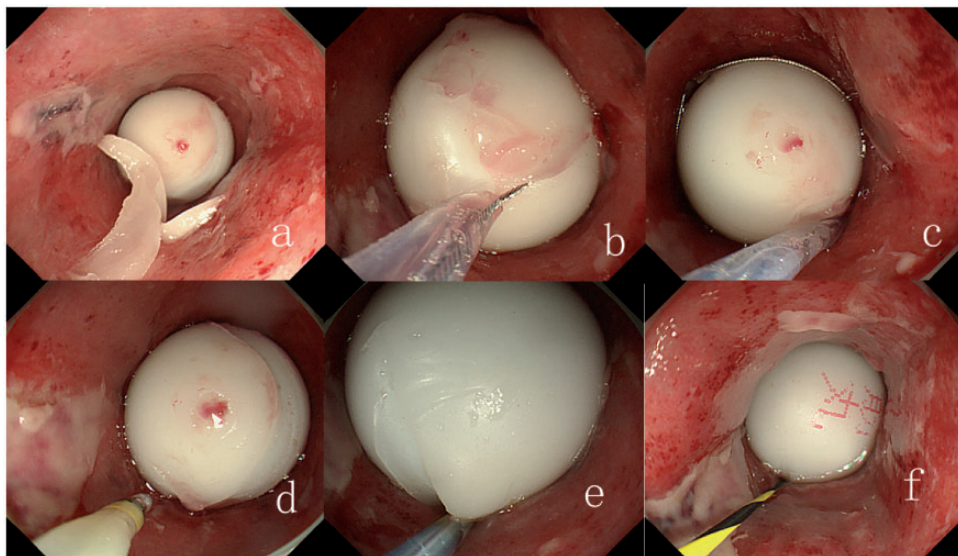
A 38-year-old man was admitted to the hospital for mistakenly ingesting wax pills 2 hours prior. Two hours before admission, after the patient had eaten the wax pills, he developed odynophagia and dysphagia but no hematemesis, fever, or other symptoms. Consequently, he presented to our hospital. The patient had a medical history of smoking and drinking, but he had no hypertension, heart disease, or family history of tumors. His vital signs on admission were stable. His heart and lungs showed no specific abnormalities. His abdomen was soft, and no tenderness, rebound pain, or masses were discerned by palpation. The intestinal sounds were normal. Painless gastroscopy in our hospital showed a white spherical foreign body incarcerated at the upper end of the esophagus (Figure 1); the object was closely attached to the esophageal wall and could not be expelled. Endoscopic foreign body extraction under



**Figure 1.** A white spherical foreign body was incarcerated at the upper end of the esophagus.

intravenous anesthesia was performed on an emergency basis.

A transparent cap was placed on the front end of the gastroscope (model GIF-Q260J; Olympus, Tokyo, Japan), which was then inserted into the esophagus. The white spherical foreign body was located at the upper end of the esophagus. The foreign body could not be clipped because it was large and smooth, and the foreign body forceps were too small and weak to clip the foreign body (Figure 2(a)). We then attempted to switch to the trap (MTN-PFS-E-24/23; Micro-Tech, Nanjing, China), which also failed to remove the foreign body because the surface of the foreign body was very smooth (Figure 2(b)). Next, we attempted to trap the foreign body with a stone-capturing basket (model FG-23Q-1; Olympus), which also failed after repeated attempts (Figure 2(c)). Because the foreign body was large and tightly lodged within the esophagus, a stone-capturing basket (model B-V232P-A; Olympus) could not be advanced to the distal end of the foreign body (Figure 2(d)). We implanted a macula guide wire (model M00556580; Boston Scientific, Marlborough, MA, USA) under the pill along the gastroscope clamp canal. The stone-capturing balloon was implanted into the distal end of the pill, which had a diameter of 2.0 cm, but forced dragging of the balloon could not move the pill (Figure 2 (e), (f)). We believe that the pill was too tightly incarcerated and that the stress on the balloon and pill was uneven, which led to deviation to one side. Therefore, we replaced the double-clamp endoscope (model GIF-2TQ260M; Olympus) with two macula guide wires, and two stone-capturing balloons were implanted at the distal end of the pill. The two balloons were injected into the space, which had a diameter of 1.5 cm. The two balloons were simultaneously dragged to the mouth, and the foreign bodies were then completely removed with a stone net basket (Figure 3). Endoscopic



**Figure 2.** (a) Removal of the foreign body by forceps failed. (b) Removal of the foreign body by a trap failed. (c) Removal of the foreign body by a stone-capturing balloon failed. (d) The stone-capturing balloon could not be inserted into the distal end of the foreign body. (e, f) A guide wire was used to guide the balloon to the distal end of the foreign body, but the guide wire could not drag the foreign body.

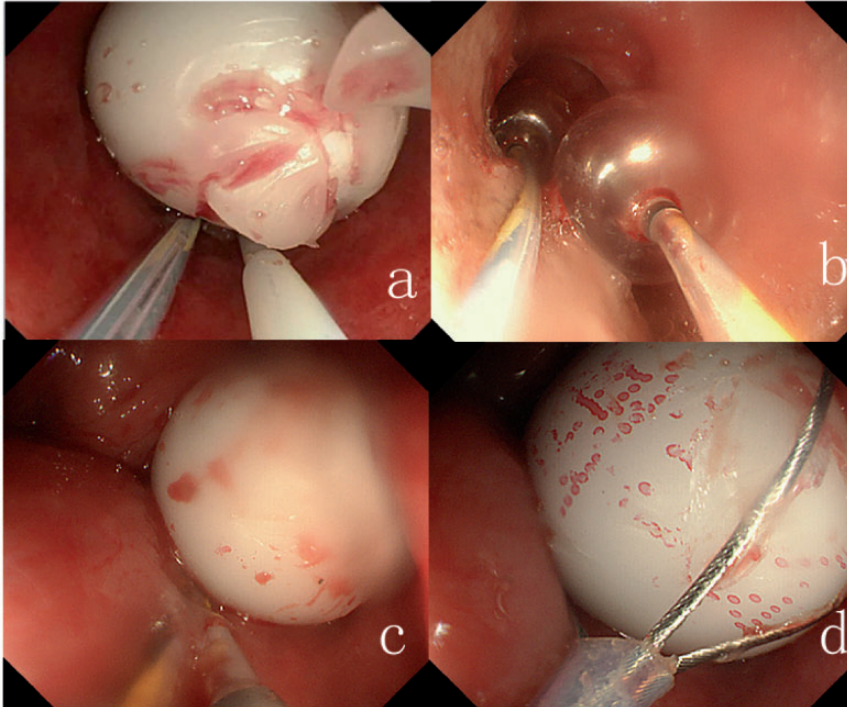
examination of the site at which the foreign body had been incarcerated revealed congestion and edema of the mucous membranes; however, no damage, bleeding, or perforation was observed (Figure 4).

Written informed consent was obtained from the patient. This article is a case report, and all details are anonymous. We have de-identified the details such that the identity of the patient may not be ascertained in any way. The requirement for ethics approval was waived because this is a case report, and all details are anonymous.

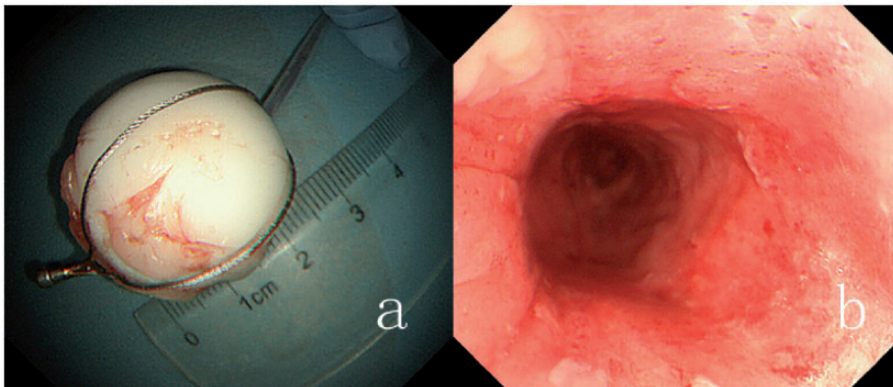
## Discussion

The presence of a foreign body in the upper gastrointestinal tract is one of the most common disorders of the digestive system. If the foreign body becomes incarcerated, the upper gastrointestinal mucosa may undergo tearing, bleeding, or even perforation; this may cause a mediastinal abscess,

esophageal aortic aneurysm, or similar conditions, even resulting in death.<sup>1</sup> According to the patient's medical history, the clinician must first check the type, size, shape, quantity, and position of the foreign body as well as the duration of incarceration, and the most reasonable treatment mode should then be selected. With the development of digestive tract endoscopes, endoscopy has become the first-choice treatment for the upper gastrointestinal tract. The removal of foreign material under endoscopy should occur as early as possible. Under endoscopy, smooth, round, and spherical foreign bodies should be taken out with a trielcon, basket, foreign object pliers, or net pocket. The types and shapes of foreign bodies encountered in clinical practice are complex. Foreign bodies with regular edges, such as circular or circular-like foreign bodies, can reportedly be removed by Foley catheters.<sup>2</sup> The Foley catheter must be properly manipulated to successfully



**Figure 3.** (a–d) Two guide wires were implanted into a double stone-capturing balloon, and the foreign body was dragged to the mouth.



**Figure 4.** (a) The white spherical foreign body was completely removed. (b) The site at which the foreign body had been incarcerated exhibited congestion and edema of the mucous membranes.

remove the foreign body. If the Foley catheter is improperly manipulated, the foreign body can be inserted into the lower part of the esophagus; eccentric expansion can also

occur during gas injection of the air bag, causing the treatment to fail. The operation is also difficult to implement when a spherical foreign body completely blocks the

esophagus, resulting in the absence of space within the esophageal lumen; in such cases, the end of the Foley catheter balloon cannot pass the foreign body. In patients with spherical or similarly shaped foreign bodies, a clamp or trap can easily fall off when the esophagus is physiologically narrow during removal of the foreign body by the endoscope. In the present case, a double-forceps-channel endoscope and double balloon were used to successfully remove a large spherical foreign body from the esophagus.

### Acknowledgements

We are grateful to the staff members at Panzihua Central Hospital for their support.

### Authors' contributions

Shan Yu, Xiaoming Wang, and Xin Chen treated the patient. Shan Yu and Xiaoming Wang wrote the article.

### Declaration of conflicting interest

The authors declare that there is no conflict of interest.

### Funding

This research received no specific grant from any funding agency in the public, commercial, or not-for-profit sectors.

### ORCID iD

Xiaoming Wang  <https://orcid.org/0000-0003-1849-2069>

### References

1. Ikenberry SO, Jue TL, Anderson MA, et al. Management of ingested foreign bodies and food impactions. *Gastrointest Endosc* 2011; 73: 1085–1091.
2. Burgos A, Rabágo L and Triana P. Western view of the management of gastroesophageal foreign bodies. *World J Gastrointest Endosc* 2016; 8: 378–384.