

Phlegmasia Cerulea Dolens: A Rare Case Report

Abstract

Phlegmasia cerulea dolens is a severe form of deep venous thrombosis (DVT) characterized by severe venous outflow obstruction, marked limb swelling, pain, bluish discoloration, and even venous gangrene if the condition is untreated. In our case, 75-year-old woman, with general abdominal pain, which increases with eating and anorexia and 5 days of coldness and swelling of the left leg, was accepted. The patient had a history of Type II diabetes, ischemic heart disease, congestive heart failure, hyperlipidemic (HLP), hypertension, metastatic ovarian cancer, and previous DVT. She has undergone chemotherapy for the past 3 weeks due to ovarian cancers. Anticoagulation with intravenous administration of heparin and fluid resuscitation started immediately. The evidence of color Doppler sonography approved acute DVT in common femoral vein extending to the left external iliac. The patient did not consent for continuing the procedure in the hospital and succumbed to her illness on the 7th day after discharge.

Keywords: Case report, phlegmasia cerulean dolens, thrombectomy

Introduction

Phlegmasia cerulea dolens (PCD) is a severe form of deep venous thrombosis (DVT) characterized by severe venous outflow obstruction, marked limb swelling, pain, bluish discoloration, and even venous gangrene, if the condition is untreated.^[1] It is usually resulted from acute massive venous thrombosis and obstruction of the venous drainage of an extremity and may occur at any age, but is more common during the fifth and sixth decades of life.^[2] Incidence is higher in females than in males and also in the lower extremities, left-sided involvement is more common by a 3:1 or 4:1 ratio. In the 16th century, Fabricius Hildanus first described the clinical syndrome of what is currently called PCD. In 1938, Gregoire made an outstanding description of the condition and used the term PCD to differentiate ischemia-associated massive venous thrombosis from phlegmasia alba dolens, which describes fulminant venous thrombosis without ischemia.^[3]

More than 600,000 cases of venous thromboembolism are estimated to occur each year in the United States. Pulmonary embolism (PE) complicates approximately

50% of cases of untreated proximal DVT and contributes to 10%–15% of all hospital deaths. The main causative factor in phlegmasia is massive thrombosis and occlusion of major venous channels with significantly compromised venous outflow.^[4] Multiple triggering factors exist. Malignancy is the most common triggering factor and is present in approximately 20%–40% of patients with PCD. Other associated risk factors include hypercoagulable syndrome, surgery, trauma, ulcerative colitis, gastroenteritis, heart failure, mitral valve stenosis, vena cava filter insertion, and May-Thurner syndrome (compression of the left iliac vein by the right iliac artery).^[5] While PCD is highly associated with systemic disease and inherited coagulopathies in adults, hospitalists and primary care providers should understand the implications and management of PCD. In this study, we reported a PCD case of 75-year-old woman who had abdominal pain, cold, swelling, and discoloration of the left lower limb.

Case Report

A 75-year-old woman referred to the emergency ward of Al-Zahra Hospital

**Alireza Abootalebi,
Mohsen Salemi,
Farhad Heidari,
Azita Azimi Meibody**

*From the Department of
Emergency Medicine, Isfahan
University of Medical Sciences,
Isfahan, Iran*

*Address for correspondence:
Dr. Azita Azimi Meibody,
Department of Emergency
Medicine, Isfahan University of
Medical Sciences, Isfahan, Iran.
E-mail: azita_azimi@yahoo.com*

This is an open access journal, and articles are distributed under the terms of the Creative Commons Attribution-NonCommercial-ShareAlike 4.0 License, which allows others to remix, tweak, and build upon the work non-commercially, as long as appropriate credit is given and the new creations are licensed under the identical terms.

For reprints contact: WKHLRPMedknow_reprints@wolterskluwer.com

How to cite this article: Abootalebi A, Salemi M, Heidari F, Azimi Meibody A. Phlegmasia cerulea dolens: A rare case report. *Adv Biomed Res* 2020;9:31.

Received: 05 January 2020
Revised: 12 February 2020
Accepted: 07 April 2020
Published: 27 July 2020

Access this article online

Website: www.advbiores.net

DOI: 10.4103/abr.abr_3_20

Quick Response Code:



because of cold, swelling, and discoloration of the left lower limb (from fingers to upper left knee) [Figure 1]. The patient complained of general abdominal pain, which increases with eating, and she was anorexic but had gas passing. Patients had a history of Type II diabetes, ischemic heart disease, congestive heart failure, HLP, hypertension, metastatic ovarian cancer, and previous DVT. She has undergone chemotherapy for the past 3 weeks due to ovarian cancers. Coldness and swelling of the left leg started about 5 days ago. The patient was treated with warfarin, metformin, and pantoprazole. On examination, the patient had no decrease in pulmonary hearing loss, and no rale, crackles, and wheeze were heard. The heart sound was muffled, and s1 s2 was normal.

Abdominal ultrasound was normal, and there was no local tenderness and guarding. According to chest X-ray, heart shadow was normal, and lung parenchyma was clear. In the vascular examination, pulses of the right foot were touched normally, but dorsalis pedis and posterior tibial artery pulses were not touched. Legs were different in size (32 cm right leg, 42 cm left leg). O2sat: 90%, PCO2 29 mmHg and PO2 48 mmHg, pH: 7.44, PR: 110/min, T: 37°C, blood pressure: 130/80 mmHg.

In the Echo Doppler performed from the left foot, the DVT was seen extending to the external iliac. The patient's d-dimer level was >10,000. Other laboratory factors are also reported in Table 1. The patient's electrocardiogram was also normal [Figure 2]. Intravenous, arterial color Doppler ultrasound of the left lower limb revealed that the common and superficial, popliteal, posttibial, and ant tibialis femoral arteries had normal intima-media thickness and common, superficial and popliteal femoral arteries had normal peak systolic velocity (PSV) and normal spectral waveforms. The dorsalis pedis artery had normal PSV and biphasic waveform, and in the study of the left lower extremity, common femoral vein (CFV) had an increased diameter and no normal compressibility. The hyperco image of the heterogeneity of thrombus was seen on the

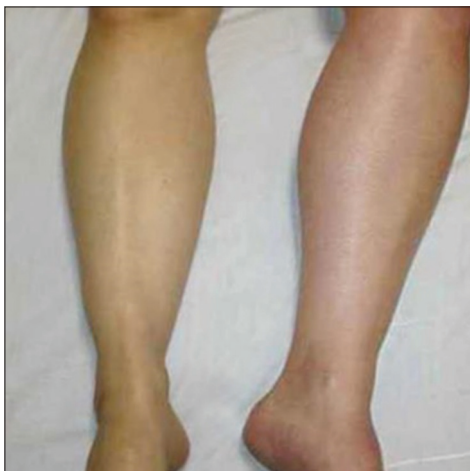

Figure 1: Case of phlegmasia cerulea dolens of the lower limb

CFV. Furthermore, the vascular flow was not observed in the normal state with augmentation maneuver in the external iliac. The above evidence suggested acute DVT in CFV, extending to the left external iliac.

The patient was treated with heparin dosage and admitted to the emergency ward with a diagnosis of PCD after hyperglycemia control and injecting the first dose of necessary antibiotics and reach to stable vital signs, the patient was referred for the necessary procedure (injection of streptokinase in the obstruction site). However, due to the lack of access to the proper catheter for streptokinase injections, fibrinolytic therapy was not performed and was only treated with anticoagulant therapy. During the hospitalization (4 days) and treatment of the patient in the ward, the patient developed heparin-induced thrombocytopenia (HIT) and pancytopenia. Due to the patient's dissatisfaction with being hospitalized and with the approval of the hospital's forensic doctor, she was discharged from the hospital with the necessary treatment, but unfortunately, she died about 1 week later.

Discussion

PCD is a poorly understood, fulminant, limb-threatening, and life-threatening condition, which is caused by acute massive venous thrombosis.^[1] Patients may present with sudden and severe leg pain, swelling, cyanosis, compartment syndrome, venous gangrene, and/or arterial compromise. Release of inflammatory mediators can cause a vasodilatory state, and patients may develop circulatory collapse and hypovolaemic shock due to third spacing. Progressive swelling preceding arterial insufficiency, and

Table 1: Laboratory parameters

Parameters	First day	Second day	Third day	Fourth day
Hemoglobin	12.4	10.8	9.9	9.2
WBC	11.600	2.900	1.500	900
pH	7.30	7.32	7.38	7.40
Creatinine	1.7	1.6	1.3	1.3
Blood sugar	580	450	305	270
Platelet	83000	56000	24000	17000
INR	1	1.1	1.15	1.36

WBC: White blood cell, INR: International normalized ratio

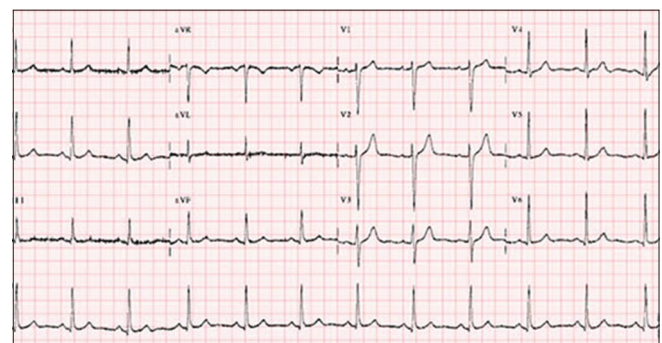


Figure 2: Electrocardiogram

associated with pain and cyanosis, is highly suggestive of PCD. Cancer is the most common cause in obese adults, with advanced age and immobilization as other contributing factors. Treatment involves heparinization, catheter-directed thrombolysis, and thrombectomy.^[3,4] Due to its rarity, there is no consensus regarding its management though anticoagulation, catheter-directed thrombolysis, and mechanical thrombectomy form the mainstay of management. The purpose of rapid heparin anticoagulation is to decrease the risk of proximal clot propagation or thromboembolism. Heparin does not directly affect limb swelling. The best nonsurgical method to decrease edema is steep leg elevation. Thrombolysis seems to be another attractive alternative in the management of PCD and venous gangrene. In 1970, Paquet was the first to use thrombolysis for the treatment of PDC.^[6,7] Some authors propose catheter-directed thrombolysis directly into the vein with high doses of urokinase or tissue plasminogen activator. Other authors support the method of intraarterial low-dose thrombolysis via the common femoral artery, reasoning that the arterial route delivers the thrombolytic agent to the arterial capillaries and subsequently, to the venules. In the present case, the patient had the risk factors of ovarian cancer and diabetes, and she was treated according to the standard protocol with anticoagulant agents. In a similar case, a 50-year-old woman with known diabetic and hypertensive presented with fever, dyspnea and left-sided pleuritic chest pain and left lower limb swelling worsening over the past 1 week. On examination, her vitals were stable, and she had significant left lower limb edema extending up to the upper thigh with livedo reticularis. There was excruciating pain on the light touch and passive flexion of the toes and ankle. The patient was initiated on anticoagulation with unfractionated heparin and supportive care, such as lower limb elevation and analgesics. Her eventual workup for malignancy and blood cultures were negative. Despite 12 h of anticoagulation, her pain and swelling did not subside, and the patient developed gangrene of the lower limb and underwent below-knee amputation. Subsequently, the session of debridement of necrotic tissue of the affected compartment post fasciotomy was done, and a negative-pressure wound therapy was adopted to improve wound healing. On the 3rd postoperative day, she developed a cough with dyspnea, which progressed to septic shock. Despite broad-spectrum antibiotics, she succumbed to her illness on the 7th postoperative day.^[1] In another case, a 71-year-old woman with 23 years of treated diabetes mellitus was accepted for gastrointestinal imaging study for suspicions of the neoplastic process of the stomach. On the 3rd day, she complained of edema, agonizing pain and cyanosis, many blisters, and starting necrosis on the dorsal and lateral surface of the right ankle, progressively extended to distal one-third of the leg. Anticoagulation with intravenous administration of heparin and fluid resuscitation started immediately. Six days after starting heparin therapy, a fall of thrombocyte count was found ($16 \times 10^9/L$), and

HIT was suspected. Low-molecular-weight heparins such as Clezan (Enoxaparine) at doses 1 mg/kg/day in two times replaced standard heparin. Despite continued intravenous anticoagulation, the clinical findings progressed to venous gangrene, and amputation of the lower limb was performed. Postoperatively, the patient was placed on Clezan 0.3 ml sc and on the 8th postoperative day, the patient started rehabilitation program.^[8]

As mentioned, despite proper treatment, the cases were finally undergone the last treatment modality of open surgical thrombectomy, which is a difficult procedure that requires the use of general anesthesia, which might propose a challenge for patients with comorbidities. In another case, a 56-year-old male was diagnosed with a case of extensive left femoral DVT and PE. Two days after being managed by systemic thrombolytics and heparin, his condition worsened as he developed cyanosis of the affected limb, compartment syndrome, and foot drop, so he was referred for further management. Computed tomography venogram showed thrombosis of the left popliteal vein extending into the left common iliac vein, confirming the diagnosis of PCD and May-Turner syndrome. It was adopted a limb preserving approach using a pharmacomechanical catheter-directed thrombolysis. The patient recovered fully with a complete resolution of his foot drop. In our case, the patient was unsatisfied to stay in the hospital, and it may be the reason for ineffective therapeutic procedures, possibly with the fate of surgery. However, this approach was also found to be associated with a higher rate of recurrence of thrombus and mortality compared to the interventional catheters.

Our case shows that a rare entity of DVT as PCD could be a result of improper management of acute proximal DVT in the background of anatomical variabilities and background diseases that, despite the late presentation of such a rare condition there still a role for a limb preserving approach with endovascular techniques.

Declaration of patient consent

The authors certify that they have obtained all appropriate patient consent forms. In the form the patient(s) has/have given his/her/their consent for his/her/their images and other clinical information to be reported in the journal. The patients understand that their names and initials will not be published and due efforts will be made to conceal their identity, but anonymity cannot be guaranteed.

Financial support and sponsorship

Nil.

Conflicts of interest

There are no conflicts of interest.

References

1. Chinsakchai K, Ten Duis K, Moll FL, de Borst GJ. Trends in

- management of phlegmasia cerulea dolens. *Vasc Endovascular Surg* 2011;45:5-14.
2. Bhatt S, Wehbe C, Dogra VS. Phlegmasia cerulea dolens. *J Clin Ultrasound* 2007;35:401-4.
3. Lewis CB, Hensley MK, Barrett JE, van Norman SB, Taylor AS, Horowitz JC. Phlegmasia cerulea dolens: A rare cause of shock. *Respirol Case Rep* 2019;7:e00424.
4. Maiti A, Das A, Smith DT. Phlegmasia cerulea dolens. *Postgrad Med J* 2016;92:690.
5. Kalagher SD, Kane DD. Phlegmasia cerulea dolens: Before and after lysis. *Intern Emerg Med* 2015;10:103-4.
6. Oguzkurt L, Ozkan U, Demirturk OS, Gur S. Endovascular treatment of phlegmasia cerulea dolens with impending venous gangrene: Manual aspiration thrombectomy as the first – Line thrombus removal method. *Cardiovasc Intervent Radiol* 2011;34:1214-21.
7. Sarwar S, Narra S, Munir A. Phlegmasia cerulea dolens. *Tex Heart Inst J* 2009;36:76-7.
8. Singh AD, Makkar N, Ray A, Sood R. Phlegmasia cerulea dolens presenting with acute compartment syndrome and pulmonary embolism. *Case Reports* 2018;2018:bcr-2018-224879.