

IMAGES AND VIDEOS

Confirmed early myocardial rupture in a patient with pulseless electrical activity (PEA) following late presentation of ST elevation myocardial infarction

Baskar Sekar MRCP MPhil¹, Joe Martins MD FRCP² and Sanjiv Petkar MD FRCP¹

¹Cardiology Department, Heart and Lung Centre, New Cross Hospital, Royal Wolverhampton NHS Trust, Wolverhampton, UK

²Cardiology Department, Russell's Hall Hospital, The Dudley Group NHS Foundation Trust, Dudley, UK

Correspondence should be addressed to B Sekar

Email
cardiologist1978@gmail.com

Summary

A 69-year-old male, an ex-smoker, was admitted with ongoing chest pain of 11 h duration. Past medical history included treated hypertension and gastro-oesophageal reflux disease. He delayed seeking medical attention as he assumed the pain to be due to indigestion and kept taking antacids without much symptomatic relief. Clinical examination on arrival was unremarkable. Admission 12 lead electrocardiogram (ECG) was diagnostic of a recent anterolateral myocardial infarction (MI) (Fig. 1A). Bedside trans-thoracic echocardiogram (TTE) confirmed an established anterolateral MI (Fig. 1B and Video 1). Unfortunately, en route to the cardiac catheter laboratory for a primary percutaneous coronary intervention (PPCI), he suffered a cardiac arrest, due to pulseless electrical activity. An urgent repeat TTE confirmed significant pericardial effusion due to myocardial rupture with thrombus in the left ventricular apex (Fig. 1C and Video 2). Attempts at resuscitating him were unsuccessful. It is rare to see and confirm a diagnosis of early myocardial rupture outside the autopsy room, as it is an extremely serious and lethal mechanical complication of acute MI. PEA in a patient with a first MI and without overt heart failure has a high predictive accuracy for this diagnosis. Anterior location of MI, age >70 years, and female sex are risk factors for myocardial rupture, while a patent infarct-related artery, either after PPCI or fibrinolytic therapy appears to be protective. As in this case, when time allows, TTE plays an invaluable role in diagnosing this condition.

Video 1

Initial transthoracic echocardiogram (A4C View) showing RWMA suggestive of an anterolateral myocardial infarction. There is no pericardial effusion or left ventricular thrombus. View Video 1 at <http://movie-usa.glencoesoftware.com/video/10.1530/ERP-17-0007/video-1>.

Video 2

Transthoracic echocardiogram (A4C View) during cardiac arrest due to pulseless electrical activity showing significant pericardial effusion and left ventricular thrombus. View Video 2 at <http://movie-usa.glencoesoftware.com/video/10.1530/ERP-17-0007/video-2>.

Declaration of interest

The authors declare that there is no conflict of interest that could be perceived as prejudicing the impartiality of this article.

Funding

This work did not receive any specific grant from any funding agency in the public, commercial, or not-for-profit sector.

Patient consent

Patient deceased.

Author contribution statement

B Sekar was responsible for managing the patient along with cardiologist in-charge and helped in manuscript preparation. J Martins was the cardiologist in-charge of the patient and helped in manuscript preparation. S Petkar was the cardiologist in-charge of the patient and critically revised the paper.

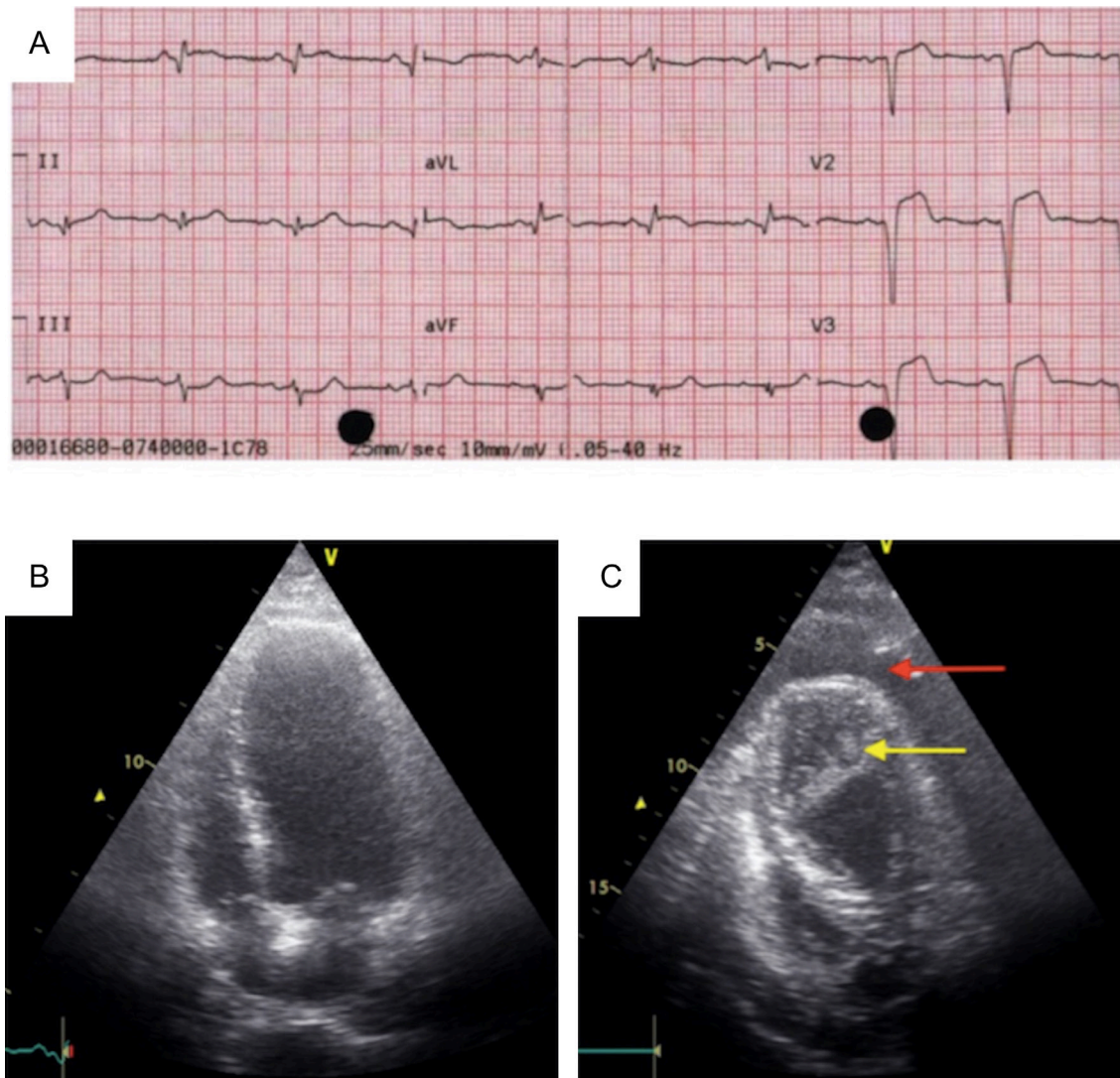


Figure 1

(A) 12-Lead ECG showing 3 mm ST elevation with deep q waves in the anterolateral leads. (B) Initial transthoracic echocardiogram (A4C View) showing RWMA (Video 1) suggestive of an anterolateral myocardial infarction. There is no pericardial effusion or left ventricular thrombus. (C) Transthoracic echocardiogram (A4C View) during cardiac arrest (Video 2) due to pulseless electrical activity showing significant pericardial effusion (red arrow) and left ventricular thrombus (yellow arrow).

References

- 1 See RH, Calvo D, Shi Y, Kawa H, Luke MP & Yuan Z 2001 Stimulation of p300-mediated transcription by the kinase MEKK1. *Journal of Biological Chemistry* **276** 16310–16317. (doi:10.1074/jbc.M008113200)
- 2 Royer P 1991 Hormonal regulation of calcium metabolism: biology and pathology. In *Pediatric Endocrinology*, edn 2, ch 6, pp 477–543. Eds J-C Job & M Pierson. New York, NY, USA: John Wiley & Sons.

Received in final form 26 January 2017

Accepted 18 April 2017

Accepted Preprint published online 18 April 2017