



OPEN ACCESS

Recurrent pneumonia post atrial fibrillation ablation: do not forget to look for pulmonary vein stenosis

Aki Mizuno , Sarah Mauler-Wittwer, Hajo Muller, Stephane Noble

Department of Cardiology,
Geneva University Hospital,
Geneva, Switzerland

Correspondence to

Dr Aki Mizuno;
aki.mizuno9@gmail.com and
Dr Stephane Noble;
stephane.noble@hcuge.ch

Accepted 26 November 2022

SUMMARY

A man in his 50s presented with persistent chest pain, haemoptysis, cough and dyspnoea 5 months after undergoing catheter ablation for atrial fibrillation (AF). Several chest CT scans suggested pneumonia. Despite adequate treatment for recurrent pneumonia, symptoms persisted. While reviewing the initial chest CT, a partial venous infarction of the left lower lobe associated with severe left inferior pulmonary vein stenosis (PVS) was diagnosed. Stenting of the left inferior pulmonary vein with a vascular bare metal stent was performed, guided by fluoroscopy and transoesophageal echocardiography. Dual antiplatelet therapy (aspirin/clopidogrel) was introduced for 3 months, followed by long-term aspirin monotherapy. The treatment resulted in relief of his symptoms and the resolution of pulmonary opacities on chest CT. Despite low frequency, AF ablation remains the most common cause of acquired PVS. As highlighted in this case, symptoms are not specific and include recurrent pulmonary infection with delayed management.

BACKGROUND

Atrial fibrillation (AF) ablation remains the most common cause of acquired pulmonary vein stenosis (PVS), despite a decrease in the frequency of this complication in recent years.¹⁻³ First described in 1998,⁴ PVS was a common complication of AF ablation with the earliest techniques involving ablation within the pulmonary vein themselves. To avoid this issue, AF ablation techniques further evolved towards more proximal pulmonary vein isolation (circumferential or segmental) by first

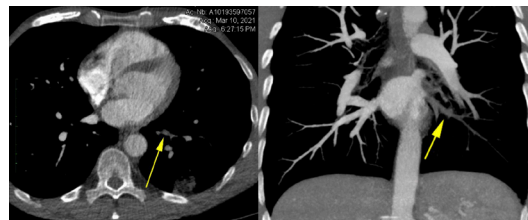


Figure 2 Chest CT scan with contrast showing an opacification delay in the left inferior pulmonary vein (yellow arrow) suggestive of stenosis or thrombotic occlusion.

ostial ablation, and nowadays antral isolation. With this latest technique, the incidence of severe PVS decreased to less than 1%.⁵ Nowadays, the diagnosis of PVS is often delayed or missed and it should not be forgotten. Here, we report a case of PVS with a delayed diagnosis despite suggestive symptoms.

CASE PRESENTATION

A man in his 50s was admitted for his third episode of pneumonia in 2 months. His medical history includes a pneumothorax treated conservatively during his 30s, a paroxysmal AF treated by radiofrequency catheter ablation 5 months prior to his presentation, an ophthalmic migraine, and a 20 pack-year history of smoking. During the last few months, the patient developed recurrent respiratory symptoms characterised as chest pain, cough, minor haemoptysis and shortness of breath leading to several medical consultations. Physical examination revealed coarse crackles at the left inferior lobe without signs of respiratory distress.

INVESTIGATIONS

His ECG and routine laboratory tests with D-dimer were initially normal. An inflammatory syndrome (C reactive protein 124 mg/L) was later noticed, with a negative nasopharyngeal SARS-COV2 PCR (PCR). In total, three chest CT scans were performed in 2 months. On the first CT, ground glass opacities of the left inferior lobe suggesting viral pneumonia were found. The second imaging study showed a progression of the ground glass opacities in addition to the development of heterogeneous condensation, suggesting bacterial pneumonia. Despite the introduction of co-amoxicillin, a third CT scan revealed worsening of the opacities, leading to a switch of antibiotics to levofloxacin. Clinical and biological evolution was transiently favourable, but pulmonary symptoms persisted for more than 1 month. A fourth chest CT showed improvement of the condensations but the persistence of

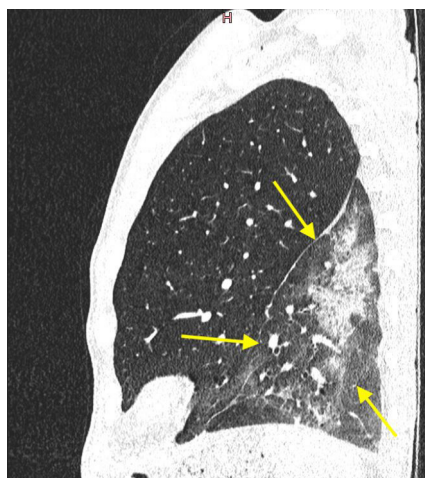
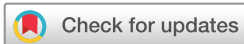

Figure 1 Chest CT scan showing ground glass opacities of the left inferior lobe, compatible with a partial venous infarction of the left lower lobe (yellow arrows).



© BMJ Publishing Group Limited 2022. Re-use permitted under CC BY-NC. No commercial re-use. See rights and permissions. Published by BMJ.

To cite: Mizuno A, Mauler-Wittwer S, Muller H, et al. *BMJ Case Rep* 2022;**15**:e250896. doi:10.1136/bcr-2022-250896

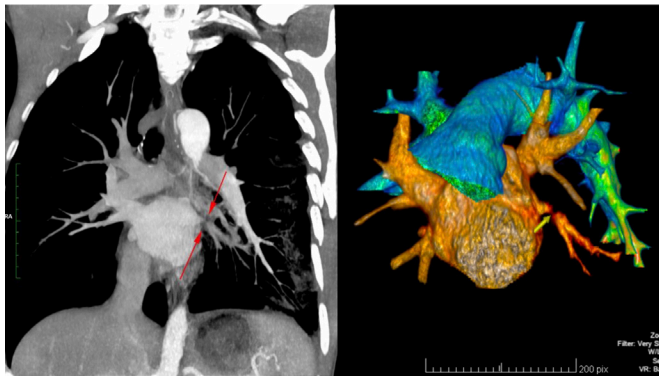


Figure 3 Pulmonary CT angiography showing severe stenosis of the left inferior pulmonary vein without complete occlusion (red arrow on the left figure) and three-dimensional reconstruction (yellow arrow on the right figure).

ground glass opacities of the left inferior lobe, compatible with a partial venous infarction of the left lower lobe (figure 1). After reviewing the first chest CT scan with contrast, an opacification delay was observed in the left inferior pulmonary vein suggestive of stenosis or thrombotic occlusion (figure 2). A pulmonary CT angiography was performed, showing a residual flow and confirming severe stenosis of the left inferior pulmonary vein without complete occlusion (figure 3). Transoesophageal echocardiography showed a normal ejection fraction and no significant valvulopathy. The mean gradient was measured at 4.3 mm Hg (maximal gradient of 10 mm Hg) in the left inferior pulmonary vein systolodiastolic flow.

TREATMENT

A pulmonary vein angiography was performed under general anaesthesia by way of right femoral venous access, followed by transseptal puncture and injection of the pulmonary veins. The stenosis of left inferior pulmonary vein was predilated by a

5 mm (EUPHORA 5×15 mm, Medtronic) balloon. A vascular balloon-expandable bare metal stent (over the wire OMNI ELITE 8.0×19 mm, Abbott Vascular) was then implanted from the ostium to above the first bifurcation. The stent was postdilated by an 8 mm (Powerflex PRO 8×40 mm, Cordis) balloon in the distal part and a 10 mm (Powerflex PRO 10×40 mm) balloon in the proximal part of the pulmonary vein. The intervention was guided by fluoroscopy and transoesophageal echocardiography (figure 4). The treatment resulted in a decrease in the mean and maximal gradient of the left inferior pulmonary vein systolodiastolic flow from 4.3 to 2 mm Hg and from 10 to 7 mm Hg, respectively. A 3-month dual antiplatelet therapy with aspirin and clopidogrel was introduced, followed by long-term aspirin monotherapy.

OUTCOME AND FOLLOW-UP

After the intervention, the symptoms immediately improved. At 6-month follow-up, the patient had no cardiorespiratory symptoms. A chest CT confirmed stent patency and a near complete resolution of the pulmonary opacities.

DISCUSSION

The presentation of PVS is variable and the symptomatology depends on the severity of the PVS and the number of pulmonary veins affected.⁶ Symptoms are not specific, including shortness of breath, cough, fatigue, chest pain, haemoptysis and recurrent pulmonary infection, and appear after a mean of 4.0 ± 3.0 months after the most recent ablation procedure.⁷ The average delay between onset of symptoms and diagnosis of PVS was 4.4 ± 5.4 months in a prospective, observational study that included 124 patients with severe PVS between 2000 and 2014.⁷ Diagnosis delay can lead to useless or even harmful exams, such as bronchoscopy or pulmonary biopsy. Furthermore, PVS can progress to total occlusion of the pulmonary vein, which would complexify or prevent its treatment.

PVS can be diagnosed by CT or MRI. These modalities help define the severity of PVS, ranging from mild (<50%), moderate (50%–70%) to severe (>70%), depending on the percentage reduction

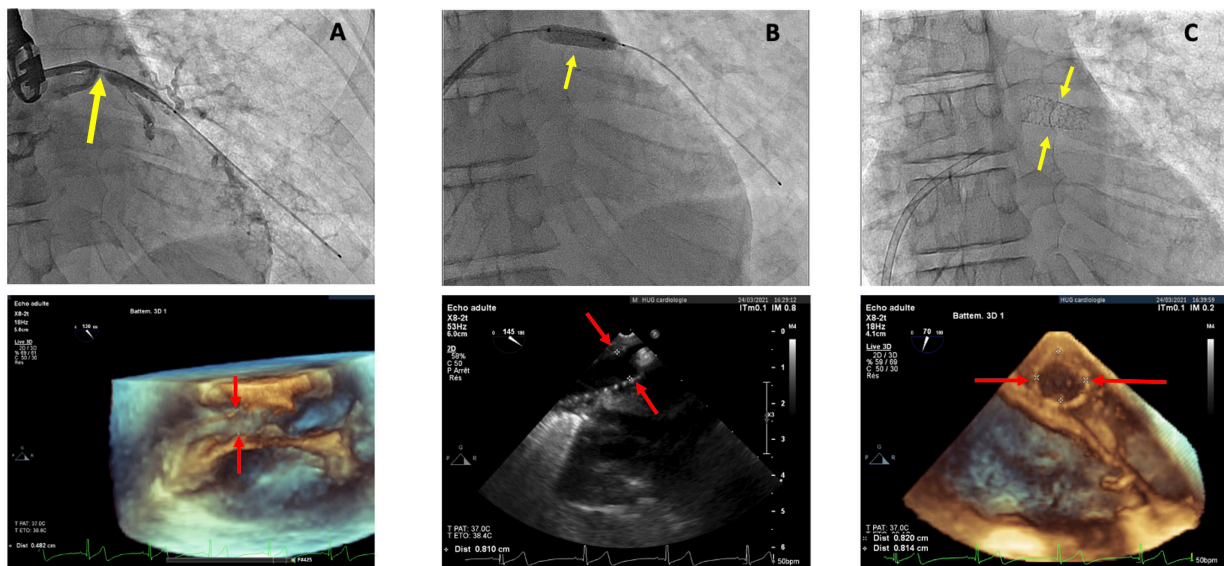


Figure 4 Stenting of left inferior pulmonary vein (LIPV) (A): severe stenosis of LIPV in fluoroscopy (yellow arrow on upper figure) and transoesophageal echocardiography (red arrows on lower figure): LIPV systolodiastolic flow mean gradient 4.3 mm Hg and maximum gradient 10 mm Hg. (B) stenting (Omni elite 8.0×19 mm) of LIPV in fluoroscopy (yellow arrow on upper figure) and transoesophageal echocardiography (red arrows on lower figure). (C) Final result in fluoroscopy (yellow arrows on upper figure) and transoesophageal echocardiography (red arrows on lower figure): left inferior pulmonary vein systolo-diastolic flow mean gradient 2 mm Hg and maximum gradient 7 mm Hg

of the luminal diameter according to the 2017 expert consensus.² Perfusion scans and transoesophageal echocardiography constitute alternative imaging modalities. In addition, pulmonary venography is particularly useful when total occlusion of the pulmonary vein is suspected on CT scan as it may reveal a residual channel allowing the introduction of a catheter for invasive treatment.

Intervention should be considered when the patient is symptomatic. Patients with asymptomatic PVS should be monitored by imaging every 3–6 months and angioplasty should be considered when PVS is severe, especially in presence of ipsilateral PVS.⁸ The treatment consists of angioplasty of the pulmonary vein and provides a significant improvement of symptoms.⁹ However, according to a recent meta-analysis, the overall incidence of restenosis remains high, up to 46% at 32 months, but is higher with balloon angioplasty alone (62.0%) compared with stenting (28.5%, risk ratio RR 2.18 (95% CI 1.64 to 2.89), $p=0.001$), with a comparable safety.¹⁰ Some studies suggest that long-term patency could be superior with stent sizes larger than 9 mm in diameter.^{9 11} Continuing follow-up is therefore recommended.

CONCLUSION

PVS is a serious complication of AF ablation that can be easily misdiagnosed. Although the incidence of this complication decreased due

to technical improvements, it is important to mention the diagnosis of PVS when a patient presents with suggestive symptoms post AF ablation. The longer the diagnosis is delayed, the greater the vascular and parenchymal lung damage, and in turn the more difficult it is to treat the PVS. Currently, the treatment of choice is angioplasty with stenting, preferably with a stent larger than 9 mm in diameter. A successful angioplasty can significantly relieve symptoms.

Acknowledgements We acknowledge the patient for his consent to publish the case. We acknowledge Dr Alix Juillet De Saint Lager for the images. We acknowledge Pr Dipen Shah for his review.

Contributors AM and SN conceived and designed the manuscript. AM collected and analysed the clinical data. AM wrote the original draft. SM-W and HM and SN revised the manuscript. All authors have read and agreed to the published version of the manuscript.

Funding The authors have not declared a specific grant for this research from any funding agency in the public, commercial or not-for-profit sectors.

Competing interests None declared.

Patient consent for publication Not applicable.

Provenance and peer review Not commissioned; externally peer reviewed.

Open access This is an open access article distributed in accordance with the Creative Commons Attribution Non Commercial (CC BY-NC 4.0) license, which permits others to distribute, remix, adapt, build upon this work non-commercially, and license their derivative works on different terms, provided the original work is properly cited and the use is non-commercial. See: <http://creativecommons.org/licenses/by-nc/4.0/>.

Case reports provide a valuable learning resource for the scientific community and can indicate areas of interest for future research. They should not be used in isolation to guide treatment choices or public health policy.

ORCID iDs

Aki Mizuno <http://orcid.org/0000-0001-9534-1390>

Stephane Noble <http://orcid.org/0000-0002-8018-2857>

REFERENCES

- 1 Pazos-López P, García-Rodríguez C, Guitián-González A, *et al*. Pulmonary vein stenosis: etiology, diagnosis and management. *World J Cardiol* 2016;8:81.
- 2 Calkins H, Hindricks G, Cappato R, *et al*. 2017 HRS/EHRA/ECAS/APHS/SOLAECE expert consensus statement on catheter and surgical ablation of atrial fibrillation. *EP Europace* 2018;20:e1–160.
- 3 Cappato R, Calkins H, Chen S-A, *et al*. Updated worldwide survey on the methods, efficacy, and safety of catheter ablation for human atrial fibrillation. *Circ Arrhythm Electrophysiol* 2010;3:32–8.
- 4 Robbins IM, Colvin EV, Doyle TP, *et al*. Pulmonary vein stenosis after catheter ablation of atrial fibrillation. *Circulation* 1998;98:1769–75.
- 5 Teunissen C, Velthuis BK, Hassink RJ, *et al*. Incidence of Pulmonary Vein Stenosis After Radiofrequency Catheter Ablation of Atrial Fibrillation. *JACC Clin Electrophysiol* 2017;3:589–98.
- 6 Holmes DR, Monahan KH, Packer D. Pulmonary vein stenosis complicating ablation for atrial fibrillation. *JACC Cardiovasc Interv* 2009;2:267–76.
- 7 Fender EA, Widmer RJ, Hodge DO, *et al*. Severe pulmonary vein stenosis resulting from ablation for atrial fibrillation: presentation, management, and clinical outcomes. *Circulation* 2016;134:1812–21.
- 8 Rostamian A, Narayan SM, Thomson L, *et al*. The incidence, diagnosis, and management of pulmonary vein stenosis as a complication of atrial fibrillation ablation. *J Interv Card Electrophysiol* 2014;40:63–74.
- 9 Prieto LR, Schoenhagen P, Arruda MJ, *et al*. Comparison of stent versus balloon angioplasty for pulmonary vein stenosis complicating pulmonary vein isolation. *J Cardiovasc Electrophysiol* 2008;19:673–8.
- 10 Buiatti A, von Olshausen G, Martens E, *et al*. Balloon angioplasty versus stenting for pulmonary vein stenosis after pulmonary vein isolation for atrial fibrillation: a meta-analysis. *Int J Cardiol* 2018;254:146–50.
- 11 Neumann T, Kuniss M, Conradi G, *et al*. Pulmonary vein stenting for the treatment of acquired severe pulmonary vein stenosis after pulmonary vein isolation: clinical implications after long-term follow-up of 4 years. *J Cardiovasc Electrophysiol* 2009;20:251–7.

Patient's perspective

My story starts with an ablation procedure to treat atrial fibrillation which initially started 7 months prior to the intervention. As part of the standard post-operative medication, I was put on apixaban for 3 months. 2 days after stopping the apixaban I started experiencing severe pain in my left lung, coughing blood. After visiting emergency department I was initially diagnosed with suspected pneumonia and put on a course of antibiotics. After 7 days, and with my condition not improving, I was put on another type of antibiotic. After another 10 days with no progress, I was admitted to hospital again for further scans and tests which revealed a stenosis in one of my pulmonary veins.

Immediately after the procedure to reopen this pulmonary vein with a stent the lung pain and coughing of blood completely stopped. I have not had any reoccurrence of the lung issues since the procedure.

Learning points

- Pulmonary vein stenosis (PVS) should be suspected when suggestive symptoms (shortness of breath, cough, fatigue, chest pain, haemoptysis and recurrent pulmonary infection) develop after atrial fibrillation ablation procedure.
- Treatment is indicated when symptomatic.
- Treatment consists of angioplasty of the pulmonary vein.
- The overall incidence of restenosis after angioplasty alone is high, up to 46% at 32 months, but is lower with stenting (especially with stent sizes larger than 9 mm in diameter) compared with balloon angioplasty alone.

Copyright 2022 BMJ Publishing Group. All rights reserved. For permission to reuse any of this content visit <https://www.bmj.com/company/products-services/rights-and-licensing/permissions/>
BMJ Case Report Fellows may re-use this article for personal use and teaching without any further permission.

Become a Fellow of BMJ Case Reports today and you can:

- ▶ Submit as many cases as you like
- ▶ Enjoy fast sympathetic peer review and rapid publication of accepted articles
- ▶ Access all the published articles
- ▶ Re-use any of the published material for personal use and teaching without further permission

Customer Service

If you have any further queries about your subscription, please contact our customer services team on +44 (0) 207111 1105 or via email at support@bmj.com.

Visit casereports.bmj.com for more articles like this and to become a Fellow