



Contents lists available at ScienceDirect

## International Journal of Surgery Case Reports

journal homepage: [www.casereports.com](http://www.casereports.com)

## Duodenal duplication cyst extending into the posterior mediastinum

Tuzun Sefa<sup>a</sup>, Cakir Mikail<sup>a,\*</sup>, Savas Anil<sup>a</sup>, Gur Umit<sup>a</sup>, Gundogdu Gokcen<sup>b</sup><sup>a</sup> Ministry of Health Haseki Research and Training Hospital, Department of General Surgery, Istanbul, Turkey<sup>b</sup> Istanbul University Faculty of Medicine, Department of Pathology, Istanbul, Turkey

## ARTICLE INFO

## Article history:

Received 19 December 2014

Received in revised form 12 February 2015

Accepted 12 February 2015

Available online 18 February 2015

## Keywords:

Duodenal duplication  
Diaphragmatic hernia  
Surgery

## ABSTRACT

**INTRODUCTION:** Duodenal duplication is a rare congenital malformation. Although more frequent in childhood, it is rarely observed in adulthood. Preoperative diagnosis can be difficult.**PRESENTATION OF CASE:** We report a case of 42 year-old woman with duodenal duplication cyst situated in the posterior mediastinum, who was misdiagnosed even after a primary surgery. Detailed diagnostic workup and a second operation was done.**DISCUSSION:** This article discusses the incidence of duodenal duplications, their types and clinical presentations, the radiologic and diagnostic features with different therapeutic options.**CONCLUSION:** Duodenal and the other intestinal duplication cysts should be considered in the differential diagnosis of oral contrast enhanced intrathoracic lesions in thoracoabdominal computerised tomography imaging.© 2015 The Authors. Published by Elsevier Ltd. on behalf of Surgical Associates Ltd. This is an open access article under the CC BY-NC-ND license (<http://creativecommons.org/licenses/by-nc-nd/4.0/>).

## 1. Introduction

Duplications of duodenum are rare congenital malformations observed 1 out of 100,000 deliveries, representing only 2–12% of gastrointestinal tract (GIT) duplications [1,2]. These abnormalities are usually diagnosed in infancy and childhood. In rare cases, they remain asymptomatic until adulthood, and 38% of patients are diagnosed after age of 20 [3]. Although duplication cysts can be seen at any level of alimentary tract from mouth to anus, with varying types, shapes and sizes; they mostly appear in distal ileum, followed by the esophagus, colon and jejunum [2,4,5]. They are usually located in the second or the third parts of duodenum, communicating with duodenal lumen in 25% of cases [6,7]. However, any cases of duodenal duplication cysts extending into the posterior mediastinum were not reported in the literature.

Because the lesion is rare and symptoms are nonspecific, duodenal duplications can represent a diagnostic challenge. Treatment is mainly surgical and total excision, if possible, is the procedure of choice. Because of extensive size or critical location, alternative procedures such as subtotal removal or digestive derivations are required [1,3,8].

In this article, we report an incidentally diagnosed duodenal duplication cyst placed in the posterior mediastinum in a 42 year-old woman. The diagnosis was confirmed by operative findings and subsequent histopathologic examinations. So we reviewed the literature by the way of this rare and complicated case.

## 2. Presentation of case

42 year-old female patient had right upper abdomen and thoracic pain with no other associated symptoms since the age of 7. Her pain was not related with eating in the earlier. In the last 15 years, the patient had daily pain, specially after eating and the pain was localised to the right upper abdomen, around stomach, right half of the back and specially in the right thoracic cage with nausea, vomiting and burping with bad odor. She had a weight loss of 10 kg because of eating fear in the last 3 months.

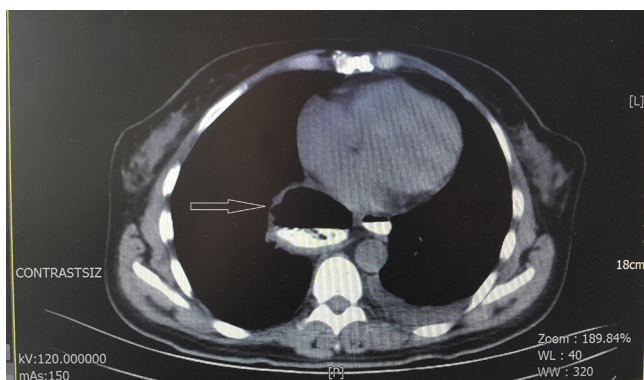
She had been hospitalised several times since the age of 7; but she had no accurate diagnosis and she had been treated symptomatically until 42 years old. Recently, a contrast enhanced thoracoabdominal computerised tomography (CT) demonstrated that intestines were placed in thoracic cavity so diaphragmatic hernia was thought. In the middle of the diaphragm, there was a defective area of 2.5 cm in diameter between the aorta and inferior vena cava, jejunal segments were herniated into the thoracic cavity from this defected area and compressed the esophagus.

*According to another radiologist:* Proximal duodenum was dilated and the other parts of duodenum were herniated to the posterior mediastinum. (Picture 1) Also there were other remarkable findings that lower cervical and upper thoracic 1st, 2nd, 3rd vertebrae were seen as hemivertebrae creating a vertebral block, and cecum was not in normal position, it was seen in hepatic flexura region.

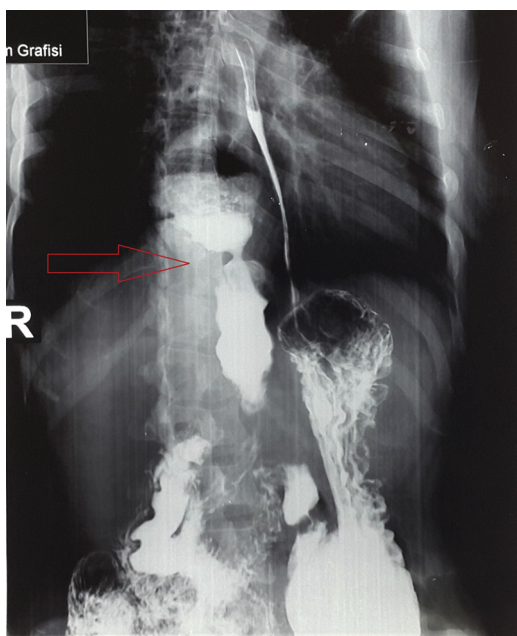
*Stomach and duodenum graphy:* An intestinal segment of 16 × 5 cm in dimensions extending to thoracic cavity from the mid-line of abdomen was compatible with diaphragmatic hernia. Also duodenum 3rd and 4th parts were located laterally in an opposite direction according to normal location (Picture 2).

\* Corresponding author. Tel.: +90 5324678191.

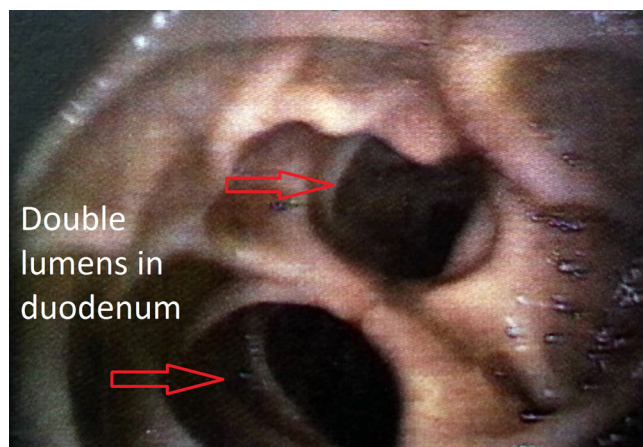
E-mail address: [drmikailcakir@yahoo.com](mailto:drmikailcakir@yahoo.com) (C. Mikail).



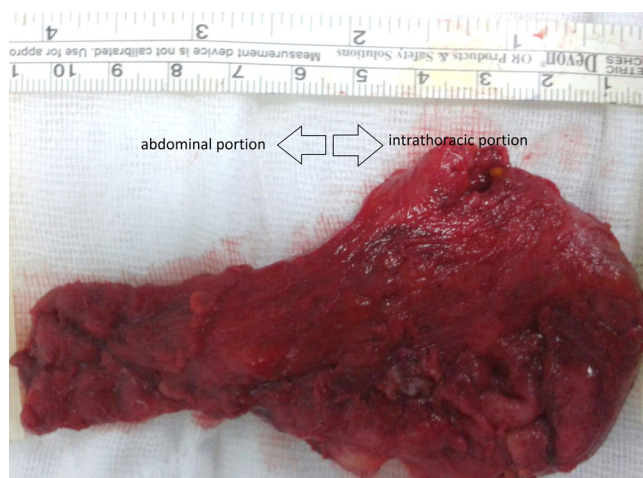
Picture 1. Herniation in the posterior mediastinum.



Picture 2. Intestinal segment extending into thoracic cavity.



Picture 3. Double lumens in the 3rd part of duodenum.



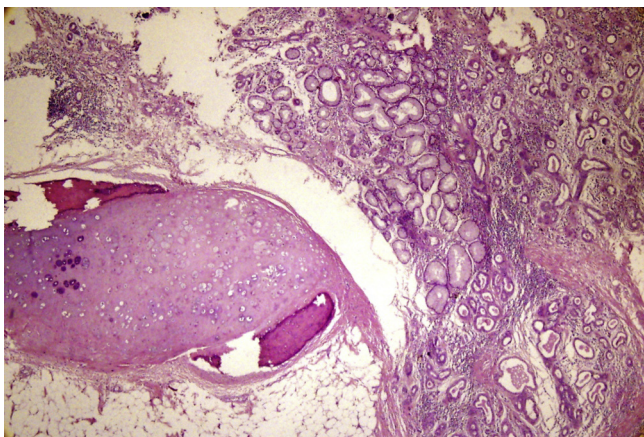
Picture 4. Specimen.

**Esophagogastroduodenoscopy:** Double lumens were seen in the third part of duodenum; one of them was covered with normal mucosa and advancing with endoscope was possible but in the other lumen, there were intestinal contents, and luminal continuity was not seen, endoscope could not be advanced (Picture 3).

With all these findings the patient was operated by a team in Haseki Research and Training Hospital with the preoperative diagnosis of diaphragmatic hernia. In this operation, the diaphragm was evaluated as normal, diaphragmatic hernia was not identified but 3rd and 4th parts of duodenum were not found in normal location, and Treitz ligament was not seen, these parts were placed laterally in an opposite direction. Cecum and ascending colon were not seen in normal location, cecum was in the location of hepatic flexura, also a recessus was identified in the area of Treitz ligament. Through the recessus, transvers colon was internally herniated. This hernia was repaired and the operation was finished.

On the 6th day postoperatively, the patient was unrest with fever, abdominal tenderness and the same complaints before the operation. Another contrast enhanced thoracoabdominal CT was done. The findings were the same as preoperative CT. Also inflammatory changes and fluid collection were identified. The patient was reoperated by another surgical team. Exploration did not reveal any herniation into diaphragm initially and the colonic segment brought to normal location in the first operation was ischemic. The

ischemic segment was resected and anastomosed end to end. Then, the diaphragm was re-examined and subdiaphragmatically, connective tissue between the aorta and the inferior vena cava was explored with the guidance of CT findings. A tubular structure about 1.5 cm in diameter extending retroperitoneally was identified at the superior border of the pancreas. This structure was extending to pancreas inferiorly, and to diaphragm posterosuperiorly, finally reaching to thoracic cavity between the aorta and the inferior vena cava. The tubular structure was aspirated by a fine needle. Some fluid stained with bile was collected in the syringe. The puncture site was incised 2 mm, bile containing fluid was recollected. Number 3 and 4 Bakes dilators were inserted through the incision. The lumen of tubular structure was connected inferiorly to the third part of duodenum behind pancreas and superiorly extending about 15 cm into the thoracic cavity with a blind end. Then, 12F Foley catheter was inserted and by giving contrast media, directographies were taken. Inferiorly, duodenum was seen with contrast media and superiorly in thoracic cavity, a saccular cystic structure of 8 cm in diameter was seen. It was thought that removal of this saccular cyst would not be possible from the abdomen. Therefore a right anterior thoracotomy was performed through the 6th intercostal space. The cyst was located in the posterior mediastinum and with careful dissection, upper end of the cyst conjoined with vertebrae was divided. The lesion was 15 cm in length. Intraabdominal portion was divided by a linear stapler from the upper border of pancreas (Picture 4).



**Picture 5.** Duplication cyst with chondroid areas.

The patient was discharged on the 7th day postoperatively with no complaints. Also she had no complaint after 3 months postoperatively. Regular follow-up was advised for retropancreatic tubular structure.

### Pathology

Duodenal mucosa, squamous epithelium and ulceration with prominent inflammation were seen in the microscopic examination of the duodenal lesion. Among the submucosal, intramural and subserosal layers of the duodenum, glandular structures as groups and chronic inflammation with lymphoid follicle hyperplasia were detected. Immunohistochemically the glandular structures were positive with cytokeratin 19. Focal chondroid areas with ossification were observed.

Histopathologic and surgical findings were consistent with duodenal duplication cyst with metaplastic changes and ectopic pancreatic tissue (Picture 5)

### 3. Discussion

GI duplication cysts are rare congenital anomalies. They are defined by a smooth muscle coat, an intimate attachment to the native GIT and GIT mucosal lining [2,9]. They can occur anywhere along the GIT, with varying types, shapes and sizes. GI duplication cysts are most commonly found in the distal ileum, followed by the esophagus, colon and jejunum [2,4,5,9].

Duodenal duplication cysts are the rarest type of all intestinal duplications, only 5% of all cases [4,10]. A recent meta-analysis between 1998 and 2009 reported a total of 47 cases of duodenal duplication cysts [1,11]. Classically, they are located in the second or the third parts of duodenum and share a common wall, communicating with the duodenal lumen in 25% of cases [6,7]. They can be cystic or tubular, communicating or non-communicating, but the most common type is cystic and non-communicating. The cysts are usually filled with clear fluid, but might contain gallstones, bile or pancreatic fluid depending on communication with the biliary or pancreatic systems [2,12].

In our case, the duodenal duplication was cystic and located in the third part of the duodenum, it was communicating type, the neck part located between the aorta and the inferior vena cava was extending into the posterior mediastinum through the diaphragm. The length was 15 cm. Inside the cyst, there was biliary content. In the literature review, such a case, lesion extending into posterior mediastinum through diaphragm has not been reported until now.

Like other intestinal duplications, most duodenal duplications are diagnosed in childhood, and detecting such a lesion in advanced age is extremely rare. 38% of patients are diagnosed after 20 years of age [3]. A variety of clinical manifestations have been reported. Generally, the most common symptoms are abdominal pain, nausea and vomiting [1,2]. The most common complication is pancreatitis, reported in up to 53% of patients. Other manifestations such as intussusception, infection or weight loss have also been reported [13]. In a few cases, ectopic gastric mucosa can be observed and causes ulceration, bleeding and even perforation [1,8,14]. Duodenal duplication cysts are generally benign lesions, nevertheless, three cases of malignant tumors arising inside have been reported [3,15].

In our case, the patient had non-specific right upper abdominal and right thoracic pain since the age of 7. She had many times symptomatic treatments until she was 42 years old. In the last 15 years, the right back pain, nausea, vomiting, burping with bad odor were added to her complaints. In addition, there was a weight loss of 10 kg in the last 3 months because of fear of eating.

The preoperative diagnosis of duodenal duplication is often inaccurate [1,2]. Diagnosis is usually made by imaging modalities such as ultrasonography (USG) or CT scans. On USG, duodenal duplication is seen as having an echogenic inner mucosa surrounded by a hypoechogenic outer muscular layer [5]. CT scan often reveals a cystic mass connected with the alimentary tract and is more useful in demonstrating the precise anatomical relationship between cyst and surrounding structures [5]. Magnetic resonance imaging as well as endoscopic USG is useful in evaluating upper GIT masses [10,16]. However, all modalities provide us only to suspect the presence of an abnormal lesion, and diagnostic confirmation is possible only after resection [2].

Also in our case, although non-specific symptoms were present since the age of 7, it was not definitely diagnosed despite all these examinations until she was 42. When she was 42 years old, an incidentally performed thoracoabdominal CT showed a cystic structure in the thorax. First it was thought that intestinal segments had been located in the thorax and misdiagnosed as diaphragmatic hernia. However, upper GIT radiography, endoscopy and the other examinations did not conclude in a preoperative accurate diagnosis.

In the first operation, diaphragmatic defect could not be identified and diagnosis was missed. Internal herniation of the transvers colon was identified due to anomalies of the third and the fourth parts of duodenum and absence of Treitz ligament. However, the definite diagnosis was made in the second laparotomy needed on the 6th day after the first operation.

Treatment of duodenal duplication cyst is mainly surgical, and total excision, if possible is the procedure of choice. However, in some cases, because of extensive size or critical location, alternative procedures, such as subtotal removal or digestive derivations, are required [1,2,17]. Treatment of asymptomatic cases remains controversial. However, as neoplasms have been reported within duodenal duplication cysts, surgical resection must be considered [2,13].

In our case, duodenal duplication cyst extending into the posterior mediastinum was excised subtotally, retropancreatic portion of about 3 cm in length was left in place. Pathologic result is benign and the patient will be followed annually with CT and endoscopic USG.

In conclusion, duodenal duplication cysts are rare congenital anomalies that are seldom reported in adults. However, intrathoracic lesions containing contrast media in thoracoabdominal contrast enhanced CT's should not be thought as diaphragmatic hernia each time. It should be kept in mind that it might also be a GI duplication cyst also.

## References

- [1] A. Al-Harake, A. Bassal, et al., Duodenal duplication cyst in a 52 year-old man: a challenging diagnosis and management, *Int. J. Surg. Case Rep.* 4 (2013) 296–298.
- [2] S.Y. Ko, S.H. Ko, et al., A of a duodenal duplication case presenting as melena, *World J. Gastroenterol.* 19 (October 14 (38)) (2013) 6490–6493.
- [3] B. Seelinger, T. Piardi, et al., Duodenal duplication cyst: a potentially malignant disease, *Ann. Surg. Oncol.* 19 (November (12)) (2012) 3753–3754.
- [4] S. Tanaka, M. Goubaru, et al., Duodenal duplication cyst of the ampulla of Vater, *Intern. Med.* (2015), <http://dx.doi.org/10.2169/46.0451>.
- [5] N.K. Lee, S. Kim, et al., Complications of congenital and development abnormalities of gastrointestinal tract in adolescents and adults: evaluation with multimodality imaging, *Radiographics* 30 (2010) 1489–1507.
- [6] A. McArdle, et al., Duodenal duplication cyst presenting with gastric outlet obstruction in an adult male, *Endoscopy* 43 (2011) E352–E353.
- [7] R.B. Trobs, M. Hemminghaus, et al., Stone-containing perampullary duodenal duplication cyst with aberrant pancreatic duct, *J. Pediatr. Surg.* 44 (2009) 33–35.
- [8] T. Merrot, R. Anastasescu, et al., Dudenal duplications, clinical charesteristics, embryological hypotheses, histological findings, treatment, *Eur. J. Pediatr. Surg.* 16 (2006) 18–23.
- [9] H.C. Chang, S.C. Huang, et al., Duodenal duplication cyst: a rare cause of geriatric gastrointestinal bleeding, *J. Chin. Med. Assoc.* 74 (2011) 233–236.
- [10] R.T. Soper, A.C. Selke, Duplication cyst of the duodenum: case report and discussion, *Surgery* 68 (1970) 562–566.
- [11] J.-J. Chen, H.-C. Lee, Meta analysis: the clinical features of the duodenal duplication cyst, *J. Pediatr. Surg.* 45 (8) (2010) 1598–1606.
- [12] R.J. Lad, P. Fitzgerald, et al., An unusual cause of recurrent pancreatitis: duodenal duplication cyst, *Can. J. Gastroenterol.* 14 (2000) 341–345.
- [13] J.J. Chen, H.C. Lee, et al., Meta analysis: the clinical features of the duodenal duplication cyst, *J. Pediatr. Surg.* 45 (2010) 1598–1606.
- [14] D. Arbell, A. Lebenthal, et al., Duplication cyst of the duodenum as an unusual cause of massive gastrointestinal bleeding in an infant, *J. Pediatr. Surg.* 37 (2002) E8.
- [15] D.G. Coit, mĭEsc Adenocarcinoma arising within a gastric duplication cyst, *J. Surg. Oncol.* 50 (1992) 274–277.
- [16] A. Rotondo, M. Scialpi, et al., Duodenal duplication cyst: MR imaging apperance, *Eur. Radiol.* 9 (1999) 890–893.
- [17] A. Conlin, T. Kaltenbach, et al., Endoscopic resection of gastrointestinal lesions: advancement in the application of endoscopic submucosal dissection, *J. Gastroenterol. Hepatol.* 25 (2010) 1348–1357.

## Open Access

This article is published Open Access at [sciedirect.com](http://sciedirect.com). It is distributed under the [IJSCR Supplemental terms and conditions](#), which permits unrestricted non commercial use, distribution, and reproduction in any medium, provided the original authors and source are credited.