

ORIGINAL ARTICLE

# An observational study to determine volume changes in the functional liver remnant following portal vein embolization

Vikrant Dhurandhar,\*  Richard Waugh,\* Sulman Ahmed,<sup>†</sup> Suchitra Mantrala\* and Joga Chaganti\*<sup>‡</sup> 

Departments of \*Medical Imaging, <sup>†</sup>Surgery, Nepean Hospital, Kingswood and <sup>‡</sup>Department of Radiology, St Vincent's Hospital, Sydney, New South Wales, Australia

## Key words

functional liver remnant, hepatic resection, outcomes, portal vein embolization.

Accepted for publication 1 July 2021.

## Correspondence

\*Vikrant Dhurandhar, Medical Imaging Department, West Block, Nepean Hospital, Derby Street, Kingswood, NSW 2747, Australia.  
Email: vikrantdhurandhar@gmail.com

**Declaration of conflict of interest:** No conflicts of interest were identified.

## Abstract

**Background and Aim:** Portal vein embolization (PVE) prior to hepatic resection reduces the risk of hepatic insufficiency in the postoperative period by redistributing blood from the embolized unhealthy liver to the healthy liver, termed the functional liver remnant (FLR). A retrospective analysis of liver volumes after embolization in a single institution was performed to identify change in volume of the FLR and determine factors affecting this change.

**Methods:** Between 2013 and 2015, 21 patients undergoing PVE followed by hepatic resection for varied indications (colorectal metastases, hepatocellular carcinoma, cholangiocarcinoma, etc.) were included in this study. *n*-butyl cyanoacrylate glue diluted with Lipiodol (35–45% strength) along with 75–100 µm of polyvinyl alcohol particles were used for embolization. Liver volumetric determination was performed before and after PVE and volume changes in the FLR were analyzed. Biochemical factors and factors affecting FLR hypertrophy were also analyzed.

**Results:** Majority of the patients (*n* = 18) underwent right-lobe embolization. All were performed using the ipsilateral approach. No major complications occurred with only one patient developing post-procedural ascites requiring percutaneous draining. A significant increase in the mean volume of the FLR by 63.7% ± 91.6%, *P* = 0.001 was noted after PVE. The FLR/total liver volume (TLV) increased significantly by 17% ± 18%. No significant demographic factors affected FLR hypertrophy and no significant biochemical changes were noted. Thirteen patients were successfully operated on after embolization.

**Conclusions:** PVE is effective in inducing significant hypertrophy of the future FLR, prior to hepatic resection in our institution.

## Introduction

Portal vein embolization (PVE) is a procedure done prior to hepatic resection to reduce the risk of hepatic insufficiency in the postoperative period. It involves the redistribution of blood flow from the area of liver being resected to the healthy portion of liver. This induces atrophy in the diseased segments to be resected while promoting growth of healthy liver, thereby increasing functional liver remnant (FLR) volume prior to resection. Evidence shows this procedure reduces adverse outcomes following partial hepatectomy.<sup>1</sup>

The portal vein can be embolized via a range of approaches. Surgical approaches, such as the transileocolic approach, have recently been overtaken by percutaneous techniques, including the transhepatic ipsilateral and contralateral approaches, as the preferred technique.<sup>2</sup> There are also a variety of embolic agents that can be deployed, including microparticles, fibrin glue, coils, and *n*-butyl cyanoacrylate.<sup>2</sup> Generally, right-lobe PVE is more common, as the right lobe of the liver is

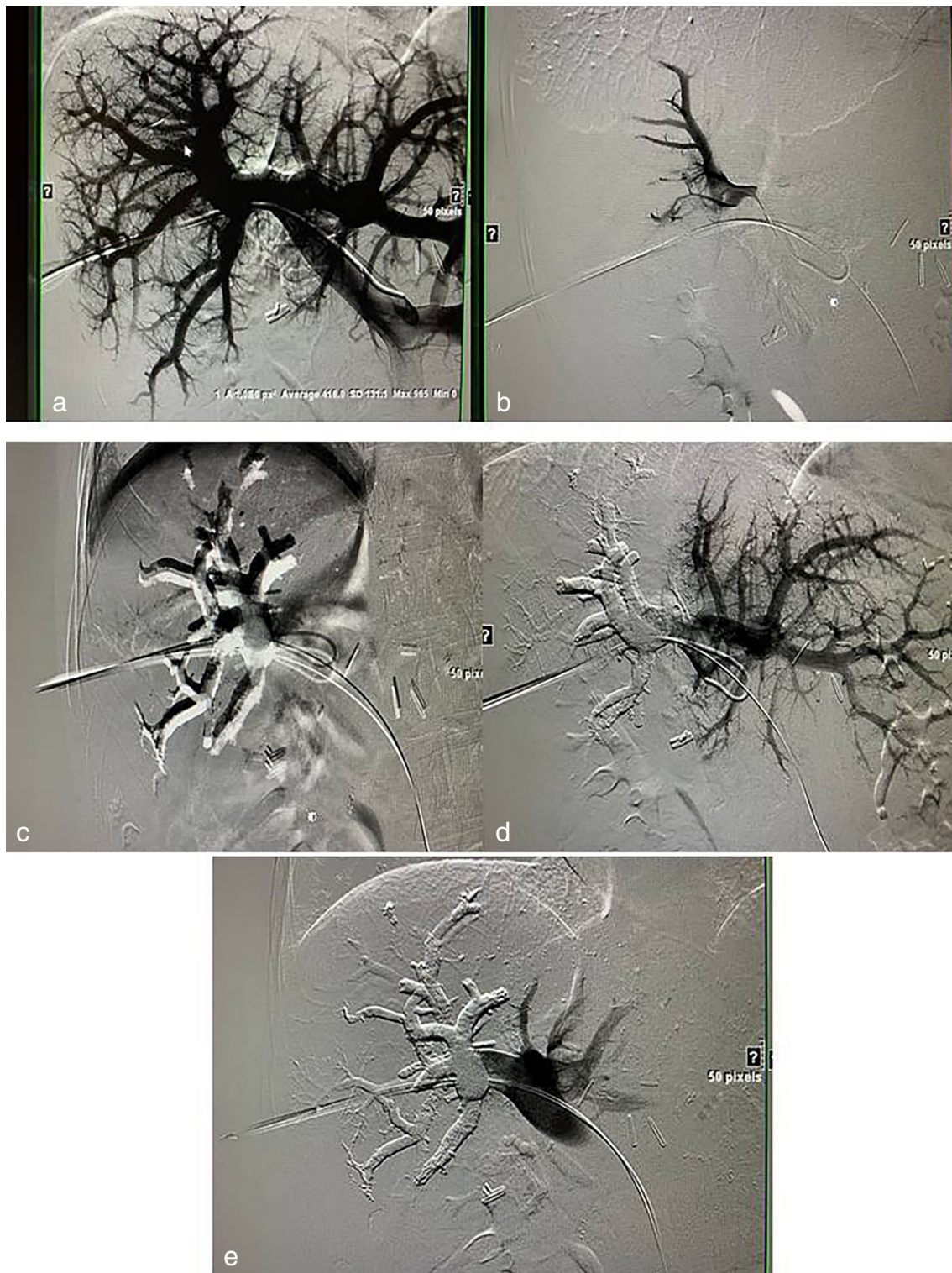
usually large enough to accommodate for left sided liver resections, thereby reducing the need for left lobe PVE.

Although evidence exists to demonstrate the beneficial effects of PVE,<sup>3</sup> thus far to our knowledge there has not been a collaboration of data within an Australian institution with regards to change in liver volume following the procedure. We present our initial data on 21 patients who underwent preoperative PVE and assess the efficacy of embolization in the regeneration of the FLR. We also discuss the factors affecting the outcomes in the regeneration of FLR and assess how this compares with the published literature.

The aim of this study is to analyze and quantify the response, measured as changes in liver volume, in all patients undergoing PVE at our institution, and compare our outcomes with existing literature.

## Methods

Institutional ethics approval was obtained prior to conducting this retrospective observational study.



**Figure 1** (a) Portogram through right portal venous access; (b) Shepherd's hook catheter in the main portal vein with catheter tip facing the right portal vein and right portal venogram with microcatheter (Progreat 2.7F 110 cm); (c, d) buddy wire in the portal vein, Shepherd's hook drawn further inwards toward portal vein and *n*-butyl cyanoacrylate glue cast in the right portal vein; (e) final portogram demonstrating embolized right portal vein and patent main and left portal vein.

**Patient selection.** From 2013 to 2015, there were 24 patients who underwent PVE at our institution.

**Procedural technique.** A percutaneous transhepatic approach was carried out. All patients underwent gelfoam slurry embolization of the tract. Embolization was performed using 75–100  $\mu\text{m}$  polyvinyl alcohol (PVA) particles to embolize distal portal branches followed by *n*-butyl cyanoacrylate (NBCA) glue diluted to 35–45% strength with Lipiodol. Volume of glue used depended on the portal vein bed, but generally about 5–6 mL were used on average. Coils were used to complete the target portal vein occlusion if there was any concern regarding reflux of the NBCA glue. Each glue catheter was discarded after procedure. Figure 1 shows the procedural images of one of the patients in our cohort.

**Liver volumetry protocol.** All patients underwent computer tomography (CT) scanning on day 1, and a follow-up CT scan at approximately 4 weeks was performed. Liver volumes for all patients were measured using CT Syngo.Via (Siemens Healthcare, Siemens AG, Germany) by an experienced technician and supervised by a radiologist with over 20 years of experience. Using these measurements, the changes in volumes of the FLR, the embolized liver segments, and the entire liver were calculated.

**Definition of terms.** The FLR was considered to be the non-diseased liver intended to be the remnant liver after surgical resection.

Hypertrophy response was defined as the percentage increase in FLR post-embolization.

The FLR/total liver volume ratio (FLR/TLV%) as well as the increase in this ratio was also calculated.

Liver enzymes, full blood count, and coagulation profile were measured before the PVE, 1–2 days after the procedure, and 3–4 weeks after the procedure. Operative details of hepatic resection and complications were identified for each patient.

**Statistical analysis.** Stata version 12.0 was used for all the statistical analysis.

Data are expressed as mean  $\pm$  SD or percentage  $\pm$  SD unless otherwise stated and analyzed using the one-tailed paired *t*-test and the unpaired *t* test for factors affecting FLR hypertrophy. A *P* value less than 0.05 was considered significant throughout.

## Results

Out of the initial 24 patients, 3 patients were excluded. One patient had no follow-up CT after PVE and therefore changes in liver volume were unable to be calculated. One patient had a previous left hemihepatectomy and had a right posterior PVE, but the CT did not calculate the required volumes within the existing right liver lobe. One patient's procedure was abandoned due to possible portal vein thrombosis. Thus, a total of 21 patients were included in the study.

There were 7 females and 14 males, with a mean age of  $60.9 \pm 8.3$  years. Three out of the 21 patients had a left PVE, while the remaining 18 had a right PVE. Colorectal metastases

**Table 1** Demographic data

Variable	Number ( <i>n</i> )
Overall	21
Males	14
Age (mean $\pm$ years)	$60.8 \pm 8.3$
Indication	
Colorectal carcinoma metastases	13
Hepatocellular carcinoma	3
Neuroendocrine tumor	2
Cholangiocarcinoma	2
Thyroid carcinoma metastases	1
Underlying systemic disease	
Cirrhosis	6
Neoadjuvant chemotherapy	5
Diabetes	3

**Table 2** Changes in liver volume

Variable	Pre-embolization (mean $\pm$ SD)	Post-embolization (mean $\pm$ SD)	<i>P</i> value
TLV ( $\text{cm}^3$ )	$1931.6 \pm 503.8$	$1851.3 \pm 410.8$	0.31
FLR ( $\text{cm}^3$ )	$635.6 \pm 318.2$	$933.8 \pm 444.6$	0.001
FLR/TLV (%)	$33.3 \pm 15.5$	$50.3 \pm 20.1$	<0.001
Hypertrophy of FLR (%)		$63.7 \pm 91.6$	
Increase in FLR/TLV (%)		$17 \pm 18$	

FLR, functional liver remnant; TLV, total liver volume.

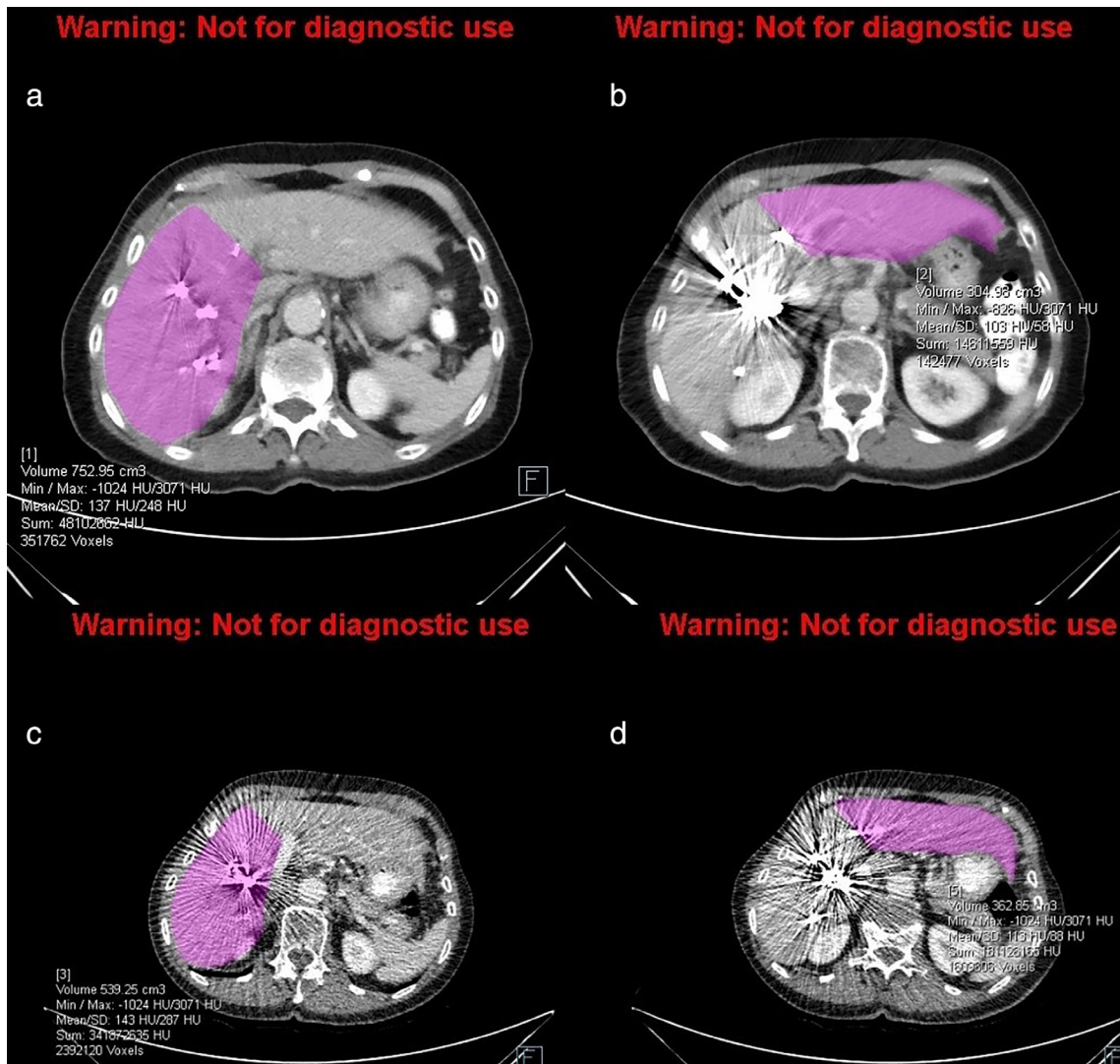
was the most common indication for the procedure ( $n = 13$ ). An ipsilateral approach was followed for all the procedures except for left PVE (right portal vein accessed and left portal vein was embolized). All procedures included in the study ( $n = 21$ ) were technically successful with only one patient developing post-procedural ascites requiring percutaneous drain insertion, which was removed on resolution on day 2. Ascites was not a major issue in our cohort as the Child–Pugh class was never more than A. The patient demographics and indications are tabulated in Table 1.

There was a significant increase in the mean FLR volume after embolization as well as in the FLR/TLV ratio. The volume changes are tabulated in Table 2. Figure 2 demonstrates the use of the CT mapping technique used to determine liver volumes before and after PVE.

The biochemical changes demonstrated no significant changes in liver enzymes, coagulation profile, and full blood count, which returned to baseline by week 4 after PVE. These are summarized in Table 3.

No significant relationship was demonstrated to affect the change in FLR volume after embolization. These are tabulated in Table 4.

Out of 21 patients undergoing PVE, 13 underwent successful hepatic resection (right segmentectomy = 2, right hemihepatectomy = 7, right extended hemihepatectomy = 3, left extended hemihepatectomy = 1). One patient developed major complications in the form of portal vein thrombosis with acute



**Figure 2** These images show liver volume mapping from the CT Syngo.Via program on a single patient undergoing right sided PVE. The pre- and post-PVE volumes of the left lobe/FLR were (b) 304.98 cm<sup>3</sup> and (d) 362.85 cm<sup>3</sup>, respectively, demonstrating hypertrophy. The pre- and post-PVE volumes of the right lobe/embolized lobe were (a) 752.95 cm<sup>3</sup> and 539.25 cm<sup>3</sup>, respectively, demonstrating atrophy. CT, computed tomography; FLR, functional liver remnant; PVE, portal vein embolization.

**Table 3** Biochemical changes before and after PVE

Variable	1 day before PVE (mean ± SD)	1–2 days after PVE (mean ± SD)	3–4 weeks after PVE (mean ± SD)
AST (U/L)	60.9 ± 15.3	64.7 ± 35.7	44.5 ± 20.4
ALT (U/L)	83.6 ± 26.2	72.7 ± 48.5	44.5 ± 18.9
ALP (U/L)	75.4 ± 103.6	152.7 ± 6.2	192.6 ± 118.4
Bilirubin (µmol/L)	8.9 ± 4	13.4 ± 6.2	11.5 ± 4.1
Hemoglobin (g/L)	126.3 ± 15.2	122.3 ± 18.6	129.7 ± 17.2
WCC × 10 <sup>9</sup> /L	6.3 ± 1.8	7.9 ± 2.4	6.6 ± 2.6
Platelet × 10 <sup>9</sup> /L	237.4 ± 98	197.5 ± 82.3	215.8 ± 94.8
INR	1 ± 0.1	1.1 ± 0.1	1.04 ± 0.08

ALT, alanine aminotransferase; ALP, alkaline phosphatase; AST, alkaline phosphatase; PVE, portal vein embolization; WCC, white cell count.

fulminant liver failure resulting in mortality perioperatively. One patient developed a contained bile leak postoperatively, which resolved within 3 days with percutaneous drain insertion. Four patients developed tumor recurrence at the resection margins within 1 year, while one patient developed resection margin recurrence in 3 years. Eight patients did not receive a hepatic resection after PVE. Six patients developed metastases in the FLR, while one patient was considered a poor surgical candidate d/t poor mobility and was offered micro-ablation of the deposits instead. Only one patient did not reach satisfactory regeneration. No predictors of satisfactory regeneration were identified.

The average number of days between PVE and the follow-up CT measurements was 29 ± 7 days.

**Table 4** Factors affecting functional liver remnant (FLR) hypertrophy

Variable	N	FLR hypertrophy (% ± SD)	P value
Age			NS
≤60 years	7	77.7 ± 130.6	
>60 years	14	56.7 ± 69.8	
Gender			NS
Male	14	59.5 ± 103.9	
Female	7	71.9 ± 66.9	
Cirrhosis			NS
Yes	6	40.4 ± 51.8	
No	15	73.0 ± 103.5	
Neoadjuvant chemotherapy			NS
Yes	5	106.6 ± 150.0	
No	16	50.3 ± 66.3	
Diabetes			NS
Yes	3	87.8 ± 104.2	
No	18	59.6 ± 92.1	

Figure 2 demonstrates the use of the CT mapping technique used to determine liver volumes before and after PVE.

## Discussion

This is one of the largest PVE series from an Australian institution. The results from our institution demonstrate a significant increase in the mean volume of the FLR and a significant increase in the FLR to total liver volume ratio. Our mean hypertrophy rate of approximately 64% is higher than available literature.

A systematic review conducted by Van Lienden *et al.*<sup>4</sup> analyzed 44 articles and included 1791 patients undergoing PVE. Although statistical analysis was difficult due to the heterogeneity of the data collected in these articles, it found that the mean hypertrophy response was 37.9%. Kuo *et al.*<sup>5</sup> found a 35% increase in FLR volume following PVE, in a retrospective review of 25 patients. It can be seen that there is a difference in hypertrophy rates, with our study demonstrating a greater hypertrophy response. The higher success rate could be due to the small sample size and the fact that there was a wide range in the degree of FLR hypertrophy as evidenced by the SD of 91 cm<sup>3</sup>. No significant differences in the selection criteria or the methodology were thought to be a known factor.

Although the data from our institution are encouraging, there exists a wide range of results in FLR hypertrophy. With the growing use of PVE in our center as well as in other centers, it is important to consider some of the reasons why such a range of results may exist.

One factor affecting the response to PVE is the presence or absence of cirrhosis. An appropriate hypertrophy response is dependent on healthy residual hepatic tissue being able to regenerate, however in patients with cirrhosis this is less likely.<sup>4,6</sup> Moreover, primary hepatocellular carcinoma (requiring PVE) is more likely in patients with chronic liver disease and cirrhosis.<sup>7,8</sup> Only six patients had Child–Pugh A cirrhosis (three with hepatocellular carcinoma, two with colorectal cancer metastases, and one with cholangiocarcinoma). The other patients had no

cirrhosis. The colorectal cancer metastases patients did have multiple cycles of chemotherapy, which can diminish regeneration but it is very difficult to quantify this. Interestingly, the presence or absence of cirrhosis did not significantly affect the FLR hypertrophy in our study.

The type of embolization material used during the procedure may also have a role in the degree of embolization and subsequent hypertrophy of healthy liver.<sup>9</sup> Although large studies investigating this are lacking, the systematic review conducted by Van Lienden *et al.* demonstrated a possible link between *n*-butyl cyanoacrylate use and increased hypertrophy.<sup>4</sup> In our institution, the first few cases were initially performed with coils and PVA particles before NBCA glue was used. Thus, it is difficult to quantify whether this may have influenced the results.

The accuracy in measurement of liver volumes is also paramount. Measurements are done by the radiologist using computer-aided algorithms but there is a degree of variability, which is difficult to quantify.<sup>10</sup> Furthermore, some centers use differing measurements for determining the degree of hypertrophy. These include measuring total functioning liver volume, which involves measuring the tumor volume specifically and subtracting this from the total liver volume.<sup>11</sup> Other centers also use liver volumes standardized to patient body surface area.<sup>12</sup> These differences can lead to difficulty in comparison of results from different centers.

This study is limited by the inherent limitations of a retrospective study. Additionally, despite this being the largest series of patients in Australia, the total numbers are small compared with other international centers. There is no distinct selection criterion for patients undergoing portal venous embolization in Australia and all decisions are made by a multidisciplinary team. Thus, selection bias cannot be adequately excluded.

In conclusion, PVE is an effective method of inducing hypertrophy of healthy hepatic tissue prior to hepatic resection. The results from our institution are encouraging, with slightly better results to existing data in FLR hypertrophy measurements. Further large data research and collaboration are needed to quantify the factors influencing the effectiveness of PVE and facilitate a standardized approach to liver volumetry and selection of patients for PVE.

## References

- 1 Abulkhir A, Limongelli P, Healey A *et al.* Preoperative portal vein embolization for major liver resection: a meta-analysis. *Ann. Surg.* 2008; **247**: 49–57.
- 2 Abdalla E, Hicks M, Vauthey J. Portal vein embolization: rationale, technique and future prospects. *Br. J. Surg.* 2001; **88**: 165–75.
- 3 Azoulay D, Castaing D, Smail A *et al.* Resection of nonresectable liver metastases from colorectal cancer after percutaneous portal vein embolization. *Ann. Surg.* 2000; **231**: 480–6.
- 4 van Lienden K, van den Esschert JW, de Graaf W *et al.* Portal vein embolization before liver resection: a systematic review. *Cardiovasc. Intervent. Radiol.* 2013; **36**: 25–34.
- 5 Kuo SCL, Azimi-Tabrizi A, Briggs G *et al.* Portal vein embolization prior to major liver resection. *ANZ J. Surg.* 2014; **84**: 341–5.
- 6 Imamura H, Sano K, Sugawara Y, Kokudo N, Makuuchi M. Assessment of hepatic reserve for indication of hepatic resection: decision

- tree incorporating indocyanine green test. *J. Hepatobiliary Pancreat. Surg.* 2005; **12**: 16–22.
- 7 Lee KC, Kinoshita H, Hirohashi K, Kubo S, Iwasa R. Extension of surgical indications for hepatocellular carcinoma by portal vein embolization. *World J. Surg.* 1993; **17**: 109–15.
- 8 Farges O, Belghiti J, Kianmanesh R *et al.* Portal vein embolization before right hepatectomy. *Ann. Surg.* 2003; **237**: 208–17.
- 9 Madoff DC, Hicks ME, Vauthey JN *et al.* Transhepatic portal vein embolization: anatomy, indications, and technical considerations. *Radiographics.* 2002; **22**: 1063–76.
- 10 Vauthey JN, Abdalla EK, Doherty DA *et al.* Body surface area and body weight predict total liver volume in Western adults. *Liver Transpl.* 2002; **8**: 233–40.
- 11 Kim HJ, Kim CY, Hur YH *et al.* Comparison of remnant to total functional liver volume ration and remnant to standard liver volume ration as a predictor of postoperative liver function after liver resection. *Korean J. Hepatobiliary Pancreat. Surg.* 2013; **17**: 143–51.
- 12 Vauthey JN, Chaoui A, Do KA *et al.* Standardized measurement of the future liver remnant prior to extended liver resection: methodology and clinical associations. *Surgery.* 2000; **127**: 512–19.