



Received: 2014.04.23
Accepted: 2014.05.12
Published: 2014.10.24

Evaluation of Labral Pathology and Hip Articular Cartilage in Patients with Femoroacetabular Impingement (FAI): Comparison of Multidetector CT Arthrography and MR Arthrography

Authors' Contribution:

- A** Study Design
- B** Data Collection
- C** Statistical Analysis
- D** Data Interpretation
- E** Manuscript Preparation
- F** Literature Search
- G** Funds Collection

Murat Sahin^{1ABEF}, Cuneyt Calisir^{1ADEE}, Hakan Omeroglu^{2B}, Ulukan Inan^{2AB}, Fezan Mutlu^{3G}, Tamer Kaya^{1ABD}

¹ Department of Radiology, Eskisehir Osmangazi University, School of Medicine, Eskisehir, Turkey

² Department of Orthopaedics, Eskisehir Osmangazi University, School of Medicine, Eskisehir, Turkey

³ Department of Biostatistics, Eskisehir Osmangazi University, School of Medicine, Eskisehir, Turkey

Author's address: Cuneyt Calisir, Department of Radiology, Eskisehir Osmangazi University School of Medicine, Eskisehir, Turkey, e-mail: drcalisir@gmail.com

Background:

To compare the multidetector computed tomography (MDCT) arthrography (CTa) and magnetic resonance (MR) arthrography (MRa) findings with surgical findings in patients with femoroacetabular impingement (FAI) and to evaluate the diagnostic performance of these methods.

Material/Methods:

Labral pathology and articular cartilage were prospectively evaluated with MRa and CTa in 14 hips of 14 patients. The findings were evaluated by two musculoskeletal radiologists with 10 and 20 years of experience, respectively. Sensitivity, specificity, accuracy, and positive predictive value were determined using surgical findings as the standard of reference.

Results:

While the disagreement between observers was recorded in two cases of labral tearing with MRa, there was a complete consensus with CTa. Disagreement between observers was found in four cases of femoral cartilage loss with both MRa and CTa. Disagreement was also recorded in only one case of acetabular cartilage loss with both methods. The percent sensitivity, specificity, and accuracy for correctly assessing the labral tearing were as follows for MRa/CTa, respectively: 100/100, 50/100, 86/100 ($p < 0.05$). The same values for acetabular cartilage assessment were 89/56, 40/60, 71/71 ($p > 0.05$) and for femoral cartilage assessment were 100/75, 90/70, 86/71 ($p > 0.05$). Inter-observer reliability value showed excellent agreement for labral tearing with CTa ($\kappa = 1.0$). Inter-observer agreement was substantial to excellent with regard to acetabular cartilage assessment with MRa and CTa ($\kappa = 0.76$ for MRa and $\kappa = 0.86$ for CTa)

Conclusions:

Inter-observer reliability with CTa is excellent for labral tearing assessment. CTa seems to have an equal sensitivity and a higher specificity than MRa for the detection of labral pathology. MRa is better, but not statistically significantly, in demonstrating acetabular and femoral cartilage pathology.

MeSH Keywords:

Arthrography • Femoroacetabular Impingement • Hip • Magnetic Resonance Imaging • Multidetector Computed Tomography

PDF file:

<http://www.polradiol.com/abstract/index/idArt/890910>

Background

The assessment of patients with chronic and mechanical hip pain is a clinical dilemma. In these cases, hip pain can be

caused by various pathologies. Femoroacetabular impingement (FAI) is one of the causes of chronic hip pain, and it is an important factor in the development of osteoarthritis [1]. Chronic microtrauma from recurrent impingement can lead

to acetabular labral tears and breakdown of the articular cartilage, resulting in osteoarthritis as breakdown of cartilage already implies osteoarthritis. Surgical intervention may prevent later cartilage loss and development of osteoarthritis if performed before the onset of cartilage breakdown [2]. For this reason, imaging may play an important role in planning joint-preserving treatment options and thus preventing early hip osteoarthritis. Although newer MRI hardware and new MRI techniques such as 3Tesla scanners, T2 mapping, and dGEMRIC have revolutionized

the evaluation of musculoskeletal disorders of the hip, MR arthrography (MRA) is considered the best imaging modality for routine evaluation of the internal hip pathology [3–6]. The most important advantages of this method include better visualisation of the joint anatomy owing to easy differentiation of the joint surface and a higher soft tissue contrast obtained by intra-articular gadolinium dilution [7]. A number of groups have also investigated the role of non-contrast MRI in the detection of labral tears associated with FAI and acetabular dysplasia [8–11]. However, both methods have limitations in terms of spatial resolution, which can make the detection of a subtle labral and cartilage pathology challenging [12]. Advances in multidetector CT (MDCT) technology enables sub-millimeter spatial resolution and restored interest in the role of CT arthrography of the shoulder, wrist, knee, ankle and elbow [13]. There are only few studies on the use of this technique in the detection of intra-articular hip pathologies. Several studies have examined the efficiency of MDCT arthrography to assess cartilage loss in the hip and have demonstrated that its accuracy is equal to or better than the accuracy of MR arthrography [14–16]. There are only limited data regarding the efficiency of MDCT to assess labral pathology [7,11,13]. The aim of this study was to prospectively compare the MRA and CTA findings with surgical findings in patients with FAI and to investigate the superiority of these methods.

Material and Methods

Between October 2009 and February 2013, a total of 64 patients with hip symptomatology suggestive of FAI were examined with both arthrographic methods. All patients were evaluated by a hip surgeon with 19 years of experience before imaging, and arthrography was performed in patients with suspected hip impingement. Fourteen patients (eleven females and three males, age range of 19–52 years, mean 35 years) underwent surgery and were included in this study. CTA and MRA images were independently evaluated by two musculoskeletal radiologists with 10 and 20 years of experience, respectively. The reviewers were not aware that this group of patients was scheduled for arthroscopy at the time of interpretation. The study was approved by the local ethical committee and written informed consent was obtained from each patient. The intra-articular administration of gadolinium is licensed by the national drug administration. In all cases the symptoms were unilateral and thus 14 hips were finally studied. A detailed analysis of our population study is shown in Table 1.

Arthrography

Arthrography was performed under guidance of ultrasonography and fluoroscopy by a senior musculoskeletal

Table 1. Patient population study group with femoroacetabular impingement.

Patient age (years and sex) pathology/predisposing factor	Hip examined	Underlying
43/F	L	Mixed-type FAI
52/F	R	Mixed-type FAI
42/M	L	Mixed-type FAI
36/M	R	Cam-type FAI
30/F	L	Mixed-type FAI
50/F	R	Mixed-type FAI
19/F	R	Mixed-type FAI
20/F	L	Cam-type FAI
42/F	R	Mixed-type FAI
37/M	L	Mixed-type FAI
28/F	R	Mixed-type FAI/ hip dysplasia
20/F	R	Cam-type FAI
36/F	L	Cam-type FAI
22/F	L	Mixed-type FAI/ extremity shortness

radiologist with 20 years of experience. The patient was positioned supine on the fluoroscopy table, and the lower extremity was held in neutral or slight internal rotation. Standard sterile precautions were used. With an anterolateral approach, a 22-gauge needle was advanced towards the hip joint space. The intra-articular position of the needle tip was verified with 2–3 mL of contrast material. A mean volume of 13 mL (range, 10–16 mL) of standard dilute gadolinium solution was injected. The mixture was prepared as follows: 0.8 mL of gadolinium (376.9 mg of Meglumingadoterat (Dotarem/guerbet) at 1 mL) was added to 100 mL of normal saline solution. As much as 10 mL of that solution was mixed with 10 mL of iodinated contrast material (61.4 mg of Iomeprole (Iomeron 300, Bracco) at 100 mL). The solution was injected under ultrasonography guidance to obtain sufficient joint distension until resistance was met or the patient experienced discomfort. MDCT was performed after walking for about 10–15 minutes for intra-articular diffusion of the contrast and the patient was transferred to an MRI suite. MR arthrograms were obtained within 25–35 minutes after contrast material injection.

Imaging protocol

The CTA examinations were performed with a 64-row MDCT scanner (Toshiba Aquillion 64, Tokyo, Japan). The parameters for all scans were the same: pitch 1.50, 120–140 kVp, 120–130 mAs, high-resolution filter, slice

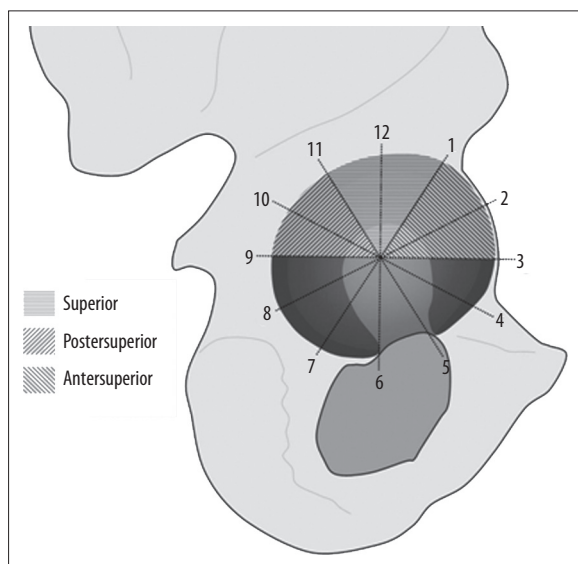


Figure 1. Diagram showing acetabular quadrants.

thickness 0.5 mm, 15-cm field of view and a 512×512 matrix. Isotropic data acquisition allowed for multiplanar reformation with 0.5-mm section thickness and 0.1-mm overlapping in the axial, coronal, sagittal, and coronal-oblique planes. All volume images (vital images) were assessed at a workstation (HP XW8200 base unit, program Vitrea).

The MRa examinations were performed with a 1.5 T scanner (Magnetom vision plus, Siemens, Germany), and a flexible wrap-around receive-only surface coil. Four image planes including axial oblique, coronal, and sagittal plane were used, according to a standard MR imaging protocol. Axial oblique imaging plane was prescribed from the coronal plane, parallel to the femoral neck. T1-weighted and fat-saturated T1-weighted MR images were obtained in axial oblique, sagittal and coronal planes with the following parameters: TR/TE 588/12, matrix size 512×512, section thickness 4–5 mm, field of view 15 cm. The routine protocol for MRa was completed with Proton/T2 fat-suppressed turbo spin-echo sequence in sagittal and coronal oblique plane: TR/TE 3000/12, matrix size 512×512, section thickness 4–5 mm, field of view 15 cm, fat-suppressed turbo spin-echo T2-w image acquisition sequence: TR/TE 4500/54, matrix size 512×512, section thickness 5–6 mm, field of view 15 cm; and an axial oblique T2*-w FLASH 2d image acquisition sequence: TR/TE 500/15, matrix size 512×512, section thickness 4–5 mm, field of view 15 cm.

Image analysis

All images were evaluated independently by two musculoskeletal radiologists with 10 and 20 years of experience, respectively. The nature of the study was prospective. Sensitivity, specificity and accuracy were determined for both MRa and CTa using surgical findings as a standard of reference. Differences in detecting labral tearing and cartilage pathology between the two imaging techniques were tested for statistical significance using a two-proportion t-test, and statistical significance was set at a p value of less than 0.05. Kappa values were calculated to quantify

the level of agreement at interobserver comparison. Kappa values were considered to indicate slight (0–0.20), fair (0.21–0.40), moderate (0.41–0.60), substantial (0.61–0.80), and excellent (0.81–1.00) agreement, according to Landis and Koch [17].

The acetabular labrum was divided into 12 regions, according to the clock quadrant for localization of labral tears (Figure 1). A route was centralized between the 3 and 9 o'clock position and the region above the route was determined as superior and the region below the route was determined as inferior. Thus, with respect to location, labral tears were classified as anterosuperior (from 1 to 3), superior (from 11 to 1) and posterosuperior (from 9 to 11). While the labral tear was defined by contrast matter transition into the labrum, acetabular and femoral cartilage defects were identified by contrast matter transition to the secondary cartilage and contrast matter stratification in there (delamination).

Only the findings of observer 2 (senior) were used for statistical analysis with regard to surgical results.

Results

Intraoperative findings in the study group are shown in Table 2. Disagreement between the two observers was recorded in two cases (14.2%) of labral tearing with MRa. Despite the above disagreement in those two patients examined with MRa, there was a complete consensus in all cases concerning the presence of a tear with CTa. Although one patient was diagnosed with labral tear with MRa by both observers, labral degeneration was observed during surgery (Figure 2). Regarding femoral cartilage loss, disagreement between observers was recorded in four cases (28.5%) with both MRa and CTa. However, disagreement was found in only one case (7%) of acetabular cartilage loss with both methods. Osseous bumps of the femoral head-neck junction were detected by surgery in eleven patients and were successfully debrided in all cases. Regarding the femoral osseous bumps, disagreement between observers was recorded in two cases (14.2%) with MRa and four cases (28.5%) with CTa. Both imaging methods offered an equal sensitivity in detecting labral tearing (Figures 3 and 4). MRa was better, but not statistically significantly, in demonstrating acetabular and femoral cartilage pathologies (Figures 5 and 6). The diagnostic ability of MRa and that of CTa are summarized in Table 3.

Inter-observer reliability value showed excellent agreement for labral tearing with CTa ($\kappa=1.0$). Inter-observer agreement was substantial to excellent with regard to acetabular cartilage assessment with MRa and CTa ($\kappa=0.76$ for MRa and $\kappa=0.86$ for CTa)

Discussion

FAI is strongly associated with increased severity of labral pathology and may play a significant role in the development of early hip osteoarthritis [18]. Cartilage damage and/or labral tear can be treated surgically at early stages and thus progression to end-stage osteoarthritis could be prevented.

Table 2. Surgical findings in patients with femoroacetabular impingement.

Patient age (years) and sex	Labral pathology	Acetabular cartilage pathology	Osteophyte	Bump	Femoral cartilage pathology	Labral tear location
43/F	None	None	None	Present	None	–
52/F	None	None	Present	Present	None	–
42/M	None	None	Present	Present	Present	–
36/M	Present	Present	None	Present	None	Anterosuperior Superior
30/F	Present	None	Present	None	None	Anterosuperior
50/F	Present	Present	Present	None	None	Anterosuperior
19/F	Present	Present	Present	Present	Present	Anterosuperior Posterosuperior
20/F	Present	Present	None	Present	Present	Anterosuperior
42/F	No	None	None	None	None	–
37/M	Present	Present	None	Present	None	Anterosuperior
28/F	Present	Present	Present	Present	Present	Anterosuperior Superior Posterosuperior
20/F	Present	Present	None	Present	None	Anterosuperior Superior
36/F	Present	Present	None	Present	None	Anterosuperior
22/F	Present	Present	None	Present	None	Anterosuperior Superior

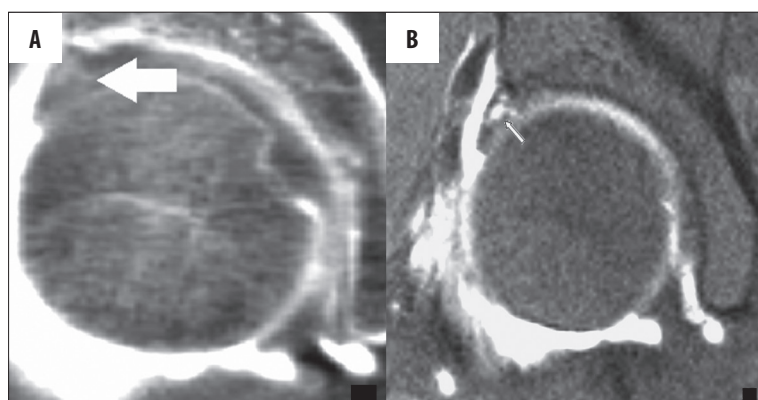


Figure 2. A 42-year-old female with pain in the right hip and surgically proven labral degeneration. The coronal CTa image (A) demonstrates a thickened labrum (arrow) but with no signs of a tear. The corresponding coronal T1-w fat-saturated MRa image (B) shows deformed labrum with evidence of contrast medium extension (arrow). Based on MRa, both observers considered the findings as a labral tear which was not verified surgically.

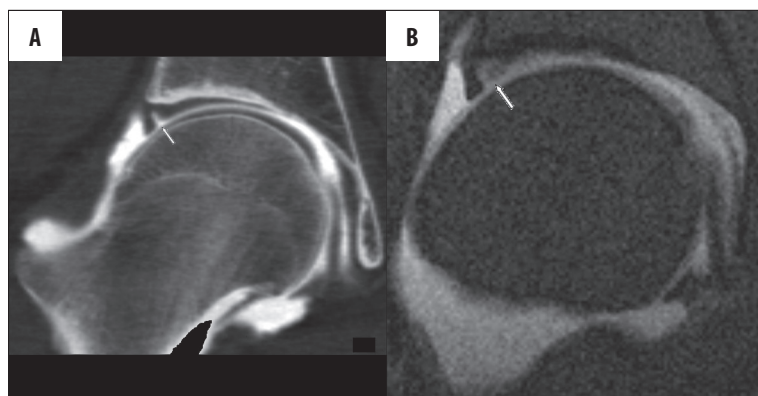


Figure 3. Cam-type FAI and labral tear in a 36-year-old male with a 4-month history of pain in the right hip. Both coronal reconstruction (A) and corresponding T1-w fat saturated MRa (B) show contrast extension into the anterosuperior labrum compatible with a tear (arrows).

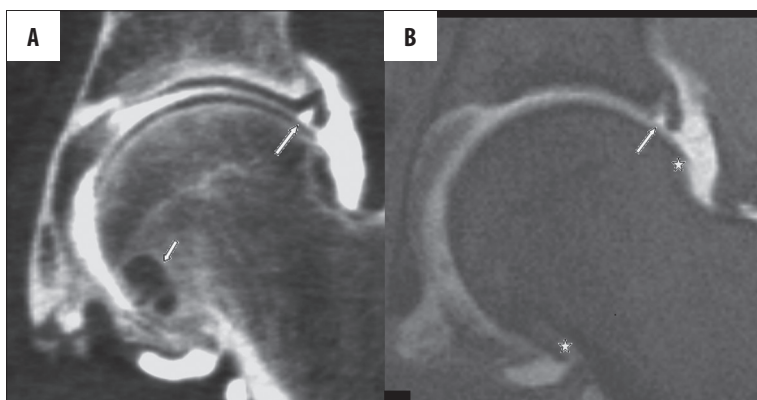


Figure 4. Mixed-type FAI and labral tear in a 30-year-old female with a 2-month history of right left pain. Both T1-w fat saturated MRa (A) and corresponding coronal reconstruction CTa (B) images show contrast extension into the anterosuperior labrum compatible with a tear (long arrows). An area of subchondral bone cyst is seen on the medial femoral head on CTa (short arrow). MRa image also reveals pericapital osteophytes in the femoral head (stars).

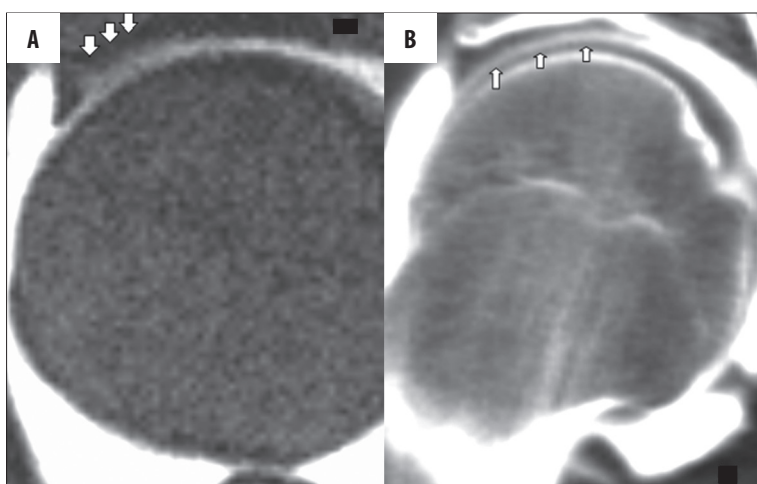


Figure 5. A 20-year-old female with right hip pain that increases with movement. Acetabular cartilage loss (arrow) is well demonstrated on MRa (A) but not on CTa (B). Of note is how clearly the femoral cartilage is demonstrated with CTa (arrows).

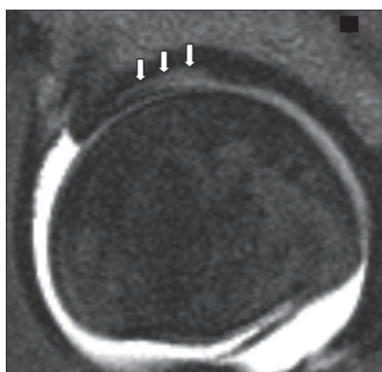


Figure 6. A 28-year-old female with a 2-month history of left hip pain. Coronal T2-w fat-suppressed MRa image clearly shows acetabular cartilage loss (arrows).

The most important role of imaging in the preoperative period is to reveal labrocartilaginous lesions in patients with FAI [19]. During the past decade there have been numerous studies that focused on the use of MRI, including both non-contrast and direct arthrographic methods, to identify intra-articular hip pathologies [8,9]. As previously reported, MRI has a good ability to detect labral and chondral pathologies in FAI [8]. Many studies have also concluded that direct MRa is an excellent method for the detection of labral pathologies [3,20]. However, it has been also emphasized that small labral tears can be overlooked due to the limited spatial resolution of MRI [21,22]. In a study carried out by Keeney et al., it was concluded that in spite of the fact that MRI arthrography has limited diagnostic potential, it is an excellent positive predictor of labral pathologies [23]. Higher field strength magnets (3T), which are commonly employed in routine practice, allow for higher spatial resolution in the same time period or faster

Table 3. Sensitivity, appecificity, and accuracy in detecting labral tears and cartilage loss on MRa and CTa.

Statistical parameter	Labral tearing		Acetabular cartilage pathology		Femoral cartilage pathology	
	MRa	CTa	MRa	CTa	MRa	CTa
Sensitivity (%)	100	100	89	56	100	75
Specificity (%)	50*	100*	40	60	90	70
Accuracy (%)	86	100	71	71	86	71

* Specificity of CTa was significantly higher than of MRa (p<0.05).

acquisition with identical spatial resolution. Therefore, they are associated with greater sensitivity and specificity for detection of labral tears and evaluation of articular cartilage [24–26]. Slice thickness is 3–4 mm in the majority of published protocols for MRa of the hip, with FOV between 14–18 cm, focusing on the symptomatic hip. Fat saturated T1- and T2-weighted images are the most useful for assessing acetabular labrum lesions. The 3D isotropic sequences which have increasingly become common practice in routine clinical settings, thanks to higher field strength magnets allow for multiplanar reconstruction, which can help in the detection of acetabular labrum lesions [27–29].

In the literature there is a relatively small number of studies investigating the use of CTa in the evaluation of intra-articular hip pathologies [7,13–15]. CTa of the hip is not a new technique but improved resolution of MDCT has made it a feasible alternative to MRI. Christie-Large et al. have recently investigated the role of MDCT arthrography in the evaluation of suspected intra-articular hip pathologies in 96 patients. They compared imaging findings with those of arthroscopy and open surgery in approximately 30% of patients. Excellent correlation was seen: the sensitivity and specificity of CTa for the detection of labral tearing, acetabular cartilage loss and femoral cartilage loss was found to be 90/100, 88/100 and 94/100, respectively [13]. Although MDCT arthrography with radial reconstructions has been shown to be useful for the evaluation of labral injuries in patients with contraindications for MRI, its sensitivity is lower than that reported in similar MR investigations [30]. In the current study, we aimed to determine the diagnostic accuracy of CTa and MRa in comparison to intraoperative findings in patients with FAI. To our knowledge, only one study had been previously published in patients. Perdidakis compared MRa and CTa within the detection of surgically proven labral tears and articular cartilage degradation and concluded that interobserver reproducibility was better with MRa for assessing labral tears [7]. In the current study, perhaps the most encouraging finding with CTa was the excellent interobserver reproducibility regarding labral tearing. Although there was no difference in sensitivity between CTa and MRa, CTa proved to have greater specificity than MRa in assessing labral tears.

The success rate of surgery mostly depends on knowing the exact location of labral tears. CTa has the advantage of demonstrating the exact location of a tear by means of its multiplanar imaging capabilities [23]. A study conducted by Blankenbaker DG et al. in which labral tear was localized on MRa by using a clock-face description found that labral tear was located in the 1 o'clock position in 85% of patients [31]. Similarly, our study showed that labral tears were more frequently found in the anterosuperior quadrant. According to intraoperative findings, CTa proved to be better in determining the exact location of tears compared to MRa. This can be explained by the inherent superior spatial resolution of MDCT.

Some recent studies have suggested that MDCT arthrography has a sensitivity equal to or better than that of MR arthrography for the demonstration of articular cartilage

loss in the hip, a finding that could be explained by the inherent superior spatial resolution of MDCT [11,14,16]. MDCT also allows for high-resolution multiplanar reformatted images to be obtained, which allows for accurate assessment of both femoral and acetabular cartilage [11,14,15]. However, when considering the increasing popularity of new hip-preserving surgical techniques, assessing biochemical properties of cartilage before structural breakdown becomes evident is gaining on importance. Cartilage mapping techniques such as delayed gadolinium-enhanced MR imaging of cartilage (dGEMRIC), T2 mapping and T1ρ mapping seem to be well-suited for early detection of preclinical cartilage damage [24]. In our series, although CTa was inferior to MRa in the demonstration of the acetabular cartilage, it was found to be equivalent to MRa in the detection of femoral cartilage loss. We also demonstrated an excellent correlation between observers regarding femoral cartilage assessment with CTa.

In the current study, CTa proved to be better at evaluating concomitant degenerative bone changes compared to MRa. A study conducted by Schmid MR et al. concluded that when concomitant degenerative bone changes are found in MRa images, the labral tears may be overestimated [12]. Moreover, we correctly diagnosed labral tears by using CTa in three cases with degenerative bone changes.

Our study had limitations. First, our sample size was small, but arthroscopic comparison was performed in all cases. Second, there was no control group; nevertheless, it can be argued that it would be unethical to perform invasive procedures such as MRa and CTa in healthy volunteers. The limited number of patients with arthroscopic correlation makes it difficult to draw conclusions on the sensitivity and specificity of CTa in this study. Therefore, a higher number of prospective studies correlated with operative findings are needed to assess the advantages and drawbacks of this method. In this study, we used an old-fashioned 1.5 T MRI scanner which did not allow for fast scanning. When considering the influence of slice thickness on acquisition time we used slice thickness of 4–6 mm rather than standard 3–4 mm to reduce scanning time. Besides, the lack of available software package did not allow us to carry out high-quality 3D imaging. These issues related our MRa imaging protocol might have skewed the balance in favour of MDCT. Finally, CT imparts radiation on the pelvis, with the patient cohort included in this study being mostly young female patients.

Conclusions

In conclusion, our study supported arguments for the popular use of MRa as the imaging method of choice in determining intrarticular hip pathologies. However, CTa seems to have similar sensitivity and higher specificity than MRa in detecting labral pathologies and a similar ability to assess acetabular and femoral cartilage. Because of its faster image acquisition, patient-based artifacts such as patient movement are less commonly observed with CTa. Finally, MDCT arthrography might be used as an alternative in patients with FAI for whom MRI is contraindicated.

References:

1. Cheryl A: Petersilge: Chronic Adult Hip Pain: MR Arthrography of the Hip. *Radiographics*, 2000; 20: 43-52
2. Ganz R, Leung M, Leunig-Ganz K et al: The Etiology of Osteoarthritis of the Hip, An Integrated Mechanical Concept. *Clin Orthop Relat Res*, 2008; 2: 264-71
3. Toomayan GA, Holman WR, Major NM et al: Sensitivity of MR arthrography in the evaluation of acetabular labral tears. *Am J Roentgenol*, 2006; 186: 449-53
4. Jessel RH, Zilkens C, Tiderius C: Assessment of osteoarthritis in hips with femoroacetabular impingement using delayed gadolinium enhanced MRI of cartilage. *J Magn Reson Imaging*, 2009; 30: 1110-15
5. Bittersohl B, Hosalkar HS, Hughes T et al: Feasibility of T2* mapping for the evaluation of hip joint cartilage at 1.5T using a three-dimensional (3D), gradient-echo (GRE) sequence: a prospective study. *Magn Reson Med*, 2009; 62: 896-901
6. Bittersohl B, Hosalkar HS, Werlen S et al: Intravenous versus intra-articular delayed gadolinium-enhanced magnetic resonance imaging in the hip joint: a comparative analysis. *Invest Radiol*, 2010; 45: 538-42
7. Perdikakis E, Karachalios T, Katonis P et al: Comparison of MR-arthrography and MDCT-arthrography for detection of labral and articular cartilage hip pathology. *Skeletal Radiol*, 2011; 40: 1441-47
8. James SLJ, Ali K, Malara F et al: MRI findings of femoroacetabular impingement. *Am J Roentgenol*, 2006; 187: 1412-19
9. James SLJ, Miocevic M, Malara F et al: MR imaging findings of acetabular dysplasia in adults. *Skeletal Radiol*, 2006; 35: 378-84
10. Mintz DN, Hooper T, Connell D et al: Magnetic resonance imaging of the hip: detection of labral and chondral abnormalities using non contrast imaging. *Arthroscopy*, 2005; 21: 385-93
11. Nishii T, Tanaka H, Sugano N et al: Disorders of the acetabular labrum and articular cartilage in hip dysplasia: evaluation using isotropic high-resolution CT arthrography with sequential radial reformation. *Osteoarthritis Cartilage*, 2007; 15: 251-57
12. Schmid MR, Notzli HP, Zanetti M et al: Cartilage lesions in the hip: diagnostic effectiveness of MR arthrography. *Radiology*, 2003; 226: 382-86
13. Christie-Large M, Tapp MJ, Theivendran K et al: The role of multidetector CT arthrography in the investigation of suspected intra-articular hip pathology. *BrJ Radiol*, 2010; 83: 861-67
14. Wyler A, Bousson V, Bergot C et al: Comparison of MR arthrography and CT arthrography in hyaline cartilage thickness measurement in radiographically normal cadaver hips with anatomy as gold standard. *Osteoarthritis Cartilage*, 2009; 17: 19-25
15. Wyler A, Bousson V, Bergot C et al: Hyaline cartilage thickness in radiographically normal cadaveric hips: comparison of spiral CT arthrographic and macroscopic measurements. *Radiology*, 2007; 242: 441-49
16. Nishii T, Tanaka H, Nakanishi K et al: Fat-suppressed 3D spoiled gradient-echo MRI and MDCT arthrography of articular cartilage in patients with hip dysplasia. *Am J Roentgenol*, 2005; 185: 379-85
17. Landis JR, Koch GG: The measurement of observer agreement for categorical data. *Biometrics*, 1977; 33: 159-74
18. Pfirrmann CW, Megiardi B, Dora C et al: Cam and pincer femoroacetabular impingement: characteristic MR arthrographic findings in 50 patients. *Radiology*, 2006; 240: 778-85
19. Tanzer M, Noiseux N: Osseous abnormalities and early osteoarthritis: the role of hip impingement. *Clin Orthop Relat Res*, 2004; 429: 170-77
20. Czerny C, Hofmann S, Neuhold A et al: Lesions of the acetabular labrum: accuracy of MR imaging and MR arthrography in detection and staging. *Radiology*, 1996; 200: 225-30
21. Chan YS, Lien LC, Hsu HL et al: Evaluating hip labral tears using magnetic resonance arthrography: a prospective study comparing hip arthroscopy and magnetic resonance arthrography diagnosis. *Arthroscopy*, 2005; 21: 1250
22. Yoon LS, Palmer WE, Kassarian A: Evaluation of radial sequence imaging in detecting acetabular labral tears at hip MR arthrography. *Skeletal Radiol*, 2007; 36: 1029-33
23. Keeney JA, Peelle MW, Jackson J et al: Magnetic resonance arthrography versus arthroscopy in the evaluation of articular hip pathology. *Clin Orthop Relat Res*, 2004; 429: 163-69
24. Guglielmi G, Biccari N, Mangano F et al: 3 T magnetic resonance imaging of the musculoskeletal system. *Radiol Med*, 2010; 115: 571-84
25. Niitsu M, Nakai T, Ikeda K et al: High-resolution MR imaging of the knee at 3 T. *Acta Radiol*, 2000; 41: 84-88
26. Ramnath RR: 3T MR imaging of the musculoskeletal system (Part II): clinical applications. *Magn Reson Imaging Clin*, 2006; 14: 41-62
27. Sutter R, Zanetti M, Pfirrmann CW: New developments in hip imaging. *Radiology*, 2012; 264: 651-67
28. Lazarus ML: Imaging of femoroacetabular impingement and acetabular labral tears of the hip. *Dis Mon*, 2012; 58: 495-542
29. Plotz GM, Brossmann J, von Knoch M et al: Magnetic resonance arthrography of the acetabular labrum: value of radial reconstructions. *Arch Orthop Trauma Surg*, 2001; 121(8): 450-57
30. Yamamoto Y, Tonotsuka H, Ueda T et al: Usefulness of radial contrast-enhanced computed tomography for the diagnosis of acetabular labrum injury. *Arthroscopy*, 2007; 23: 1290-94
31. Blankenbaker DG, De Smet AA, Keene JS et al: Classification and localization of acetabular labral tears. *Skeletal Radiol*, 2007; 36: 391-97