

Contents lists available at [ScienceDirect](http://www.sciencedirect.com)

International Journal of Surgery Case Reports

journal homepage: www.casereports.com

A case of endometriosis causing acute large bowel obstruction

Zexi Allan

Department of General Surgery, Box Hill Hospital, 8 Arnold Street, Victoria, 3128, Australia



ARTICLE INFO

Article history:

Received 5 December 2017

Accepted 16 December 2017

Available online 27 December 2017

Keywords:

Colonic obstruction

Endometriosis

ABSTRACT

INTRODUCTION: Endometriosis is a gynaecological condition which produce symptoms such as pelvic pain, abnormal menstruation and infertility. Intestinal endometriosis can occur however endometriosis causing acute large bowel obstruction is extremely rare.

PRESENTATION OF CASE: We present a 37-year-old lady with acute large bowel obstruction caused by endometriosis. Despite initial endoscopic decompression being unsuccessful due to severe mucosal stenosis, she underwent emergency laparoscopic wedge resection and decompression successfully.

DISCUSSION: Diagnosing intestinal endometriosis is difficult. While different modalities of investigation help, definitive diagnosis is achieved via laparoscopy. Treatment of obstruction is decompression followed by surgical resection.

CONCLUSION: Diagnosing intestinal endometriosis with or without obstruction is challenging. Correct diagnosis is needed for definitive management.

© 2017 The Author(s). Published by Elsevier Ltd on behalf of IJS Publishing Group Ltd. This is an open access article under the CC BY-NC-ND license (<http://creativecommons.org/licenses/by-nc-nd/4.0/>).

1. Introduction

Endometriosis is a gynaecological condition where functional endometrial tissue is found outside of the uterus [1]. Endometriosis is found in 6–10% of women in reproductive age and about 50% women will have pelvic pain, abnormal menstruation and infertility associated with it [2]. Common sites include pelvic peritoneum, ovaries and rectovaginal septum. Rarely it involves the pleura, pericardium, small and large intestines, diaphragm and other tissues [2].

Intestinal endometriosis is the most common extra-pelvic site and it is found in 12% of women with endometriosis [3]. Rectosigmoid being the most common site contributes to 72% of intestinal endometriosis [4]. Despite this, endometriosis causing intestinal obstruction is extremely rare with reported incidence between 0.1–0.7% [5]. This work has been reported in line with the SCARE criteria [6].

2. Case

A 37-year-old lady was referred via Emergency department to the Colorectal Unit by a gynaecologist with likely acute large bowel obstruction (LBO). Her last normal bowel motion was five days prior and a small bowel motion with Microlax enema two days prior. She had stopped passing flatus for one day. She denied nausea or vomiting and complained of abdominal pain and bloating. On examination, she was hemodynamically stable with a soft dis-

tended abdomen and generalised mild tenderness with no guarding or rebound tenderness. Per-rectal exam showed an empty rectum with no mass. She has a past medical history of endometriosis, coeliac disease and depression. She was taking Synarel spray for in vitro fertilisation (IVF) treatment at the time. At time of this presentation, her external computed tomography (CT) scan of the abdomen and pelvis one day prior had confirmed a distal LBO. Abdominal x-ray again showed dilated colon loops all the way to rectosigmoid (Fig. 1).

Seven months prior to her presentation, she had pelvic ultrasound showing scattered pelvic endometriosis and an infiltrative rectosigmoid nodule of endometriosis measuring 26 × 15 × 20 mm, located 16 cm from the anal verge. The lesion affected 50% of the rectal wall circumference. Subsequent laparoscopy and endometriosis resection by the gynaecologist showed an immobile segment of the rectosigmoid endometriosis at pouch of Douglas and decision was made for observation only and planned segmental resection later.

Given the history and investigation findings, a flexible sigmoidoscopy was organised to decompress the obstruction however it revealed a prolapsed and completely obstructed mucosal lumen (Fig. 2). The endoscope could not be advanced beyond the obstruction. Patient then underwent emergency laparoscopic wedge resection of rectosigmoid tumour with primary anastomosis and endoscopic decompression. Intra-operatively, it revealed a circumferential stricturing lesion at the rectosigmoid (Fig. 3). Patient recovered well post-operatively and was discharged Day 5 of admission. Histopathology confirmed sigmoid endometriosis with thickened muscularis propria containing multifocal deposits of proliferative endometrial type glands and stroma. Foci of

E-mail address: zcx.1989@hotmail.com

<https://doi.org/10.1016/j.ijscr.2017.12.031>

2210-2612/© 2017 The Author(s). Published by Elsevier Ltd on behalf of IJS Publishing Group Ltd. This is an open access article under the CC BY-NC-ND license (<http://creativecommons.org/licenses/by-nc-nd/4.0/>).

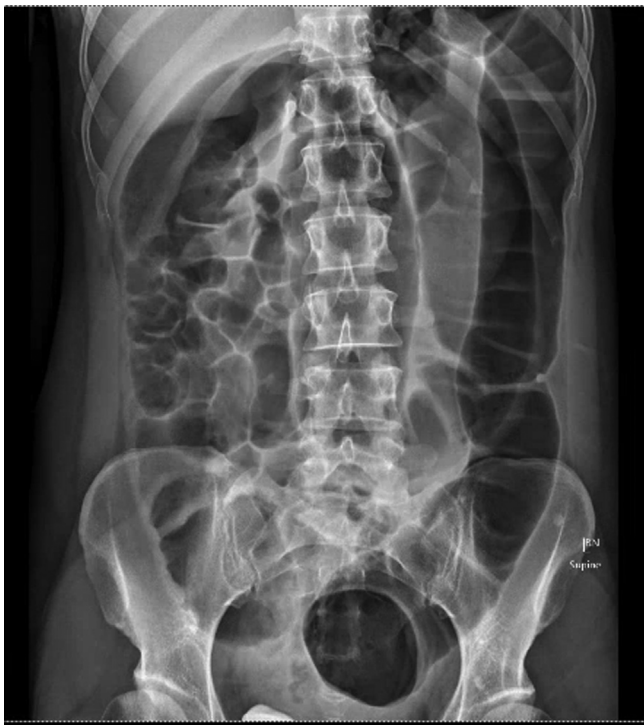

Fig. 1. Abdominal x-ray showing very dilated colon down to the rectosigmoid junction.

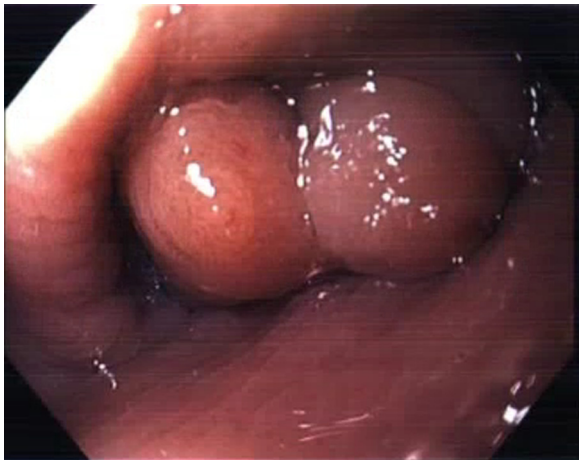


Fig. 2. Endoscopic view of the obstructed mucosal lumen.

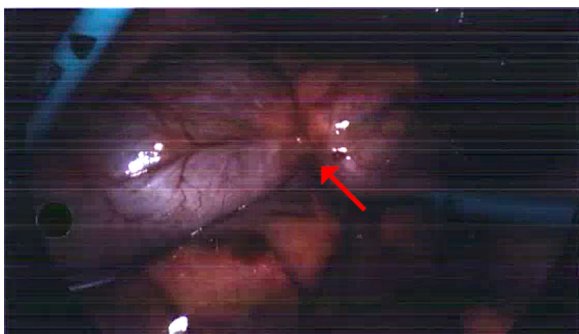


Fig. 3. Laparoscopic view of the rectosigmoid colon, with arrow showing the stricture lesion.

endometriosis were also noted within the pericolic adipose tissue. There was no evidence of neoplasia.

3. Discussion

The pathogenesis of endometriosis is not entirely known. Although theory points towards retrograde menstruation, not all women who have retrograde menstruation will develop endometriosis [2]. Other theories include vascular dissemination, colonic metaplasia and autoimmune disease [5]. Ectopic endometriosis behaves very much like uterine endometrial tissue and respond to ovarian hormones. It can implant and proliferate and form cysts or nodule (endometrioma) [7]. At distant sites, endometriosis can cause bleeding, pain, scarring and fibrosis [5].

Intestinal endometriosis often presents in the submucosal layer and involves the muscularis propria and subserosa or mesentery [5]. It rarely implants at the mucosal layer of the bowel and if it's in the sigmoid or rectum, patients can have catamenial rectal bleeding or dyschezia. Penetration of endometriosis into the intestinal lumen is found in 4.8% of patients with intestinal endometriosis according to one study [8]. Most patients with intestinal endometriosis can be asymptomatic. At times, small bowel endometriosis causes non-specific symptoms such as abdominal pain, bloating, nausea, vomiting, diarrhoea and constipation; however those symptoms are often cyclic [2,7]. Rarely, endometriosis proliferates, evolves and causes fibrosis and stricture of the intestine and thus causing bowel obstruction [3–5].

Diagnosis of intestinal endometriosis can be challenging as gastrointestinal symptoms can be non-specific and large lesions can lead to acute obstruction mimicking adenocarcinoma of the colon [9]. Pelvic or abdominal CT scan may reveal thickened bowel wall with narrowed lumen. Transvaginal ultrasonography (US) and pelvic magnetic resonance imaging (MRI) are better used in evaluating endometriomas however they perform poorly in characterising deposits and adhesions [2]. Intestinal endometriosis are typically found in the serosa and muscularis layer, sparing the mucosa [5,7]. Endoscopic evaluation generally does not show any pathology unless lesions are near obstructing such as in our patient. Biopsies of the mucosa will often be normal. The gold standard diagnosis is laparoscopy and biopsy, which allows a full assessment of the pelvis as well as surgical resection if required [9].

Empirical medical therapy can be started for dysmenorrhoea and pelvic pain in women with suspected endometriosis. First line therapy of nonsteroidal anti-inflammatory drugs (NSAIDs) together with combined oral contraceptives used cyclically or continuously are proven to be effective in reducing symptoms as well as the size of ovarian endometriomas [10,11]. Other options include gonadotropin releasing hormone (GnRH) agonist and aromatase inhibitors [2,7]. These medications work by mechanisms minimising inflammation, suppressing or interrupting ovarian hormone production resulting in a hypoestrogenic state, endometrial atrophy and sometimes oligomenorrhoea or amenorrhoea [2]. In our case patient was receiving IVF treatment and was on Synarel spray which is a GnRH agonist. Surgical options include excision, laser ablation, fulguration of endometriosis and adhesiolysis and those can be offered as a first line or post failed medical therapy. Treatment of intestinal endometriosis depends on the clinical presentation and severity. For small deposits, patients can be offered medical therapy first and elective resection to be arranged later. For large lesions causing impending obstruction, resection of the affected bowel is needed.

In acute colonic obstruction by endometriosis, it is important to confirm the underlying etiology as colonic malignancy will produce the same set of symptoms and requiring different surgical management. In our patient, diagnosis of colonic endometriosis has been

confirmed via prior investigations and laparoscopy. Treatment priority is in relieving the obstruction. Endoscopic decompression and colonic stenting have been reported in treating acute colonic obstruction from endometriosis with planned resection at a later stage [12,13]. This will avoid emergency operation which carries a higher mortality rate, longer hospital stays and higher rates of stoma formation [13]. Surgical resection is required as definitive treatment of colonic obstruction. Post operatively, recurrence rate is directly related to the completeness of resection [14]. In our case, endoscopic decompression was unsuccessful due to the severity of stenosis and obstruction of the colonic lumen; thus an emergency operation and resection was performed.

4. Conclusion

Endometriosis causing acute LBO is extremely rare and poses diagnostic challenge as it can easily be mistaken as malignant LBO. Definitive diagnosis is required and can be obtained with detailed history, examination, imaging modalities, endoscopic evaluation and laparoscopy. Treatment should be acute decompression followed by definitive surgical resection.

Conflicts of interest

Nothing to declare.

Funding

Non applicable.

Ethical approval

Ethical approval has been exempted by our institution.

Consent

Written informed consent has been obtained.

Author contribution

The author has contributed solely to all aspects of the paper.

Registration of research studies

Non applicable.

Guarantor

Zexi Allan.

References

- [1] M. Montalto, L. Santoro, F. D'Onofrio, A. Gallo, S. Campo, V. Campo, et al., Endometriosis, need for a multidisciplinary clinical setting: the internist's point of view, *Intern. Emerg. Med.* 5 (6) (2010) 463–467.
- [2] L.C. Giudice, Clinical practice. Endometriosis, *N. Engl. J. Med.* 362 (25) (2010) 2389–2398.
- [3] C.H. Macafee, H.L. Greer, Intestinal endometriosis. A report of 29 cases and a survey of the literature, *J. Obstet. Gynaecol. Br. Emp.* 196067 (2016) 539–555.
- [4] P.A. Ribeiro, F.C. Rodrigues, I.P. Kehdi, L. Rossini, H.S. Abdalla, N. Donadio, et al., Laparoscopic resection of intestinal endometriosis: a 5-year experience, *J. Minim. Invasive Gynecol.* 13 (5) (2006) 442–446.
- [5] N. Katsikogiannis, A. Tsaroucha, K. Dimakis, E. Sivridis, C. Simopoulos, Rectal endometriosis causing colonic obstruction and concurrent endometriosis of the appendix: a case report, *J. Med. Case Rep.* 5 (2011) 320.
- [6] R.A. Agha, A.J. Fowler, A. Saeta, I. Barai, S. Rajmohan, D.P. Orgill, et al., The SCARE statement: consensus-based surgical case report guidelines, *Int. J. Surg.* 34 (2016) 180–186.
- [7] A. Al-Talib, T. Tulandi, Intestinal endometriosis, *Gynaecol. Surg.* 7 (2010) 61–62.
- [8] H.S. Ribeiro, P.A. Ribeiro, L. Rossini, F.C. Rodrigues, N. Donadio, T. Aoki, Double-contrast barium enema and transrectal endoscopic ultrasonography in the diagnosis of intestinal deeply infiltrating endometriosis, *J. Minim. Invasive Gynecol.* 15 (3) (2008) 315–320.
- [9] M.G. Pramateftakis, S. Psomas, D. Kanellos, G. Vrakas, G. Roidos, A. Makrantonakis, et al., Large bowel obstruction due to endometriosis, *Tech. Coloproctol.* 14 (Suppl. 1) (2010) S87–9.
- [10] T. Harada, M. Momoeda, Y. Taketani, H. Hoshiai, N. Terakawa, Low-dose oral contraceptive pill for dysmenorrhea associated with endometriosis: a placebo-controlled, double-blind, randomized trial, *Fertil. Steril.* 90 (5) (2008) 1583–1588.
- [11] P. Vercellini, G. Frontino, O. De Giorgi, G. Pietropaolo, R. Pasin, P.G. Crosignani, Continuous use of an oral contraceptive for endometriosis-associated recurrent dysmenorrhea that does not respond to a cyclic pill regimen, *Fertil. Steril.* 80 (3) (2003) 560–563.
- [12] E.S. Miller, R.M. Barnett, R.B. Williams, Sigmoid endometriotic stricture treated with endoscopic balloon dilatation: case report and literature review, *Md. Med. J.* 39 (12) (1990) 1081–1084.
- [13] C. Whelton, A. Bhowmick, Acute endometrial bowel obstruction—a rare indication for colonic stenting, *Int. J. Surg. Case Rep.* 4 (2) (2013) 160–163.
- [14] S. Arafat, M.B. Alsabek, F. Almousa, M.A. Kubtan, Rare manifestation of endometriosis causing complete recto-sigmoid obstruction: a case report, *Int. J. Surg. Case Rep.* 26 (2016) 30–33.

Open Access

This article is published Open Access at [sciencedirect.com](https://www.sciencedirect.com). It is distributed under the [IJSCR Supplemental terms and conditions](#), which permits unrestricted non commercial use, distribution, and reproduction in any medium, provided the original authors and source are credited.