

## ELASTIC STABLE INTRAMEDULLARY NAILING FOR FRACTURES IN CHILDREN – SPECIFIC APPLICATIONS

DAN COSMA, DANA ELENA VASILESCU

Department of Pediatric Surgery and Orthopedics, Iuliu Hatieganu University of Medicine and Pharmacy, Cluj-Napoca, Romania

### *Abstract*

*Elastic stable intramedullary nailing (ESIN) is a new minimally invasive technique for the treatment of pediatric fractures. It approximates the physiological healing process of bone, without opening the fracture site. Also, the operative stress is minimal because of the minimally invasive nature of the procedure, and the volume of implants is small, offering a very good stability without plaster cast immobilization.*

**Keywords:** fracture, children, elastic nailing, femur, tibia, humerus, radius

### **Femoral fractures**

The indications of ESIN in femoral fractures are: age between 4 and 14 years and femoral fractures within multiple trauma [1].

### *Positioning*

The patient is positioned on the orthopedic traction table, and the size of the boot is adapted to the size of the child's leg. The fluoroscope is required for obtaining antero-posterior (AP) and latero-lateral (LL) views of the affected thigh and is placed so as to allow the visualization of the femur from hip to knee level. The obtaining of reduction is checked in both the AP and LL views, and rotation is also verified [2].

### *Choice of the nails*

The nail diameter should observe the general rule for choosing the nails. The following classification may be used as an alternative variant, which is correlated with the child's age:

- 6-8 years: 3 mm diameter;
- 9-11 years: 3.5 mm diameter;
- 12-14 years: 4 mm diameter.

The length of the nails is equal to the distance from the distal growth cartilage to the greater trochanter growth cartilage [3].

### *Diaphyseal fractures*

#### *The proximal and middle third*

In the case of diaphyseal fractures in the proximal and middle third, the C-shaped approach, with the nails inserted retrograde through the distal metaphysis, is chosen. In the case of proximal fractures, the proximal tip of the nails is bent, while for mid-diaphyseal fractures, the middle of the nail is curved. At the end of the operation, in the case of transverse fractures, the fragments are impacted in order to avoid residual distraction, which can be responsible for the unequal length of the lower limbs. In the case of oblique or comminuted fractures, the distal tip is bent and impacted into the bone to avoid the telescoping of the fragments and the migration of the nails.

The natural tendency of these fractures is to induce a 5-10 mm shortening immediately postoperatively, which will be compensated by the stimulation of growth during the consolidation of the fracture [4].

### *Distal fractures*

In the case of distal fractures, stabilization is more difficult and several approaches are possible [5-7]:

1. retrograde C-shaped approach, with the convex side of both nails at the level of the fracture. The unbent nails are inserted into the medullary canal, and when the distance to the fracture site is equal to the length of the nails outside the bone, their bending is performed;

2. retrograde C-shaped approach, in which the nails are crossed proximally to the fracture site;

Manuscript received: 29.04.2014

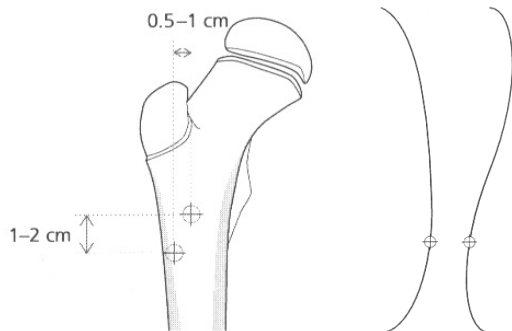
Received in revised form: 19.06.2014

Accepted: 30.06.2014

Address for correspondence: drvasilescu@yahoo.com

3. antegrade approach with C- and S-shaped nails. The entry point is at subtrochanteric level and both nails are inserted so that their distal tips are divergent in the two femoral condyles (Figure 1);

4. combined antegrade and retrograde approach.

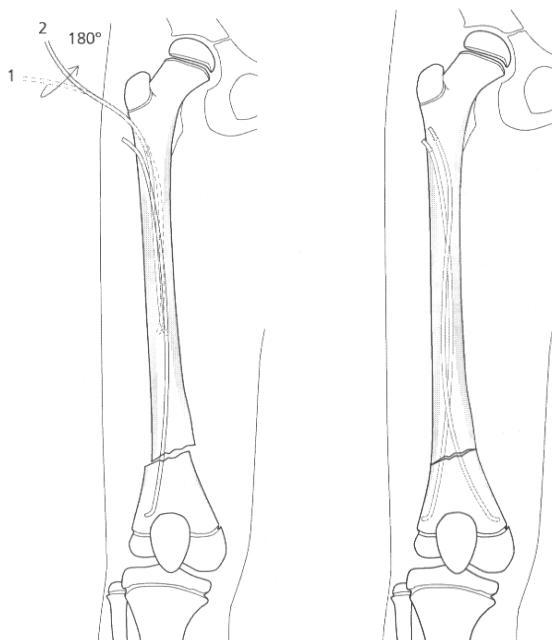


**Figure 1.** Choice of entry points and shaping of the nails with the antegrade technique

*Metaphyseal fractures*

Femoral neck fractures do not have an indication for ESIN because of the high density of the trabecular bone in the proximal femoral metaphysis, which makes the advancement and insertion of elastic nails difficult [5-7].

Distal metaphyseal fractures can be stabilized using elastic nails inserted with the antegrade technique (Figure 2) [2-4].



**Figure 2.** Antegrade ESIN technique in distal femoral fractures

*Postoperative management*

A compression bandage is maintained for several days, while rehabilitation through isometric quadriceps contractions is initiated. After several days, the active mobilization of the lower limb, with partial weight bearing using crutches, is allowed.

After the resumption of walking, the child is discharged, and walking with full weight bearing on the lower limb is allowed after 6 weeks.

Physical therapy should be focused on the quadriceps muscle, knee extension and flexion. In some situations, knee flexion can be limited due to the prominence of the distal tip of the nails. The fracture is completely consolidated after 4 months and the ablation of implants can be scheduled during the holidays. At this point, knee flexion is completely recovered.

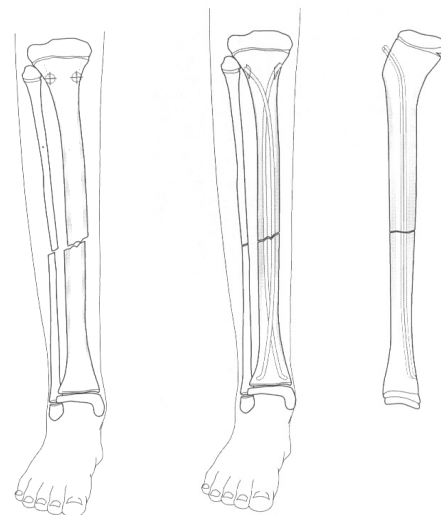
**Tibial fractures**

*Positioning and preparation of the patient*

The patient is positioned on the orthopedic table in order to facilitate reduction. The presence of the fluoroscope is mandatory for intraoperative control. The operative field must include the knee [2].

*Insertion of the nails*

The elastic nails are always inserted antegrade into the proximal metaphysis, at antero-lateral and antero-medial locations (Figure 3) [3,8].



**Figure 3.** Elastic nailing in tibial fractures (antegrade technique)

The nail diameter varies between 2.5 and 4 mm, depending on the patient's age. The use of the hammer for advancing the nails is allowed but should be used with caution.

The quality of the reduction is ensured by the nail diameter and the degree of bending.

The nails should not be impacted into the cancellous bone of the distal metaphysis before reduction is perfect; otherwise, correction procedures may destabilize osteosynthesis.

Before impaction, the rotation of fragments is checked and, in the case of the presence of residual varus deformity, this is corrected by the excessive bending of a nail. At the end of the operation, traction is relaxed and the fragments are impacted.

In the case of comminuted fractures, the proximal tips of the nails that are left outside the bone are bent at 90° and impacted into the cortical bone to prevent the telescoping of fragments.

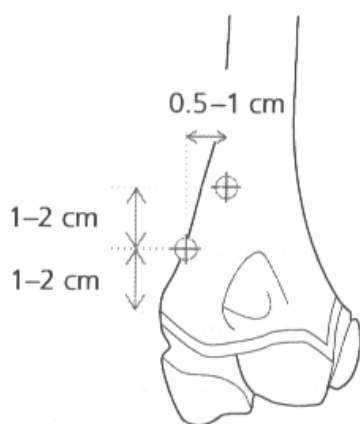
### Humeral fractures

The indications of ESIN in humeral fractures vary depending on the fracture site: the proximal metaphysis or the diaphysis. In the fractures of the surgical neck of the humerus, ESIN is indicated because it reduces the period of immobilization required in the case of conservative treatment [6,9-12].

In the case of diaphyseal fractures, the use of elastic nails is indicated regardless the presence radial nerve lesions.

#### *Insertion of the nails*

The nails are inserted using the retrograde method. The insertion points are found on the lateral margin of the supracondylar area, having a postero-lateral direction and proximal inclination (Figure 4). The entry points are prepared using a drill because the cortical bone in this area is very hard. The diameter of the nails varies between 2.5 and 3.5 mm, and they are bent identically. The nails are inserted by vertical manual pressure and rotating movements. If the fracture in the proximal metaphyseal area cannot be adequately reduced, the 180° rotation of the nails facilitates this reduction. If, however, reduction is impossible, a Kirschner guide-wire is placed in the



**Figure 4.** Elastic nailing in humeral fractures (retrograde technique)

proximal fragment before open reduction. In the case of oblique diaphyseal fractures, it is important to avoid the nails leaving the medullary canal and migrating posteriorly into the radial nerve sulcus. After both nails have crossed the fracture site, they are impacted into the cancellous bone of the proximal metaphysis.

When a residual deformation persists, this is corrected by rotating the nails with the concave side towards the angulation.

At the end of the operation, the nails are cut and hidden under the tegument, without causing local irritations, so as to be easily visible at the time of ablation [2,6,10].

#### *Particular indications*

The presence of an essential bone cyst in the proximal humerus region is an indication for ESIN. Regardless of the presence of pathological bone fracture, elastic nails increase bone resistance and facilitate the healing of the cyst.

This indication is also valid for cysts present in the proximal femur, with the difference that in this case, the nail diameter should be larger.

#### *Supracondylar fractures*

Elastic nails are an elegant method for the fixation of supracondylar fractures in children. The stability they confer allows to exclude plaster cast, without the risk of secondary displacement. The nails are extra-articular, the risk of arthritis is eliminated, and early mobilization is possible without the need for the early ablation of the osteosynthesis material.

#### *Operative technique*

The operative technique requires perfect coordination. The patient is positioned in dorsal decubitus, with the upper limb on a radiotransparent table.

The lateral side of the humerus is exposed through a longitudinal incision, below the deltoid muscle insertion. At this level, two oblique holes are drilled, through which the nails will be introduced. The two nails are pre-shaped by bending, and their tips must be sharp.

The first nail is introduced through the distal orifice, through the fracture site, with the tip oriented distally and posteriorly. The second nail is inserted in a similar manner, with the tip oriented distally and anteriorly.

Fracture reduction is subsequently performed and, under fluoroscopic control, with the elbow in flexion, the nails are advanced several millimeters into the distal fragment. After the nails have penetrated 3-4 mm into the distal fragment, sufficient stability has been reached to allow elbow extension and the assessment of reduction, particularly the Baumann angle. In lateral view, the quality of the reduction of the anterior cortical bone is evaluated. If reduction is adequate, the nails are advanced into the distal fragment up to the limit of the articular cartilage.

The proximal tips of the nails are bent and cut, to avoid skin injury. After the application of a compression bandage for 3-4 days, the upper limb can be left free, in a sling, for 15 days. After this period, the patient can mobilize his elbow gently. Normal activity can be resumed after 4-6 weeks [2].

**Radial head fractures**

These fractures are relatively rare (5% of all elbow fractures). Radial head fractures may seriously compromise elbow function by mechanical and vascular changes in the radial head. The indication for ESIN is radial head fractures with an angulation greater than 30°, which do not respond to orthopedic treatment [13,14].

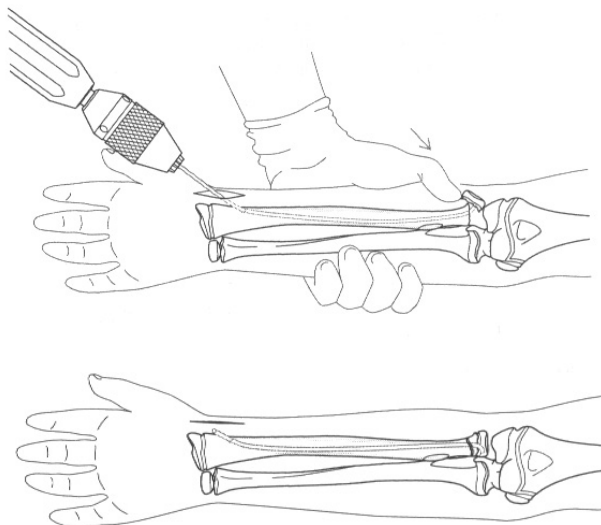
*Operative technique*

The patient is positioned in dorsal decubitus, with the upper limb on the radiotransparent table. On the lateral margin of the forearm, 1 cm proximally to the distal growth cartilage of the radius, a small incision of about 1 cm is performed. At this level, an entry hole is drilled, while avoiding radial vascular injury.

For radial head fractures, an elastic nail 1.5-2.5 mm in diameter is prepared. Its tip is bent at 3-4 mm, at a 30-45° angle, and the nail is subsequently curved in its middle portion.

Then, the nail is advanced into the radius up to the fracture site.

By positioning the elbow in extension and the forearm in pronation or supination, the position at which angulation is maximal is detected. After this position has been determined, the nail tip is oriented towards the radial head and is impacted into it using the hammer.



**Figure 5.** ESIN in radial head fractures

Then, the elastic nail is rotated by 180°, and this movement will cause fracture reduction by the consecutive mobilization of the radial head. The lateral condyle acts as a brake for overcorrection.

If there is an angulation of 80° or greater, the nail will leave the radial metaphysis above the radial head, without engaging it. In this case, an orthopedic reduction procedure, even partial, is required, which will allow the elastic nail to engage the radial head (Figure 5).

When the reduction is complete, the nail is left in the position reached, and elbow mobilization is possible given the extra-articular position of the nail.

The distal extremity of the nail is bent and cut so as to avoid the irritation of the overlying skin [2].

After the application of a compression bandage for several days, the forearm is positioned in a sling for 10-15 days. After this period, elbow mobilization is allowed, and normal activity is resumed after 3 weeks. The nail is extracted after 2-3 months.

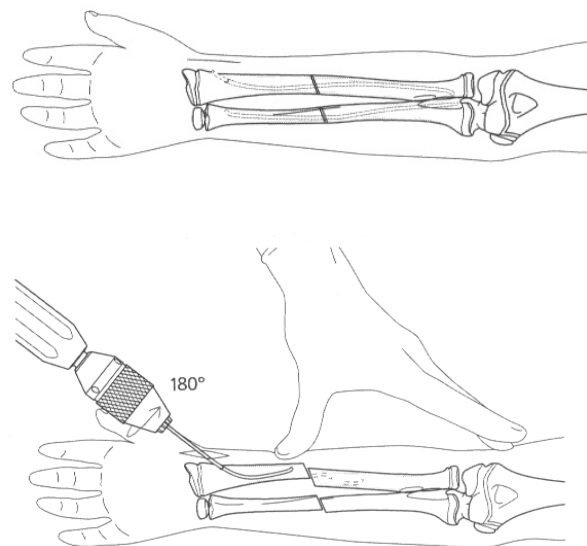
**Forearm fractures**

Orthopedic treatment in forearm fractures is accepted, but the allowed limits of spontaneously remodeled angulation are well known. If these limits are exceeded or in the case of orthopedic treatment failure, closed reduction and ESIN are indicated in forearm fractures [2,15-17].

*Operative technique*

The patient is positioned in dorsal decubitus, with the affected forearm on the radiotransparent table.

The diameter of the nails used varies between 2.5 and 3 mm. The ulnar nail is almost straight, while the radial



**Figure 6.** Reduction and elastic nailing in forearm bone fractures

nail has a marked bending in order to restore the pronatory curve of the radius.

Fixation usually starts with the bone that is easier to reduce. For the radius, the entry point is found in the distal metaphysis, above the distal growth cartilage, between the tendons of the long and short extensors of the thumb. The cortical bone is exposed through a small incision and a hole is drilled, which is enlarged by circular movements. The nail is inserted into the medullary canal up to the fracture site. Fracture reduction is performed and the nail is advanced into the proximal fragment under fluoroscopic control (Figure 6).

A similar procedure is carried out for the ulna, using the antegrade technique, with the entry point on the medial margin of the olecranon [15-17].

### Discussion

Shaft fractures of the long bones are among the most common pediatric injuries. They are characterized by a limited potential for spontaneous correction because of the fractures – distance to the physis. In the past, the gold standard of management of shaft fractures in children had been closed reduction and cast immobilization. Since then several aspects have led to an increase in the numbers of surgical procedures including changes of living, sports habits, economics, and patients' request for treatment. Because of higher chances of re-displacement in cast, especially in older children, particularly 12-16 years old, and in fractures that tend to be proximal, there has been shift in the trend of managing these fractures from closed reduction and cast immobilization to reduction and fixation with intramedullary or extramedullary devices.

In shaft fractures of the upper extremities, increasing rates of surgical procedures have been reported for the prevention of functional deficits of forearm pronation and cosmetic deformities of the humerus. In fractures of the lower extremities maximizing stability shifted into the focus of interest to achieve early mobilization and to compensate heavier body weights of children and adolescents. Consecutively, the current gold standard of pediatric shaft fracture treatment – ESIN (elastic stable intramedullary nailing) – has been modified repeatedly using end caps, pre-bended nails, and optimized surgical techniques. All these methods of pediatric fracture care carry inherent advantages that require consideration for each clinical situation. On the other hand, this has widened the spectrum of potential complications, which needs continuous evaluation to further improve treatment results.

### References

1. Papakostidis C, Grotz MR, Papadokostakis G, Dimitriou R, Giannoudis PV. Femoral biologic plate fixation. *Clin Orthop Relat Res.* 2006;450:193-202.

2. Hunter JB. The principles of elastic stable intramedullary nailing in children. *Injury.* 2005;36:20-24.

3. Salem KH, Lindemann I, Keppler P. Flexible intramedullary nailing in pediatric lower limb fractures. *J Pediatr Orthop.* 2006;26(4):505-509.

4. Berger P, De Graaf JS, Leemans R. The use of elastic intramedullary nailing in the stabilisation of paediatric fractures. *Injury.* 2005;36(10):1217-1220.

5. Metaizeau J.P. Stable elastic intramedullary nailing for fractures of the femur in children. *J Bone Joint Surg Br.* 2004;86(7):954-957.

6. Parikh SN, Nathan ST, Priola MJ, Eismann EA. Elastic Nailing for Pediatric Subtrochanteric and Supracondylar Femur Fractures. *Clin Orthop Relat Res.* 2013 Aug 17. [Epub ahead of print].

7. Salonen A, Lahdes-Vasama T, Mattila VM, Valipakka J, Pajulo O. Pitfalls of femoral Titanium Elastic Nailing. *Scand J Surg.* 2014 Apr 15. [Epub ahead of print].

8. Griffet J, Leroux J, Boudjouraf N, Abou-Daher A, El Hayek T. Elastic stable intramedullary nailing of tibial shaft fractures in children. *J Child Orthop.* 2011;5(4):297-304.

9. Kraus T, Hoermann S, Ploder G, Zoetsch S, Eberl R, Singer G. Elastic stable intramedullary nailing versus Kirschner wire pinning: outcome of severely displaced proximal humeral fractures in juvenile patients. *J Shoulder Elbow Surg.* 2014 Apr 13, S1058-2746(14)00046-9. doi: 10.1016/j.jse.2014.01.015.

10. Canavese F, Athlani L, Marengo L, Rousset M, Rouel-Rabiau N, Samba A, et al. Evaluation of upper-extremity function following surgical treatment of displaced proximal humerus fractures in children. *J Pediatr Orthop B.* 2014;23(2):144-149.

11. Khan A, Athlani L, Rousset M, Samba A, Canavese F. Functional results of displaced proximal humerus fractures in children treated by elastic stable intramedullary nail. *Eur J Orthop Surg Traumatol.* 2014;24(2):165-172.

12. Lefèvre Y, Journeau P, Angelliaume A, Bouty A, Dobremez E. Proximal humerus fractures in children and adolescents. *Orthop Traumatol Surg Res.* 2014;100(1 Suppl):S149-156. doi: 10.1016/j.otsr.2013.06.010.

13. Tarallo L, Mugnai R, Fiacchi F, Capra F, Catani F. Management of displaced radial neck fractures in children: percutaneous pinning vs. elastic stable intramedullary nailing. *J Orthop Traumatol.* 2013;14(4):291-297.

14. Yao LF, Ye ZM, Li ZX, Zhong ZP, Xu RM. Treatment of radial neck fracture in children with elastic stable intramedullary nails. *Zhongguo Gu Shang.* 2013;26(12):1028-1031.

15. Bader M, Sanz L, Waseem M. Forearm fractures in children: Single bone fixation with elastic stable intramedullary nailing in 20 cases. *Injury.* 2006;37(9):923-924.

16. Antabak A, Luetic T, Ivo S, Karlo R, Cavar S, Bogovic M, Medacic SS. Treatment outcomes of both-bone diaphyseal paediatric forearm fractures. *Injury.* 2013;44(Suppl 3):S11-15.

17. Du SH, Feng YZ, Huang YX, Guo XS, Xia DD. Comparison of Pediatric Forearm Fracture Fixation Between Single- and Double-Elastic Stable Intramedullary Nailing. *Am J Ther.* 2014 Jan 9, [Epub ahead of print].