


Mycobacterium smegmatis Skin Infection Following Cosmetic Procedures: Report of Two Cases

Caroline J Wang ¹, Yinggai Song^{2,3}, Tingting Li¹, Jian Hu¹, Xue Chen¹, Houmin Li¹

¹Department of Dermatology, Peking University People's Hospital, Beijing, People's Republic of China; ²Department of Dermatology, Peking University First Hospital, Beijing, People's Republic of China; ³Beijing Key Laboratory of Molecular Diagnosis of Dermatoses, Beijing, People's Republic of China

Correspondence: Houmin Li, Tel +86-10-88325472, Email lhoumin@sina.cn

Abstract: *Mycobacterium smegmatis* is an acid-fast bacillus of rapidly growing mycobacteria (RGM) of nontuberculous mycobacteria (NTM). *M. smegmatis* was considered nonpathogenic to humans until 1986, when the first patient was linked to the infection. To date, fewer than 100 cases have been reported in the literature, mainly related to various surgical procedures. Herein, we report two immunocompetent patients who acquired *M. smegmatis* infection following cosmetic procedures. Due to the rarity of *M. smegmatis* infection in routine clinical practice, it is challenging for medical providers to diagnose and treat patients with *M. smegmatis* infection. *M. smegmatis* infection should be considered for patients with chronic skin and soft tissue infections at the injection site or surgical site following cosmetic procedures. Histological findings, pathogen identification by molecular testing or bacterial culture are required to make a definitive diagnosis. Medical providers should raise awareness of *M. smegmatis* infection for patients with chronic skin and soft tissue infections after cosmetic procedures. Stringent sterile procedures for surgical instruments, supplies, and environments should be enforced.

Keywords: cosmetic procedures, nontuberculous mycobacterium, *Mycobacterium smegmatis*, skin and soft tissue infections

Introduction

Over the last few decades, the number of people seeking cosmetic procedures has increased dramatically worldwide.¹ NTM infection caused by cosmetic procedures deserves special attention because most NTM species exist ubiquitously in the environment, particularly in water and soil, which can easily contaminate medical devices, instruments, and reagents, leading to infection in humans. A report from Mayo Clinic suggests that the increasing number of cosmetic and body-modifying procedures is associated with the rise in sporadic cases and outbreaks of NTM skin and soft tissue infections, in which rapidly growing mycobacteria (RGM), a subgroup of NTM, caused infections make up the most significant proportion of NTM infection cases.² Cosmetic-related services have boomed in recent years in China, driven by demands and profits. The prevalence of NTM infection in China is higher than that in European countries and in the United States.³ At present, there are only a few reports of cosmetics-related NTM infection in China, and the incidence of cosmetics-induced NTM infection in China is unclear.^{4,5} Herein, we report two patients with *M. smegmatis* infection associated with cosmetic procedures/injections to raise medical providers' awareness. To our knowledge, only one case of *M. smegmatis* infection related to cosmetic procedures has been reported in China.⁵

Case Reports

From May to September 2021, two patients were referred to our hospital with facial skin and soft tissue infections after receiving cosmetic injections of unknown composition. Both patients, at two different private cosmetic clinics in China, received the same injection agent, the so-called "bone dissolving agent," which the manufacturer claims dissolves cheekbones by activating osteoclasts for bilateral zygomatic reduction. Both patients shared similar clinical manifestations and disease courses. Patients developed swelling, erythema, abscesses, subcutaneous nodules, and erythematous

plaques at the injection site, along with nonspecific clinical manifestations between two weeks and one month after the injection.

Patient A: The first patient was a 32-year-old healthy woman who developed swelling and erythema with a painful sensation at the injection site 2 weeks after receiving the “bone dissolving agent” injection. The treating physician prescribed intravenous cephalosporin for 3 days to treat the infection with no improvement. However, the patient’s symptoms worsened as nodules and abscesses formed. Then, surgical debridement was performed, and amoxicillin was added to the treatment regimen. The debridement tissue specimen was sent for cultures of common bacteria and fungi, but the results were negative. The patient presented to our hospital with worsening symptoms following two months of broad-spectrum antibiotics and surgical debridement. Physical examination revealed scattered erythematous plaques with subcutaneous nodules and abscesses on both sides of the cheeks, some of which were confluent (**Figure 1**). No systemic symptoms or lymphadenopathies were observed. The patient underwent routine laboratory investigations, including complete blood count, liver and kidney function, with results within normal ranges. The human immunodeficiency virus (HIV) test was negative. Biopsies were taken and revealed granulomatous inflammation in the dermis with epithelioid histiocytes and multinucleated giant cells intermingled with abundant lymphocytes, plasma cells, and rare neutrophils (**Figure 2**). Gram, acid-fast bacilli (AFB), and GMS stains were negative for microorganisms. Then, multiplex real-time PCR assays targeting the NTM HSP65 gene and 16S rRNA gene and panfungal multiplex real-time PCR targeting the 28S rRNA gene were performed on tissue biopsy specimens from the injection sites, and *M. smegmatis* was identified as the causative infectious agent. Due to insufficient specimens, we did not perform bacterial and fungal culture and drug sensitivity tests. After consultation with a senior expert in our hospital’s department of infectious diseases, 300 mg QD of rifampin, 150 mg TID of isoniazid, and 100 mg BID minocycline were prescribed for 6 months. Because of the severity of the local inflammation when the patient initially presented to our hospital, a combination of 0.8 mL (80 mg) amikacin, 0.1 mL Diprosan (0.7 mg betamethasone, Schering-Plough), and 0.1 mL (2 mg) lidocaine was given intralesionally into each cheek lesion. The intralesional injections were repeated one month later after the initial intralesional injection. No

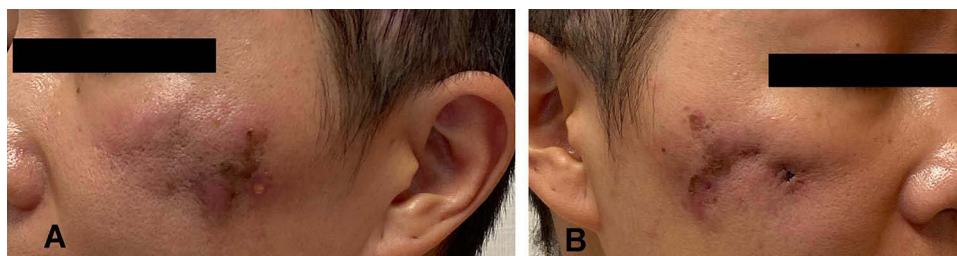


Figure 1 Clinical manifestation of *Mycobacterium smegmatis* infection after cosmetic injection in patient A. Poorly defined erythematous plaques with subcutaneous nodules and abscesses were seen on both sides of the cheeks (**A** left; **B** right).

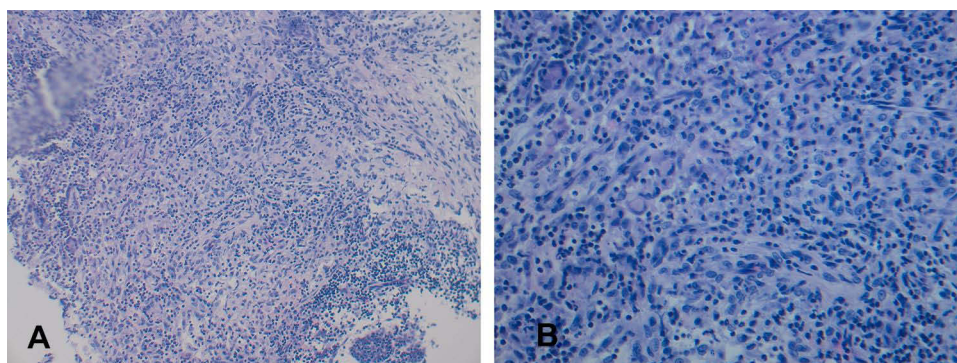


Figure 2 Histopathological findings of a representative section of biopsy specimens from patient A. The biopsy shows granulomatous inflammation in the dermis with multinucleated giant cells intermingled with epithelioid histiocytes, abundant lymphocytes, plasma cells, and rare neutrophils (hematoxylin and eosin stain, 40X (**A**) and 200X (**B**) magnifications).

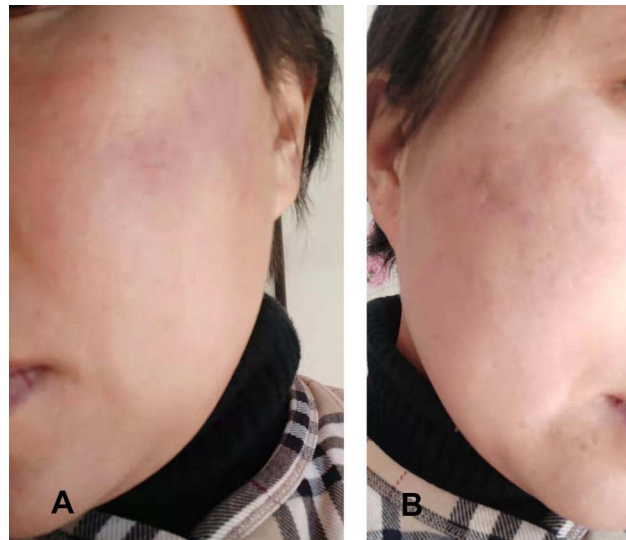


Figure 3 Follow-up photograph after 6 months of treatment in patient A. The inflammation subsided, with minimal scar formation (**A** left; **B** right).

major adverse effects were reported during antibiotics treatments. After the 6-month antimicrobial course and two intralesional injections, the symptoms were resolved with minimal scar formation on both cheeks (Figure 3).

Patient B: The second patient was a 30-year-old healthy male who developed similar symptoms as seen in patient A at the injection site one month following injection of the “bone dissolving agent”. He then went to a local primary care facility for a treatment process that involved levofloxacin and surgical debridement, with purulent discharge sent for microbiological examination. Cultures were negative for common bacteria and fungi. He also underwent head computed tomography (CT) and magnetic resonance imaging (MRI) studies, which showed swollen bilateral maxillofacial soft tissue. The patient also visited different primary care physicians and received multiple short terms of broad-spectrum antibiotics. Unfortunately, the lesions continued to progress; then, the patient was referred to our hospital for further investigation and treatment. We performed the same routine examination and laboratory tests on the patient as did for patient A and all laboratory results were within normal limits. Physical examination revealed erythematous plaques with subcutaneous nodules and abscesses on both sides of the cheeks. No systemic symptoms or lymphadenopathies were observed. The biopsy of the lesion showed dermal chronic granulomatous inflammation, and Gram, AFB, and GMS stains are negative for microorganisms. Subsequently, *M. smegmatis* was identified as the causative infectious agent by the same multiplex real-time PCR assays as described above for patient A. With the diagnosis of cutaneous *M. smegmatis* infection, 300 mg QD of rifampin, 150 mg TID of isoniazid, and 100 mg BID minocycline were administered. The patient B refused to receive an intralesional injection. The lesions were resolved after a 5-month antimicrobial treatment, mild scar formation was observed on both cheeks. No major adverse effects were reported during antibiotics treatments.

Discussion

NTM are a group of mycobacteria that exclude *M. tuberculosis* and *M. leprae*. NTM were systematically classified based on their growth rate and ability to produce pigments in light or darkness. *M. smegmatis* belongs to the category of rapidly growing mycobacteria (RGM). It was first isolated from syphilitic chancres by Lustgarten in 1884. Subsequently, the same bacterium was isolated in normal genital secretions (smegma), and then *M. smegmatis* was named in 1889. *M. wolinskyi* and *M. goodii* were added to the *M. smegmatis* group in the 1999 classification system.⁶ *M. smegmatis* was generally considered nonpathogenic in immunocompetent populations until 1986, when the first patient was observed with *M. smegmatis* infection.⁷ Since then, fewer than 100 cases have been reported in the literature. Most *M. smegmatis* infection cases are related to minor surgery, trauma, long-term central vein catheterization, and cosmetic procedures in immunocompetent patients.^{8–11} In immunocompromised individuals, *M. smegmatis* infection can get disseminated, resulting in bacteremia and mortality.¹²

M. smegmatis, like most NTM, is ubiquitously found in water, soil, and plants, is resistant to water disinfection, and can colonize body surfaces. *M. smegmatis* infections are typically the result of direct inoculation via contaminated surgical instruments and treating agents or unsterile procedures. The two patients in this report developed skin *M. smegmatis* infection after receiving injections of a so-called bone dissolving agent at different cosmetic clinics. The so-called bone dissolving agent used for this cosmetic procedure was not registered with the China National Medical Product Administration, and we were unable to obtain the agents used for these patients to identify infectious microorganisms. It is most likely that this bone resolving agent was contaminated with *M. smegmatis* and was the cause of infection because the injection agent is the only common material used for these patients at the different cosmetic clinics. In addition, not all patients who received the same lot of injection agent developed an active infection. Therefore, it is likely that patients' susceptibility and response to *M. smegmatis* may play a role in their development of an active infection. Since *M. smegmatis* is ubiquitously present in the environment and *M. smegmatis* infection is typically the result of direct inoculation via contaminated surgical instruments and therapeutic agents or unsterile procedures, medical providers must adhere to aseptic principles and utilize aseptic procedures in an aseptic environment to reduce incidence of *M. smegmatis* infection. In addition, manufacturers must exercise the current recommended manufacturing practices when producing therapeutic agents to prevent instances of NTM contamination in their products.

It is challenging to diagnose patients with *M. smegmatis*-caused skin and soft tissue infections because they lack specific clinical features. The lesions often begin at the injection/surgical sites and appear mild and benign in the early stage, often leading many patients to be overlooked. The typical clinical findings include local swelling, erythema, papules, subcutaneous nodules, abscesses, and nonhealing ulcers. These features are nonspecific and similar to infections caused by other bacteria, fungi, and actinomycetes. Our patients presented with swelling and erythema at the injection sites, along with subcutaneous nodules and abscesses without systemic symptoms. They were misdiagnosed as having common bacterial infections and treated accordingly. In a retrospective study involving 25 cases of cutaneous NTM infection, the mean time from clinical presentation to diagnosis was 7.1 months, and the misdiagnosis rate by family physicians was 82%, suggesting that patients with cutaneous NTM infections are prone to delayed diagnosis and treatment.¹³

Skin and soft tissue NTM infections can present variable histopathological features, mainly from acute suppurative inflammation to typical granulomatous inflammation. Different mycobacteria can cause identical histological findings. It appears that the host immunological status contributes to different histological findings skin and soft tissue NTM infections. Some authors noted that in immunocompetent patients, most biopsies showed psoriasiform and pseudoepitheliomatous epidermal hyperplasia with dermal granulomatous inflammation accompanied by varying amounts of necrosis and neutrophilic infiltration. Acid-fast bacilli were either not detectable or very scant on the special stains. In immunosuppressed patients, histological features predominantly show suppurative inflammation with dense collections of neutrophils and less granuloma formation.¹⁴ Acid-fast bacilli were numerous and easily identifiable in the tissue sections.^{15,16} Histological features observed in our patients align with the features reported in the literature on immunocompetent patients. Histopathological study plays an essential role in patient diagnosis. However, histological changes are not pathognomonic for NTM infection.

Bacterial culture for the diagnosis of NTM infection is challenging because NTM are slow-growing bacteria and difficult to culture. Nevertheless, bacterial culture is still a commonly used technique for mycobacterial identification, and this test is based on the growth rate on solid media, colony morphology, colony pigmentation with and without light exposure, and biochemical test results. With positive NTM culture results along with histopathological features of granulomatous inflammation in lesions at the inoculation sites, the diagnosis of NTM infection can be made with great certainty, assuming that other differential diagnoses and the possibility of sampling contamination were excluded.¹⁶ Additionally, mycobacterial susceptibility testing, which is required according to the Clinical and Laboratory Standards Institute guidelines, is based on bacterial culture and bacterial isolation. Unfortunately, bacterial cultures were not performed in either patient due to insufficient tissue samples.

Nucleic acid amplification assays are excellent tools for directly identifying mycobacteria in clinical specimens, although they are not widely available. Compared with the bacterial culture technique as an identification tool, molecular testing has dramatically improved the turnaround time, sensitivity, and specificity of diagnosing NTM infection for

clinical service. Some authors incorporated broad-range PCR followed by suspension array hybridization to identify clinically relevant mycobacterial complexes, groups, and species in one single reaction.¹⁷ Many other laboratories developed multiplex real-time PCR assays to detect tuberculous and nontuberculous mycobacteria simultaneously.^{18,19} Our university hospital molecular laboratory also used multiplex real-time PCR targeting the NTM *HSP65* gene and 16S rRNA gene and panfungal PCR targeting the 28S rRNA gene on tissue biopsy specimens to detect the NTM and fungal species. In our experience, the combination of the expected clinical presentations, histological findings, and molecular testing results often leads to a definitive diagnosis of NTM infection with specific species information.

Due to the small number of cases of *M. smegmatis* infection, there have been no large-scale clinical trials comparing different antibiotic regimens or defining the appropriate length of treatment. Therefore, many authors recommend individualized therapy based on drug sensitivity test results.²⁰ While in vitro drug sensitivity tests can guide individual treatment selection, their results do not always correlate with clinical efficacy. Some case reports have suggested doxycycline, amikacin, imipenem, moxifloxacin, ciprofloxacin, linezolid, clarithromycin, and ethambutol as choices of antibiotics for *M. smegmatis* infection.^{8–11} Others recommend at least two antibiotics to mitigate the risk of emergent antibiotic resistance. In general, surgical debridement is recommended as a critical complementary approach to treating skin and soft tissue NTM infections because it can reduce the burden of disease.^{21–23} However, excessive surgical debridement may cause fistulas at the site of skin lesions, leading to the local spread of NTM and increasing the difficulty of further treatment. The two patients in this study were treated with isoniazid, rifampin, and minocycline. We regularly monitored their liver and kidney functions and other physiological conditions during drug administration, and no significant adverse reactions occurred. In addition, the first patient was treated with intralesional injections of amikacin, Diprosan, and lidocaine. The intralesional injection was performed based on the recommendations of our infectious disease experts and our own experience with other infectious diseases. Systemic oral antibiotics may not achieve therapeutic effects due to the poor blood circulation of a local lesion and scar formation. The oral antibiotics in combination with local intralesional injection of antibiotics and steroids may increase the effectiveness of the antibacterial and anti-inflammatory properties of steroids. The intralesional injections twice in combination with the systemic antibiotics used in patient A effectively stopped disease progression, helped relieve discomfort and anxiety, and minimized scar formation. While reasonable therapeutic procedures can effectively manage the progression of the disease, it is critical for medical providers to have a high degree of suspicion to recognize NTM infection, particularly in patients with a history of recent cosmetic procedures in an unauthorized or a substandard cosmetic clinic.

Conclusion

NTM infections introduced by cosmetic procedures appear to be a common iatrogenic issue in China. *M. smegmatis* infection following cosmetic procedures is rare. Based on our knowledge, this is the second report of *M. smegmatis* infection after cosmetic procedures in China. *M. smegmatis* infection caused by cosmetic procedures is often misdiagnosed, and primary medical providers often delay proper treatment, which causes tremendous physical and mental suffering for patients. NTM infection should be included in the differential diagnosis for patients with persistent nonhealing skin lesions and poor response to general antibiotic treatment following cosmetics-related procedures. Histological evaluation and microorganism identification are essential for a definitive diagnosis. In the absence of clear treatment guidelines, local surgical debridement with an individualized antibiotic based on the bacterial identification results is needed. Stringent sterile procedures for surgical instruments, supplies, and environments should be enforced, and the relevant government regulatory agencies should implement strict policies for cosmetic institutions to prevent the use of unauthorized drugs.

Consent Statement

The written informed consents were obtained from both patients for the publication of the case details and images.

The manuscript was approved by the Peking University People's Hospital to publish the case details.

Funding

This work was supported by the National Nature Science Foundation of China No.81772160.

Disclosure

All authors report no conflicts of interest in this work.

References

- Safe IP, Macedo V, Marcelo W, et al. Nontuberculous mycobacterial infections after aesthetic procedures: comparison of clinical features and treatment. *J Clin Aesthet Dermatol.* 2021;14(3):46–49.
- Wentworth AB, Drage LA, Wengenack NL, Wilson JW, Lohse CM. Increased incidence of cutaneous nontuberculous mycobacterial infection, 1980 to 2009: a population based study. *Mayo Clin Proc.* 2013;88(1):38–45. doi:10.1016/j.mayocp.2012.06.029
- Zhou L, Xu D, Liu H, Wan K, Wang R, Yang Z. Trends in the prevalence and antibiotic resistance of non-tuberculous mycobacteria in Mainland China, 2000–2019: systematic review and meta-analysis. *Front Public Health.* 2020;8:295. doi:10.3389/fpubh.2020.00295
- Xu C, Wu W, Pan H, et al. *Mycobacterium agri* skin infection in a previously healthy patient: a case study. *Infect Drug Resist.* 2021;14:2965–2968. doi:10.2147/IDR.S322717
- Yang E, Hengshu Z. Clinical analysis of nontuberculous mycobacterial infection after minimally invasive plastic surgery and cosmetic surgery. *J Cosmet Dermatol.* 2021;00:1–7.
- Brown-Elliott BA, Wallace RJ Jr. Clinical and taxonomic status of pathogenic nonpigmented or late-pigmenting rapidly growing mycobacteria. *Clin Microbiol Rev.* 2002;15(4):716–746. doi:10.1128/CMR.15.4.716-746.2002
- Vonmoos S, Leuenberger P, Beer V, de Haller R. Infection pleuropulmonaire a *Mycobacterium smegmatis*. Description d'un cas et revue de la littérature. *Schweiz Med Wochenschr.* 1986;116(52):1852–1856.
- Butt S, Tirmizi A. *Mycobacterium smegmatis* bacteremia in an immunocompetent host. *IDCases.* 2019;12(15):e00523. doi:10.1016/j.idcr.2019.e00523
- Newton JA Jr, Weiss PJ, Bowler WA, Oldfield EC 3rd. Soft-tissue infection due to *Mycobacterium smegmatis*: report of two cases. *Clin Infect Dis.* 1993;16(4):531–533. doi:10.1093/clind/16.4.531
- Pennekamp A, Pfyffer GE, Wuest J, George CA, Ruef C. *Mycobacterium smegmatis* infection in a healthy woman following a facelift: case report and review of the literature. *Ann. Plast. Surg.* 1997, 39, 80–83.
- Saffo Z, Ognjan A. *Mycobacterium smegmatis* infection of a prosthetic total knee arthroplasty. *IDCases.* 2016;5:80–82. PMID: 27516972; PMCID: PMC4978199. doi:10.1016/j.idcr.2016.07.007
- Pierre-Audigier C, Jouanguy E, Lamhamedi S, et al. Fatal disseminated *Mycobacterium smegmatis* infection in a child with inherited interferon gamma receptor deficiency. *Clin Infect Dis.* 1997;24(5):982–984. doi:10.1093/clinids/24.5.982
- Dodiuk-Gad R, Dyachenko P, Ziv M, et al. Nontuberculous mycobacterial infections of the skin: a retrospective study of 25 cases. *J Am Acad Dermatol.* 2007;57(3):413–420. doi:10.1016/j.jaad.2007.01.042
- Bartralot R, Garcia-Patos V, Sitjas D, et al. Clinical patterns of cutaneous nontuberculous mycobacterial infections. *Br J Dermatol.* 2005;152(4):727–734. doi:10.1111/j.1365-2133.2005.06519.x
- Bartralot R, Pujol RM, Garcia-Patos V, et al. Cutaneous infections due to nontuberculous mycobacteria: histopathological review of 28 cases. Comparative study between lesions observed in immunosuppressed patients and normal hosts. *J Cutan Pathol.* 2000;27(3):124–129. doi:10.1034/j.1600-0560.2000.027003124.x
- Li JJ, Beresford R, Fyfe J, Henderson C. Clinical and histopathological features of cutaneous nontuberculous mycobacterial infection: a review of 13 cases. *J Cutan Pathol.* 2017;44(5):433–443. doi:10.1111/cup.12903
- Li H, Turhan V, Chokhani L, Stratton CW, Dunbar SA, Tang Y-W. Identification and differentiation of clinically relevant mycobacterium species directly from acid-fast bacillus-positive culture broth. *J Clin Microbiol.* 2009;47(12):3814–3820. doi:10.1128/JCM.01534-09
- Sarro YDS, Butzler MA, Sanogo F, et al. Development and clinical evaluation of a new multiplex PCR assay for a simultaneous diagnosis of tuberculous and nontuberculous mycobacteria. *EBioMedicine.* 2021;70:103527. doi:10.1016/j.ebiom.2021.103527
- Kim JU, Ryu DS, Cha CH, Park SH. Paradigm for diagnosing mycobacterial disease: direct detection and differentiation of *Mycobacterium tuberculosis* complex and non-tuberculous mycobacteria in clinical specimens using multiplex real-time PCR. *J Clin Pathol.* 2018;71:774. doi:10.1136/jclinpath-2017-204945
- Ryu YJ, Koh WJ, Daley CL. Diagnosis and treatment of nontuberculous mycobacterial lung disease: clinicians' perspectives. *Tuberc Respir Dis.* 2016;79(2):74–84. doi:10.4046/trd.2016.79.2.74
- Jabbour SF, Malek AE, Kechichian EG, Tomb RR, Nasr MW. Nontuberculous mycobacterial infections after cosmetic procedures: a systematic review and management algorithm. *Dermatol Surg.* 2020;46(1):116–121. doi:10.1097/DSS.0000000000001929
- Wi YM. Treatment of extrapulmonary nontuberculous mycobacterial diseases. *Infect Chemother.* 2019;51(3):245–255. doi:10.3947/ic.2019.51.3.245
- Holt MR, Kasperbauer S. Management of extrapulmonary nontuberculous mycobacterial infections. *Semin Respir Crit Care Med.* 2018;39(03):399–410. doi:10.1055/s-0038-1651490

Clinical, Cosmetic and Investigational Dermatology

Dovepress

Publish your work in this journal

Clinical, Cosmetic and Investigational Dermatology is an international, peer-reviewed, open access, online journal that focuses on the latest clinical and experimental research in all aspects of skin disease and cosmetic interventions. This journal is indexed on CAS. The manuscript management system is completely online and includes a very quick and fair peer-review system, which is all easy to use. Visit <http://www.dovepress.com/testimonials.php> to read real quotes from published authors.

Submit your manuscript here: <https://www.dovepress.com/clinical-cosmetic-and-investigational-dermatology-journal>