

Inflammatory Bowel Disease: A Gastrointestinal Presentation of Congenital Plasminogen Deficiency

Bhairavi Balram, MD, FRCPC¹, Aducio Thiesen, MD, PhD, MSc, FRCPC², and Karen I. Kroeker, MD, MSc, FRCPC¹

¹Division of Gastroenterology, University of Alberta, Edmonton, Alberta, Canada

²Department of Laboratory Medicine and Pathology, University of Alberta Hospital, University of Alberta, Edmonton, Alberta, Canada

ABSTRACT

Plasminogen deficiency (PD) is a rare autosomal recessive disease that results in the formation of fibrin-rich pseudomembranes, which impair wound-healing capacity. We report a 21-year-old man with congenital PD-associated inflammatory bowel disease. After an episode of *Clostridioides difficile* infection, he developed chronic diarrhea. Colonoscopy revealed moderate friability and erythema of the colon. Histology showed fibrin deposits in the lamina propria of the colonic mucosa with surrounding inflammation and focal ulceration. He was treated with infliximab and achieved clinical remission. To our knowledge, this is the first reported case of colonic involvement of PD.

INTRODUCTION

We present a 21-year-old man with congenital plasminogen deficiency (PD) who presented with chronic diarrhea after a *Clostridioides difficile* infection. Subsequent investigations led to the possible diagnosis of inflammatory bowel disease (IBD). PD is a rare autosomal recessive disease with an estimated prevalence of 1:1,000,000.^{1,2} It is classified as type 1 PD (reduced plasminogen antigen and activity) and type 2 PD (reduced plasminogen activity only).³ Plasminogen plays an important function in both extravascular and intravascular fibrinolysis. It has also been implicated in wound healing, tissue remodeling, cell migration, embryogenesis, and angiogenesis.⁴ PD leads to an inability of fibrin breakdown, resulting in the accumulation of fibrin and the formation of pseudo-membranous (ligneous) changes. The most common presentation of PD is ligneous conjunctivitis, which is characterized by the development of fibrin-rich ligneous lesions.³ The disordered extracellular fibrin clearance can also affect other mucosal areas such as the female genital tract, oropharynx, upper and lower respiratory tract, renal collecting system, and duodenum.^{2,5}

CASE REPORT

A 21-year-old man with PD-associated IBD presented with ligneous conjunctivitis and hydrocephalus. He was diagnosed with PD at 3 months of age. Laboratory investigations showed low plasminogen antigen levels of $<0.09 \mu\text{g/mL}$. There was no family history of IBD or PD. He subsequently developed myxomatous mitral valve regurgitation, chronic multifocal osteomyelitis, and bronchiectasis complicated by recurrent pulmonary infections. He first developed gastrointestinal symptoms at the age of 3, with reflux symptoms, vomiting, abdominal pain, and failure to thrive. An esophagogastroduodenoscopy showed esophagitis, gastritis, and duodenitis with histologic findings of fibrin deposits within the esophageal, gastric antral, and duodenal mucosa. He was treated with a twice-daily proton pump inhibitor with symptom improvement.

At the age of 15, he developed *C. difficile* infection in the context of antibiotic use, requiring hospital admission and treatment with metronidazole. After this infection, he continued to have chronic diarrhea, which was thought to be recurrent *C. difficile* infection (despite negative stool cultures) or nonsteroidal anti-inflammatory drug-induced enteropathy. He was on regular nonsteroidal anti-inflammatory drugs for inflammatory arthropathy, particularly of the knees and ankles. Laboratory investigations showed elevated inflammatory markers (C-reactive protein: 48 g/L), iron deficiency anemia (hemoglobin 76 g/L, mean corpuscular volume 71, and ferritin 30), and elevated fecal calprotectin (1,527 mg/kg). He subsequently underwent a colonoscopy which revealed moderate

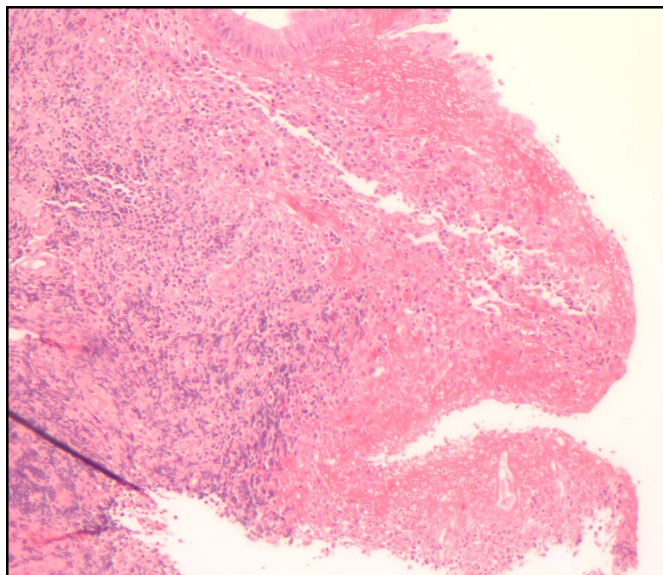


Figure 1. Photomicrograph showing fibrin deposits in the lamina propria of the colonic mucosa with surrounding inflammation and focal ulceration.

friability, erosions, and erythema throughout the colon without skip lesions or spontaneous bleeding. The terminal ileum appeared normal. An esophagogastroduodenoscopy showed edema and mild erosions in the distal third of the esophagus, stomach, and duodenum. Histology revealed extensive fibrin deposits in the lamina propria of the colonic and small bowel mucosa with surrounding inflammation, ulceration, and hemorrhage (Figure 1). There was also mild crypt distortion with crypt abscesses. Biopsies from the esophagus, stomach, and duodenum showed patchy fibrin deposits with focal erosions.

A magnetic resonance enterography demonstrated thickening and hyperenhancement of the colon and distal small bowel, in keeping with an inflammatory process. There was no obvious small bowel wall thickening or focal stricture. The transverse colon was dilated. There was increased fluid within the peritoneal cavity with no evidence of an abscess or mass. Given these findings, the decision was made to treat with corticosteroids as an induction agent for indeterminate colitis in a pediatric patient. He was started on a prolonged taper of oral prednisone (40 mg daily, tapered by 5 mg weekly) with good response. However, he had a recurrence of diarrhea when the prednisone dose was weaned. A repeat colonoscopy showed moderate colitis, similar to his previous colonoscopy. Thus, he was transitioned to a treatment regimen of infliximab (5 mg/kg/dose at 0, 2, 6 weeks, and then every 8 weeks) and oral methotrexate (12.5 mg weekly), the recommended treatment for refractory Crohn disease in a pediatric patient. Despite the initiation of a biologic, he did not achieve remission (with persistently elevated inflammatory markers), necessitating a dose escalation of infliximab to 10 mg/kg/dose. With the dose escalation, the inflammatory markers trended down, and the

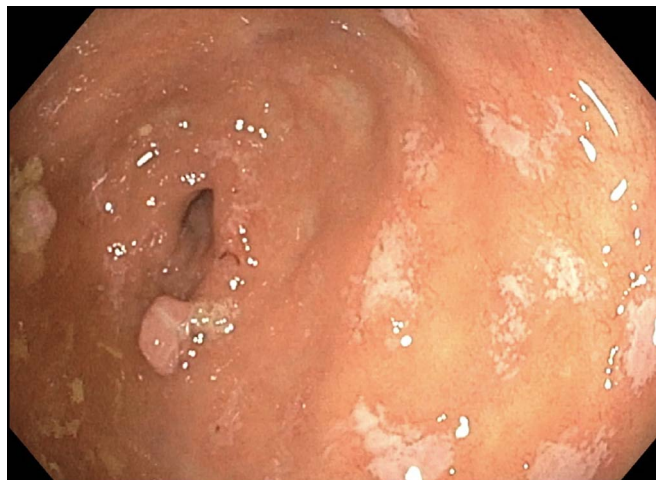

Figure 2. Colonoscopy showing patchy ulcerated mucosa, erosions, and inflammatory polyps in the rectum and cecum consistent with Crohn disease.

patient remained asymptomatic. The patient has been maintained on infliximab and methotrexate for 4 years, with occasional treatment interruptions because of recurrent pulmonary infections. The infliximab infusions were resumed after the treatment of infections without reinduction.

Most recently, at the age of 21, the patient had elevated fecal calprotectin (1,200 mg/kg), although he was asymptomatic. A colonoscopy performed showed patchy ulcerated mucosa, erosions, and inflammatory polyps in the rectum and cecum consistent with Crohn disease (Figure 2). Histological findings were similar to previous biopsies with fibrin deposits in the lamina propria throughout the colon with active inflammation and ulceration in the cecum and rectum. A decision was made to reduce the interval of infliximab dosing from every 8 to every 4 weeks. The patient has continued the methotrexate to control the inflammatory arthropathy.

DISCUSSION

We report a case of PD-associated IBD. To our knowledge, this is the first reported case of colonic involvement of PD. Our review of the literature found 4 case reports of patients with PD with gastrointestinal involvement. However, all cases were limited to the upper gastrointestinal tract.⁶⁻⁹ Patients presented with epigastric pain and were found to have duodenal ulcers on endoscopy. Histology revealed fibrin-rich deposits in the duodenal mucosa with inflammatory cells. Patients were subsequently treated with oral proton pump inhibitor with good response.

IBD arises as a consequence of dysregulated immune responses to luminal microbiota. PD, in the absence of plasmin activity, results in the formation of fibrin-rich pseudomembranes, which impair wound-healing capacity with excessive fibrin deposition, inflammation, and ulceration, resulting in clinical,

endoscopic, and histologic findings similar to IBD. There is currently no definitive treatment for PD-associated IBD. In our case, treatment with corticosteroids, infliximab, and methotrexate resulted in remission with symptom resolution. Management of colitis was complicated by recurrent infections because the initiation of infliximab resulted in more frequent and severe pulmonary infections, requiring infliximab interruptions. We recommend a multidisciplinary approach for the management of this condition with collaboration between specialists to treat various sites of the liginous lesions.

DISCLOSURES

Author contributions: B. Balram wrote the case report. A. Thiesen and KI Kroeker revised the manuscript for intellectual content, approved the final manuscript and is the article guarantor.

Financial disclosure: None to report.

Informed consent was obtained for this case report.

Received December 1, 2020; Accepted March 2, 2021

REFERENCES

1. Peyvandi F, Asselta R, Mannucci PM. Autosomal recessive deficiencies of coagulation factors. *Rev Clin Exp Hematol* 2001;5:369–88.
2. Schuster V, Seregard S. Liginous conjunctivitis. *Surv Ophthalmol* 2003;48:369–88.
3. Mehta R, Shapiro AD. Plasminogen deficiency. *Haemophilia* 2008;14:1261–8.
4. Castellino FJ, Ploplis VA. Structure and function of the plasminogen/plasmin system. *Thromb Haemost* 2005;93:647–54.
5. Baithun M, Freeman-Wang T, Chowdary P, et al. Liginous cervicitis and endometritis: A gynaecological presentation of congenital plasminogen deficiency. *Haemophilia* 2018;24:359–65.
6. Rodríguez-Ares MT, Abdulkader I, Blanco A, et al. Liginous conjunctivitis: A clinicopathological, immunohistochemical, and genetic study including the treatment of two sisters with multiorgan involvement. *Virchows Arch* 2007;451:815–21.
7. Veres G, Korponay-Szabó I, Maka E, et al. Duodenal ulceration in a patient with celiac disease and plasminogen I deficiency: Coincidence or cofactors? *Pediatrics* 2011;128:e1302–6.
8. Schuster V, Seidenspinner S, Zeitler P, et al. Compound-heterozygous mutations in the plasminogen gene predispose to the development of liginous conjunctivitis: Presented in part on the XIVth International Congress on Fibrinolysis and Thrombolysis, Ljubljana, June 22–26, 1998; Fibrinolysis & Proteolysis 12:20, 1998 (abstr 54, suppl 1). *Blood* 1999;93:3457–66.
9. Tefs K, Gueorguieva M, Klammt J, et al. Molecular and clinical spectrum of type I plasminogen deficiency: A series of 50 patients. *Blood* 2006;108:3021–6.

Copyright: © 2021 The Author(s). Published by Wolters Kluwer Health, Inc. on behalf of The American College of Gastroenterology. This is an open access article distributed under the terms of the Creative Commons Attribution-Non Commercial-No Derivatives License 4.0 (CCBY-NC-ND), where it is permissible to download and share the work provided it is properly cited. The work cannot be changed in any way or used commercially without permission from the journal.