



Oral care and photobiomodulation protocol for the prevention of traumatic injuries and lip necrosis in critically ill patients with COVID-19: an observational study

Fernanda de Paula Eduardo¹ · Marcella Ferreira Gobbi¹ · Livia Goron Bergamin¹ · Cesar Augusto Migliorati² · Leticia Mello Bezinelli¹

Received: 1 October 2021 / Accepted: 10 November 2021 / Published online: 19 November 2021

© The Author(s), under exclusive licence to Springer Nature Switzerland AG 2021

Abstract

It is well reported that severe cases of COVID-19 frequently need critical care in the ICU to manage respiratory complications, often requiring orotracheal intubation (OTI). Due to complex systemic conditions, the patient may remain intubated for a long period of time and be placed in prone position. This positioning and the pressure of the intubation device on the lips may lead to the development of traumatic injuries. Oral care and the use of photobiomodulation (PBM) can be successfully implemented to promote oral mucosa healing and prevent soft tissue necrosis. We describe the outcomes of the management protocol that was routinely used by the ICU oral medicine team, leading to the implementation of a preventive protocol for the OTI-related oral injuries. We retrospectively analyzed the records of 472 patients with COVID-19 in the ICU from May 2020 to February 2021. 60/472 patients developed traumatic injuries and were managed with the oral care protocol and PBM, to prevent the progress to lip necrosis. When appropriated, in addition to oral care and PBM, other measures were taken to prevent further local trauma (lip hydration, changes in tube fixation). The proposed oral care protocol associated with PBM successfully prevented the progress of traumatic lesions, ulceration, necrosis, and loss of tissue associated with IOT. The quality of life of patients in the ICU and after their recovery was preserved.

Keywords COVID-19 · Oral care · Photobiomodulation

Introduction

The new coronavirus disease described in 2019 (COVID-19) has been characterized as a highly transmissible infection, which can lead to severe and life-threatening complications. Characteristic signs and symptoms associated with severe COVID-19 are distinct from other known acute respiratory syndromes [1]. Some of the most significant complications are the potential to induce high morbidity and the need for long duration of stay in intensive care units (ICUs) due to respiratory complications. Vascular disorders and dysregulation of the immune system are other peculiarities of COVID-19 that may be associated with pathological changes in tissues and organs, including the oral mucosa [2].

Clinical reports have described the presence of lesions in the oral mucosa, especially in patients with severe COVID-19. Their clinical features include different patterns, such as aphthous-like oral ulcers, hemorrhagic ulcerations, oral ulcers with necrotic areas, petechiae, herpetic-like lesions, geographical tongue, vesiculobullous lesions, and mucosal

✉ Fernanda de Paula Eduardo
fpeduard@einstein.br

Marcella Ferreira Gobbi
marcellafgobbi@gmail.com

Livia Goron Bergamin
lilabergamin@gmail.com

Cesar Augusto Migliorati
C.Migliorati@dental.ufl.edu

Leticia Mello Bezinelli
lebezinelli@einstein.br

¹ Hospital Israelita Albert Einstein, Av. Albert Einstein, 627/520, São Paulo, CEP 05651-901, Brazil

² Department of Oral and Maxillofacial Diagnostic Sciences, College of Dentistry, University of Florida, Gainesville, USA

pigmentation [3–11]. It is still unclear if these lesions can be directly related to COVID-19. In patients with severe illness, the effect of COVID-19 on the respiratory system may require intensive care in the ICUs [12]. Oral traumatic injuries (usually located on the lips region) may develop due to the prolonged time that patients may remain intubated and, sometimes, for being maintained in a prone position. Other oral traumatic injuries may also include traumatic bites [9, 13–16].

Medical device-related pressure ulcers (PU) are a major issue among the hospitalized patients, and generally represent 34.5% of all hospital-acquired PU. PU of the mouth and lips are not that commonly reported, accounting for 3.4% [17] of the medical device-associated PU, but very frequently related to endotracheal tubes [9]. This data is even more scarce regarding COVID-19 critically ill patients, which develop several oral complications (including traumatic injuries) with an underreported frequency [9, 16].

In May 2020, the Hospital Israelita Albert Einstein (HIAE) (Sao Paulo, Brazil) oral medicine team began to receive requests for evaluation of patients admitted to the COVID-19 ICU. One of the most frequent reasons for consultation was the assessment of intubated patients who had developed severe and extensive lip ulcerations. Lesions had a necrotic center and were in direct contact with the intubation device, most frequently in patients in prone position. Keeping critical care patients in this particular position improves oxygen levels and has been frequently used in COVID-19 patients [12].

Based on the initial observation of the type of oral lesions that this group of patients was developing, the team then implemented a preventive management protocol to treat the patients while in the ICU.

The objective of this manuscript is to describe the outcomes of the implementation of the oral care protocol and the use of PBM to prevent the progress of traumatic lip lesions to extensive lip necrosis.

Materials and methods

This retrospective cohort study followed the “Strengthening the Reporting of Observational Studies in Epidemiology (STROBE) guidelines” (von Elm E et al. The Strengthening the Reporting of Observational Studies in Epidemiology (STROBE) statement: guidelines for reporting observational studies. *Ann Intern Med* 2007; 147 [8]:573–577).

The care of the patients throughout the study period was conducted in accordance with the principles of the Helsinki Declaration of 1975, as revised in 2000. The oral medicine team, housed within the hospital, actively evaluates and manages patients admitted in the ICU daily, and use standardized protocols.

This was a retrospective cohort study carried out at HIAE, Brazil. At the beginning of the COVID-19 pandemic, we observed that traumatic injuries of the lip associated with OTI evolved rapidly, progressing to local necrosis, and extensive soft tissue loss (Figure 1). In an attempt to mitigate the progress to extensive oral lesions and traumatic lip necrosis, the proposed oral care protocol associated with the use of photobiomodulation (PBM) was implemented. Medical records of all patients diagnosed with COVID-19, admitted to the ICU, submitted to OTI, from May 2020 to February 2021 were selected for review.

The selected patients must have been managed with the oral care and the PBM protocol. Males and females, age > 18 years, were included, and the patients must have had a diagnosis of a traumatic lesions or be at risk of oral lesions of traumatic etiology. In addition, patients that received OTI, tracheostomy (TQT), hospitalized for 7 days or more, maintained in a pronated position or after proning, and diagnosed with any pathological lip changes in oral cavity were also included. The purpose of the initial evaluation was to assess oral health status. Any changes in the oral cavity, presence of outbreaks of infections, and active oral/dental disease were recorded. The information of periodic follow-up must also have been recorded in the patient record.

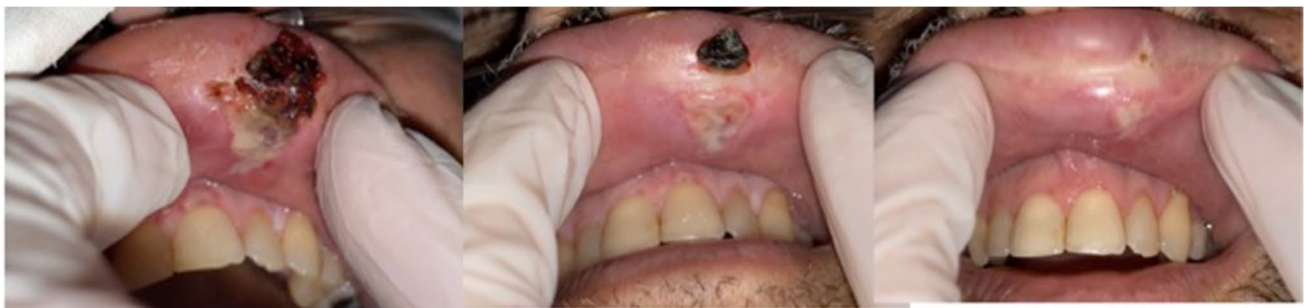

Fig. 1 Number of patients evaluated at the ICU from May 2020 to February 2021 and distribution of oral alterations in that period. OTI, orotracheal intubation

We excluded patients with incomplete dental records and without sufficient information on the oral conditions. Patients who did not receive oral care protocol or the application of PBM, patients with oral lesions not related to trauma, and those without correct demographic information, such as gender and age, were also excluded from the study.

For patients who presented with oral traumatic injuries, information was collected regarding the characteristics of the injury (hematoma, ulcer, and necrosis with tissue loss) and the protocol used for the treatment of these injuries and whether or not the oral care protocol and the PBM application prevented further lip damage and stimulated healing. Data such as gender, age, days of OTI until the beginning of the injury, total days of OTI, if patient was maintained in a prone position, were also included.

Routine intraoral examination of patients at the ICU

The dental evaluation was performed through a standardized intraoral examination by two oral medicine providers. Visual inspection was carried out using a portable spotlight and a disposable wooden spatula. We examined the lips, soft and hard palate, gingiva, tongue (lateral border and dorsal/ventral surfaces), buccal mucosa, and floor of the mouth. For patients with accumulation of debris, crusting, or other residues on the surface of the oral mucosa, a superficial cleaning with 0.9% saline solution was performed before the oral examination.

During the clinical exam in patients who presented lip lesions with or without erosion or ulcerations, a preliminary differential diagnosis was recorded and the oral care and PBM protocol was initiated.

Oral care protocol

Oral care performed by the team on OTI patients consisted of daily assessment, oral hygiene 3×/day performed by the nursing team. The standard operating protocol of oral hygiene for intubated patients included evaluation of the oral mucosa and teeth and the necessity of removal of infectious foci, and debridement of traumatic sites. All hospitalized patients diagnosed with COVID-19 in the ICU are isolated with both contact and aerosol precautions, which requires the use of disposable gown, gloves, protective goggles, N95 face mask, and face shield (when the procedure presents the risk of aerosol dispersion).

Oral hygiene was performed using a swab or toothbrush with 1.0% hydrogen peroxide plus 0.12% chlorhexidine, every 8 h, with the following steps: hand disinfection, donning of gowns and gloves, aspiration the oral cavity, oral hygiene of dental surfaces, oral mucosa, palate, tongue dorsum, and

endotracheal tube. The team maintained constant aspiration the oral cavity during hygiene to avoid undesirable swallowing or aspiration of debris. Following, the patient was prescribed an oral lubricant for the lips to be used every 6 h to minimize dryness.

Endotracheal tube lateralization and/or alteration of tube fixation was performed as needed, to minimize excessive pressure on the lips. If any evidence of ischemia or hematoma representing the initial formation of a traumatic injury was detected, the PBM protocol was then initiated.

PBM protocol

PBM was started at the first sign of trauma to the oral mucosa or the lip. The area to be treated was irradiated once a day, with the following parameters applied to each irradiation point: diode laser Therapy® (DMC, São Carlos, SP, Brazil), 100 mW, 0.09 cm² spot area, 660 nm, 10 s, 1 J, 11.1 J/cm² per point, continuous wave, point by point, in contact mode. The number of points varied, depending on the size of the area of the injury, with the goal of covering the entire lesion and the immediate surrounded tissues. The PBM application protocol was adapted from Bezinelli et al. [18] with the objective to control inflammation and stimulate tissue healing, preventing the formation of tissue necrosis. It is important to state that the validation and calibration of the equipment are done by the manufacturer, once a year. The validation and calibration results are reported to the hospital clinical engineer following the institution protocol. Regarding laser therapy safety protocol, both oral medicine team members and the patients wear safety goggles with appropriate wavelength protection, even when the patient is unconscious. Two calibrated oral medicine specialists were responsible for the diagnosis and treatment of the traumatic lip lesions. Both delivered laser therapy and evaluated the response to therapy and healing. In addition to the oral medicine providers, the ICU medical team followed the progress of the healing. All those evaluating the patients had to achieve a consensus on the outcome of therapy.

After the initiation of the oral care and PBM treatment, patients were evaluated daily. The oral medicine providers recorded the clinical status of the lesion and whether or not healing was progressing. Follow-up was carried out from the first day of detection of the lip lesion until remission, discharge of the patient from the ICU, or until the patient's death. Remission was considered for lesions that healed completely and partial remission for lesions that reduced in size or showed a reduction in inflammatory signs. These assessments were made clinically by 2 calibrated oral medicine providers.

Results

The oral medicine team evaluated 472 patients with COVID-19 in the ICU from May 2020 to February 2021. Of these, 332 had oral lesions, and 60/332 (18.1%) were lesions related to mechanical trauma (Figure 1).

Most injuries associated with trauma were located on the upper lip and labial mucosa, near to or at the area of fixation of the orotracheal tube. Clinically, the traumatic lesions were ulcerated with irregular margins, covered by fibrinoid exudation, some of which had a superficial crust (Figures 1A and B). It was noticed that prior to the ulceration, the area of the labial mucosa would present a hematoma (Figure 1C) or an area of ischemia (Figure 1D).

Most patients who had oral traumatic injuries were male (40/60, 67%), with a mean age of 69 years and an average intubation time of 16.5 days. Of the 60 patients who presented with traumatic injuries and were managed with the oral care protocol and PBM, 9 (15%) exhibited hematoma; 51 (85%) had ulcers and did not progress to lip destruction with tissue loss. Twenty two patients (36.6%) had to stay in the prone position between 12 and 36 h at some point during hospitalization.

Oral lesions treatment and clinical outcomes

The oral care protocol was performed in 60 patients. Of those, 52 (86.6%) patients received lip hydration with vitamin E cream or saline solution, 12 patients (20%) required a rotation of the tube, and 9 patients (15%) required a new tube fixation. All 60 patients (100%) received PBM therapy. Patients who presented with hematoma (9/60) required only 2 to 3 daily PBM applications that lasted less than 5 min. None of them progressed to ulceration and had complete remission of the lesions. The patients with lip ulcerations (51/60) required 4 to 6 daily PBM applications. Of the 51 patients who developed traumatic ulcers, 41 (80.4%) had complete remission of the lesions; 10 (19.6%) had partial remission. Of these 10 patients, 7 with progressive healing died before complete remission could be achieved. Three patients were extubated and discharged from the ICU. We observed an average time of 9 days in OTI before the appearance of an ulcerated lesion on the lip and or on the labial mucosa.

The following cases are examples of the experience our team had in the diagnosis and management of these individuals, which lead to the implementation of the oral care/PBM protocol.

Case 1

A 51-year-old male patient was admitted to the Hospital Albert Einstein, on March 2021, with complaints of severe dyspnea and fever. His past medical history was significant for obesity.

On physical examination, his body temperature was 38.8 °C, blood pressure 117/67 mmHg, heart rate 81 beats per minute, respiratory rate 11 breaths per minute, and oxygen saturation 84% on room air (critical). His laboratory results showed serum glucose 350 mg/dL, creatinine 1.23 mg/dL, white blood cell count 5980 cells per microliter (neutrophils = 81%; lymphocytes = 14.8%), D dimer 750 nd/mL, C-reactive protein 92.2 mg/dL, and hemoglobin 14.3 g/dL. Lung CT showed medium (between 25 and 50%) hyperdense areas in both lungs. rRT-PCR for SARS-CoV-2 yielded positive results. The patient was admitted to ICU and treated with enoxaparin sodium 40 mg, prednisolone 40 mg, and azitromicina 500 mg. Four days after intubation, the oral medicine team was called for evaluation of an oral ulcer on the upper lip. The examination revealed a 3.0-cm ulcer on the upper lip (Figure 1A). The lesion developed following a trauma during the period of OTI. The team initiated the oral care protocol and PBM applications. Two days after, the lesion was smaller and divided in two small ulcers of 1 cm each (Figure 1B), and 4 days later, the lesion had almost complete remission (Figure 1C).

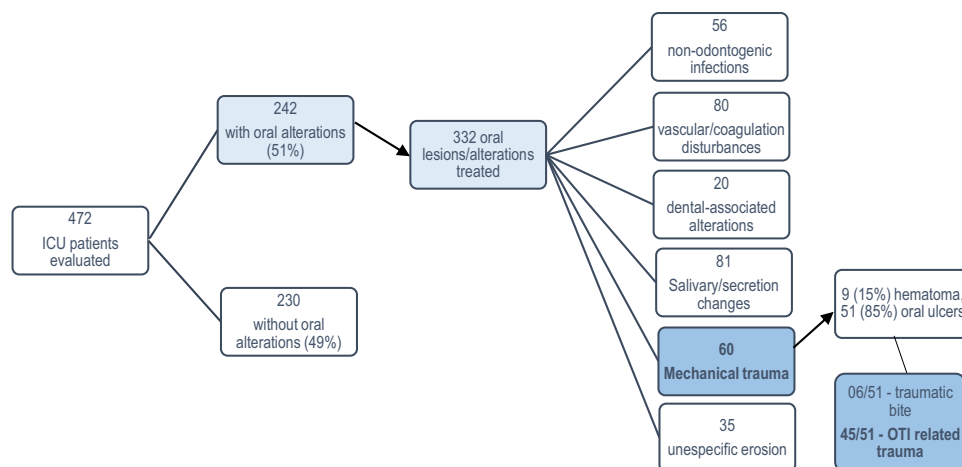
Case 2

An 86-year-old male patient was admitted to the Hospital Albert Einstein on April 2020, due to severe dyspnea and fever. His past medical history was significant for obesity and myeloid sarcoma. On physical examination, his body temperature was 38.8 °C, blood pressure 122/66 mmHg, heart rate 101 beats per minute, respiratory rate 25 breaths per minute, and oxygen saturation 95% on room air (critical). His laboratory results showed serum glucose 135 mg/dL, creatinine 1.02 mg/dL, white blood cell count 3610 cells per microliter (neutrophils = 51.2%; lymphocytes = 36.3%), D dimer 493 nd/mL, C-reactive protein 37.9 mg/dL, and hemoglobin 11.0 g/dL. Lung CT showed medium (between 25 and 50%) hyperdense areas in both lungs. rRT-PCR for SARS-CoV-2 yielded positive result. The patient was admitted to ICU and treated with warfarin sodium 2.5 mg, AAS 100 mg, and axetilcefuroxima 500 mg. The oral care team consultation identified a 2.0-cm ulcer on the upper lip associated with soft tissue necrosis (Figure 2A). The lesion developed after tube-related trauma, 9 days after OTI. Lip necrosis was observed 2 days after the first ulcer (Figure 2B). The team initiated the oral care and PBM protocol. Two days into therapy, the lip healed but lost soft tissue substance (Figure 2C). The overall health status of the patient worsened, and the patient died.

Discussion

The use of PBM for the treatment of traumatic injuries in patients in ICU is not well reported. This is the first paper, to our knowledge, to document a successful protocol used

Fig. 2 A 3.0-cm ulcer on the upper lip



for this purpose, with an 80.4% rate of ulcers remission. Other authors have reported using PBM and antimicrobial photodynamic therapy (aPDT) for the management of oral lesions in COVID-19 patients. For example, Ramires et al. treated a patient with extensive upper and lower lip lesions after extubating with 2 days of aPDT and 1 day of PBM, with complete wound healing after 4 days of treatment [19]. Teixeira et al. reported a case series of four hospitalized patients with COVID-19, also treated with association of PBM and aPDT. None of the cases reported related to intubated patients [20].

Regarding medical devices-related oral ulcers, Siotos et al. described a case of a COVID-19 patient intubated for 16 days, and intermittently for 10 days in prone position [9]. After extubating, an extensive upper lip lesion was observed and surgically closed. The author also conducted a literature review that showed that these events are alarmingly underreported and discussed treatment alternatives such as use of topical corticosteroids, PBM, and relocation of tube fixation [9].

The present study evaluated the outcomes of the implementation of an oral care protocol and the use of PBM therapy to manage patients with COVID-19 infection in the ICU. Oral traumatic injuries are one of the most frequent changes in the oral cavity of patients with COVID-19 with OTI [16]. We speculate that traumatic injuries occur during the intubation or the extubation process, but also can result from the prolonged time that these patients may remain intubated in the ICU, as reported previously by Hocková et al. [16]. It is known that severely ill COVID-19-infected individuals are admitted in the ICU and may require to be in a prone position to improve oxygenation [12]. This position may lead the intubation tube exert excessive and prolonged pressure on the upper lip [13–16]. The frequent use of corticosteroids, anticoagulants, and high doses of vasoactive drugs to treat these individuals may contribute to the development of the oral lesions, associated with deficient oxygenation

of peripheral tissues [9, 13, 14, 16] and raise the question if these factors could also mitigate tissue healing. In this context, PBM could be helpful to promote angiogenesis and improve tissue oxygenation [21], and play an important role to improve these oral lesions healing and prevent oral mucosal necrosis. It is also why we believe that OTI-related traumatic injuries prognosis could be much better with the oral care protocol associated with the PBM treatment, instead of the oral care protocol alone.

Our experience shows that the initial manifestation of these lesions presents as hematoma or erythema, progressing to large areas of ulceration and extensive tissue loss (Figure 3). These lesions in COVID-19 patients develop rapidly, requiring immediate diagnosis and treatment. Ulcerated lesions increase the risk of secondary infection and may increase the risk of bacterial and/or viral aspiration pneumonia in patients on mechanical ventilation, increasing the morbidity of COVID-19 and the risk of sepsis [22].

The present study shows the importance of an oral care team to participate actively in the care of these patients. Previous work with hospitalized patients and the effective use of oral care lead us to develop the proposed protocol to care for the COVID-19-infected individuals in the ICU [10]. The presence of oral medicine specialists in the ICU is of utmost importance in the early diagnosis of oral cavity complications [16], immediate implementation of a daily oral care protocol, and the use of PBM [19]. We demonstrated that this protocol decreases the risk of infection, inflammation, and stimulate the rapid healing of oral lesions, decreasing the morbidity that oral lesions can cause.

A study limitation can be assumed, regarding any retrospective study, eventually relying on well reported medical records. Also, as an observational study without a control/placebo group, there were some aspects of the PBM protocol that could not be evaluated in this study.

We were able to show that the proposed protocol could prevent the progress of traumatic lesions associated with

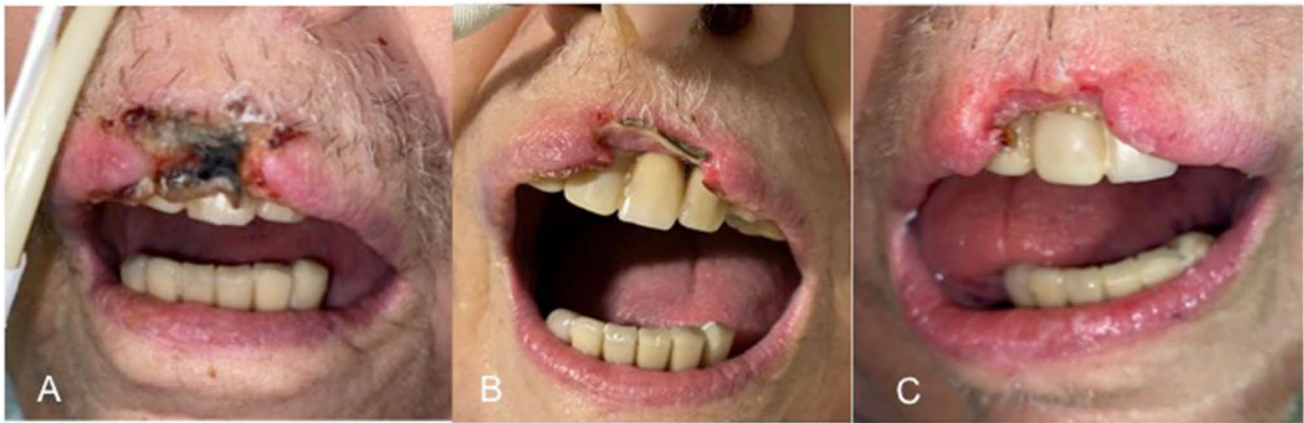

Fig. 3 A 2.0-cm ulcer on the upper lip

IOT into extensive ulcerated lesions, necrosis, and the loss of tissue. Such lesions can lead to disfiguration, difficulty of speech and eating, affecting the quality of life of these patients [16]. Furthermore, large areas of oral ulcers in immunocompromised patients can increase the risk of life-threatening systemic infections.

Therefore, being able to early diagnose these complications and treat them with effective protocols is of great importance. We also demonstrated the efficacy of PBM therapy in the control of inflammation and in stimulating healing. In our experience, the use of low-intensity lasers was very effective using the parameters reported in the study. The PBM technology played an important role in reducing the clinical signs of oral lesions. We believe that these actions, associated with hydration of the oral and labial mucosa with vitamin E, and the adjustment of the tube position, prevented the development of traumatic injuries from lip compression. We hope that our experience will contribute to the improvement of care of COVID-19-infected individuals with severe illness and in care at the ICU, especially those intubated and in a prone position.

Conclusion

The results of this observational study suggest that the availability of oral medicine specialists to routinely participate in the care of patients admitted to the ICU with COVID-19 is instrumental in the early diagnosis of oral complications. These providers can implement effective oral care protocol and the use of PBM when indicated. They can focus on immediate treatment of patients, mitigating the possibility of severe complications that affect the quality of life of these individuals.

Acknowledgements All authors gave their final approval and agreed to be accountable for all aspects of the work.

Declarations

Ethics approval The Albert Einstein Hospital ethics committee approved the protocols for this project (Proc. 37760820.0.0000.0071).

Conflict of interest The authors declare no competing interests.

References

1. Li X, Ma X. Acute respiratory failure in COVID-19: is it “typical” ARDS? *Crit Care* [Internet]. 2020 Dec 6;24(1):198. Available from: <https://ccforum.biomedcentral.com/articles/https://doi.org/10.1186/s13054-020-02911-9>
2. Cruz Tapia RO, Peraza Labrador AJ, Guimaraes DM, Matos Valdez LH. Oral mucosal lesions in patients with SARS-CoV-2 infection. Report of four cases. Are they a true sign of COVID-19 disease? *Spec Care Dent*. 2020;(July):1–6.
3. Brandão TB, Gueiros LA, Melo TS, Prado-Ribeiro AC, Nesralah ACFA, Prado GVB et al (2020) Oral lesions in patients with SARS-CoV-2 infection: could the oral cavity be a target organ? *Oral Surg Oral Med Oral Pathol Oral Radiol* 00(00):1–7
4. Amorim dos Santos J, Normando AGC, Carvalho da Silva RL, De Paula RM, Cembranel AC, Santos-Silva AR, et al. Oral mucosal lesions in a COVID-19 patient: new signs or secondary manifestations? *Int J Infect Dis*. 2020;97:326–8.
5. Soares C, Carvalho R, Carvalho K, Carvalho M, Almeida O. Letter to editor: oral lesions in a patient with Covid-19. *Med Oral Patol Oral y Cir Bucal* [Internet]. 2020;25(4):e563–4. Available from: <http://www.medicinaoral.com/medoralfree01/aop/24044.pdf>
6. Fidan V, Koyuncu H, Akin O. Oral lesions in Covid 19 positive patients. *Am J Otolaryngol* [Internet]. 2021 May;42(3):102905. Available from: <https://linkinghub.elsevier.com/retrieve/pii/S0196070921000065>
7. Tomo S, Miyahara GI, Simonato LE. Oral mucositis in a SARS-CoV-2-infected patient: secondary or truly associated condition? *Oral Dis* [Internet]. 2020 Aug 6;odi.13570. Available from:

- <https://onlinelibrary.wiley.com/doi/abs/https://doi.org/10.1111/odi.13570>
8. Brandini DA, Takamiya AS, Thakkar P, Schaller S, Rahat R, Naqvi AR. Covid-19 and oral diseases: crosstalk, synergy or association? *Rev Med Virol*. 2021;(January):1–15.
 9. Siotos C, Bonett AM, Hansdorfer MA, Siotou K, Kambeyanda RH, Dorafshar AH. Medical device related pressure ulcer of the lip in a patient with COVID-19: case report and review of the literature. *J Stomatol Oral Maxillofac Surg* [Internet]. 2020 Oct;(January). Available from: <https://linkinghub.elsevier.com/retrieve/pii/S2468785520302329>
 10. Bezinelli LM, Eduardo F de P, Ferreira MH, Gobbi MF, Castro FG, Santos GMASA, et al. Severe acute respiratory syndrome coronavirus 2 and herpesvirus in oral lesions in patients with severe coronavirus disease 2019: viral interaction? *J Dermatol* [Internet]. 2021 May 25;1346-8138.15964. Available from: <https://onlinelibrary.wiley.com/doi/https://doi.org/10.1111/1346-8138.15964>
 11. La Rosa GRM, Libra M, De Pasquale R, Ferlito S, Pedullà E. Association of viral infections with oral cavity lesions: role of SARS-CoV-2 infection. *Front Med* [Internet]. 2021 Jan 14;7. Available from: <https://www.frontiersin.org/articles/https://doi.org/10.3389/fmed.2020.571214/full>
 12. Meng L, Qiu H, Wan L, Ai Y, Xue Z, Guo Q, et al. Intubation and ventilation amid the COVID-19 outbreak: Wuhan's experience. *Anesthesiology*. 2020;(Xxx):1317–32.
 13. Alsiddiky A (2011) Lip necrosis as a complication of a prone position in scoliosis surgery. *Sultan Qaboos Univ Med J* 11(2):273–275
 14. Perrillat A, Foletti JM, Lacagne AS, Guyot L, Graillon N. Facial pressure ulcers in COVID-19 patients undergoing prone positioning: how to prevent an underestimated epidemic? *J Stomatol Oral Maxillofac Surg* [Internet]. 2020;121(4):442–4. Available from: <https://doi.org/10.1016/j.jormas.2020.06.008>
 15. Challoner T, Vesel T, Dosanjh A, Kok K. The risk of pressure ulcers in a proned COVID population. *Surg* [Internet]. 2021 Aug; Available from: <https://linkinghub.elsevier.com/retrieve/pii/S1479666X21001219>
 16. Hocková B, Riad A, Valky J, Šulajová Z, Stebel A, Slávik R et al (2021) Oral complications of ICU patients with COVID-19: case-series and review of two hundred ten cases. *J Clin Med* 10(4):1–13
 17. Black JM, Cuddigan JE, Walko MA, Didier LA, Lander MJ, Kelpel MR. Medical device related pressure ulcers in hospitalized patients. *Int Wound J* [Internet]. 2010 Oct;7(5):358–65. Available from: <https://onlinelibrary.wiley.com/doi/https://doi.org/10.1111/j.1742-481X.2010.00699.x>
 18. Bezinelli LM, Corrêa L, Vogel C, Kutner JM, Ribeiro AF, Hamerschlak N, et al. Long-term safety of photobiomodulation therapy for oral mucositis in hematopoietic cell transplantation patients: a 15-year retrospective study. *Support Care Cancer* [Internet]. 2021 Nov 22;29(11):6891–902. Available from: <https://doi.org/10.1007/s00520-021-06268-9>
 19. Ramires MCC, Mattia MB, Tateno RY, Palma LF, Campos L. A combination of phototherapy modalities for extensive lip lesions in a patient with SARS-CoV-2 infection. *Photodiagnosis Photodyn Ther* [Internet]. 2021;33(January):102196. Available from: <https://doi.org/10.1016/j.pdpdt.2021.102196>
 20. Teixeira IS, Leal FS, Tateno RY, Palma LF, Campos L. Photobiomodulation therapy and antimicrobial photodynamic therapy for orofacial lesions in patients with COVID-19: a case series. *Photodiagnosis Photodyn Ther* [Internet]. 2021 Jun;34(February):102281. Available from: <https://linkinghub.elsevier.com/retrieve/pii/S1572100021001071>
 21. Basso FG, Soares DG, Pansani TN, Cardoso LM, Scheffel DL, de Souza Costa CA, et al. Proliferation, migration, and expression of oral-mucosal-healing-related genes by oral fibroblasts receiving low-level laser therapy after inflammatory cytokines challenge. *Lasers Surg Med* [Internet]. 2016 Dec;48(10):1006–14. Available from: <https://onlinelibrary.wiley.com/doi/https://doi.org/10.1002/lsm.22553>
 22. Le Balc'h P, Pinceaux K, Pronier C, Seguin P, Tadié JM, Reizine F. Herpes simplex virus and cytomegalovirus reactivations among severe COVID-19 patients. *Crit Care*. 2020;24(1):1–3.

Publisher's note Springer Nature remains neutral with regard to jurisdictional claims in published maps and institutional affiliations.