



Published in final edited form as:

Am J Med Case Rep. 2020 ; 8(12): 478–480. doi:10.12691/ajmcr-8-12-12.

Pseudoaneurysm of the Mitral-Aortic Fibrosa in the Absence of Valvulitis

Harshith Chandrakumar¹, Yuvraj Singh Chowdhury², Basil Elamir¹, Anoop Puskoor¹, Mrinali Shetty³, Krunal H. Patel¹, Azizul Rehman², Vaibhavi Uppin², Moro O. Salifu¹, Samy I. McFarlane^{1,*}

¹Department of Internal Medicine, State University of New York, Downstate- Health Science University, Brooklyn, NY, USA - 11203

²Division of Cardiovascular Disease, State University of New York, Downstate- Health Science University, Brooklyn, NY, USA - 11203

³Division of Cardiovascular Disease, University of Chicago (NorthShore), Evanston, IL, USA - 60201

Abstract

The mitral-aortic intervalvular fibrosa (MAIVF) is the thin avascular fibrous structure located between the left side of the non-coronary cusp, the left coronary cusp and the anterior mitral leaflet. MAIVF pseudoaneurysm typically results as a complication of endocarditis, aortic valve surgery or chest trauma. We present a case of an incidental MAIF pseudoaneurysm in a 68-year female with a history of rheumatic fever without involvement of the mitral apparatus. We also discuss the presentation, evaluation and management of this rather rare valvular disorder.

Keywords

mitral-aortic intervalvular fibrosa; mitral valve; rheumatic fever; thrombus; anticoagulation; endocarditis

1. Introduction

The mitral aortic intervalvular fibrosa (MAIVF) is a thin fibrous tissue located between the aortic and mitral valves. It forms a junction between the left half of the non-coronary cusp, the adjacent left coronary cusp of the aortic valve and the anterior leaflet of the mitral valve [1]. The roof comprises pericardium and the ventricular side serves as the posterior surface of the left ventricular outflow tract (LVOT). It is a relatively avascular structure making it prone to insults from infection and surgical trauma. Pseudoaneurysm of the mitral aortic intervalvular fibrosa (P-MAIVF) is an uncommon, potentially serious condition occurring as a sequela of various etiologies including aortic valve endocarditis, valvular surgeries and

chest trauma [2,4]. It is usually discovered on Trans-Thoracic Echocardiography (TTE) and confirmed with a Trans-Esophageal Echocardiogram (TEE) or Computed Tomography (CT) angiography. Here in, we report a unique case of incidental MAIVF pseudoaneurysm in a patient with a history of rheumatic fever without affliction of the mitral apparatus.

2. Case Report

A 68-year female with history of COPD, rheumatic fever, and current 30 pack year smoker was brought into the Emergency Department (ED) for worsening shortness of breath for 7 days which was accompanied by a productive cough as well as new onset confusion. She had no history of prior chest trauma, infective endocarditis or cardiac surgery.

On presentation to the ED her blood pressure (BP) was 86/58 mm of Hg, heart rate (HR) was 112 beats per minute (bpm), temperature was 97.4 F, with an oxygen saturation of 78% on room air and a respiratory rate of 24 per minute. On examination she appeared in moderate respiratory distress sitting up in the bed holding on to the railings. She had flaring of her alae nasi and prominent sternocleidomastoid muscles with poor air entry bilaterally. Chest X ray (CXR) demonstrated hyper inflated lungs and mild pulmonary vascular congestion. Electrocardiogram (ECG) showed nonspecific ST-T wave changes. Her symptoms were attributed to exacerbation of her underlying chronic obstructive pulmonary disease (COPD). Patient was placed on BiPAP @ 50% FiO₂, fluids, nebulizers, vancomycin, aztreonam and methylprednisone. Patient was later intubated for increasing respiratory distress and was eventually extubated. On Day 2, patient developed A-Fib w/ RVR (ChadsVAsc 2) and was started on a Cardizem Drip and Eliquis 5mg BID and eventually converted to Sinus on Day 4 with Amiodarone and Digoxin.

A TTE was obtained and demonstrated an ejection fraction of 60%, grade II diastolic dysfunction, mild mitral regurgitation, normal aortic valve and a 4 × 4 cm pulsatile echolucent structure at the junction of the base of anterior mitral leaflet, the top of interatrial septum and non-coronary leaflet of aortic valve that filled during systole (Figure 1). There was no evidence of rheumatic involvement of the mitral apparatus or the aortic valve. TEE demonstrated echo density in the MAIVF pseudo aneurysm. A cardiac CT showed the pseudoaneurysm with a contained thrombus. Blood cultures had no growth at 5 days. After resolution of her COPD exacerbation, the patient was evaluated by Cardiothoracic surgery, but refused a surgical evaluation and was managed conservatively with anticoagulation.

3. Discussion

The first case of P - MAIVF was reported by Waldhausen *et al* in 1966 [3]. By 2009, 89 cases had been reported [4] which grew to approximately 166 cases in 2014 noted by Sahan *et al* [4]. The entity is being increasingly recognized from broadened awareness and feasibility of diagnostic modalities. P-MAIVF can occur secondary to infection, valvular intervention, chest wall trauma or congenital etiologies. Sahan *et al* reported that 40% of patients had active endocarditis, with 18% having had a prior history of endocarditis. Aortic valve surgeries have a higher predisposition than mitral valve [4]. Other interventions like cardiac catheterization ventricular septal defect repair near the area can also result in P-

MAIVF [4]. Congenital heart diseases like septal defects, coarctation of aorta, bicuspid aortic valve could be present [5]. Other causes include abscesses, Takayasu arteritis, rheumatic carditis, aortic regurgitation [6,7]. Till date, there have been only two reported cases of P-MAIVF occurrence with rheumatic heart disease [8,9]. Our patient had a history of rheumatic fever without valvulitis and the symptoms were attributed to exacerbation of underlying lung disease rather than from valvular decompensation.

It has been postulated that aortic valve endocarditis predisposes MAIVF to pseudoaneurysm commonly from 1) direct extension of infection through the aortic wall or 2) indirectly through increased aortic regurgitant jet pressure striking the walls. The avascular nature renders it more prone to infection, leading to subaortic abscesses [1,7]. In patients with aortic valve surgery, local traction and trauma can lead to disruption of the MAIVF over time, eventually leading to pseudo aneurysm, even without signs of infection. Bicuspid aortic valve is more susceptible to trauma likely from congenital weakness in the MAIVF region [2]. The commonly reported clinical features include shortness of breath, signs and symptoms of heart failure, active infection (from infective endocarditis), chest pain, atypical angina. Some remain to be asymptomatic where the pseudoaneurysm is incidentally diagnosed, like in our case [2,4]. Uncommonly, cerebrovascular accidents and embolic events have been recorded [10].

Echocardiography is the primary modality of interpretation. The pseudoaneurysm appears as a false lumen below the AV annulus at the level of MAIVF. The pulsatile nature of the cavity with expansion during systole and collapse during diastole is characteristic [2]. During systole, the blood moves into the pseudoaneurysm, but during diastole the blood flows back into the LVOT. This finding can be blunted in the case of a fistulous communication between the atrial and ventricular cavity [11]. CT angiography is advantageous in the evaluation of valvular structures, atherosclerotic plaque and precise location of pseudoaneurysm [11]. Cardiac CT and magnetic resonance imaging (MRI) can further delineate the lesions. In our patient, TTE demonstrated the presence of P-MAIVF and a thrombus in the same cavity confirmed by cardiac CT.

In our case, the patient was managed for the exacerbation of COPD. After detailed discussion, patient refused surgical intervention and decided to follow up outpatient. The prognostication after conservative management is unclear as most patients after diagnosis, be it asymptomatic or symptomatic end up having surgical intervention. But, recently there has been case reports addressing survival from non-surgical intervention. Gin et al reported a series of 3 patients with history of valve surgeries and P-MAIVF with no intervention. These patients were followed up for an average of 5 years with good tolerance, except one who died due to non-cardiac causes [12]. Chieppa *et al*/reported a case of conservative management for 9 years who remained in stable condition [13].

Surgical management is recommended in complicated, symptomatic patients to prevent further expansion of pseudoaneurysm. Aortic valve or aortic root replacement, pseudoaneurysmal resection and repair have been performed [14]. When coronary arteries are involved, coronary artery bypass grafting may be required, potentially leading to cardiac transplantation in one case [15]. Untreated P- MAIVF can lead to severe complications,

including 1) slow enlargement of pseudoaneurysm leading compression of surrounding structures 2) rupture into the pericardium causing cardiac tamponade 3) rupture into left atrium causing a fistulous connection between the left atrium and ventricle with simultaneous mitral regurgitation 4) dissection 5) thromboembolism leading to CVA 6) worsening heart failure [2,7].

Although, our patient denied any surgical intervention, careful and frequent monitoring is imperative. Currently, there are no guidelines regarding the frequency of surveillance on asymptomatic patients and should be decided on a case-by case basis. It should also be kept in mind that surgical correction is not the end of management. Procedural complications are challenging. De oliveira *et al* looked at patients with surgical correction of P-MAIVF, of which 10 % had intra operative mortality and the 10-year survival rate was 50% [16].

4. Conclusion

Pseudoaneurysm of mitral aortic intervalvular fibrosa is a serious complication particularly recognized in patients with endocarditis, valvular surgeries, bicuspid aortic valve, rheumatic heart disease. When symptomatic, these patients can acutely decompensate requiring surgical correction. While most asymptomatic patients end up with surgical correction, the clinical course and surveillance of conservative management is yet to be clearly elucidated. Valvulitis is often seen as a sequelae of acute rheumatic fever and established valvular disease regarded a risk factor for infective endocarditis. MAIF pseudoaneurysm in patients with a history of rheumatic fever have been traditionally ascribed to one of these etiologies. Our case represents an incidentally discovered MAIVF pseudoaneurysm as an isolated manifestation in the absence of any valve involvement or infection and questions if rheumatic carditis may complicate into a MAIF pseudoaneurysm.

Acknowledgements

This work is supported, in part, by the efforts of Dr. Moro O. Salifu MD, MPH, MBA, MACP, Professor and Chairman of Medicine through NIMHD Grant number S21MD012474.

References

- [1]. Han J, He Y, Gu X, Sun L, Zhao Y, Liu W et al. Echocardiographic Diagnosis and Outcome of Pseudoaneurysm of the Mitral-Aortic Intervalvular Fibrosa: Results of a Single-Center Experience in Beijing. *Medicine (Baltimore)*. 2016 3; 95(11): e3116. [PubMed: 26986160]
- [2]. ahan E, Gül M, ahan S, Sokmen E, Guray YA, & Tufekçioglu O. Pseudoaneurysm of the mitral-aortic intervalvular fibrosa. *Herz*, 2014 11; 40(S2), 182–189. [PubMed: 25468033]
- [3]. Waldhausen JA, Petry EL, Kurlander GJ. Successful repair of subvalvular annular aneurysm of the left ventricle. *N Engl J Med* 1966; 3: 984–7.
- [4]. Sudhakar S, Sewani A, Agrawal M, Uretsky BF. Pseudoaneurysm of the mitral-aortic intervalvular fibrosa (MAIVF): A comprehensive review. *J Am Soc Echocardiogr*. 2010; 23(10): 1009–1112. [PubMed: 20868952]
- [5]. Gelehrter S, Wright G, Gless T et al. (2002) Left ventricular outflow tract pseudoaneurysms in congenital heart disease. *Am J Cardiol* 90(7): 806–809. [PubMed: 12356409]
- [6]. Tufekcioglu O, Ozlu MF, Cay S, Tuna F, Basar N, Gurel OM, et al. Pseudoaneurysm of the mitral-aortic intervalvular fibrosa in a patient with Takayasu's arteritis. *Can J Cardiol*. 2008 9; 24(9): 718. [PubMed: 18787725]

- [7]. Bansal RC, Graham BM, Jutzy KR, Shakudo M, Shah PM. Left ventricular outflow tract to left atrial communication secondary to rupture of mitral-aortic intervalvular fibrosa in infective endocarditis: diagnosis by transesophageal echocardiography and color flow imaging. *J Am Coll Cardiol.* 1990; 15(2): 499–504. [PubMed: 2299090]
- [8]. Parakh N, Yadav N, Kathuria S, Chaturvedi V, Trehan V, Tyagi S. Pseudo-aneurysm of mitral aortic intervalvular fibrosa: two case reports. *Indian Heart J.* 2013 Jan-Feb; 65(1): 100–3. [PubMed: 23438623]
- [9]. Fazlinezhad A, Fatehi H, Tabaee S, Alavi M, Hoseini L, Yousefzadeh H. Pseudoaneurysm of mitro-aortic intervalvular fibrosa during the course of mitral valve endocarditis with aorto-left ventricle outflow tract fistula. *J Saudi Heart Assoc.* 2012 7; 24(3): 201–4. [PubMed: 23960696]
- [10]. Koch R, Kapoor A, Spencer KT., Stroke in patient with an intervalvular fibrosa pseudoaneurysm and aortic pseudoaneurysm. *J Am Soc Echocardiogr.* 2003 8; 16(8): 894–6. [PubMed: 12879001]
- [11]. Mittal K, Agrawal R, Dey AK, Gadewar R, Dadhania D, Hira P. Pseudoaneurysm Arising from Mitral Aortic Intervalvular Fibrosa (P-MAIVF) Communicating with Left Atrium (LA): Multiple Detector Computed Tomography (MDCT) Evaluation. *Pol J Radiol.* 2015 2 17; 80: 85–8. [PubMed: 25745522]
- [12]. Gin A, Hong H, Rosenblatt A, Black M, Ristow B, & Popper R (2011). Pseudoaneurysms of the mitral-aortic intervalvular fibrosa: Survival without reoperation. *American Heart Journal*, 161(1), 130.e1–130.e5. [PubMed: 21167344]
- [13]. Rosario Chieppa DR, Scardigno AD, Deluca G, Capodivento S, Quinto N, Cicala M. Conservative treatment of a pseudoaneurysm of the mitral-aortic intervalvular fibrosa: 9 years of follow-up. *G Ital Cardiol (Rome).* 2017; 18(6): 525–528. [PubMed: 28631767]
- [14]. Saeed G, Lips S, Neuzner J. Surgical treatment of a mitral-aortic intervalvular fibrosa pseudoaneurysm. *Asian Cardiovasc Thorac Ann.* 2015; 23(4): 496–497. [PubMed: 25740021]
- [15]. Almeida J, Pinho P, Torres JP et al. (2002) Pseudoaneurysm of the mitral-aortic fibrosa: myocardial ischemia secondary to left coronary compression. *J Am Soc Echocardiogr* 15(1): 96–98 [PubMed: 11781563]
- [16]. De Oliveira NC, David TE, Armstrong S, Ivanov J. Aortic and mitral valve replacement with reconstruction of the intervalvular fibrous body: an analysis of clinical outcomes. *J Thorac Cardiovasc Surg.* 2005; 129(2): 286–290. [PubMed: 15678037]

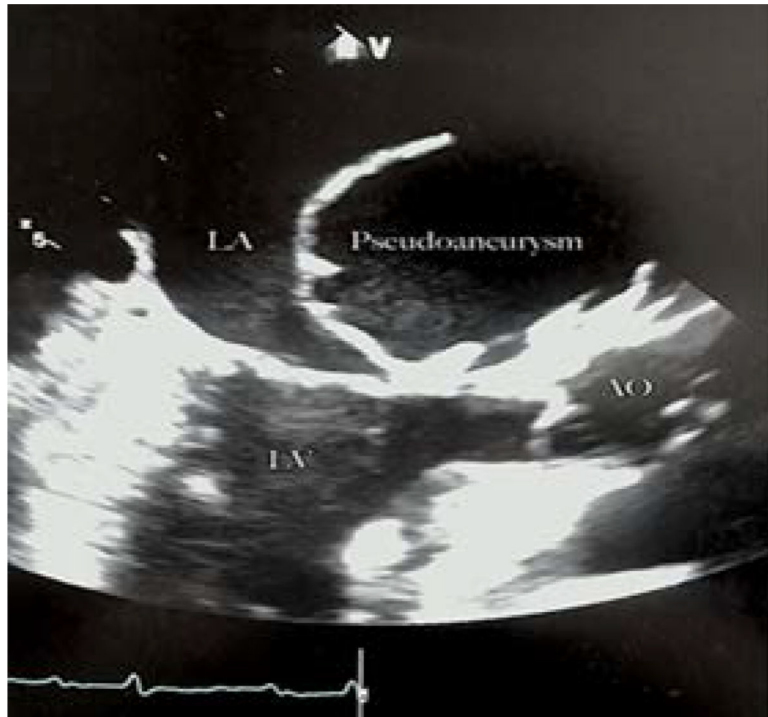


Figure 1.
Mitral-Aortic Intervalvular Fibrosa Pseudoaneurysm

Author Manuscript

Author Manuscript

Author Manuscript

Author Manuscript