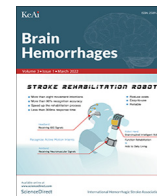




Since January 2020 Elsevier has created a COVID-19 resource centre with free information in English and Mandarin on the novel coronavirus COVID-19. The COVID-19 resource centre is hosted on Elsevier Connect, the company's public news and information website.

Elsevier hereby grants permission to make all its COVID-19-related research that is available on the COVID-19 resource centre - including this research content - immediately available in PubMed Central and other publicly funded repositories, such as the WHO COVID database with rights for unrestricted research re-use and analyses in any form or by any means with acknowledgement of the original source. These permissions are granted for free by Elsevier for as long as the COVID-19 resource centre remains active.



Clinical research

Vertebral artery dissecting aneurysm rupture under severe COVID-19

Takenori Sato, Yoichi Miura, Ryuta Yasuda, Naoki Toma, Hidenori Suzuki*

Department of Neurosurgery, Mie University Graduate School of Medicine, Tsu, Japan



ARTICLE INFO

Article history:

Received 27 June 2022

Received in revised form 29 July 2022

Accepted 9 August 2022

Available online 12 August 2022

Keywords:

SARS-CoV-2

COVID-19

Subarachnoid hemorrhage

Vertebral artery dissecting aneurysm

ABSTRACT

Objective: We report a rare case of subarachnoid hemorrhage (SAH) caused by a ruptured vertebral artery (VA) dissecting aneurysm (DA) under severe COVID-19 treatment, and discuss the potential relationships. **Case presentation:** A 58-year-old woman with COVID-19 fell into severe pneumonia needing mechanical ventilation at 10 days post-onset (day 10). The patient had no risk factors for DA or stroke other than COVID-19 infection. At day 17 when weaning ventilatory management, her systolic blood pressure was transiently elevated, and her consciousness did not recover thereafter. Computed tomography (CT) at day 21 revealed SAH with modified Fisher grade 4, and CT angiography revealed a DA in the right VA just distal to the right posterior inferior cerebellar artery (PICA). The DA was treated emergently with internal trapping by endovascular coiling, while the right PICA was preserved. Postoperative course was uneventful, and 2-time negative SARS-CoV-2 PCR results were obtained at day 45. The patient recovered to 4-month modified Rankin Scale 2.

Conclusions: Although it is not clear from the present case alone whether SARS-CoV-2 infection causes SAH by a ruptured VA DA, the accumulation of more cases and further studies are warranted to clarify the relationships between SARS-CoV-2 infection and ruptured intracranial DAs.

© 2022 International Hemorrhagic Stroke Association. Publishing services by Elsevier B.V. on behalf of KeAi Communications Co. Ltd. This is an open access article under the CC BY-NC-ND license (<http://creativecommons.org/licenses/by-nc-nd/4.0/>).

1. Introduction

The COVID-19 pandemic continues to spread around the world. SARS-CoV-2 infection is known to cause a hypercoagulable state,¹ sometimes associated with ischemic stroke.² Non-aneurysmal subarachnoid hemorrhage (SAH) is rarely complicated, and aneurysmal SAH is even less.³ Even if the rate of infections that trigger aneurysmal SAH is uncommon, the potentially serious neurological sequela needs investigating the clinical characteristics of the disease under COVID-19 infections. We here report a case of SAH caused by vertebral artery (VA) dissecting aneurysm (DA) rupture during treatment for COVID-19.

2. Case presentation

A 58-year-old Hispanic woman with a history of one-dose COVID-19 mRNA vaccination and colon cancer presented with dysgeusia and dyspnea by COVID-19. The patient was treated for colon cancer at the age of 56 and had no recurrence since. She had nei-

ther obvious risk factors for atherosclerosis and DA nor COVID-19 aggravating factors such as obesity, smoking, hypertension, dyslipidemia, diabetes mellitus, trauma and other certain diseases.

At 10 days post-onset (day 10), the patient was admitted to our hospital to treat pneumonia needing mechanical ventilation. The patient was deeply sedated under continuous administration of midazolam, fentanyl and rocuronium bromide, and her blood pressure was relatively stable without antihypertensive medication. Pneumonia caused by COVID-19 was treated with antiviral (favipiravir and remdesivir) and anti-inflammatory (dexamethasone and tocilizumab) drugs, and gradually improved. Although there were no other complications associated with COVID-19, apixaban was administered enterally to prevent deep vein thrombosis. At day 16, for the purpose of weaning from mechanical ventilation, the anesthetics were changed to a combination of dexmedetomidine hydrochloride and propofol, and continuous intravenous administration of nicardipine was started to avoid an increase in blood pressure. At day 17, however, her systolic blood pressure suddenly increased to 200 mmHg several hours pre-extubation, followed by serum D-dimer value elevation (4.0 to 8.9 µg/dl) on the following day. At day 21, computed tomography (CT) scans taken for persistent conscious disorder revealed severe pneumonia and SAH with modified Fisher grade 4 (Figs. 1 and 2). CT angiography revealed a DA in the V4 segment of the right VA.

* Corresponding author at: Department of Neurosurgery, Mie University Graduate School of Medicine, 2-174 Edobashi, Tsu, Mie 514-8507, Japan.

E-mail address: suzuki02@med.mie-u.ac.jp (H. Suzuki).

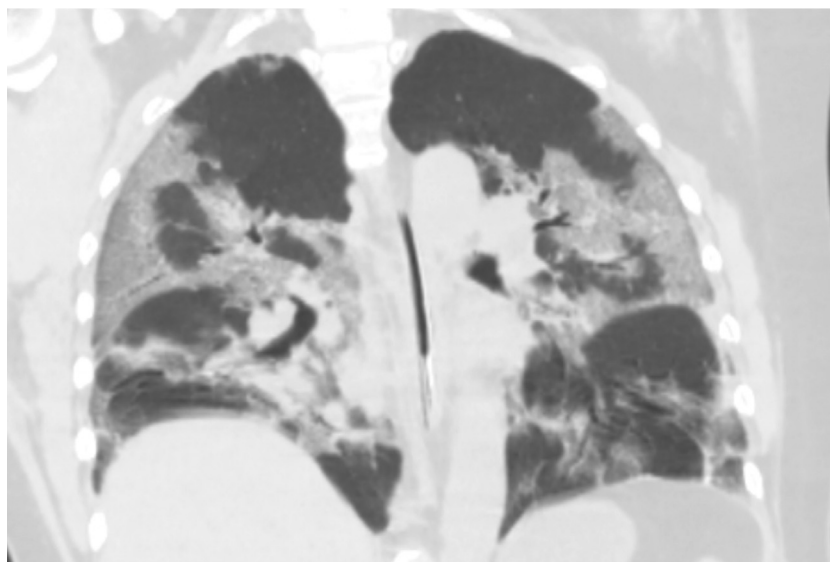


Fig. 1. Chest computed tomography at 21 days after COVID-19 onset (day 21) showing multiple lung frosted shadows.

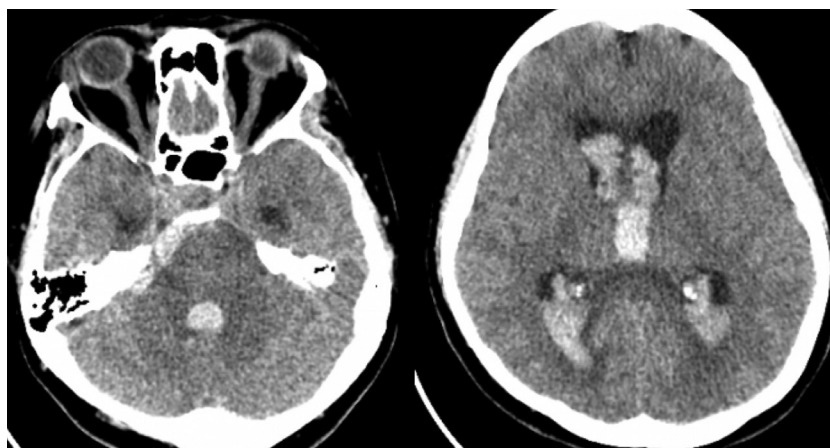


Fig. 2. Head computed tomography at 21 days after COVID-19 onset (day 21) showing subarachnoid hemorrhage with intraventricular hematomas and ventriculomegaly.

After performing emergency bilateral ventricular drainage, cerebral angiography was performed. The angiography revealed a DA distal to the origin of posterior inferior cerebellar artery (PICA) in the right VA (Fig. 3A-B), and the left VA was well developed. Thus, it was decided to perform emergency endovascular internal

trapping of the right VA DA. Under general anesthesia, a 6-French guiding catheter was placed into the proximal right VA, and a microcatheter was advanced into the dilated segment of the VA. The VA DA was completely obliterated with eight coils and the right PICA was preserved (Fig. 3C). The contralateral left

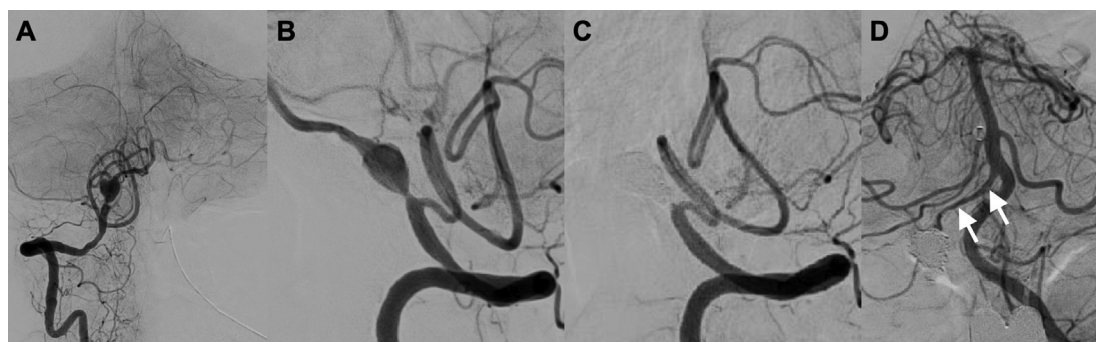


Fig. 3. Digital subtraction angiography of the right vertebral artery (VA; A-C) and the left VA (D) at day 21. A VA dissecting aneurysm (DA) is shown at just distal to the right posterior inferior cerebellar artery (A, anteroposterior view; B, lateral view), and disappears after internal trapping by endovascular coiling (C, lateral view). Left VA angiogram shows a retrograde blood flow into the right VA (white arrows) just distal to the obstructed VA DA (D).

VA sufficiently perfused the basilar artery, and anterior spinal artery originating from the right VA was also preserved (Fig. 3D).

Postoperative course was uneventful with neither delayed cerebral ischemia nor shunt-dependent hydrocephalus. The quarantine was lifted at day 45 after 2-time negative SARS-CoV-2 PCR results. She was discharged to rehabilitation at day 51 and recovered to 4-month modified Rankin Scale 2.

3. Discussion

The impact of COVID-19 pandemic on SAH is unclear, but SARS-CoV-2 infection may induce arterial dissection.⁴ So far, more than 40 cases of multisite arterial dissections have been reported in COVID-19 patients without any antecedent causes: aortic dissection was the most common (52.3 %), followed by coronary artery dissection (23.8 %), and less common cerebral and vertebral artery dissections (7.1 % each) mostly caused intracerebral hemorrhage or ischemic stroke.⁵ Although the present case associated with DA-induced SAH did not show the direct evidence linking a DA with COVID-19, the patient had no predisposing factors of DA development including smoking, trauma, a particular genetic background, certain diseases such as Ehlers-Danlos or Marfan diseases, and infectious or inflammatory diseases other than COVID-19.⁶ In addition to systemic inflammation, it has been reported that blood pressure fluctuations by a severe cough and invasive ventilator support, and anticoagulation or coagulopathy may trigger SAH secondary to COVID-19 infection,^{7,8} but those factors did not appear to apply in this case.

Several studies reported that the number of acute stroke admissions declined under the COVID-19 pandemic compared with the pre-pandemic period, including or except for SAH.^{9,10} The reasons remain speculative, but may include social isolation, infection control practices, hospital avoidance behavior, overwhelmed health-care systems, and a real decrease in stroke incidence.^{9,10} Although there is a logical premise for host immune responses to COVID-19 to promote vascular endothelial dysfunction and inflammation via the angiotensin-converting enzyme II receptors, the influence of SARS-CoV-2 infection on cerebral aneurysm pathology and rupture risk remains unknown and the events might be a coincidence.^{7,11} However, even though the risk of SAH is not increased in COVID-19 – positive patients, the outcomes are generally worse compared with patients with SAH without COVID-19 and patients with COVID-19 without SAH, likely due to higher frequency of systemic comorbidities.¹² Thus, a high degree of suspicion in diagnosing such a rare complication as a DA is pertinent for timely management.

Although rare, the ratio of DA-induced SAH to saccular aneurysmal SAH may increase under COVID-19, from up to a few percent in COVID-19 – negative patients to almost equivalent in COVID-19 – positive patients.¹¹ The pathophysiology of DAs differs from saccular aneurysms as it involves a defect in the internal elastic lamina followed by mural dissection and pseudoaneurysm formation. As far as we know, 8 cases of DA-induced SAH have been reported in – COVID-19 – positive patients: internal carotid artery, 1; anterior communicating artery, 1; VA, 1; PICA, 3; posterior cerebral artery, 1; and pericallosal artery, 1.^{2,11,13,14} However, the detail information is extremely limited. Interestingly, most DAs developed in small-sized arteries except for one internal carotid artery and one VA cases with no information including intervals between COVID-19 and SAH onsets. It was reported that most SAHs were non-aneurysmal ones,^{3,15} for which a potential mechanism might be infectious and immune-mediated vasculitis involving the small- and medium-sized arteries in the brain, but the involvement of large-sized cerebral arteries was also demonstrated.¹⁵ Reportedly, ischemic stroke of the posterior circulation occurred in high frequencies after an average of 5-day COVID-19 symptoms, possibly

by SARS-CoV-2-induced hyperinflammation and vascular injury.¹⁶ As well, DAs in small-sized arteries may develop by SARS-CoV-2-induced hyperinflammation causing a tear in the intima and internal elastic lamina.^{16,17} DAs in the main trunk artery such as VAs may develop by SARS-CoV-2-induced inflammatory obstruction of capillaries from the vasa vasorum causing degeneration of the tunica media,^{16,17} therefore possibly needing a longer interval from SARS-CoV-2 infection such as this case (17 days). There are also reports suggesting that local inflammation of the arterial wall spread by systemic inflammation could be involved in the formation of a fragile DA,¹⁸ and that SARS-CoV-2-triggered inflammatory response and endothelial dysfunction could rupture atherosclerotic plaque, thereby leading to the formation of hematoma in the arterial wall and a DA.⁵ High-dose corticosteroid therapy commonly used for the treatment of COVID-19 could also be a causative factor for spontaneous dissection in an already weakened arterial wall.⁵ However, histological examination was not performed in this study, because ruptured DA was treated with an endovascular procedure; therefore, there is no evidence that SARS-CoV-2 infection evoked inflammatory obstruction of capillaries from the vasa vasorum or VA wall inflammation. The accumulation of additional cases as well as further studies including pathological examinations are needed to clarify the relationships between SARS-CoV-2 infection and ruptured intracranial DAs.

4. Conclusion

The authors reported a case of SAH by a ruptured VA DA which occurred under the treatment for severe pneumonia by COVID-19, and discussed the potential relationships between SARS-CoV-2 infection and SAH by a ruptured VA DA. To demonstrate the relationships, the accumulation of more cases and further studies are needed.

Author contribution

Design (NT, HS), literature search (TS, HS), discussion (TS, YM, RY, NT, HS), first draft (TS), critical comments (YM, RY, NT, HS).

Funding

No funding was received.

Ethical approval

The study was approved by the ethics committee of Mie University Graduate School of Medicine. The study was conducted in accordance with the Declaration of Helsinki.

Informed consent

Written informed consent was provided by the patient.

Declaration of Competing Interest

The authors declare that they have no known competing financial interests or personal relationships that could have appeared to influence the work reported in this paper.

References

1. Abou-Ismaïl MY, Diamond A, Kapoor S, et al. The hypercoagulable state in COVID-19: incidence, pathophysiology, and management. *Thromb Res.* 2020;194:101–115. <https://doi.org/10.1016/j.thromres.2020.06.029>.
2. Fraiman P, Junior CG, Moro E, et al. COVID-19 and cerebrovascular disease: a systematic review and perspective for stroke management. *Front Neurol.* 2020;11. <https://doi.org/10.3398/fneur.574694> 574694.

3. Daly SR, Nguyen AV, Zhang Y, et al. The relationship between COVID-19 infection and intracranial hemorrhage: a systematic review. *Brain Hemorrhages*. 2021;2:141–150. <https://doi.org/10.1016/j.hest.2021.11.003>.
4. Morassi M, Bigni B, Cobelli M, et al. Bilateral carotid artery dissection in a SARS-CoV-2 infected patient: causality or coincidence? *J Neurol*. 2020;267:2812–2814. <https://doi.org/10.1007/s00415-020-09984-0>.
5. Abraham B, Mathew SD, Sridharan K. A systematic review of arterial dissections in COVID-19 patients. *Curr Cardiol Rev* 2022. doi: 10.2174/1573403X18666220628093303. Epub ahead of print.
6. Tiu C, Terecoasa E, Grecu N, et al. Vertebral artery dissection: a contemporary perspective. *Maedica (Bucur)*. 2016;11:144–149 <https://www.ncbi.nlm.nih.gov/pmc/articles/PMC5394579/pdf/maedica-11-144.pdf>.
7. Khan D, Naderi S, Ahmadi M, et al. Intracranial aneurysm rupture after SARS-CoV2 infection: case report and review of literature. *Pathogens*. 2022;11:617. <https://doi.org/10.3390/pathogens11060617>.
8. Fayed I, Pivazyan G, Conte AG, et al. Intracranial hemorrhage in critically ill patients hospitalized for COVID-19. *J Clin Neurosci*. 2020;81:192–195. <https://doi.org/10.1016/j.jocn.2020.08.026>.
9. Yoshimoto T, Yamagami H, Sakai N, et al. Impact of COVID-19 on the volume of acute stroke admissions: a nationwide survey in Japan. *Neurol Med Chir (Tokyo)* 2022. doi: 10.2176/jns-nmc.2022-0099. Epub ahead of print.
10. Balucani C, Carhuapoma JR, Canner JK, et al. Exploring the collateral damage of the COVID-19 pandemic on stroke care: a statewide analysis. *Stroke*. 2021;52:1822–1825. <https://doi.org/10.1161/STROKEAHA.121.034150>.
11. Dodd WS, Jabbour PM, Sweid A, et al. Aneurysmal subarachnoid hemorrhage in patients with coronavirus disease 2019 (COVID-19): a case series. *World Neurosurg*. 2021;153:e259–e264. <https://doi.org/10.1016/j.wneu.2021.06.092>.
12. Qureshi AI, Baskett WI, Huang W, et al. Subarachnoid hemorrhage and COVID-19: an analysis of 282,718 patients. *World Neurosurg*. 2021;151:e615–e620. <https://doi.org/10.1016/j.wneu.2021.04.089>.
13. Al-Mufti L, Becker C, Kamal H, et al. Acute cerebrovascular disorders and vasculopathies associated with significant mortality in SARS-CoV-2 patients admitted to the intensive care unit in the New York Epicenter. *J Stroke Cerebrovasc Dis*. 2021;30. <https://doi.org/10.1016/j.jstrokecerebrovasdis.2020.105429>.
14. Al Saiegh F, Ghosh R, Leibold A, et al. Status of SARS-CoV-2 in cerebrospinal fluid of patients with COVID-19 and stroke. *J Neurol Neurosurg Psychiatry*. 2020;91:846–848. <https://doi.org/10.1136/innp-2020-323522>.
15. Keller E, Brandi G, Winkhofer S, et al. Large and small cerebral vessel involvement in severe COVID-19: detailed clinical workup of a case series. *Stroke*. 2020;51:3719–3722. <https://doi.org/10.1161/STROKEAHA.120.031224>.
16. Humayun L, Smith C, Li W, et al. SARS-CoV-2-related vascular injury: mechanisms, imaging and models. *Microphysiol Syst*. 2021;5:1. <https://doi.org/10.21037/mps-20-6>.
17. Bond KM, Krings T, Kanzino G, et al. Intracranial dissections: a pictorial review of pathophysiology, imaging features, and natural history. *J Neuroradiol*. 2021;48:176–188. <https://doi.org/10.1016/j.neurad.2020.03.007>.
18. Saito A, Kawaguchi T, Hori E, et al. Subarachnoid hemorrhage after an ischemic attack due to a bacterial middle cerebral artery dissecting aneurysm: case report and literature review. *Neurol Med Chir (Tokyo)*. 2014;54:196–200. <https://doi.org/10.2176/nmc.cr2012-0251>.