

## Clinical Article

# Our Experience with Surgically Treated Epidural Hematomas in Children

Sang-Won Jung, M.D., Dong-Won Kim, M.D., Ph.D.

Department of Neurosurgery, Keimyung University School of Medicine, Daegu, Korea

**Objective :** Traumatic epidural hematomas (EDHs) in children are a relatively unusual occurrence. The cause and outcome vary depending on period and region of study. The aims of this analysis were to review the cause and outcome of pediatric EDHs nowadays and to discuss outcome-related variables in a large consecutive series of surgically treated EDH in children.

**Methods :** This is a retrospective review of 29 patients with surgically treated EDHs between Jan 2000 and February 2010. Patients' medical records, computed tomographic (CT) scans, and, if performed, magnetic resonance imaging (MRI) were reviewed to define variables associated with outcome. Variables included in the analysis were age, associated severe extracranial injury, abnormal pupillary response, hematoma thickness, severity of head injury (Glasgow Coma Scale score), parenchymal brain injury, and diffuse axonal injury.

**Results :** The mean (SD) age of the patients was 109 months (0-185 months). Most of the injuries with EDHs occurred in traffic accident (14 cases, 48.2%) and followed by slip down in 6 cases and falls in 6 cases. There were one birth injury and one unknown cause. EDHs in traffic accidents occurred in pedestrians hit by a motor vehicle, 9 cases; motorbike and car accidents, 5 cases and bicycle accidents, 1 case. The locations of hematoma were almost same in both sides (left side in 15 cases). Temporal lobe is the most common site of hematomas (13 cases, 44%). The mean size of the EDHs was 18 mm (range, 5-40 mm). Heterogeneous hematomas in CT scans were 20 cases (67%). Two patients were referred with unilateral or bilateral dilated pupil(s). There was enlargement of EDH in 5 patients (17%). All of them were heterogeneous hematomas in CT scans. Except for 4 patients, all EDHs were associated with skull fracture(s) (87%). There was no case of patient with major organ injury. CT or MRI revealed brain contusion in 5 patients, and diffuse axonal injury in one patient. The mortality was zero, and the outcomes were excellent in 26 and good in 2 patients. None of the tested variables were found to have a prognostic relevance.

**Conclusion :** Regardless of the EDH size, the clinical status of the patients, the abnormal pupillary findings, or the cause of injury, the outcome and prognosis of the patients with EDH were excellent.

**Key Words :** Traumatic epidural hematomas (EDHs) · Children · Cause · Outcome.

## INTRODUCTION

Acute epidural hematomas (EDHs) in children and infants represent a potentially life-threatening condition after head injury. EDHs in children are a relatively unusual occurrence. The reported incidence of EDH ranges between 1% and 6% after head trauma in hospitalized children<sup>5,10</sup>. Early identification and adequate management depending on the patient's clinical condition and the size of EDH are prerequisites for good outcome<sup>10</sup>. However, besides the presence of midline structure shift on head computed tomographic (CT) scan and clinical signs of uncal herniation, other factors, such as associated brain contusion, dif-

fuse axonal injury (DAI), or extracranial injury, may determine the outcome of the children. Also, the causes and outcomes of acute EDHs vary depending on period and region. The aims of this analysis were to review the cause and outcome of surgically treated pediatric EDHs in our hospital and to discuss outcome-related variables in a large consecutive series of surgically treated EDH in children for 10 years.

## MATERIALS AND METHODS

### Patient population

A total of 175 children were admitted with head trauma be-

• Received : November 18, 2011 • Revised : March 21, 2012 • Accepted : April 15, 2012

• Address for reprints : Dong-Won Kim, M.D., Ph.D.

Department of Neurosurgery, Keimyung University School of Medicine, 56 Dalseong-ro, Jung-gu, Daegu 700-712, Korea  
Tel : +82-53-250-7333, Fax : +82-53-250-7356, E-mail : dongwon@dsmc.or.kr

• This is an Open Access article distributed under the terms of the Creative Commons Attribution Non-Commercial License (<http://creativecommons.org/licenses/by-nc/3.0>) which permits unrestricted non-commercial use, distribution, and reproduction in any medium, provided the original work is properly cited.

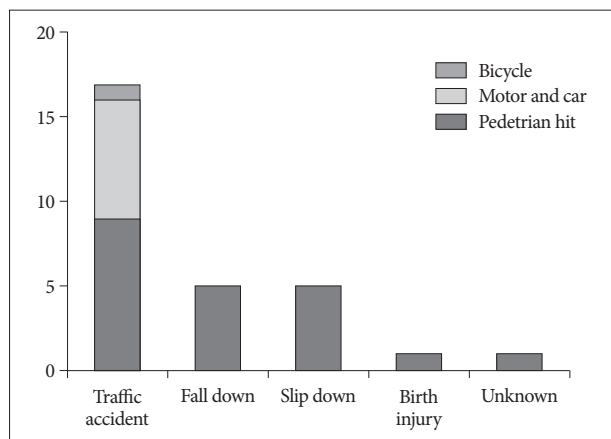


Fig. 1. Cause of pediatric EDHs. EDHs : epidural hematomas.

Table 1. General characteristic of 29 patients

Index	Value
Age (months)	109
GCS score	12.9
Sex (M : F)*	
Male	19
Female	10
Mean time to surgery (hours)	23 (range 3-122)
Abnormal pupil finding*	2
Radiologic finding	
Thickness of hematoma (mm)	18 (range 5-40)
Skull fracture*	24
Midline shifting*	14
Heterogeneity of hematoma nature*	20
Enlargement of hematoma thickness*	6
Contusion*	5
Diffuse axonal injury*	1

\*Values represent the number of patients, unless otherwise indicated. GCS : glasgow coma scale

tween Jan 2000 and Feb 2010. There were 57 patients with EDHs. Among 57 patients, 29 patients with EDH were surgically treated. All patients were documented in a database at the time of treatment. Perioperative course, radiological findings, and outcome were evaluated retrospectively. Items included in the database were demographic features, cause of trauma, preoperative clinical status according to the Glasgow Coma Scale (GCS) score, signs of transtentorial herniation (unilateral or bilateral dilated pupil), isolated head injury or associated substantial extracranial injury, time to treatment (including the reason for delayed treatment, if performed), and the outcome according to the modified Rankin Scale (mRS) and Glasgow Outcome Scale (GOS). The outcome was classified as excellent (mRS score, 0; GOS score, 5), good (mRS score, 1,2; GOS score, 4), or adverse (mRS score  $\geq 3$ ; GOS score  $\leq 3$ ).

**Surgical procedures and imaging studies**

All patients were treated according to a standard advanced

trauma life support protocol if presented immediately to the emergency department of our institution. Trauma workup was initiated according to the clinical status and the mechanism of the trauma and usually included a head and body CT scan and abdominal ultrasound. After documentation of an EDH treatment, indication for surgery was a thickness of the hematoma of at least 10 mm (maximal thickness), dislocated skull fractures associated with EDH, or a documented increase of the hematoma size with clinical deterioration. Operative treatment of EDH was performed as a standardized procedure. After osteoplastic craniotomy, hematoma evacuation was performed. Any craniotomy performed more than 10 hours after injury was classified as “delayed”. All patients underwent either postoperative cranial CT or magnetic resonance imaging (MRI) to document adequate removal of the hematoma, trauma-associated brain contusion, or any complication related to the trauma or operative treatment. MRI was the preferred method of control imaging whenever DAI was suspected from the severity and mechanism of trauma.

**Statistical analysis**

Comparisons of demographic variables including age at trauma, isolated head injury, unilateral or bilateral dilated pupil, severe head injury (GCS <8) before treatment, hematoma size, presence of brain contusion, and time to operative evacuation between the groups were performed using unpaired t-test,  $\chi^2$  test. Values of  $p < 0.05$  were considered significant.

**RESULTS**

**General characteristics**

Twenty-nine patients with EDH were surgically treated in study period. Age ranged from 1 day to 15 years (mean age : 109 months). Two patients (6.8%) were younger than 1, two (6.8%) younger than 4, 10 (34.5%) between 4 and 10, and 15 (51.9%) older than 10 years. Nineteen patients (65.5%) were male. The most common cause was traffic accident (14 cases, 48.2%). In cases of traffic accident, pedestrian hit was most common cause (9 cases, 31%) followed by fall down (6 cases, 20.6%), slip down (6 cases, 20.6%), and birth injury (1 case, 3.4%) (Fig. 1). One case was due to unknown cause. He had no history of trauma. The GCS score before hematoma evacuation ranged from 3 to 15 (Mean score, 12.9). Only 1 patient (3.4%) had severe head injury (GCS score <8), 6 patients (20.7%) had a GCS score between 9 and 12, and in 22 patients (75.9%), the GCS score was 13 to 15. The mean time to surgery was 23 hours; however, 11 patients (37.9%) underwent surgical evacuation of the hematoma within 10 hours. Delayed surgery (more than 10 hours after trauma) was performed in 8 cases (27.5%). Abnormal pupil finding was only 2 cases (6.8%) (Table 1).

**Radiologic finding**

Hematoma location was temporal in 13 cases (44.8%), frontal

in 7 cases (24.1%), parietal and occipital in 4 cases respectively (13.7%) (Fig. 2). The locations of hematoma were almost same in both sides (left side 15 cases). The mean thickness of the hematoma was 18 mm (range, 5-40 mm), and 14 patients (48.2%) showed midline shift in initial imaging. Twenty-four patients (82.5%) had an associated skull fracture. Five patients had cerebral contusion. Three patients underwent MRI after the treatment of the EDH, and 1 patient showed signs of DAI. Heterogeneous hematomas in CT scans were 20 cases (68.9%). Among these cases, 6 cases showed enlargement of hematoma in follow-up CT scans.

### Clinical outcome

None of the patients in this series died of EDH (0% mortality). In this study, only one patient died. He was 1-year-old and fell down on the kitchen floor. When he arrived at the hospital, he was in cardiac arrest. His CT scan showed small amount of EDH in right temporal area. Finally, he died due to hypoxic brain damage and hemoperitoneum. Except this case, no patient died of EDH. The overall outcomes were excellent in 26 patients (92.8%) and good in 2 patients (7.2%).

## DISCUSSION

Incidence of epidural hematoma in children was scarcer than that in adults due to tight adherence of the dura to the inner table of the skull<sup>10</sup>. In other studies, of all head-injured admitted children under 15 years of age admitted, 2-3% were found to have extradural hematomas<sup>7</sup>. But in our study, 32.6% of all admitted head-injured children (57 of 175) had EDHs. A possible explanation for this difference might be found in the difference of cause of trauma. In other studies, the most common cause was fall down. But in our study, it was traffic accident.

Children sustaining cranial traumas associated with EDH represent a heterogeneous group with various clinical outcomes. The approximated mortality is 5%, although mortality in the quoted literature ranges from 0% to 12%, and was even higher in the pre-CT era<sup>3,5,11</sup>.

In our study, mortality was zero, 26 cases had excellent outcome. Only 2 cases had good outcome. A possible explanation

for the overall very good outcome might be the advanced contemporary pediatric trauma care and urgent surgery in patients with clinical signs of uncal herniation.

There was significant difference between children and adults in the clinical course. 20-30% of adult patients were unconscious (GCS <8). However, only 3% of children in our study were unconscious. It was in concordance with other studies<sup>1,4,7-13</sup>.

Prognostic factors of EDH in children are GCS, pupillary reaction and light response, and the presence of focal neurological deficit, the laboratory findings of hyperglycemia and hypokalemia<sup>5</sup>. These are similar to those in adults<sup>3</sup>. But, mortality of EDH in children is lower than that of adult<sup>10</sup>. Such a good outcome in children is probably related to the significantly lower incidence of associated intradural injury and the lower incidence of unconsciousness of patients requiring immediate surgery<sup>10</sup>.

The criteria for determining which cases for conservative and which cases for surgical treatment remained controversial. Bejjani et al.<sup>5</sup> found that the most important radiographic parameter dictating surgical evacuation was maximum diameter of hematoma of more than 15 mm and midline shift of more than 5 mm. Only patients with EDHs less than 10 mm and no focal deficits were treated conservatively and followed up closely, but if any deterioration occurred and/or an increase in the size of the hematoma was seen, we decided to perform a surgical evacuation.

It was reported that the incidence of skull fracture in children was 60-82% and it was known that there was no difference in that of adult<sup>6,7,9,10,13</sup>. In our study, the incidence of skull fracture was 82.5% and it corresponded to reported literature.

The mean time to surgical intervention was 23 hours. Surgery was performed within 24 hours in about 80% of adults, but only in 54% of children. It is thought that it was because of insidious clinical course of EDH in children<sup>7,10</sup>.

The heterogeneous hematoma appearances of some actively bleeding extradural hematomas have been termed the "swirl sign"<sup>2</sup>. In our study, 70.0% (20 of 29) had the "swirl sign". Six of 20 patients showed increased hematoma volume in follow-up CT scans.

This study was retrospective and included a small number of patients. Therefore, we could not show statistically meaningful factor which affected prognosis. But, our good outcome may be

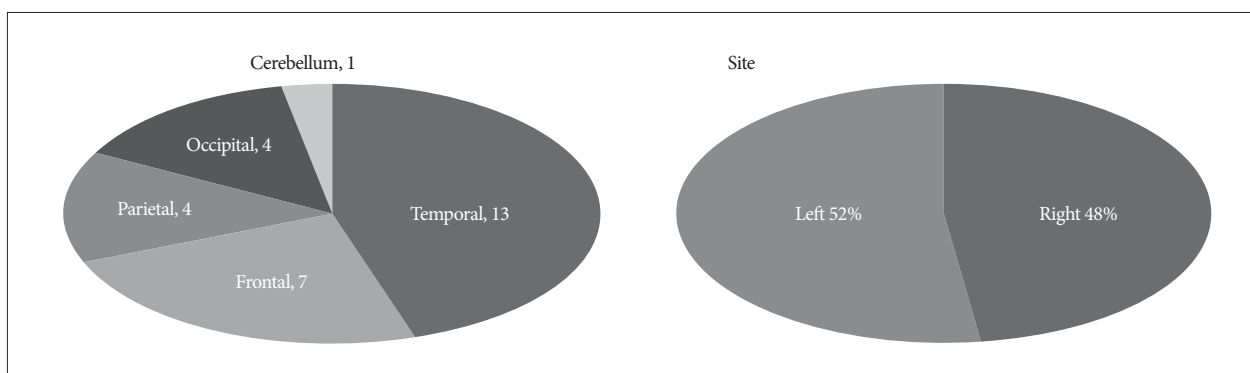


Fig. 2. Location and side of all EDHs. EDHs : epidural hematomas.

kept in mind in case of children with extensive EDH and clinical signs of uncal herniation are seen in the emergency department.

## CONCLUSION

Extradural hemorrhage is one of the most threatening lesions in patients with craniocerebral trauma, and early diagnosis is essential for its adequate treatment. It can be managed with excellent outcome even in children with low GCS scores, abnormal pupillary reaction, and large hematoma size. However, these cases should be treated surgically without delay when necessary.

## References

1. Balmer B, Boltshauser E, Altermatt S, Gobet R : Conservative management of significant epidural haematomas in children. *Childs Nerv Syst* 22 : 363-367, 2006
2. Barras CD, Tress BM, Christensen S, MacGregor L, Collins M, Desmond PM, et al. : Density and shape as CT predictors of intracerebral hemorrhage growth. *Stroke* 40 : 1325-1331, 2009
3. Ben Abraham R, Lahat E, Sheinman G, Feldman Z, Barzilai A, Harel R, et al. : Metabolic and clinical markers of prognosis in the era of CT imaging in children with acute epidural hematomas. *Pediatr Neurosurg* 33 : 70-75, 2000
4. Browne GJ, Lam LT : Isolated extradural hematoma in children presenting to an emergency department in Australia. *Pediatr Emerg Care* 18 : 86-90, 2002
5. Bullock MR, Chesnut R, Ghajar J, Gordon D, Hartl R, Newell DW, et al. : Surgical management of acute epidural hematomas. *Neurosurgery* 58 : S7-S15; discussion Si-iv, 2006
6. Cordobés F, Lobato RD, Rivas JJ, Muñoz MJ, Chillón D, Portillo JM, et al. : Observations on 82 patients with extradural hematoma. Comparison of results before and after the advent of computerized tomography. *J Neurosurg* 54 : 179-186, 1981
7. Dhellemmes P, Lejeune JP, Christiaens JL, Combelles G : Traumatic extradural hematomas in infancy and childhood. Experience with 144 cases. *J Neurosurg* 62 : 861-864, 1985
8. Erşahin Y : Extradural haematomas in children. *Br J Neurosurg* 24 : 503, 2010
9. Gerlach R, Dittrich S, Schneider W, Ackermann H, Seifert V, Kieslich M : Traumatic epidural hematomas in children and adolescents : outcome analysis in 39 consecutive unselected cases. *Pediatr Emerg Care* 25 : 164-169, 2009
10. Jamjoom A, Cummins B, Jamjoom ZA : Clinical characteristics of traumatic extradural hematoma : a comparison between children and adults. *Neurosurg Rev* 17 : 277-281, 1994
11. Maggi G, Aliberti F, Petrone G, Ruggiero C : Extradural hematomas in children. *J Neurosurg Sci* 42 : 95-99, 1998
12. Paiva WS, Andrade AF, Mathias Júnior L, Guirado VM, Amorim RL, Magrini NN, et al. : Management of supratentorial epidural hematoma in children : report on 49 patients. *Arq Neuropsiquiatr* 68 : 888-892, 2010
13. Rocchi G, Caroli E, Raco A, Salvati M, Delfini R : Traumatic epidural hematoma in children. *J Child Neurol* 20 : 569-572, 2005