

# Evaluation of two different types of radial head prosthesis in practical use. Using either Evolve® or MoPyC® radial head prosthesis in the treatment of comminuted radial head fractures

Tim Friedrich Raven,<sup>1,2</sup>

Lukas Banken,<sup>2,3</sup>

Gerhard Schmidmaier,<sup>2</sup>

Stefan Studier-Fischer,<sup>4</sup>

Bahram Biglari,<sup>4</sup> Arash Moghaddam<sup>1,2</sup>

<sup>1</sup>ATORG – Aschaffenburg Trauma and Orthopaedic Research Group, Center of Orthopaedic and Trauma surgery and Sports medicine, Aschaffenburg;

<sup>2</sup>HTRG – Heidelberg Trauma Research Group, Division of Trauma and Reconstructive Surgery, Center for Orthopaedics, Trauma Surgery and Spinal Cord Injury, University Hospital Heidelberg; <sup>3</sup>Schön Klinik Hamburg-Eilbek, Hamburg; <sup>4</sup>BG Trauma Center, Ludwigshafen, Germany

## Abstract

The aim of this retrospective study was to undertake a comparative evaluation of the Evolve® modular metallic radial head implant prosthesis and the MoPyC® pyrocarbon prosthesis in acute care. Seventy-five patients having a comminuted radial head fracture with an Evolve® prosthesis (=G1) and 11 with a MoPyC® prosthesis (=G2) were available for a follow-up. Postoperative patient outcomes were evaluated according to a standardized follow-up protocol which included the Morrey rating system. Assessment criteria were range of motion (ROM), functional scores, and rate of complications. G1 showed a mean Morrey score of 86 points. Four direct prosthesis complications were observed in this group (n=75). The average achieved Morrey score in G2 was 84 points. In this group (n=11), 2 direct prosthesis complications were diagnosed. The average range of motion did not differ greatly between both groups. Radial head replacement with either prosthesis yielded sufficient to satisfactory results in a mid-term perspective regarding the range of motion and function of the elbow joint when performed in carefully selected patients. The Evolve® Prosthesis appears to show a slightly lower rate of complication by way of a similar functional outcome.

## Introduction

The radial head is involved in about one-third of all elbow-fractures and up to 2-5% of all fractures,<sup>1-3</sup> but in combination with the accompanying injuries of the elbow joint it is problematic. The insufficiency of the radial head as a radial pillar of this joint leads to instability of the entire elbow joint.<sup>4-7</sup> Some authors recommend, that fractures with more than 3 fragments should not be reconstructed, because of a higher risk of a weak outcome and a higher rate of complications. Previous studies have shown that, in the case of radial head fractures with unstable ligamentous apparatus, the step towards endoprosthesis replacement should be taken and a complete radial head resection should only be performed in exceptional cases; partial removal is no longer recommended.<sup>8-10</sup> Resection can only be performed if the joint is completely stable. However, if the joint is unstable during surgery, a radius head prosthesis should be considered. The indication for a radial head prosthesis is usually given intraoperatively, if the elbow joint is unstable, as follows: radial head comminuted fracture with elbow dislocation, comminuted fractures with injury to the collateral ligament or comminuted fractures with injury to the interosseous membrane. Over the years, various prostheses have appeared on the market, with the first generation of radial head prostheses being characterized by high complication rates and poor outcome. In the meantime, however, some second-generation prostheses have established themselves and in some cases they have achieved very good results.<sup>11-17</sup>

The aim of this study was to evaluate two of the prosthesis models that are used by the present authors with regards to their clinical and functional outcomes in acute care.

## Materials and Methods

For the present study, two collectives were recorded at the two locations where the present authors are practitioners. One patient group was treated with the Evolve® prosthesis (Wright Medical Technology, Inc., Arlington, USA) (=G1) and a second group was treated with the MoPyC® prosthesis (Tornier, Montbonnot-Saint-Martin, France) (=G2).

In this study, all patients were examined according to a standardised follow-up protocol, which included the topics of pain, strength, function and everyday complaints. The measurement of the maximum force

Correspondence: Tim Friedrich Raven, ATORG - Aschaffenburg Trauma and Orthopaedic Research Group, Center for Trauma Surgery, Orthopaedics and Sports Medicine, Hospital Aschaffenburg-Alzenau, Am Hasenkopf 1, 63739 Aschaffenburg, Germany.

Tel.: +49.6021.3243.4136.

E-mail: dr.raventf@gmail.com

Key words: Radial head, Fracture, Prosthesis, Evolve, MoPyC.

Conflict of interest: The is no conflict of interest.

Contributions: TFR, LB, AM, GS, SSF and BB were involved with the design of the study, data acquirement, statistical analysis, and manuscript preparation. TR, SSF, AM and BB assisted with the data interpretation and manuscript preparation. All authors read and approved the final manuscript.

Funding: None.

Availability of data and materials: The dataset used and analyzed during the current study is available from the corresponding author on reasonable request.

Ethics approval and consent to participate: This study was approved by the ethics committee of the Medical Faculty of the University of Heidelberg (No. S-531/2011) and from the local ethics committee (Board of Medical Profession of Rhineland-Palatinate in Mainz) (No. 837.322.07(5857)). The study design and patient inclusion follows the declaration of Helsinki in its present form. From all patients, informed consent to participate in the study was obtained.

Received for publication: 22 November 2019.  
Accepted for publication: 14 February 2020.

This work is licensed under a Creative Commons Attribution NonCommercial 4.0 License (CC BY-NC 4.0).

©Copyright: the Author(s), 2020

Licensee PAGEPress, Italy

Orthopedic Reviews 2020;12:8386

doi:10.4081/or.2020.8386

was undertaken with the Jamar® hand dynamometer. To assess the outcome of the treatment, the Morrey score (2) was used. Furthermore, the subjective satisfaction of the result was evaluated. The fracture classification and the data evaluation were based on the international distribution according to the Mason classification,<sup>18</sup> modified according to Broberg and Morrey.<sup>19</sup> In addition to age and sex, the course and mechanism of the accident as well as the extent of the concomitant injuries were surveyed.

## Postoperative-treatment

Early functional mobilization was enforced at the earliest opportunity where possible. The patients, who had a refixation of the collateral ligament, were instructed to avoid varus and valgus stress for 6 weeks. A dorsal splint was applied to limit the extension of the elbow, if a refixation of the processus coronoideus was indicated. To prevent periarticular ossifications, which are very common after treatment of radial head fractures, all patients were medicated with 145.6 mg diclofenac-colestyramin for 4 weeks postoperatively.

## Radiographic examination

In the course of this retrospective study, the x-ray images, being computed tomography (CT) or magnetic resonance imaging (MRI) scans, were interpreted by two orthopedic surgeons. The radiographic evaluation and assessment impinged on the basis of the radiological images of the accident and the follow-up images. The assessment criteria were correct articulation of the joint components, implant position, humeroulnarthritis, prosthesis loosening and lysis margin formation.

### G1 (Evolve®-Prothesis)

In group 1, 75 patients (35 men, 40 women) who were treated with an Evolve® prosthesis in the period from 05/2001 to 11/2009 for radial head comminuted fractures were included in the study and re-examined.

The Evolve® prosthesis is a metal monoblock prosthesis consisting of two

variable components, the prosthesis head and the prosthesis stem. These are interlocked intraoperatively. The prosthesis surface is polished and thus fulfils a rotating placeholder function.<sup>12,14</sup>

The mean follow-up time was 41.5 (mean: 33.0; min: 4 - max: 93) months. The average patient age was 55.9 (55; 26 - 85) years.

Left-side or right-side dominance was involved in 38 cases.

Overall, there were 2 (2.7%) Mason II fractures, 21 (28.0%) Mason III fractures, and 52 (69.3%) Mason IV fractures.

Surgical treatment was performed 8 (30.0; 6 - 265) days after injury on average. Thirty-five patients (46.7%) were treated within the first 5 days after injury, and 40 patients (53.3%) were treated at later time points. Delayed treatment was mostly because patients came from external hospitals within a period of several days after injury.

The results regarding this patient population, having an Evolve® radius head prosthesis, have already been published.

### G2 (MoPyC®-Prothesis)

For group 2, 11 patients (9 women, 2 men) who had a radius head fracture between 09/12 and 8/16 were recruited and they were treated using a MoPyC® radial head prosthesis (Bioprofile, Tornier, Montbonnot-Saint-Martin, France).

The stem and the neck of the modular MoPyC® radial head prosthesis are made of titanium alloy. Each is available in 4 different sizes. There are 3 different sizes of the

spherical head, which is made of pyrolytic pyrocarbon. That provides 48 different possibilities for assembly of the prosthesis, which leads to a high wear resistance and an elasticity modulus, similar to the characteristics of human bone and cartilage. The non-cemented system is fixated using a primary press-fit fixation due to a dynamic expansion device in the stem, which provides good biocompatibility.<sup>20-27</sup>

The mean follow-up time was 46.1 (48.0; 15 - 67) months. The average age was 52.8 (52.0; 18 - 76) years. In 8 cases (72.7%) the right upper extremity was affected and in 3 cases (27.3%) the left upper extremity of a complete right dominant collective was affected.

According to the Mason classification, 2 patients (18.2%) presented a Mason III fracture and 9 patients (81.8%) presented a Mason IV fracture. In 5 cases (45.5%) there was a direct elbow trauma, in 4 cases (36.4%) a fall on the arm extended forward and in 2 cases (18%) a backward fall. Five patients (45.5%) suffered a trauma in their domestic environment 5 patients (45.5%) suffered a trauma while undertaking sports or leisure activities. The remaining one patient (9.1%) was injured on the way to work. On average, the patients received surgical treatment on the 3.4 (3.0; 0 - 8) day after the accident. Postoperative exercises were started after 3.0 (1.5; 1 - 12) days on average.

A part of the first early data from G2 has already been published.

**Table 1. Accompanying injuries.**

	G1*		G2	
	Number (n=75)	Percentage rates	Number (n=11)	Percentage rates
Patients with accompanying injuries	64	85.3	10	90.9
Patients without accompanying injuries	11	14.7	1	9.1
Fracture of the proc. coronoideus	38	50.7	7	63.6
Injury of the radial collateral ligament	18	24.0	9	81.8
Injury of the ulnar collateral ligament	13	17.3	8	72.7
Fracture of the olecranon	5	6.7	3	27.3
Essex-Lopresti-lesions	1	1.3	0	0.0

\* Percentage rates refer to the number of patients instead of the number of accompanying injuries as described in the previously published data.

**Table 2. Range of motion.**

	G1*		G2	
	Affected side	Non-affected side	Affected side	Non-affected side
Flexion	125.7° (130; 90 - 150)°	138.5° (140; 120 - 150)°	128.2° (130; 95 - 145)°	136.8° (140; 130 - 140)°
Extension	-16.5° (-15; 0 - (-50))°	1.2° (0; 10 - (-30))°	-16.7° (-9; 0 - (-70))°	0.9° (0; 0 - 5)°
Pronation	70.5° (80; 0 - 90)°	83.6° (80; 70 - 90)°	73.2° (80; 5 - 90)°	86.4° (90; 80 - 90)°
Supination	67.1° (80; (-45) - 90)°	84.3° (85; 60 - 90)°	75.5° (80; 5 - 90)°	86.4° (90; 80 - 90)°

### Analysis of the data

The analysis of the data was performed using Microsoft Office Excel® 2016 and IBM SPSS® Statistics 24. Data are shown as mean value, median and range.

## Results

### Associated injuries

G1: In 85.3% of the cases an accompanying injury of the affected extremity was present. The most frequent concomitant injury was elbow joint dislocation with tearing off of the coronoid process (50.7%) followed by injuries of the radial collateral ligament (24.0%) (Table 1).

G2: In 10 patients (90.9%), other osseous or ligamentous damage was present in addition to the radial head fracture (Table 1).

### Functional outcome

The range of motion of both groups is described in Table 2.

### Strength

G1: On average, 25.1 (24; 4 - 50) kg could be measured on the affected side and 32.4 (32; 10 - 56) kg could be measured on the uninjured side. Handgrip strength of the injured arm compared to the non-injured arm was 78.8%.

G2: The maximum power of the affected extremity was on average 25.5 (22.0; 10 - 58) kg compared to 26.6 (22.0; 14 - 48) kg of the opposite side. The injured side showed 95.6% of the handgrip strength compared to the non-injured arm.

**Table 3. Mayo Elbow Performance Index of G1 and G2.**

	G1	G2
Average	83.3	75.5
Median	85.0	80.0
Minimum	40	40
Maximum	100	100

**Table 4. Disabilities of Arm, Shoulder and Hand score of G1 and G2.**

	G1	G2
Average	26.1	22.8
Median	22.5	19.2
Minimum	0.0	0.0
Maximum	75.8	53.3

### Analysis of the scores

G1: According to the Morrey score 25 patients (33.3%) received the rating of very good,<sup>2</sup> 31 patients (41.3%) good; 17 patients (22.7%) satisfactory and 2 patients (2.7%) poor. The patients had an average of 85.7 (90.2; 44 - 100) points on the Morrey Score (Figure 1).<sup>2</sup>

On the Mayo Elbow Performance Index (MEPI)(28) patients achieves an average 83.3 (85.0; 40-100) points (Table 3). The DASH-scores showed an average of 26.1 (22.5; 0.0-75.8) points (Table 4).<sup>28</sup>

G2: In group 2 the average Morrey score was 84.3 (90.0; 53 - 100) points.<sup>2</sup> Two patients (18.2%) had a good result, 6 patients (54.5%) had a very good result and 3 patients (27.3%) had a sufficient result (Figure 1).

The mean MEPI(28) was 75.5 (80.0; 40 - 100) (Table 3). The DASH-score showed an average of 22.8 (19.2; 0.0-53.3) points (Table 4).<sup>29</sup>

### Complications

G1: In the Evolve collective 4 (5.3%) direct prosthesis complications were observed. In 2 cases, revisional surgery was necessary because of persistent pain and radiologic findings of loosening of the prosthesis. One patient showed an implant displacement according to radiographs performed during the study. Revisional surgery was offered to the patient. This patient refused the revision due to their lack of pain and good ROM. The fourth direct prosthesis complication was a disconnection of the head stem interface. A new identical prosthesis was implanted.

One other case experienced a loosening of the prosthesis after falling down on the

same arm five months after the first operation. This case was not declared as a (direct) prosthesis complication because of the traumatic genesis.

Beside the aforementioned specific prosthesis complications, 3 additional general complications were noted.

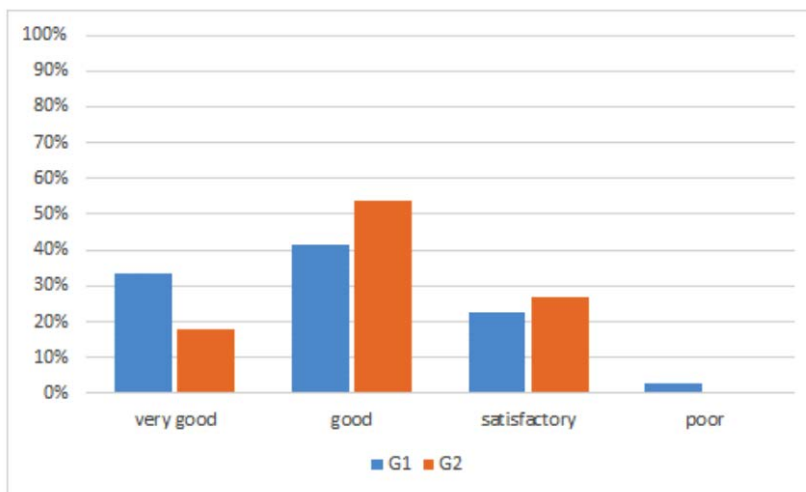
One patient required a neurolysis of the ulnaris nerve because of persistent pain, another patient developed a neobursa, and in one case extensive swelling and blistering was observed.

With these general complications the overall complication-rate for G1 is 9.3%.

G2: In 3 cases (27.3%) complications occurred postoperatively, of which 2 (18.2%) were directly caused by the prosthesis. One patient reported a numbness in fingers D III to D V since the operation. Initially, this numbness decreased, but the improvement stagnated in the course of the operation, so that no further improvement could be expected at the time of the data collection. In another patient, with an initial Monteggia fracture, postoperative instability continued with a tendency to subluxation. An attempt was made to have tendon plastic surgery that could not completely eliminate the instability. Finally, a full elbow prosthesis was implanted and a stable situation was achieved. However, at the time of the follow-up examination there was a high degree of movement restriction in this case (extension/flexion: 0/70/140; pronation/supination: 5/0/5). One case showed an inlay fracture, hence a change was necessary.

### Subjective rating of the patients

G1: Seventy-six percent (76.0%) of the patients in G1 reported the absence of or only a slight pain; 24.0% reported regular



**Figure 1. The Morrey score of G1 and G2.**



and/or constant pain; 77.3% of patients reported a reduction in strength.

Fifty-five patients (73.3%) rated the operative results as good or very good; 14 patients (18.7%) were satisfied with the results; and 6 patients (8.0%) were dissatisfied. Thirty-three patients (44.0%) reported no restrictions at all in their daily activities; 38 patients (50.7%) reported resting the affected extremity on a daily basis; and 4 patients (5.3%) reported serious restrictions in daily activities.

G2: In G2, 3 patients (27.3%) complained of regular pain sensations. The remaining 8 patients (72.7%) reported feeling occasional or no pain.

Nine patients (81.8%) reported a subjective loss of strength compared to before the trauma. The other 2 patients (18.2%) did not feel this deficiency.

In each case, 4 patients (36.4%) rated the result as very good and good. Two patients (18.2%) gave the rating of 'satisfactory' and 1 patient (9.1%) gave the rating of 'dissatisfied'. Four patients (36.4%) reported minor restrictions in everyday life and rest. The remaining 7 patients (63.6%) reported having no restrictions whatsoever in their everyday activities.

## Discussion

The biomechanically important role of the radial head for the stability of the elbow is known from various studies in the body of literature. Depending on the flexion position of the arm, forces acting axially on the forearm are transmitted by up to 60% to the upper arm via the radial abutment.<sup>4,5,30-32</sup>

Injuries of the radial head, especially when the ligamentary structures are involved, pose a challenge. In these cases, resection alone would lead to instability of the joint. If osteosynthesis is not possible, only the endoprosthesis remains. Various models for this purpose are available on the market.<sup>33-35</sup>

The present study evaluated the clinical-functional results of the Evolve® prosthesis and the MoPyC® prosthesis.

The weaknesses of this study are the low number of patients in G2 and the retrospective design.

The strengths of this study are the uniform post-treatment and data collection scheme that are valid for both treatment methods, and these can be positively emphasized.

According to the Morrey score patients with the Evolve® prosthesis achieved an average result of 1.4 points more than patients fitted with a MoPyC® prosthesis

(G1: 85.7; G2: 84.3).<sup>2</sup> This comparable result is also evident after the scores that were derived from the Morrey rating.<sup>2</sup> G1 received in 74.7% of cases a very good and a good result (56 patients), in 22.7% of cases (17 patients) a satisfactory result, and in 2.7% of cases (2 patients) a poor result.

In G2, 72.7% of cases had a very good to a good result and in the remaining 27.3% a sufficient result; no patient showed a poor result.

The MEPI for G1 is with a mean score of 83.3 points which is slightly higher than in G2 (75.5 points). According to the DASH score the patient in G2 had minor restriction in their everyday life compared to the patients in G1 (G1: 26.1; G2: 22.8).<sup>29</sup>

The measured dimensions of movement are similar between the two groups. The average flexion differs by only 2.5° (G1: 125.7°, G2: 128.2°), and the average extension deficit is almost identical with 16.5° in G1 and 16.7° in G2. For supination (G1: 67.1°, G2: 75.5°) and pronation (G1: 70.5°, G2: 73.2°) the results of G2 are slightly superior. Compared to the opposite side, the force measurement in G1 was, at 78.8%, inferior to G2 with 95.6%, but in absolute terms the difference was considered to be negligible (G1: 25.1kg, G2: 25.5kg).

In group 1, a prosthesis-specific complication was found in 4 patients (5.3%) during the follow-up period. In 2 cases persistent pain and a loosening led to a revision. One displacement of the prosthesis and 1 disconnection of the head were observed.

The overall complication-rate was 9.3%.

Group 2 showed 2 prosthesis-specific complications and 1 general complication (1x burst of the inlay, 1x instability of the elbow, 1x neurologic damage) and, therefore, there was a distinctly higher rate of complications (prosthesis specific: 18.2%, overall: 27.3%).

In terms of patient satisfaction, the MoPyC® prosthesis received 72.7% very good to good ratings, comparable to the Evolve® prosthesis with 73.3% very good to good ratings. The ratings of patients who reported no to minor restrictions in everyday life are slightly lower in G1 with 94.7% compared to G2 with 100%. Regular to frequent pain is reported in G1 by 24.0% of patients compared to 27.3% in G2.

In summary, the two prosthesis models presented in this study produced a similar outcome according to the extent of movement, the Morrey score,<sup>2</sup> the MEPI and DASH-score,<sup>28,29</sup> as well as in terms of pain frequency. In prosthesis specific complications, the Evolve® prosthesis was superior with a 12.9 percentage point lower rate.

Also, the overall complication rate was 18.0 percentage points lower in G1. From the results of this study, a small superiority of the Evolve® prosthesis can, therefore, be derived due to the lower complication rate with a largely comparable clinical, functional result. However, the small collective size in G2 must be taken into account.

In other studies, results that are comparable to the present study were found. Probably, the most meaningful data on the MoPyC® prosthesis can be found in the meta-study by Laumonerie *et al.*, which reports on 171 patients from 5 collectives with a mean follow-up period of 3.1 years. One-hundred-and-fifty-seven (157) (92%) of the patients achieved good to excellent results according to the Mayo elbow performance score (MEPS>74). The complication rate was 13% with a reoperation rate of 11% and, therefore, is well below the complication rate in this study. The most common complications were prosthetic dislocation (5%) followed by stiffness (4%). The mean flexion-extension arc is described with 124.7°, the mean pronation is described with 77.0°, and supination is described with 76.8°.<sup>16</sup>

For the Evolve® prosthesis, in the study by Laflamme *et al.* was described an average Mayo Elbow Performance Index (MEPI) of 97, with 1 out of 100 points for 21 patients and a follow-up period of 10.4 (2.0 - 15.1) years. The revision rate of 0% is lower than in group 1. The mean flexion deficit in the collective of Laflamme *et al.* was 1°, the extension deficit was 12°, the supination deficit was 14°, and the pronation deficit was 5°.<sup>36</sup>

In general, prosthetic care seems to be an adequate therapy for a well-selected patient population. The MoPyC® prosthesis offers an exact adaptation possibility to the sites due to the many possible combinations of the individual components. It could be assumed, however, that this model is more susceptible to complications due to its higher complexity. Some model-specific complications are described for the MoPyC® prosthesis by Hackl *et al.*<sup>37</sup> The data in the present study also show a slightly higher complication rate in comparison. In the aforementioned meta-study, the complication rate is already lower, but it is nonetheless somewhat higher than in the Evolve® collective of Laflamme *et al.* and in the present paper.

In the short to medium term, both models can achieve a good clinical and functional result, especially if the severity of the injury is taken into account. The high rate of concomitant injuries with approximately 90%, which in some previous studies was significantly lower (30-68%), should be

emphasized once again.<sup>38,39</sup> A slight superiority may exist due to the seemingly lower complication rates for the Evolve® prosthesis. However, it is unclear whether the functionality and the good medium-term results will be maintained in the long term, and whether a model will prove to be evidently more robust or advantageous in the long term. Further acquisition data is essential for this purpose and studies with a longer follow-up period should be undertaken.

## Conclusions

The prosthetic treatment of unstable radial head comminuted fractures remains the procedure of choice for a well-selected patient population. A clear recommendation for one of the two examined prosthesis models cannot be given from the data in the present study or from the overall review of the literature. The Evolve® prosthesis appears to have a slightly lower complication rate. However, it is advisable to continue using the model, with practitioners having the most surgical experience. Close attention should be paid to the concomitant injuries.

## References

- Ambacher T, Maurer F, Weise K. [Treatment results after primary and secondary resection of the radial head]. *Der Unfallchirurg* 2000;103:437-43.
- Morrey B. *The elbow and its disorders*. Philadelphia: Saunders; 1993.
- Zimmermann G, Wagner C, Moghaddam A, et al. Radiusköpfchenfraktur und Ellenbogenluxation. *Trauma und Berufskrankheit* 2004;6:297-303.
- Beingessner DM, Dunning CE, Gordon KD, et al. The effect of radial head fracture size on elbow kinematics and stability. *J Orthop Res* 2005;23:210-7.
- Charalambous CP, Stanley JK, Siddique I, et al. Radial head fracture in the medial collateral ligament deficient elbow; biomechanical comparison of fixation, replacement and excision in human cadavers. *Injury* 2006;37:849-53.
- van Riet RP, Morrey BF. Documentation of associated injuries occurring with radial head fracture. *Clin Orthop Relat Res* 2008;466:130-4.
- Visna P, Kalvach J, Beitel E, et al. [Open posterior dislocation of the elbow with fractures of the radial head and coronoid process and multiple diaphyseal fractures of the ulna]. *Unfallchirurg* 2008;111:193-6.
- Moghaddam A, Raven T, Dremel E, et al. Outcome of Radial Head Arthroplasty in Comminuted Radial Head Fractures: Short and Midterm Results. *Trauma Monthly* 2016.
- Raven TF, Schonewald M, Doll J, et al. Evaluation of MoPyC-prosthesis implantation and the use of angular stable plates in the treatment of comminuted radial head fractures. *J Orthop* 2019;16:288-93.
- Rief H, Raven T, Lennert A, et al. Is radial head resection after trauma still considered up to date. *Obere Extremität* 2014;2:121-7.
- Gebauer M, Rucker AH, Barvencik F, Rueger JM. [Therapy for radial head fractures]. *Unfallchirurg* 2005;108:657-67.
- Grewal R, MacDermid JC, Faber KJ, et al. Comminuted radial head fractures treated with a modular metallic radial head arthroplasty. Study of outcomes. *J Bone Joint Surg Am* 2006;88:2192-200.
- Morrey BF, Askew L, Chao EY. Silastic prosthetic replacement for the radial head. *T J Bone Joint Surg Am* 1981;63:454-8.
- Ring D, King G. Radial head arthroplasty with a modular metal spacer to treat acute traumatic elbow instability. Surgical technique. *J Bone Joint Surg Am* 2008;90:63-73.
- Vanderwilde RS, Morrey BF, Melberg MW, Vinh TN. Inflammatory arthritis after failure of silicone rubber replacement of the radial head. *J Bone Joint Surg Br* 1994;76:78-81.
- Laumonerie P, Tibbo ME, Kerezoudis P, et al. Short to midterm outcomes of one hundred and seventy one MoPyC radial head prostheses: meta-analysis. *Int Orthop* 2018;42:2403-11.
- Moghaddam A, Raven TF, Dremel E, et al. Outcome of Radial Head Arthroplasty in Comminuted Radial Head Fractures: Short and Midterm Results. *Trauma monthly*. 2016;21:e20201.
- Mason ML. Some observations on fractures of the head of the radius with a review of one hundred cases. *Br J Surg* 1954;42:123-32.
- Broberg M, Morrey B. Results of delayed excision of the radial head after fracture. *J Bone Joint Surg Am* 1986;68:669-74.
- Moghaddam A, Lennert A, Studier-Fischer S, et al. [Prosthesis after comminuted radial head fractures: midterm results]. *Unfallchirurg* 2008;111:997-1004.
- Allieu Y, Winter M, Pequignot JP, de Mourgues P. Radial head replacement with a pyrocarbon head prosthesis: preliminary results of a multicentric prospective study. *Eur J Orthop Surg Traumatol* 2006;16:1-9.
- Cook SD, Beckenbaugh RD, Redondo J, et al. Long-term follow-up of pyrolytic carbon metacarpophalangeal implants. *T J Bone Joint Surg Am* 1999;81:635-48.
- Cook SD, Klawitter JJ, Weinstein AM. The influence of implant elastic modulus on the stress distribution around LTI carbon and aluminum oxide dental implants. *J Biomed Mater Res* 1981; 15:879-87.
- Gauci MO, Winter M, Dumontier C, et al. Clinical and radiologic outcomes of pyrocarbon radial head prosthesis: midterm results. *J Shoulder Elbow Surg* 2016;25:98-104.
- Hackl M, Wegmann K, Ries C, et al. Radiuskopfendoprothetik – Operationstechnik und eigene Ergebnisse. *Zeitschrift Orthop Unfallchirurgie* 2015;153:652-6.
- Ricón FJ, Sánchez P, Lajara F, et al. Result of a pyrocarbon prosthesis after comminuted and unreconstructable radial head fractures. *J Shoulder Elbow Surg* 2012;21:82-91.
- Sarris IK, Kyrkos MJ, Galanis NN, et al. Radial head replacement with the MoPyC pyrocarbon prosthesis. *J Shoulder Elbow Surg* 2012;21:1222-8.
- Morrey BF. Functional evaluation of the elbow. In: Morrey BF, Sanchez-Sotelo J, editors. *The Elbow and its Disorders*. 4 ed. Philadelphia Saunders/Elsevier; 2009. p. 80-91.
- Germann G, Harth A, Wind G, Demir E. [Standardisation and validation of the German version 2.0 of the Disability of Arm, Shoulder, Hand (DASH) questionnaire]. *Unfallchirurg* 2003;106:13-9.
- Halls AA, Travill A. Transmission of pressures across the elbow joint. *Anatom Record* 1964;150:243-7.
- Morrey BF, An KN, Stormont TJ. Force transmission through the radial head. *J Bone Joint Surg Am* 1988;70:250-6.
- Schneeberger AG, Sadowski MM, Jacob HA. Coronoid process and radial head as posterolateral rotatory stabilizers of the elbow. *J Bone Joint Surg Am* 2004;86:975-82.
- Burkhart KJ, Wegmann K, Dargel J, et al. Treatment of radial head and neck fractures: in favor of anatomical reconstruction. *Eur J Trauma Emerg Surg* 2012;38:593-603.
- Ikeda M, Sugiyama K, Kang C, et al. Comminuted fractures of the radial

- head. Comparison of resection and internal fixation. *J Bone Joint Surg Am* 2005;87:76-84.
35. Zwingmann J, Bode G, Hammer T, et al. Radial head prosthesis after radial head and neck fractures - current literature and quality of evidence. *Acta chirurgiae orthopaedicae et traumatologiae Cechoslovaca* 2015;82:177-85.
36. Laflamme M, Grenier-Gauthier PP, Leclerc A, et al. Retrospective cohort study on radial head replacements comparing results between smooth and porous stem designs. *J Shoulder Elbow Surg* 2017;26:1316-24.
37. Hackl M, Wegmann K, Koslowsky TC, et al. Rare implant-specific complications of the MoPyC radial head prosthesis. *J Shoulder Elbow Surg* 2017;26:830-7.
38. Burkhart KJ, Mattyasovszky SG, Runkel M, et al. Mid- to long-term results after bipolar radial head arthroplasty. *J Shoulder Elbow Surg* 2010;19:965-72.
39. Chien HY, Chen AC, Huang JW, et al. Short- to medium-term outcomes of radial head replacement arthroplasty in posttraumatic unstable elbows: 20 to 70 months follow-up. *Chang Gung Med J* 2010;33:668-78.