

Management of complete iliofemoral artery avulsion with a hybrid technique

Grace E. Mosley, BS,^a William Beckerman, MD,^b Jason C. Kovacic, MD,^c Annapoorna S. Kini, MD,^c Samin K. Sharma, MD,^c and Rami O. Tadros, MD,^b *New York, NY*

Transcatheter aortic valve replacement is a viable alternative for patients who are too high risk for traditional surgical aortic valve replacement, but it is not without risk of vascular complication. We report a case in which a hybrid stent and bypass graft technique was used to repair a complete iliofemoral artery avulsion after a transcatheter aortic valve replacement procedure. We believe that particular caution should be taken with patients with peripheral arterial disease in access vessels. Access vessel diameter must be considered in planning of procedures, and preprocedural preparation for potential major vascular complications is crucial for reducing morbidity and mortality. (*J Vasc Surg Cases* 2016;2:37-9.)

For many patients with aortic stenosis, surgical aortic valve replacement (SAVR) is not an option because of high operative risk secondary to comorbid conditions. Transcatheter aortic valve replacement (TAVR) is a viable and less invasive alternative that enables such patients to undergo valve replacement.¹ TAVRs, however, are associated with a greater risk of vascular complications.² We report a case in which a hybrid stent and bypass graft technique was used to repair a complete iliofemoral artery avulsion after TAVR. The patient's consent for publication was obtained.

CASE REPORT

A 78-year-old woman was referred for cardiac evaluation after detection of a murmur and worsening dyspnea, dizziness, and severely limiting fatigue. Transthoracic echocardiography revealed severe aortic stenosis (aortic valve area, 0.65 cm²; peak gradient, 68.0 mm Hg; mean gradient, 45.0 mm Hg). Peripheral pulses were nonpalpable, but Doppler signals were biphasic. Her Society of Thoracic Surgeons score was 2.95%, compounded by morbid obesity; preoperative computed tomography angiography revealed occlusive disease affecting the arch vessels (making a subclavian or axillary artery approach suboptimal) as well as circumferential calcification of the aorta and iliac arteries (common iliac artery [CIA] minimal luminal diameter, 8 mm; right and left external iliac artery, 6 and 7 mm, respectively). Deemed too high risk for SAVR, the decision was made to perform transfemoral TAVR.

From the Icahn School of Medicine at Mount Sinai^a; and the Division of Vascular Surgery, Department of Surgery,^b and Division of Cardiology, Department of Medicine,^c Mount Sinai Hospital.

Author conflict of interest: none.

Correspondence: Rami O. Tadros, MD, Division of Vascular Surgery, Icahn School of Medicine at Mount Sinai, 1425 Madison Ave, 4th Fl, Box 1273, New York, NY, 10029 (e-mail: rami.tadros@m Mountsinai.org).

The editors and reviewers of this article have no relevant financial relationships to disclose per the Journal policy that requires reviewers to decline review of any manuscript for which they may have a conflict of interest.

2352-667X

© 2016 The Authors. Published by Elsevier Inc. on behalf of Society for Vascular Surgery. This is an open access article under the CC BY-NC-ND license (<http://creativecommons.org/licenses/by-nc-nd/4.0/>).

<http://dx.doi.org/10.1016/j.jvsc.2016.03.002>

Because of the patient's peripheral arterial disease, extra precautions were taken in preparing her arteries for TAVR. After access was gained to the right common femoral artery (CFA), surgical cutdown of the left CFA was performed, and the distal external iliac artery and femoral bifurcation were exposed. Circumferential aortic and bilateral iliac calcification precluded use of a standard conduit. An attempt to deliver dilators before TAVR proved unsuccessful. Instead, bilateral long 7F vascular sheaths were delivered superior to the aortic bifurcation, and 7-mm iCast (Atrium Medical, Hudson, NH) covered stent grafts were placed from both CIAs to the distal aorta in a "kissing" fashion. The stent grafts were postdilated to 8 mm, allowing 24F outer diameter, the maximum possible for this aorta (11 mm at the aortic bifurcation). Left iliac bifurcation stenosis necessitated placement of a 7-mm bare-metal stent across the hypogastric artery origin. An 18F SoloPath (Terumo Interventional Systems, Somerset, NJ) balloon-expandable sheath (21F outer diameter) allowing controlled dilation was advanced into the aorta to facilitate aortic valve placement, which deployed successfully.

After TAVR deployment, an attempt was made to exchange the SoloPath sheath. There was some resistance to withdrawal of the sheath, not unexpected in atherosclerotic vessels. However, on sheath retraction, the iliac artery was found to be adherent to the sheath by the intraluminal stents (Fig 1). The iliofemoral artery had completely avulsed from the aortic to the femoral bifurcation, and the patient was hemorrhaging severely from the left groin incision. Manual pressure was held on the abdomen to stanch bleeding.

The patient became hemodynamically unstable and suffered transient cardiac arrest. Cardiac compressions and resuscitation were initiated. The contralateral pigtail catheter used for imaging was exchanged for an Amplatz wire, and an aortic occlusion balloon was rapidly inflated through a newly placed 11F sheath. Aortic control was obtained by occlusion balloon, and the patient began to regain hemodynamic stability.

Simultaneously, 11-mm Viabahn (W. L. Gore & Associates, Flagstaff, Ariz) stent grafts were deployed from the distal abdominal aorta toward the patent left CFA in a sequential fashion (while maintaining wire access on the contralateral side in case of right CIA compromise) with sufficient overlap to seal to below the inguinal ligament. The most distal Viabahn stent graft was clamped, and an aortogram showed no extravasation.

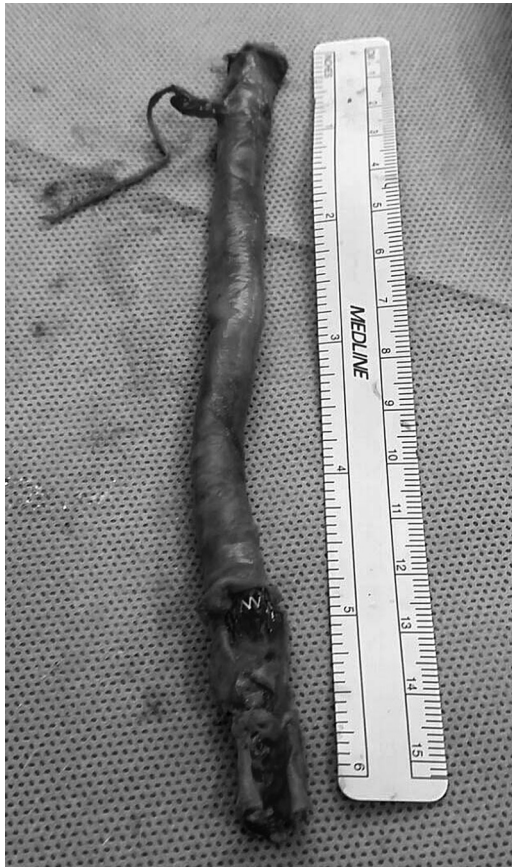

Fig 1. The avulsed iliofemoral artery. Adherence of the SoloPath sheath to the diseased artery by the stents caused complete avulsion from the common iliac artery (CIA) to the femoral bifurcation.

With the patient hemodynamically stable, a 7-mm Gore polytetrafluoroethylene graft was sewn to the left femoral bifurcation. A needle was introduced through the bypass graft into the Viabahn stent, through which a stiff guidewire was placed. Over the guidewire, the tract was dilated with an 8F sheath, and a series of 8-mm Viabahn stent grafts were telescoped into the established left-sided Viabahn grafts and into the bypass graft. These were postdilated to gain apposition, allowing inflow into the bypass.

Bypass graft and Viabahn stent were sutured closed, and the graft hood was repaired. The distal Viabahn stent graft end was triple ligated and clipped. Completion angiography showed excellent left lower extremity inflow (Figs 2 and 3). Both groins were closed, and the patient was transferred to the intensive care unit.

On postoperative day 1, the patient underwent emergent left leg four-compartment fasciotomy because of compartment syndrome, likely contributed to by 3 hours of leg ischemia from an occlusive sheath and clamping during avulsion management. The fasciotomy was successfully closed 2 weeks after initial surgery. After a lengthy intensive care unit stay, the patient was discharged 6 weeks postoperatively, ambulating fully and at baseline mental status.

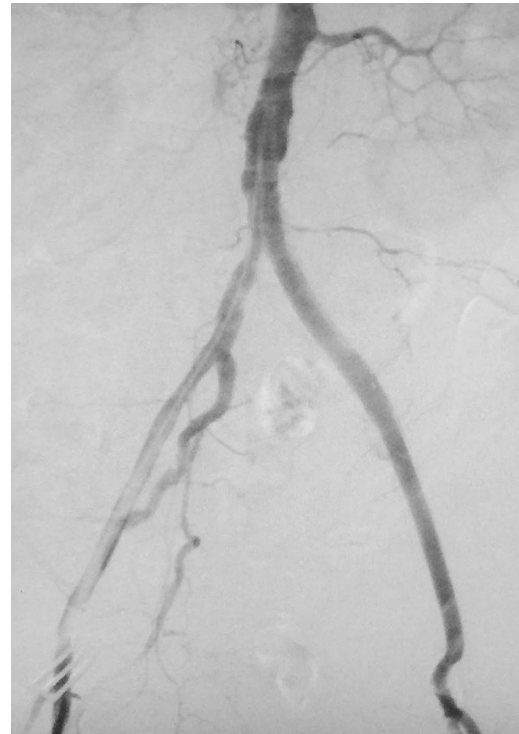

Fig 2. Completion angiogram shot from the contralateral femoral artery demonstrating excellent flow through newly constructed hybrid iliofemoral conduit to left lower extremity.

DISCUSSION

Although TAVR is better suited than SAVR to high-risk patients, it is not without significant complication risk. The most common TAVR complications are vascular access emergencies,³ with major and minor vascular complications occurring in approximately 11.9% and 9.7% of cases, respectively.⁴ Vascular events are largely limited to the iliac and femoral arteries, with iliac and femoral complications occurring at similar frequencies.⁵ Alternatives to transfemoral access for aortic valve replacement (not appropriate for this patient) include use of iliac conduits, upper extremity subclavian or axillary arterial accesses, transapical access, and direct aortic access.

Factors that place TAVR patients at greatest risk of vascular complications relate to specific device use and pre-existing vascular disease. Device-related risk factors are sheath to femoral artery ratio and use of large-caliber devices; vascular risk factors include tortuosity, heavy calcifications, and inadequate access vessel diameter.^{6,7} Whereas vascular injury may occur at any stage of the procedure, sheath advancement and exchange require extra caution. It should be considered that not all patients are candidates for transfemoral TAVR.

Our patient's circumferential iliac artery calcification and stenosis heightened her risk of vascular complications. We prepared for this by pretesting the aorta and pretesting the iliac arteries with postdilation to increase luminal

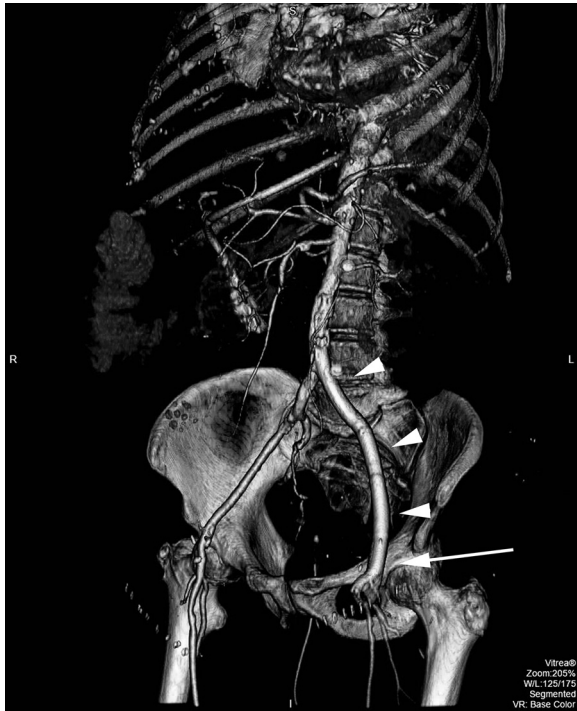


Fig 3. Three-dimensional reconstruction of postoperative computed tomography scan of the hybrid stent and bypass graft repair. The *arrowheads* point to Viabahn covered stents; the *arrow* shows the polytetrafluoroethylene graft material anastomosed to the native common femoral artery (CFA).

diameter to 8 mm and to reinforce the arteries. It is possible that these stents added stress to already diseased arteries, weakening vessel walls. Although this case used the expandable SoloPath sheath, in patients with stenotic and occlusive vasculature, it may be advisable to employ the collapsible SoloPath to limit injury risk during sheath removal, as anecdotal reports suggest that expandable sheaths are particularly difficult to remove in narrow vessels.

Our options for management of the avulsion were limited by diseased vasculature. Even in the most skilled hands, converting to an open procedure with direct aortic clamping would be less expedient than balloon occlusion through pre-existing femoral access. In addition, with the

patient's habitus, need for repositioning for retroperitoneal exposure, and more limited catheterization laboratory resources, an open approach was suboptimal. An alternative hybrid repair, aortouni-iliac stent graft placement with femoral-femoral bypass, may have been less technically challenging, but the patient's tenuous hemodynamics prevented occlusion balloon deflation.

This case exemplifies the importance of preparation for potential severe complications during TAVR, especially in patients with questionable access. Whereas complete avulsions are uncommon, immediate access to stent grafts, maintaining bilateral femoral access, and mounting an aortic occlusion balloon contralaterally during critical moments may help prevent loss of life and limb after a major vascular complication.

CONCLUSIONS

Hybrid stent and bypass graft repair is a viable option for management of iliofemoral avulsion after TAVR. Thorough preprocedural preparation for the possibility of major vascular complications, especially for patients with arterial disease, is likely to improve outcomes after vascular injury.

REFERENCES

1. Kodali SK, Williams MR, Smith CR, Svensson LG, Webb JG, Makkar RR, et al. Two-year outcomes after transcatheter or surgical aortic-valve replacement. *N Engl J Med* 2012;366:1686-95.
2. Smith CR, Leon MB, Mack MJ, Miller DC, Moses JW, Svensson LG, et al. Transcatheter versus surgical aortic-valve replacement in high-risk patients. *N Engl J Med* 2011;364:2187-98.
3. Rehders TC, Nienaber CA. Complications of stent graft placement in the thoracic aorta. In: Branchereau A, Jacobs M, editors. *Complications in vascular and endovascular surgery: part 1*. Armonk, NY: Futura; 2001. p. 185-92.
4. Genereux P, Head SJ, Van Mieghem NM, Kodali S, Kirtane AJ, Xu K, et al. Clinical outcomes after transcatheter aortic valve replacement using valve academic research consortium definitions: a weighted meta-analysis of 3,519 patients from 16 studies. *J Am Coll Cardiol* 2012;59:2317-26.
5. Obon-Dent M, Reul RM, Mortazavi A. Endovascular iliac rescue technique for complete arterial avulsion after transcatheter aortic valve replacement. *Catheter Cardiovasc Interv* 2014;84:306-10.
6. Fernandez JD, Craig JM, Garrett HE Jr, Burgar SR, Bush AJ. Endovascular management of iliac rupture during endovascular aneurysm repair. *J Vasc Surg* 2009;50:1293-9.
7. Hayashida K, Lefevre T, Chevalier B, Hovasse T, Romano M, Garot P, et al. Transfemoral aortic valve implantation: new criteria to predict vascular complications. *J Am Coll Cardiol* 2011;4:851-8.

Submitted Dec 2, 2015; accepted Mar 5, 2016.