

Case Report

# Traumatic corneal flap avulsion and loss 13 years after LASIK



Virgilio Galvis<sup>a,b,c</sup>; Alejandro Tello<sup>a,b,c,\*</sup>; Alvaro I. Ortiz<sup>c</sup>; María P. Quintero<sup>a,d</sup>; M. Margarita Parra<sup>a,d</sup>; Nicolás A. Blanco<sup>a,d</sup>

## Abstract

Postoperative flap displacements after Laser In Situ Keratomileusis (LASIK) are uncommon complications, and flap losses are even less frequent, occurring most commonly within 24 hours after the procedure. Although cases of late subluxation have been reported up to 14 years after the surgery, the longest reported time after surgery for late flap loss is four years after LASIK. We report a case of a 54-year-old man that presented a traumatic total flap avulsion and loss 13 years after LASIK. According to our knowledge, this is the longest time reported in such a case in the literature. Medical treatment yielded an acceptable visual result. This case reinforces the concept that there could be a lifelong potential risk of traumatic corneal flap loss after LASIK.

**Keywords:** Myopia, Laser In Situ Keratomileusis complications, Corneal injuries, Laser corneal surgery

© 2018 The Authors. Production and hosting by Elsevier B.V. on behalf of Saudi Ophthalmological Society, King Saud University. This is an open access article under the CC BY-NC-ND license (<http://creativecommons.org/licenses/by-nc-nd/4.0/>).  
<https://doi.org/10.1016/j.sjopt.2018.08.001>

## Introduction

Laser Assisted In Situ Keratomileusis (LASIK) flap complications occur more frequently in the early postoperative period.<sup>1</sup> However, traumatic dislocations have occurred up to 14 years after the procedure.<sup>2</sup> On the other hand, total avulsion of the LASIK corneal flap (sometimes with flap loss) is much less common. This event has been related with intraoperative free caps but also has been reported in English literature in five cases of hinged flaps up to four years after initial surgery.<sup>3–9</sup> According to our knowledge, this is the first report of traumatic loss of a LASIK flap occurring so late (13 years) postoperatively.

## Case report

A 54-year-old man had undergone uneventful LASIK (nasal hinged flap using an Automated Corneal Shaper microkeratome with a 160 microns plate) in both eyes (OU) in 2001 for the correction of composed myopic astigmatism. Preoperative pachymetries were 522 and 521 microns in the right and left eyes respectively (Orbiscan IIz, Bausch & Lomb, New York, U.S.A.). Planned tissue ablation was 107 microns in both eyes. The postoperative refraction seven months after the surgery was +0.25 Diopters (D) OU, and uncorrected distance visual acuity (UDVA) was 20/20 OU.

Thirteen years later he hit his right eye with a wooden handle of a floor dustpan. At presentation, seven hours later, his UDVA in the right eye (OD) was counting fingers at one meter. Slit-lamp examination showed in the right eye

Received 2 June 2017; received in revised form 12 June 2018; accepted 6 August 2018; available online 15 August 2018.

<sup>a</sup> Fundación Oftalmológica de Santander FOSCAL, Ophthalmology Department, Floridablanca, Colombia

<sup>b</sup> Universidad Autónoma de Bucaramanga, Faculty of Health Sciences, Bucaramanga, Colombia

<sup>c</sup> Centro Oftalmológico Virgilio Galvis, Floridablanca, Colombia

<sup>d</sup> Universidad Industrial de Santander, Faculty of Health, Bucaramanga, Colombia

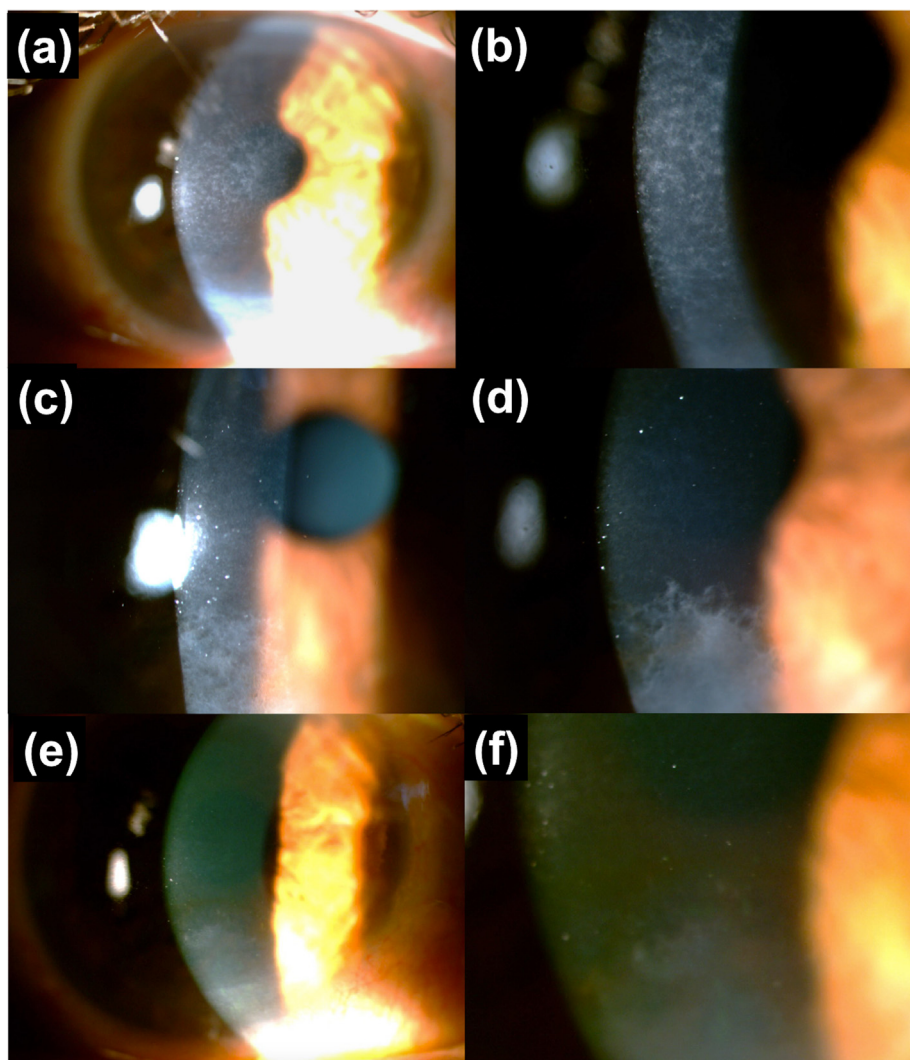
\* Corresponding author at: Centro Oftalmológico Virgilio Galvis, Centro Médico Ardila Lülle, 3rd Floor, Module 7, Floridablanca, Santander, Colombia. Fax: +57 7 6392626.

e-mail address: [atello579@unab.edu.co](mailto:atello579@unab.edu.co) (A. Tello).

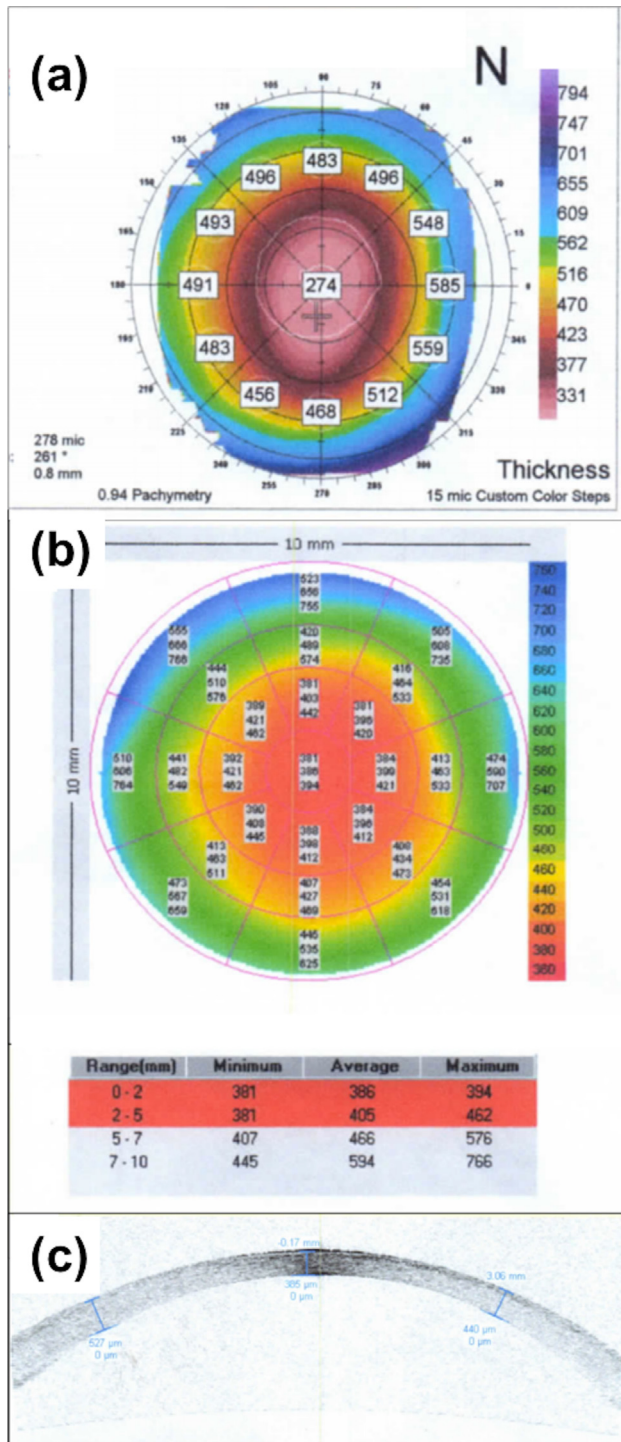
absence of the corneal LASIK flap. Gatifloxacin 0.3 % and sodium hyaluronate 0.4 % were prescribed. One month later his refraction was:  $-1.50 -3.00 \times 20^\circ$  and the corrected distance visual acuity (CDVA) was 20/40. Slit-lamp examination showed corneal granular haze involving visual axis (Fig. 1a, b). Pachymetry map of Orbscan IIz topographer reported a central mean measurement of 274 microns, however, Visante OCT reported 386 microns (Fig. 2). The thinner thickness reported by the Orbscan IIz was considered inaccurate due to the presence of corneal haze (and it was confirmed, when a new Orbscan IIz was obtained 21 months later found 349 microns). Sagittal (keratometric) map of Orbscan showed irregular astigmatism (Fig. 3a). Fluorometholone 0.1 % was prescribed and tapered off during the next 8 weeks. Two months later right eye UDVA was 20/50; refraction:  $-1.25 -2.50 \times 30^\circ$  and CDVA 20/25; corneal haze become mild in the central cornea and the symptoms improved. However, a denser area of corneal haze became evident in the inferior paracentral and peripheral cornea (Fig. 1c). 21 months after the trauma, in the right eye UDVA was: 20/100; refraction

was  $+0, 50 -2.00 \times 25^\circ$  and CDVA 20/30. Dense corneal haze was affecting the inferior cornea, without compromising the visual axis (Fig. 1d). The left eye had uncorrected visual acuity of 20/25 and refraction was  $+0.25 -0.25 \times 140^\circ$ , with CDVA 20/20. At the last follow-up visit, 38 months after the flap loss, OD refraction was  $+1.00 -2.00 \times 25$  and CDVA 20/30. Corneal haze was less noticeable (Fig. 1e,f). Topographic pattern changed when compared to one month after the injury, persisting some irregular astigmatism (Fig. 3b,c). Right eye central pachymetry was 383 with the Sirius tomographer (CSO, Florence, Italy) and 388 microns with Anterior Segment OCT Triton (Topcon, Tokyo, Japan). In the left eye, in comparison, it was 457 with both devices (Fig. 3d,e).

According to the anterior segment OCT imaging, the difference in central corneal thickness between the two eyes (69 microns) was determined mainly by the absence of Bowman membrane in the right eye along with a difference of around 53 microns in the thickness of the stroma, since the epithelium layer, also lost with the corneal flap, completely regenerated (Fig. 3d,e).



**Fig. 1.** Right eye. (a): Corneal haze one month after traumatic flap avulsion. (b): Closer view. (c) Corneal haze in the visual axis diminished by the third month but the density of paracentral and peripheral inferior haze increased. (d) 21 months after the trauma inferior haze reached its peak. (e, f) At the last checkup visit 38 months after traumatic corneal flap avulsion paracentral and peripheral inferior haze had reduced its density.



**Fig. 2.** (a): Pachymetry map one month after the trauma with the Orbscan IIz system reported 274 microns, which was considered inaccurate due to the presence of haze. (b) and (c): Visante OCT measured a central pachymetry of 386 microns.

## Discussion

A study performed on human eye bank corneas from donors that had LASIK showed that the mean peak tensile strength of the flap wound margin reached a maximum value of around 28.1% of control corneas (between 3.5 and

6.5 years after LASIK) but the central and paracentral LASIK wounds reached only 2.4% of its normal strength.<sup>10</sup>

Late LASIK flap dislocation cases have been reported up to 14 years after surgery.<sup>2</sup>

Although a rare event, with enough force a LASIK corneal flap may be completely avulsed, and sometimes loss. Searching the MEDLINE literature database through PubMed interface we found that only 12 cases have been reported in the English literature (Table 1).<sup>3-9</sup>

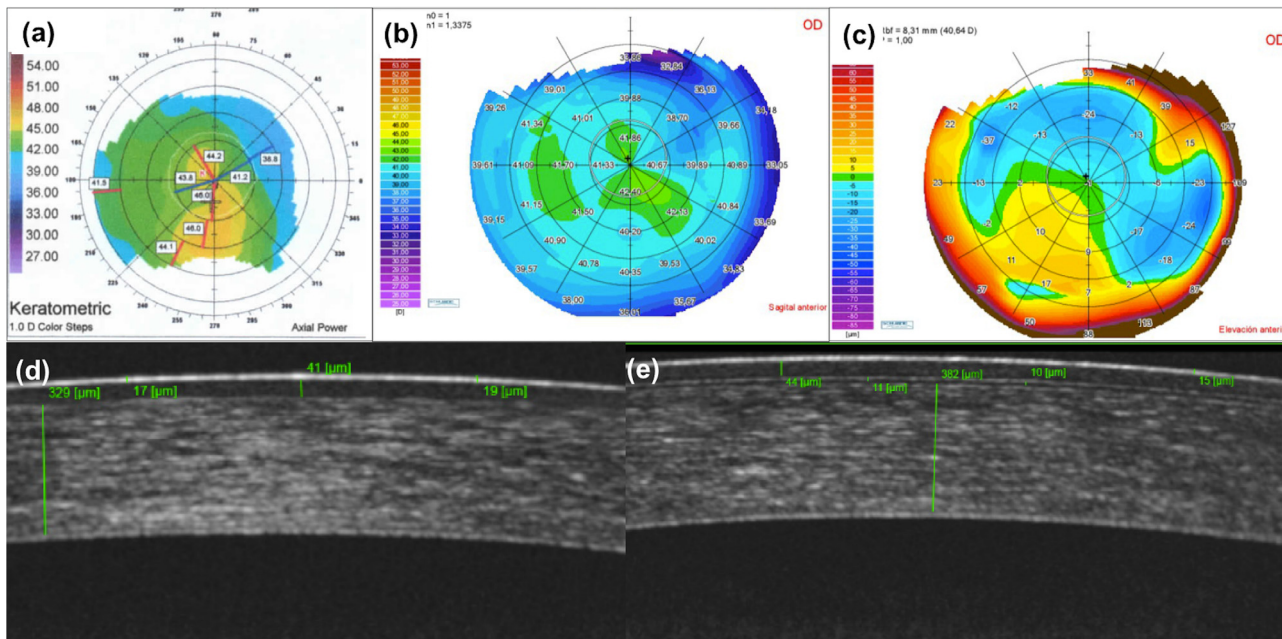
Two of the published cases in English were free caps, and in the remaining ten cases of hinged flaps traumatically avulsed, specific mechanisms included: pulling with a finger while removing a contact lens (one case)<sup>3</sup>; hitting with a tree branch (one case)<sup>5</sup>; hitting with a finger of another person (two cases)<sup>6,7</sup> and being struck by a tool (one case).<sup>8</sup> No clear mechanism was determined in another case<sup>4</sup> and no clinical data were provided about four mentioned by Xiao et al. in their series from China published in 2014.<sup>9</sup> Final corrected distance visual acuity ranged from 20/15 to 20/70.<sup>2-9</sup> Refractive errors, before any additional refractive surgical procedure, were very varied: one eye was emmetropic<sup>7</sup>; one eye showed low mixed astigmatism<sup>5</sup>; four eyes showed moderate myopic astigmatism,<sup>3,4,6</sup> and one eye had high myopic astigmatism that required additional photorefractive keratectomy.<sup>8</sup>

Significant visual symptoms (dysphotopsia) remained as sequela in one case.<sup>6</sup>

In our case, the final refraction showed mixed astigmatism with a corrected vision of 20/30. The decrease in corrected visual acuity may be related to the presence of paracentral haze and irregular astigmatism (Figs. 2 and 3). In several of the reported cases it is mentioned that mild central corneal haze was observed, and in two cases corrected distance visual acuity (CDVA) was lower than 20/40 (Table 1). Thomas and Tanzer applied mitomycin C after the traumatic avulsion in order to diminish the risk of haze, with good visual results (CDVA: 20/20<sup>-1</sup>).<sup>7</sup> It is possible that if we had used that medication the results in the present case might have been better.

A striking point is that the patient reported here initially had central haze, which disappeared, but also presented corneal haze in the lower mid-periphery that developed since the third month after the trauma. This type of haze has not been reported in the other cases of traumatic avulsion of the LASIK flap (Table 1). We evaluated the possibility of phototherapeutic keratectomy and mitomycin C but, since the density of the corneal haze diminished between 21 and 38 months after the trauma (Fig. 1 d-f) and also because the patient felt comfortable with his binocular vision because the distance corrected visual acuity was not so affected (20/30), we decided to maintain him in observation.

The fact that in our patient avulsion of the flap presented 13 years after surgery, highlights the possible consequences of ocular trauma in eyes with LASIK flaps even long time after the surgery. To our knowledge, this is the first report of traumatic loss of a LASIK flap occurring more than 10 years after the procedure, which confirms that wound resistance of the corneal interface probably will never have a normal tensile strength. Flap loss may lead to an unpredictable residual refractive change, as seen in several of the published cases and in our patient.<sup>3-7,9</sup> Undoubtedly the most important issue with this kind of flap related complication is prevention.



**Fig. 3.** (a): Sagittal map of Orbscan IIz one month after the flap avulsion. Sagittal (b) and anterior elevation (c) maps from the Sirius 38 months after the trauma. The presence of irregular astigmatism persists, albeit to a lesser extent. Anterior segment OCT right (d), and left (e) eyes, 38 months after the LASIK flap avulsion in right eye. In the right eye there is not evidence of Bowman membrane (as expected after losing the LASIK flap), which is clearly visible in the left eye as a 10 to 11 microns thick layer below the epithelium. The stroma in the central cornea is 53 microns thinner in the right eye, due to the loss of the flap. In the left eye the interface between the LASIK flap performed 16 years earlier and the stromal bed, is not distinctly observable.

**Table 1.** Reported cases complete avulsion of corneal LASIK flap.

Author(s), Year	Postoperative time when subluxation/avulsion occurred	Trauma mechanism	Management	Final UDVA//CDVA// Refraction
Sridhar et al. <sup>3</sup> , 2001	10 days	Accidental self-removal with the fingers when removing a contact lens.	Patching and bandage soft contact lens	<b>UDVA:</b> Not reported. <b>CDVA:</b> 20/70 <sup>**</sup> <b>Refraction:</b> -0.75 -0.75 × 77
Eggink et al. <sup>4</sup> , 2002	Case 1: 1 day	Not clear. Thin flap, extreme blinking.	Phototherapeutic keratectomy (PTK) one month postoperatively.	<b>UDVA:</b> 20/125 <b>CDVA:</b> 20/50 <sup>**</sup> <b>Refraction:</b> Plano -5.00 × 22
	Case 2: 9 days	Intraoperative free cap. Hit with an elastic wrapper	Patching Chloramphenicol 0.5% Fluorometholone	<b>UDVA:</b> 20/50 <b>CDVA:</b> 20/25 <sup>**</sup> <b>Refraction:</b> -2.50 -0.75 × 75
	Case 3: First day (replaced) and 10 days (loss)	Intraoperative free cap. Accidental self-removal with the fingers when removing a bandage contact lens. No data on the second event of flap loss.	Flap suturing with 4 interrupted 10-0 nylon sutures. Epithelial ingrowth scraping. After scraping, presented flap loss for the second time.	<b>UDVA:</b> 20/40 <b>CDVA:</b> 20/25 <sup>**</sup> <b>Refraction:</b> -0.50 -2.00 × 15
Haw and Manche <sup>5</sup> , 2004	5 months	Hit with a tree branch with loss of the flap. It was recovered from the ground 8 hours later and replaced	Realignment and flap suturing with 8 interrupted 10-0 nylon sutures.	<b>UDVA:</b> 20/25 <b>CDVA:</b> 20/20 <b>Refraction:</b> 0.25 -0.75 × 162
Tetz et al. <sup>6</sup> , 2007	41 months	Struck by the finger of another person (karate).	Bandage contact lens. Dexamethasone eyedrops.	<b>UDVA:</b> Not reported <b>CDVA:</b> 20/20 <sup>**</sup> <b>Refraction:</b> -1.75 -0.50 × 30
Thomas and Tanzer <sup>7</sup> , 2009	2 months (femtosecond LASIK)	Hit by another person's finger	Application of mitomycin-C 0.01% for 1 minute in the stromal bed. Bandage contact lens. Gatifloxacin. Prednisolone.	<b>UDVA:</b> 20/20 <sup>-2</sup> <b>CDVA:</b> 20/20 <sup>-1</sup> <b>Refraction:</b> -0.50
Motwani et al. <sup>8</sup> , 2011	4 years	Hit with a shovel	Photorefractive keratectomy (PRK) with mitomycin-C. fluorometholone	<b>UDVA:</b> 20/200 <b>CDVA:</b> 20/25 <sup>+2*</sup> <b>Refraction:</b> -5.00 -1.25 × 90° <b>After PRK:</b> <b>UDVA:</b> 20/15

(continued on next page)

Table 1 (continued)

Author(s), Year	Postoperative time when subluxation/avulsion occurred	Trauma mechanism	Management	Final UDVA//CDVA// Refraction
Xiao et al. <sup>9</sup> , 2014	Four cases of total or partial NA flap loss. Time after surgery not indicated.		NA	NA

UDVA: Uncorrected distance visual acuity.

CDVA: Corrected distance visual acuity.

\* Visual acuity 10 days after the flap loss. Central stromal haze was present.

\*\* Mild central haze was present.

According to the published evidence, it seems that there could be a lifelong potential risk of traumatic flap complications after LASIK, so it is very important to inform the patients about that possibility and teach them basic principles of eye protection to diminish the chance of eye trauma. Although these preventive strategies are more important during the first month, basic protective measures must be maintained permanently.

### Conflict of interest

The authors declare that there is no conflict of interest regarding the publication of this article.

### References

- Galvis V, Tello A, Guerra AR, Rey JJ, Camacho PA. Risk factors and visual results in cases of LASIK flap repositioning due to folds or dislocation: case series and literature review. *Int Ophthalmol* 2014;**34**:19–26.
- Holt DG, Sikder S, Mifflin MD. Surgical management of traumatic LASIK flap dislocation with macrostriae and epithelial ingrowth 14 years postoperatively. *J Cataract Refract Surg* 2012;**38**:357–61.
- Sridhar MS, Rapuano CJ, Cohen EJ. Accidental self-removal of a flap: a rare complication of laser in situ keratomileusis surgery. *Am J Ophthalmol* 2001;**132**:780–2.
- Eggink FA, Eggink CA, Beekhuis WH. Postoperative management and follow-up after corneal flap loss following laser in situ keratomileusis. *J Cataract Refract Surg* 2002;**28**:175–9.
- Haw WW, Manche EE. Successful corneal flap replacement following complete traumatic flap amputation after laser-assisted in situ keratomileusis. *Arch Ophthalmol* 2004;**122**:275–6.
- Tetz M, Werner L, Müller M, Dietze U. Late traumatic LASIK flap loss during contact sport. *J Cataract Refract Surg* 2007;**33**:1332–5.
- Thomas KE, Tanzer DJ. Visual acuity recovery after late traumatic femtosecond laser in situ keratomileusis flap loss. *J Cataract Refract Surg* 2009;**35**:1134–7.
- Motwani M, Lizano GJ, Yam K, English C. Photorefractive keratectomy after late traumatic LASIK flap loss. *J Refract Surg* 2011;**27**:542–4.
- Xiao J, Jiang C, Zhang M, Jiang H, Li S, Zhang Y. When case report became case series: 45 cases of late traumatic flap complications after laser-assisted in situ keratomileusis and review of Chinese literature. *Br J Ophthalmol* 2014;**98**:1282–6.
- Schmack I, Dawson DG, McCarey BE, Waring 3rd GO, Grossniklaus HF, Edelhauser HF. Cohesive tensile strength of human LASIK wounds with histologic ultrastructural, and clinical correlations. *J Refract Surg* 2005;**21**:433–45.