

EUS-guided transmural drainage of hemorrhagic pancreatic fluid collections without associated arterial pseudoaneurysms

Dear Editor,

Pancreatic fluid collections (PFCs) are an important local consequence of both acute and chronic pancreatitis. The PFC can present with a number of complications including pain, infection, gastric outlet obstruction, biliary infection, and hemorrhage into the cyst. Intracystic bleeding is a rare but potentially lethal complication of pancreatitis that commonly occurs due to a leaking pseudoaneurysm (PA).^[1] Bleeding pseudocysts with arterial PA are treated surgically or a combined radiological and endoscopic approach of initial angioembolization followed by either endoscopic transpapillary or transmural drainage.^[2,3] However, all patients with intracystic bleed do not have an arterial PA, and other causes such as venous bleeding and diffuse small-vessel hemorrhage from the walls of PFC can also lead to bleed into the PFC.^[4] The management of hemorrhagic PFCs without a detectable PA either on computed tomography angiography (CTA) or EUS is a therapeutic dilemma. Because of better ability to identify the cause as well as control the bleed, most of these patients are treated surgically. The experience with endoscopic transmural drainage of such hemorrhagic PFCs is limited, and therefore, we retrospectively evaluated the safety and efficacy of endoscopic transmural drainage in patients with hemorrhagic PFC without a detectable PA.

The records of 13 patients (mean age: 35.9 ± 6.9 years; 11 males) with hemorrhagic PFC without a detectable PA either on CTA or EUS seen over the last 10 years and treated with EUS-guided transmural drainage were retrieved and analyzed. All the studied patients had bled into the PFC as demonstrated on CT abdomen as a collection with a high-attenuated fluid and/or fluid–fluid levels or hyperdense contents and confirmed by aspiration of hemorrhagic fluid during EUS-guided drainage [Figure 1]. After obtaining informed consent, patients underwent EUS-guided transmural drainage of

the hemorrhagic PFC [Figure 1]. Postprocedure patients were admitted and carefully watched for bleeding. The treatment success was defined as symptomatic improvement with resolution of PFC on cross-sectional imaging with no need for rescue surgery.

The etiology of pancreatitis was alcohol, gallstones, and idiopathic in 8, 2, and 3 patients, respectively. Five (38%) patients presented with abdominal pain and gastrointestinal bleed whereas 8 (62%) patients presented with increasing abdominal pain only. The mean size of PFC was 11.1 ± 2.7 cm, and CT revealed high-attenuation fluid in all the patients. Eleven (85%) patients had coexistent splenic vein thrombosis and perigastric venous collaterals, but none had esophagogastric varices. EUS demonstrated prominent vessels in the wall of the PFC in 3 (23%) patients. Endoscopic drainage was technically successful in all 13 patients, and 9 patients underwent transmural drainage with multiple plastic stents whereas 4 patients

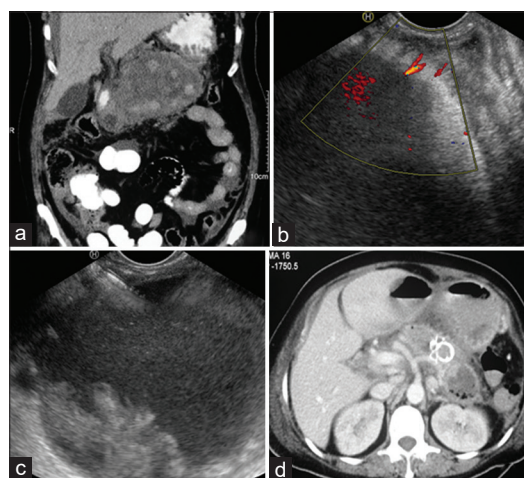


Figure 1. (a) Computed tomography abdomen: Pancreatic fluid collection with hyperdense contents. (b) EUS: small-caliber vessels in the wall of pancreatic fluid collection. (c) EUS-guided drainage of pancreatic fluid collection. Echogenic contents suggestive of blood seen in the collection. (d) Computed tomography abdomen: Resolution of pancreatic fluid collection postlumen-apposing metal stent insertion

were treated with lumen-apposing metal stents. Direct endoscopic necrosectomy was needed in 3 (23%) patients. The PFC resolved in all patients within 20.6 ± 5.9 days. None of the treated patients developed postprocedural bleeding nor any patient required postprocedure blood transfusion. Following resolution of PFC, patients underwent magnetic resonance cholangiopancreatography and plastic transmural stents were left for indefinite period in patients with disconnected pancreatic duct ($n = 5$). In the remaining 8 patients, transmural stents could be removed uneventfully. There has been no recurrence of PFC in successfully treated patients.

In conclusion, endoscopic transmural drainage seems to be safe and effective in patients with hemorrhagic PFC without a detectable PA.

Financial support and sponsorship

Nil.

Conflicts of interest

Surinder Singh Rana is an Editorial Board Member of the journal. The article was subject to the journal's standard procedures, with peer review handled independently of this Member and his research groups.

Surinder Singh Rana¹, Ravi Sharma¹, Rajesh Gupta²

¹Department of Gastroenterology, Postgraduate Institute of Medical Education and Research, Chandigarh, India;

²Department of Surgical Gastroenterology, Postgraduate Institute of Medical Education and Research, Chandigarh, India

Address for correspondence

Prof. Surinder Singh Rana,

Department of Gastroenterology, Postgraduate Institute of Medical Education and Research, Chandigarh - 160 012, India.

E-mail: drsurinderrana@gmail.com

Received: 2021-02-05; **Accepted:** 2021-05-06;

Published online: 2021-09-03

REFERENCES

1. Masatsugu T, Yamaguchi K, Yokohata K, *et al.* Hemorrhagic pseudocyst and pseudocyst with pseudoaneurysm successfully treated by pancreatectomy: Report of three cases. *J Hepatobiliary Pancreat Surg* 2000;7:432-7.
2. Rana SS, Kumar A, Lal A, *et al.* Safety and efficacy of angioembolisation followed by endoscopic ultrasound guided transmural drainage for pancreatic fluid collections associated with arterial pseudoaneurysm. *Pancreatology* 2017;17:658-62.
3. Bhasin DK, Rana SS, Sharma V, *et al.* Non-surgical management of pancreatic pseudocysts associated with arterial pseudoaneurysm. *Pancreatology* 2013;13:250-3.
4. Balthazar EJ, Fisher LA. Hemorrhagic complications of pancreatitis: Radiologic evaluation with emphasis on CT imaging. *Pancreatology* 2001;1:306-13.

This is an open access journal, and articles are distributed under the terms of the Creative Commons Attribution-NonCommercial-ShareAlike 4.0 License, which allows others to remix, tweak, and build upon the work non-commercially, as long as appropriate credit is given and the new creations are licensed under the identical terms.

Access this article online	
Quick Response Code: 	Website: www.eusjournal.com
	DOI: 10.4103/EUS-D-21-00045

How to cite this article: Rana SS, Sharma R, Gupta R. EUS-guided transmural drainage of hemorrhagic pancreatic fluid collections without associated arterial pseudoaneurysms. *Endosc Ultrasound* 2021;10:396-7.

© 2021 Spring Media Publishing Co. Ltd | Published by Wolters Kluwer - Medknow