



Since January 2020 Elsevier has created a COVID-19 resource centre with free information in English and Mandarin on the novel coronavirus COVID-19. The COVID-19 resource centre is hosted on Elsevier Connect, the company's public news and information website.

Elsevier hereby grants permission to make all its COVID-19-related research that is available on the COVID-19 resource centre - including this research content - immediately available in PubMed Central and other publicly funded repositories, such as the WHO COVID database with rights for unrestricted research re-use and analyses in any form or by any means with acknowledgement of the original source. These permissions are granted for free by Elsevier for as long as the COVID-19 resource centre remains active.



Case Report

Re-infection with a different SARS-CoV-2 clade and prolonged viral shedding in a hematopoietic stem cell transplantation patient[☆]



Abeer N. Alshukairi^a, Sherif A. El-Kafrawy^{b,c}, Ashraf Dada^d, Muhammad Yasir^{b,c}, Amani H. Yamani^a, Mohammed F. Saeedi^a, Ahmed Aljohaney^{a,e}, Naif I. AlJohani^f, Husam A. Bahauden^g, Intikhab Alam^h, Takashi Gojobori^h, Aleksandar Radovanovic^h, Thamir A. Alandijany^{b,c}, Norah A. Othman^b, Tagreed L. Alsubhi^b, Ahmed M. Hassan^b, Ahmed M. Tolah^b, Jaffar A. Al-Tawfiq^{i,j,k}, Alimuddin Zumla^{l,m}, Esam I Azhar^{b,c,*}

^a Department of Medicine, King Faisal Specialist Hospital and Research Center, Jeddah, Saudi Arabia

^b Special Infectious Agents Unit-BSL3, King Fahd Medical Research Center, King Abdulaziz University, Jeddah, Saudi Arabia

^c Department of Medical Laboratory Technology, Faculty of Applied Medical Sciences, King Abdulaziz University, Jeddah, Saudi Arabia

^d Department of Pathology and Laboratory Medicine, King Faisal Specialist Hospital and Research Center, Jeddah, Saudi Arabia

^e Department of Internal Medicine, Faculty of Medicine, King Abdulaziz University, Jeddah, Saudi Arabia

^f Adult Hematology and Bone Marrow Transplant Section, Oncology Department, King Faisal Specialist Hospital and Research Center, Jeddah, Saudi Arabia

^g Department of Medicine, College of Medicine, King Saud bin Abdulaziz University for Health Sciences, Jeddah, Saudi Arabia

^h Computational Bioscience Research Centre, King Abdullah University of Science and Technology, Thuwal, Saudi Arabia

ⁱ Infectious Disease Unit, Specialty Internal Medicine, Johns Hopkins Aramco Healthcare, Dhahran, Saudi Arabia

^j Infectious Disease Division, Department of Medicine, Indiana University School of Medicine, Indianapolis, Indiana, USA

^k Infectious Disease Division, Department of Medicine, Johns Hopkins University School of Medicine, Baltimore, Maryland, USA

^l Division of Infection and Immunity, Centre for Clinical Microbiology, University College London Royal Free Campus, London, UK

^m NIHR Biomedical Research Centre, UCL Hospitals NHS Foundation Trust, London, UK

ARTICLE INFO

Article history:

Received 22 May 2021

Revised 12 July 2021

Accepted 14 July 2021

KEYWORDS:

SARS-CoV-2

Re-infection

Prolonged viral shedding

Immunocompromised

Hematological stem cell transplant

COVID-19

ABSTRACT

Immunocompromised patients who have a severe acute respiratory syndrome coronavirus 2 (SARS-CoV-2) infection pose many clinical and public health challenges. We describe the case of a hematopoietic stem cell transplantation patient with lymphoma who had a protracted illness requiring three consecutive hospital admissions. Whole genome sequencing confirmed two different SARS-CoV-2 clades. Clinical management issues and the unanswered questions arising from this case are discussed.

© 2021 The Author(s). Published by Elsevier Ltd on behalf of International Society for Infectious Diseases.

This is an open access article under the CC BY-NC-ND license (<http://creativecommons.org/licenses/by-nc-nd/4.0/>)

1. Introduction

The coronavirus disease 2019 (COVID-19) pandemic continues to spread worldwide (WHO 2020). Understanding severe acute respiratory syndrome coronavirus 2 (SARS-CoV-2) shedding, transmission dynamics, and re-infection with different SARS-CoV-2 clades

in immunocompromised persons is an important clinical and public health challenge (Choi et al., 2020).

2. Case presentation (Figure 1A)

2.1. First admission to hospital

A 51-year-old female patient presented with a 3-day history of fever, cough, malaise, and headache. Several of her family members had recently been ill with SARS-CoV-2 infection. PCR on her nasopharyngeal swab was positive for SARS-CoV-2 (cycle threshold (Ct) value of 3) and a clinical diagnosis of COVID-19 was made. Five years prior to this admission, the patient had been diagnosed with follicular non-Hodgkin lymphoma and had received an au-

[☆] Abeer N. Alshukairi, Sherif A. El-Kafrawy, Alimuddin Zumla, and Esam I. Azhar contributed equally.

* Corresponding author: Esam I. Azhar, Special Infectious Agents Unit-BSL3, King Fahad Medical Research Center, King Abdulaziz University, Jeddah, Saudi Arabia. Tel: +966 566615222.

E-mail address: eazhar@kau.edu.sa (E.I. Azhar).

tologous hematopoietic stem cell transplantation (ASCT) for which she received multiple courses of chemotherapy. She had experienced a relapse of lymphoma, and remission was achieved on rituximab therapy. She was also receiving monthly intravenous immunoglobulins (IVIG) for lymphoma-associated hypogammaglobulinemia. She was admitted to hospital and received a 7-day course of intravenous ceftriaxone for pneumonia. She improved clinically and was discharged home on day 7 post admission. The patient did not receive remdesivir, since it was not available in the hospital during this period. She did not receive steroids during this admission.

2.2. Second hospital admission

On day 19 post first admission, she was re-admitted to hospital with fever, cough, and dyspnea. Her oxygen saturation was 96% on room air and a chest X-ray showed bilateral lung infiltrates. PCR of a nasopharyngeal swab was positive for SARS-CoV-2, with a Ct value of 13. A chest computed tomography (CT) scan showed diffuse bilateral ground glass opacities. She received steroids, meropenem, and IVIG. Two weeks after her admission, she received methylprednisolone 1 mg/kg IV daily for three days followed by 0.5 mg/kg iv daily for two days. SARS-CoV-2 serology was negative by both ELISA and microneutralization antibody test (MNT) on day 40. She was discharged after 3 weeks of hospitalization and managed in the outpatient setting for presumed cryptogenic organizing pneumonia. She received 40 mg of prednisolone daily for 10 days, followed by tapering doses of prednisolone over 1 month. She then received 30 mg of prednisolone daily for 3 weeks, followed by tapering doses of prednisolone over another month. Her fever improved but she had persistent exertional dyspnea. The patient re-presented to the emergency room (ER) with fever and feeling unwell on day 114. PCR of a nasopharyngeal swab was positive for SARS-CoV-2 (Ct value of 17). She was prescribed a 7-day course of ciprofloxacin for pneumonia and sent home.

2.3. Third hospital admission

The patient was readmitted on day 160 with a history of progressive fever and dyspnea over several weeks since her last visit to the ER. Her nasopharyngeal swab PCR was positive for SARS-CoV-2 (Ct value of 34). A plaque assay for the tested samples showed a high viral load for both the nasopharyngeal (NP) sample on day 31 and bronchoalveolar lavage (BAL) sample on day 168 compared to the positive control, even at the highest dilution (10^6) (**Supplementary Material** Figure S1). A chest CT scan showed new ground glass opacities with air bronchogram in the right and left lower lobes. She received intravenous antibiotics (meropenem and linezolid) and dexamethasone. Bronchoscopy was performed, and BAL cytology showed reactive bronchial epithelial cells, alveolar macrophages, and mixed inflammatory cells, with no cytopathic effect noted. Bacterial, fungal, and mycobacterial cultures, as well as special stains for fungi and acid-fast bacilli, were negative. Her serum cytomegalovirus (CMV) PCR was negative. Lymphocyte analysis were performed twice, at 6 weeks and 5 months post infection, and showed a CD19 B lymphocyte count of less than 1 cell/ μ l. The patient's CD4 count was 540 (normal range 564–1721) and her CD8 count was 1670 (normal range 322–1161). Serum IgG levels were normal during all of the patient's admissions. Five months into the third admission, repeat SARS-CoV-2 serology on day 165 was still negative (ELISA and MNT). Convalescent plasma (200 ml, SARS-CoV-2 neutralization titer 1:160) was administered as a therapeutic option, after which her COVID-19-related pneumonia resolved, and she was discharged home. The patient was then evaluated in the infectious disease outpatient clinic on day 188. She had no fever or respiratory symptoms, and SARS-CoV-2 PCR on a

nasopharyngeal swab was negative. The SARS-CoV-2 serology remained negative on day 213. SARS-CoV-2 T cell immune responses were not available in the institution and it was not possible to out-source to an international laboratory in view of travel restrictions during the COVID-19 pandemic.

2.4. mRNA COVID-19 vaccination and post vaccine serology

The patient received one dose of mRNA COVID-19 vaccine 6 months following her third admission. Six weeks following her vaccination, SARS-CoV-2 neutralization testing was still negative.

2.5. Laboratory methods and findings

See **Supplementary Material** Appendix 1.

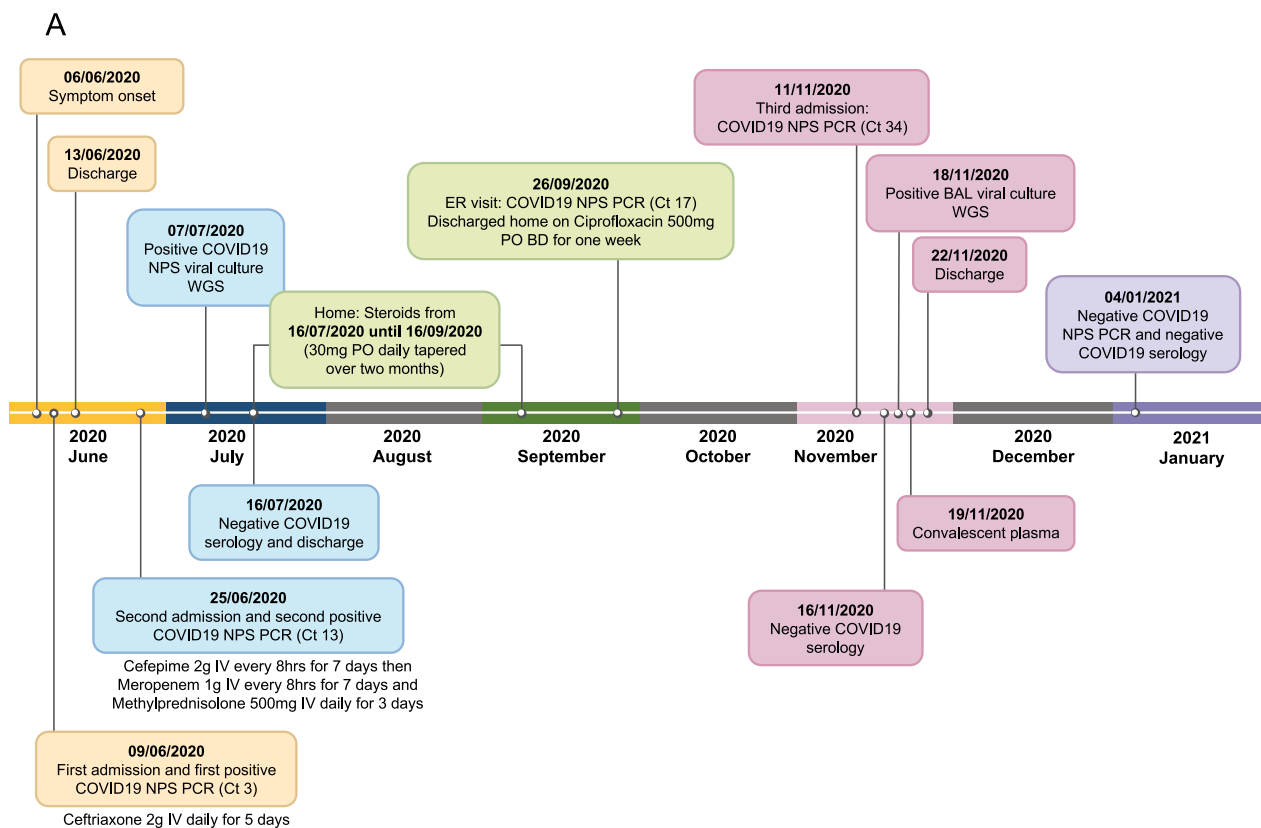
3. Discussion

Immunocompromised patients can present with prolonged SARS-CoV-2 shedding and re-infection with different SARS-CoV-2 clades, posing several clinical management challenges. Genomic analyses of the patient samples from day 31 and day 168 clearly showed a different set of mutations (**Figure 1B**).

The case patient had severe B cell depletion and did not mount antibody responses to SARS-CoV-2. She had a protracted course of COVID-19 pneumonia with prolonged viral shedding, and had positive SARS-CoV-2 viral cultures from nasopharyngeal swab (31 days) and BAL (168 days) post diagnosis. Two recent case reports involving patients with hematological malignancies and B cell immunodeficiency showed positive viral cultures up to 105 days in a patient with chronic lymphocytic leukemia and 119 days in a patient with lymphoma (**Baang et al., 2021, Avanzato et al., 2020**). A humoral antibody response is required to clear SARS-CoV-2 infection (**Tarhini et al., 2021**). Both patients had negative SARS-CoV-2 antibody responses. In the patient case described here, severe depletion of CD19 B lymphocytes is likely to have contributed to the lack of development of SARS-CoV-2 antibodies. The use of rituximab is associated with B cell depletion up to 78 weeks (**Röltgen et al., 2020**). Our patient received rituximab 56 weeks before the diagnosis of COVID-19 pneumonia. Although she was receiving routine monthly IVIG therapy, convalescent plasma was studied as a therapeutic option, and her COVID-19 pneumonia appeared to improve only after receiving convalescent plasma. As with other patients with B cell depletion, this was also associated with a reduction of SARS-CoV-2 RNAemia within 7 to 14 days from the time of administration (**Hueso et al., 2020**). Whether early administration of convalescent plasma to patients with B cell depletion is useful to reduce viral shedding and reduce the isolation period of these patients needs further evaluation.

The impact of rituximab and B cell-depleting agents on the management outcomes of COVID-19 remains to be defined (**Hueso et al., 2020**). Patients receiving rituximab may not mount a protective SARS-CoV-2 antibody response to COVID-19 vaccine and would need immunological assessment before vaccination (**Baker et al., 2020**). Our initial assumption was that this patient had prolonged viral shedding due to B cell depletion. However, whole genome sequencing (WGS) confirmed re-infection. Whilst it is difficult to determine the timing of the second infection with the new clade of SARS-CoV-2, it is likely that it occurred on day 114 when the patient presented to the ER with new onset fever after she had received 2 months of steroids for presumed cryptogenic organizing pneumonia.

Immunosuppressed patients are known to have prolonged periods of SARS-CoV-2 viral shedding. A study of three immunocompromised patients evaluated the spectrum of SARS-CoV-2 viral shedding and re-infection (**Tarhini et al., 2021**). The first patient



B

A. Mutations detected in two isolates

Sequence ID	Mutation	Annotation	Key Mutations
KSApatient.Day31	C8782T	orf1ab:S2839	
KSApatient.Day31	19547 (C) DEL	?	
KSApatient.Day31	G22468T	S:T302	
KSApatient.Day31	G28027T	ORF8:W43L	
KSApatient.Day31	T28144C	ORF8:L84S	S clade
KSApatient.Day31	G28878A	N:S202N	
KSApatient.Day31	G29742A	INTGEN:INTGEN	
KSApatient.Day168	C241T	INTGEN:INTGEN	GR clade
KSApatient.Day168	C1480T	A405	
KSApatient.Day168	C1968T	orf1ab:T568I	
KSApatient.Day168	C2094T	orf1ab:S610L	
KSApatient.Day168	C3037T	orf1ab:F924	GR clade
KSApatient.Day168	A3090C	orf1ab:E942A	
KSApatient.Day168	G7798A	orf1ab:K251I	
KSApatient.Day168	A8663C	orf1ab:T2800P	
KSApatient.Day168	C9165T	orf1ab:T2967I	
KSApatient.Day168	T13442G	orf1ab:S4393A	
KSApatient.Day168	C14408T	orf1ab:P4715L	
KSApatient.Day168	C19386T	orf1ab:D6374	
KSApatient.Day168	A2340G	S:D614G	G clade
KSApatient.Day168	C26333T	E:T30I	
KSApatient.Day168	C26542T	M:T7I	
KSApatient.Day168	C27998T	ORF8:D3S	
KSApatient.Day168	G28090T	ORF8:G66V	
KSApatient.Day168	G28881A	N:R203K	
KSApatient.Day168	G28882A	N:R203	GR clade
KSApatient.Day168	G28883C	N:G204R	

B. SARS-CoV-2 clade/lineage prediction (3 methods)




Figure 1. Case summary and SARS-CoV-2 clades. (A) Time frame of clinical symptoms, admissions to hospital, and laboratory investigations. (B) Mutation detection and assignment of SARS-CoV-2 clade/lineage, confirming the re-infection.

was asymptomatic with HIV infection and had prolonged infectious viral shedding until day 95. The second patient was a cardiac transplant recipient with severe COVID-19 pneumonia who had a positive viral culture until day 103. The third patient had rheumatoid arthritis treated with rituximab and had non-resolving COVID-19 pneumonia. This patient was positive for SARS-CoV-2 viral culture on day 84 and WGS confirmed re-infection (Tarhini et al., 2021).

In our case, re-infection was only confirmed late in the patient's illness by WGS. The clinical course of the presented case was protracted, with no improvement between the initial infection and re-infection, which compounds the difficulties of identifying re-infection with different SARS-CoV-2 clades. The identification of re-infection in this case was achieved by WGS and the utilization of three approaches to analyze the data in order to confirm the case as a re-infection. A real concern of this case is that she is a potential infection reservoir and an optimal milieu for the development of SARS-CoV-2 variants with her prolonged infectious viral shedding and acquisition of a new infection (Kemp et al., 2021). Determining the duration of isolation and extent of contact-tracing for this patient was a real challenge, as she had a positive SARS-CoV-2 viral culture on day 168 post infection (CDC 2021). It is not known whether patients with re-infection are more infectious during the second episode than the first episode of infection. In addition, the management outcome of re-infections is not clear. In our patient, the course of infection was non severe in both episodes of infection. Another challenge would be her presumed suboptimal immune response to vaccination and whether specific vaccines can induce a protective immune response compared to natural infection (Wheatley et al., 2021). This case showed that the patient's initial natural infection, subsequent re-infection, and one dose of mRNA vaccine did not induce SARS-CoV-2 antibody responses in view of her significant B cell dysfunction, which renders her susceptible to future COVID-19 disease. Unfortunately, SARS-CoV-2 T cell immune responses were not performed and it is not known whether she developed SARS-CoV-2 T cell responses after mRNA vaccination, which could be protective from future infections despite her negative SARS-CoV-2 antibody responses. The evaluation of the early use of convalescent plasma or combination monoclonal antibodies in these patients to inhibit viral replication and prevent prolonged infectious viral shedding is warranted (Gottlieb et al., 2021).

This case highlights several challenging management issues concerning reducing the risk of SARS-CoV-2 infection and re-infection in patients with hematological malignancies and other immunocompromised patients that need to be addressed. It also brings forth issues regarding susceptibility to re-infection, disease severity, increased mortality, response to therapy, protective immune responses post COVID-19 recovery, prolonged viral shedding, infection control, and response to COVID-19 vaccines and duration of protection. COVID-19 patients with malignancies or transplants who are on immunosuppressive treatments should undergo proactive long-term follow-up and surveillance to avoid relapse or detect it early, and decrease the re-infection risk.

Re-infection with different clades of SARS-CoV-2 does occur in immunocompromised patients and proactive screening for different clades of SARS-CoV-2 is required. Since WGS is not yet performed routinely at most points of COVID-19 care, it is likely that the numbers of cases of re-infection with different clades of SARS-CoV-2 is being underestimated. More systematic studies with WGS of all possible cases of SARS-CoV-2 re-infection, in both immunosuppressed and immunocompetent individuals, are required.

Acknowledgements

Sir Zumla is co-Principal Investigator of the Pan African-European Network on Emerging and Re-emerging Infections (PANDORA-ID-NET, <https://www.pandora-id.net/>) funded by the European and Developing Countries Clinical Trials Partnership, EU Horizon 2020 Framework Programme. Sir Zumla is in receipt of a UK National Institutes of Health Research (NIHR) Senior Investigator award and is a 2020 Mahathir Science Award Laureate. The authors acknowledge the generous charitable donation from the late Sheikh Ibraheem Ahmed Azhar in the form of reagents and supplies as a contribution to the scientific research community.

Funding

None.

Ethical approval

The study was conducted according to the guidelines of the Declaration of Helsinki and was approved by the Research Ethics Committee (REC) of the Unit of Biomedical Ethics, Faculty of Medicine, King Abdulaziz University, Jeddah, Saudi Arabia (Reference No. 487-20, 16 September 2020).

Conflict of interest

All authors declare no conflict of interest.

Author contributions

All authors contributed to the case management, interpretation of data, review of the literature, and writing of this report. Conceptualization: ANA, EIA, AZ. Data curation: ANA, SAE, MY, AR, AZ, EIA. Formal analysis: SAE, AMH, AMT, TAA, TLA, NAO, IA, TG, AR. Funding acquisition: EIA. Investigation: ANA, SAE, MY, AD, AHY, MFS, AA, NIA, HAB, AMH, AMT, TAA, TLA, NAO, AR, EIA. Methodology: SAE, AD, AHY, MFS, AA, NIA, HAB, AMH, AMT, TLA, NAO, IA, TG, AR. Project administration: ANA, EIA. Resources: ANA, TG, EIA. Software: SAE, MY, IA, TG, AR, EIA. Supervision: ANA, EIA, AZ. Validation: SAE, AMH, AMT, TAA, TLA, NAO, IA, TG, AR. Visualization: SAE, AMH, AMT, TAA, TLA, NAO, IA. Writing – original draft: ANA, SAE, IA, AZ, EIA. Writing – review and editing: all authors

Supplementary materials

Supplementary material associated with this article can be found, in the online version, at [doi:10.1016/j.ijid.2021.07.036](https://doi.org/10.1016/j.ijid.2021.07.036).

References

- Avanzato VA, Matson MJ, Seifert SN, et al. Case Study: Prolonged Infectious SARS-CoV-2 Shedding from an Asymptomatic Immunocompromised Individual with Cancer. *Cell* 2020;183(7):1901–12 e9.
- Baang JH, Smith C, Mirabelli C, et al. Prolonged Severe Acute Respiratory Syndrome Coronavirus 2 Replication in an Immunocompromised Patient. *J Infect Dis* 2021;223(1):23–7.
- Baker D, Roberts CAK, Pryce G, et al. COVID-19 vaccine-readiness for anti-CD20-depleting therapy in autoimmune diseases. *Clin Exp Immunol* 2020;202(2):149–61.
- Choi B, Choudhary MC, Regan J, et al. Persistence and Evolution of SARS-CoV-2 in an Immunocompromised Host. *The New England journal of medicine* 2020;383(23):2291–3.
- CDC. Discontinuation of Transmission-Based Precautions and Disposition of Patients with SARS-CoV-2 Infection in Healthcare Settings; 2021 Available at <https://www.cdc.gov/coronavirus/2019-ncov/hcp/disposition-hospitalized-patients.html> Accessed June 12.
- Wheatley AK, Juno JA, Wang JJ, et al. Evolution of immune responses to SARS-CoV-2 in mild-moderate COVID-19. *Nature Communications* 2021;12(1):1162.

- Gottlieb RL, Nirula A, Chen P, et al. Effect of Bamlanivimab as Monotherapy or in Combination With Etesevimab on Viral Load in Patients With Mild to Moderate COVID-19: A Randomized Clinical Trial. *Jama* 2021;325(7):632–44.
- Hueso T, Poudoux C, Péré H, et al. Convalescent plasma therapy for B-cell-depleted patients with protracted COVID-19. *Blood* 2020;136(20):2290–5.
- Kemp SA, Collier DA, Datir RP, et al. SARS-CoV-2 evolution during treatment of chronic infection. *Nature* 2021;592:277–82.
- Röltgen K, Powell AE, Wirz OF, et al. Defining the features and duration of antibody responses to SARS-CoV-2 infection associated with disease severity and outcome. *Sci Immunol* 2020;5(54). doi:10.1126/sciimmunol.abe0240.
- Tarhini H, Recoing A, Bridier-Nahmias A, et al. Long term SARS-CoV-2 infectiousness among three immunocompromised patients: from prolonged viral shedding to SARS-CoV-2 superinfection. *J Infect Dis* 2021;223(9):1522–7.
- WHO. WHO Coronavirus Disease (COVID-19) Dashboard; 2020 Available at: <https://covid19.who.int> Accessed 30.6.