

Received: 2019.06.07
Accepted: 2019.08.20
Published: 2019.10.12

Traumatic Double-Level Unilateral Achilles Tendon Rupture: A Case Report

Authors' Contribution:
Study Design A
Data Collection B
Statistical Analysis C
Data Interpretation D
Manuscript Preparation E
Literature Search F
Funds Collection G

BDEF Hamza Reda Gomaa
A Syed Mohsin Ali

Department of Orthopedic Surgery, Bahrain Defense Force Royal Medical Service, Riffa, Bahrain

Corresponding Author: Hamza Reda Gomaa, e-mail: Hamza9191@hotmail.com
Conflict of interest: None declared

Patient: Male, 46
Final Diagnosis: Unilateral double level Achilles tendon tear
Symptoms: Pain • swelling
Medication: —
Clinical Procedure: Achilles tendon rupture repair
Specialty: Orthopedics and Traumatology





Objective: Rare disease
Background: Unilateral double-level Achilles tendon tear is a rare presentation that has not been previously reported in the English literature. Diagnosis and management of these cases are challenging, and outcomes are not well described in the literature.

Case Report: A 46-year-old man presented to us with ankle pain following a football sports injury. Clinical examination and ultrasound scan showed unilateral Achilles tendon double-level partial tears that were managed conservatively. The patient presented again with another trauma and progression to full-thickness tear, managed operatively with open Achilles tendon repair technique.

Conclusions: Management of these cases is complex and challenging. In the literature, both operative and non-operative management have been described. However, the recent literature shows no major difference between these 2 methods of treatment. Our case was quite unique, so we decided to use the open repair technique. Awareness about this rare presentation and the need for further research is necessary for proper management of such cases.

MeSH Keywords: Achilles Tendon • Ankle Injuries • Athletic Injuries • Rupture • Tendon Injuries

Full-text PDF: <https://www.amjcaserep.com/abstract/index/idArt/917972>

 1504   4  20



Background

Achilles tendon rupture is one of the commonly recognized foot and ankle injuries in both professional and amateur sports players. It is estimated that the incidence of Achilles tendon rupture is around 7-10 per 100000 of general population [1-3]. Unilateral double-level Achilles tendon rupture is a rare unusual presentation that is not reported in published English literature. We are reporting a case of traumatic unilateral double-level Achilles tear which was treated operatively with good functional outcome. Diagnosis and management of these cases are challenging and operative repair might be preferred over conservative management for optimum functional outcomes.

Case Report

We present a case of a 46-year-old male patient with known diabetes mellitus and hypertension, with no history of steroids injection or long-term antibiotics administration. He had no history of smoking, drinking alcohol, or substance abuse.

The patient sustained sudden dorsiflexion injury to his right ankle while playing football. He initially presented with swelling, pain over the posterior ankle, localized tenderness over the Achilles tendon, and restricted ankle range of motion. Clinical examination showed a weak positive Thompson test, with no palpable defect. Achilles tendon rupture was suspected and an emergency ultrasound scan was done, showing Achilles tendon calcific tendinosis with a double-level partial tear. Ultrasound showed multiple crescentic calcific areas along with a short segment of partial fiber defect about 5 mm at the lower part of the Achilles tendon, almost 16 mm above the distal attachment of the tendon. Another area of disrupted fibers was noted about 40 mm above the insertion (Figure 1).

Operative versus non-operative management options were discussed with the patient, who agreed to receive non-operative management, and planter flexed cast was applied.

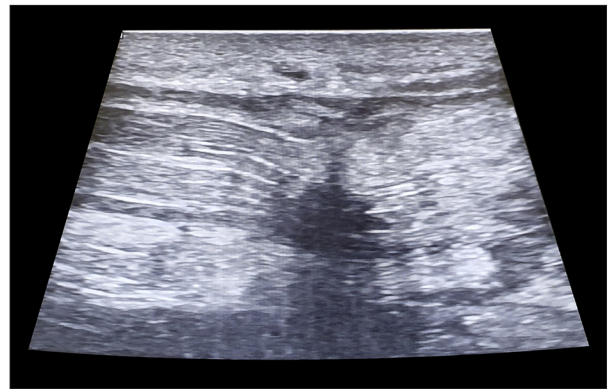


Figure 2. Full-thickness tear at the musculo-tendinous junction.

The patient presented again for follow-up after 2 weeks, with a recurrent trauma to the same injured foot. On examination, he had severe tenderness over the distal Achilles tendon region, with a palpable gap and a positive Thomson test result.

Ultrasound scanning was repeated and showed a full-thickness tear at the musculo-tendinous junction with retraction of the tendon by approximately 2 cm (Figure 2). The distal partial tear was also reported, as in the preceding ultrasound.

Taking in consideration the unique presentation, the patient was advised to have surgical repair, which was done at around 4 weeks following the initial injury. Intra-operatively, the patient was having unilateral Achilles tendon double-level tears (Figure 3). The proximal tear was complete at around 4 cm above the insertion site, while the second distal tear was partial, involving around 50% of the tendon width at the tendon insertion site.

Both tears were repaired using open Kessler suture repair technique in prone position under general anesthesia. The patient was followed-up regularly in the clinic. At the 6-month follow-up, he was fully weight-bearing, with no complains. Functional outcome was measured by means of self-survey using the Foot and Ankle Outcome Score (FAOS). He achieved a 99% Daily Living Subscale Score and 75% in the Sports and

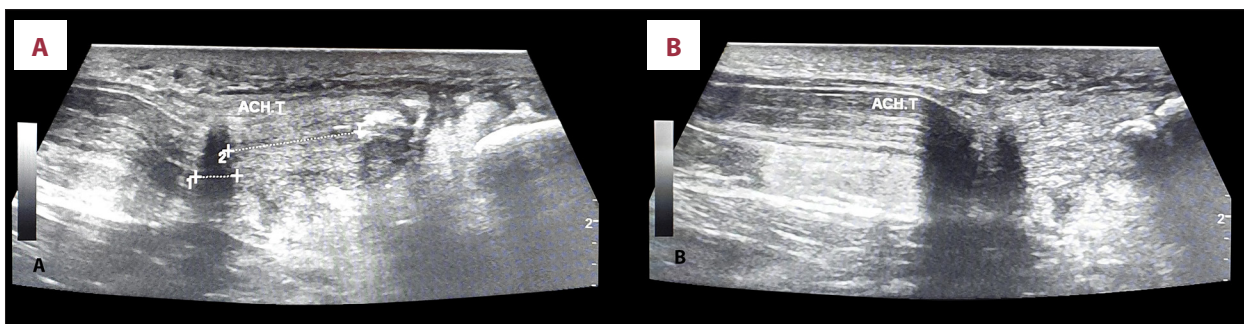


Figure 1. (A) Partial-thickness tear 1.5 cm from the tendon insertion site, with signs of calcific tendinosis. (B) Partial-thickness tear at the musculo-tendinous junction.

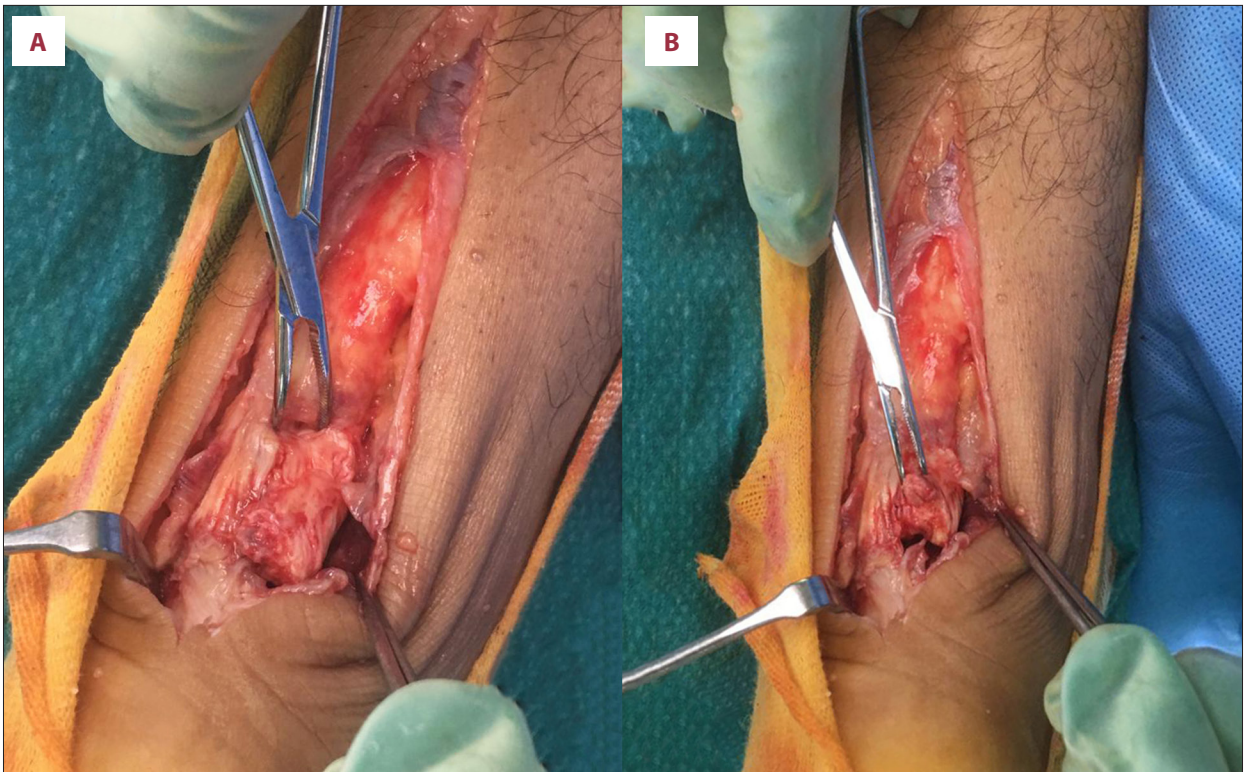


Figure 3. (A) Intraoperative picture showing the proximal full-thickness tear at the musculo-tendinous junction. (B) Distal partial tendon tear. Both tears were repaired using open Kessler suture repair technique.

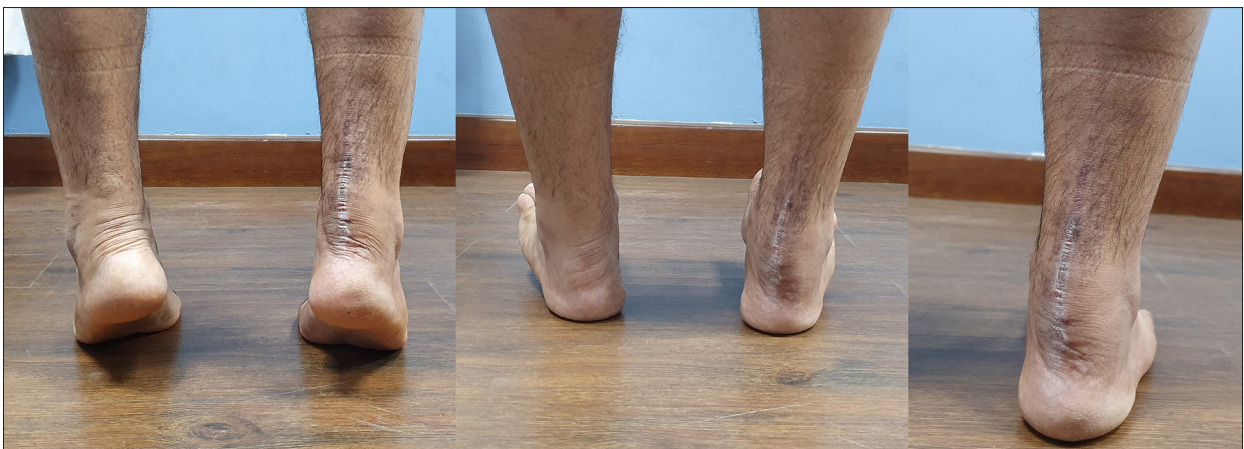

Figure 4. Patient at 6 months following open Achilles tendon double-level repair.

Recreation Subscale. Clinically, calf muscle power was 5/5 and he had full ROM at the ankle joint, with no pain at the operative site (Figure 4).

Discussion

The Achilles tendon is the thickest and strongest tendon in the body [4], and is formed from the tendinous contributions of the gastrocnemius and soleus muscles inserting into the

calcaneal tuberosity [5]. Even though the Achilles tendon receives its blood supply through both the posterior tibia and the peroneal artery [6], it has a generally a poor blood supply throughout its length, with even less vascularization over its midsection (the “watershed area”), which is located approximately 4 cm proximal to the tendon insertion point. As a result, this area is subjected to more injuries and has poor healing capacity following trauma [7].

Achilles tendon injuries are common foot and ankle injuries in middle-aged athletes and in recreational sports players. Tendinopathy occurs in up to 10% of athletic sports players, whereas tendon ruptures are estimated to occur in approximately 8% of competitive athletes, with the peak age being 30–40 years [8].

Older age, male sex, and steroid use are among the risk factors for Achilles tendinopathy [9,10]. These risk factors are believed to increase the risk for tendinopathy and subsequent tendon rupture by their effect on the tendon micro-vascularity. Other risk factors include use of fluoroquinolone antibiotics and oral glucocorticoids, although the exact mechanism remains unknown [11]. Mechanical risk factors can be divided into intrinsic and extrinsic. Extrinsic factors include excessive running duration, high-intensity running, and running on uneven surfaces. Intrinsic factors include excessive hind-foot varus or valgus, increased femoral anteversion, limb-length discrepancy, and obesity [12,13]. Aging effects on both the tendon vascularity and on the collagen crosslinking, combined with repetitive micro-traumas, also increases the risk of tendon rupture [5].

Acute Achilles tendon rupture usually occurs following sudden unexpected dorsiflexion of the ankle or violent dorsiflexion of the planter flexed foot. It could also occur following fall from height injuries. Tears usually occurs in the hypo-vascularized watershed area, approximately 2–6 cm proximal to the tendon insertion into the calcaneal tuberosity [14].

In reports of acute Achilles tendon ruptures, a rare presentation of acute bilateral Achilles tendon rupture was reported in multiple publications [15,16]; but there appears to be no report of simultaneous traumatic unilateral double-level Achilles tendon tear in the published English literature. In our case, the patient sustained acute unilateral double-level partial tears confirmed by ultrasound, with signs of preexisting Achilles tendinopathy. The patient was a recreational football player who had no known intrinsic nor extrinsic risk factors.

The mechanism of injury in such cases is unclear. Our patient had clear evidence of preexisting tendinopathy resulting from repetitive stress over the Achilles tendon, manifested in the form of fibrosis and calcifications seen in ultrasound and during operative repair. This preexisting tendinopathy puts him at great risk for acute tendon rupture, even with normal activity. This, combined with the high injury force he sustained, resulted in a spontaneous double-level tear of the Achilles tendon, both at the pathologically weakened insertion site and at the physiologically weak less vascularized watershed Achilles tendon area.

Treatment of acute Achilles tendon ruptures remains controversial. It can be generally divided into operative (open and percutaneous) and non-operative (cast immobilization and functional bracing). A meta-analysis published in 2004 by Khan et al. showed reduced risk of tendon re-rupture following operative repair compared to non-operative treatment, but the operative option is associated with higher risk of other complications, including infection, adhesions, and altered skin sensibility [17].

A more recent meta-analysis of randomized trials showed that re-rupture rates were equal for operative and conservatively treated patients if functional rehabilitation and early range of motion was employed [18].

In our case, the patient was initially managed with non-operative management consisting of immobilization and non-weightbearing. Following this, he sustained another ankle injury within 2 weeks from the initial injury and presented again with severe pain and clinical signs of a complete Achilles tendon tear. Repeated ultrasound showed progression of the previously partial proximal tear to a complete tear along with the second distal partial tear. Operative repair was decided on and both tears were repaired with open Kessler suture repair technique. The patient was followed-up in the clinic, achieving full functional recovery by 6 months.

Our operative method for this patient involved open repair of both proximal and distal defects using Kessler repair technique with edges approximated by Ethibond sutures. Following that, repair was augmented by placing circumferential Vicryl sutures throughout the length of the Achilles tendon. Despite evidence supporting the percutaneous approach in terms of cosmetic outcome and lower complication rate for single-level ruptures [19,20], we chose the open approach for this case to gain full exposure and to achieve optimal edge opposition for both tears. The patient was offered the same rehabilitation plan as for cases with single-level rupture repair in the form of non-weight-bearing mobilization and functional casting for 6 weeks followed by progressive weight-bearing and strengthening exercises.

Our experience suggests that operative treatment of unilateral double-level Achilles tears is better than conservative management. We also recommend using an open repair approach for this form of complex injury to avoid any chance of re-rupture. Awareness about this rare presentation and the need for further research is necessary for proper management of such cases. This case also shows us the importance of ultrasound scanning as a diagnostic tool and the possibility for double-level Achilles tears. It also raises the question of whether operative repair is preferred as a first-line treatment if partial double tears are diagnosed. Further studies of the recurrence rates following both methods of treatment for such cases are needed.

Conclusions

A unilateral double-level Achilles tendon tear is a rare presentation of Achilles tendon injury that requires special consideration regarding diagnosis and management. Although recent studies show equal prognostic outcomes for both operative and non-operative treatment for Achilles tendon tears, the clinical outcomes following conservative management of unilateral

double-level tears have not been described. Awareness about this rare presentation and further research are needed to ensure good treatment outcomes.

Conflict of interest

None.

References:

1. Suchak AA, Bostick G, Reid D et al: The incidence of Achilles tendon ruptures in Edmonton, Canada. *Foot Ankle Int*, 2005; 26(11): 932–36
2. Huttunen TT, Kannus P, Rolf C et al: Acute Achilles tendon ruptures: incidence of injury and surgery in Sweden between 2001 and 2012. *Am J Sports Med*, 2014; 42(10): 2419–23
3. Sheth U, Wasserstein D, Jenkinson R et al: The epidemiology and trends in management of acute Achilles tendon ruptures in Ontario, Canada: A population-based study of 27 607 patients. *Bone Joint J*, 2017; 99-b(1): 78–86
4. O'Brien M: The anatomy of the Achilles tendon. *Foot Ankle Clin*, 2005; 10(2): 225–38
5. Binstead JT, Varacallo M: Anatomy, bony pelvis and lower limb, calf. Treasure Island, FL: Statpearls Publishing, 2018
6. Wong M, Kiel J: Anatomy, bony pelvis and lower limb, Achilles tendon. Treasure Island, FL: Statpearls Publishing, 2019
7. Abate M, Salini V: Mid-portion Achilles tendinopathy in runners with metabolic disorders. *Eur J Orthop Surg Traumatol*, 2018; 29(3): 697–703
8. Leppilahti J, Orava S: Total Achilles tendon rupture. A review. *Sports Med*, 1998; 25(2): 79–100
9. Holmes GB, Lin J: Etiologic factors associated with symptomatic Achilles tendinopathy. *Foot Ankle Int*, 2006; 27(11): 952–59
10. Kleinman M, Gross AE: Achilles tendon rupture following steroid injection. Report of three cases. *J Bone Joint Surg Am*, 1983; 65(9): 1345–47
11. Van der Linden PD, Van Puijenbroek EP, Feenstra J et al: Tendon disorders attributed to fluoroquinolones: A study on 42 spontaneous reports in the period 1988 to 1998. *Arthritis Rheum*, 2001;45(3): 235–39
12. Pedowitz D, Kirwan G: Achilles tendon ruptures. *Curr Rev Musculoskelet Med*, 2013; 6(4): 285–93
13. Järvinen TA, Kannus P, Paavola M et al: Achilles tendon injuries. *Curr Opin Rheumatol*, 2001; 13(2): 150–55
14. Leppilahti J, Korpelainen R, Karpakka J et al: Ruptures of the Achilles tendon: Relationship to inequality in length of legs and to patterns in the foot and ankle. *Foot Ankle Int*, 1998; 19(10): 683–87
15. Orava S, Hurme M, Leppilahti J: Bilateral Achilles tendon rupture: A report on two cases. *Scand J Med Sci Sports*, 1996; 6(5): 309–12
16. Kapoor C, Jhaveri M, Golwala P et al: Acute bilateral traumatic Achilles tendon rupture – a rare presentation. *Cureus*, 2016; 8(7): e706
17. Khan RJ, Fick D, Brammar TJ et al: Interventions for treating acute achilles tendon ruptures. *Cochrane Database Syst Rev*, 2004; (3): CD003674
18. Soroceanu A, Sidhwa F, Aarabi S et al: Surgical versus nonsurgical treatment of acute Achilles tendon rupture: A meta-analysis of randomized trials. *J Bone Joint Surg Am*, 2012; 94(23): 2136–43
19. Lim J, Dalai R, Waseem M: Percutaneous vs. open repair of the ruptured Achilles tendon – a prospective randomized controlled study. *Foot Ankle Int*, 2001; 22(7): 559–68
20. Bradley JP, Tibone JE: Percutaneous and open surgical repairs of Achilles tendon ruptures: A comparative study. *Am J Sports Med*, 1990; 18(2): 188–95