



Case Report

# Orbitofrontal approach for the fenestration of a symptomatic sellar arachnoid cyst

Zaid Aljuboori<sup>1</sup>, William Burke<sup>1</sup>, Heegok Yeo<sup>1</sup>, Abigail McCallum<sup>1</sup>, Jeremy Clark<sup>2</sup>, Brian Williams<sup>1</sup>

Departments of <sup>1</sup>Neurosurgery, <sup>2</sup>Ophthalmology, University of Louisville, Louisville, Kentucky.

E-mail: \*Zaid Aljuboori - zaid.aljuboori@yahoo.com; William Burke - William.Burke@louisville.edu; Heegok Yeo - Heegok.Yeo@louisville.edu; Abigail McCallum - Abigail.mccallum@ul.org; Jeremy Clark - jeremy.clark.3@louisville.edu; Brian Williams - brian.williams@ul.org



\*Corresponding author:

Zaid Aljuboori,  
Departments of Neurosurgery,  
University of Louisville,  
Louisville, Kentucky.

[zaid.aljuboori@yahoo.com](mailto:zaid.aljuboori@yahoo.com)

Received : 31 December 19

Accepted : 07 January 20

Published : 17 January 20

DOI

10.25259/SNI\_541\_2019

Quick Response Code:



## ABSTRACT

**Background:** Sellar arachnoid cysts (SACs) are rare lesions and incidentally found on brain imaging. The pathophysiology is poorly understood. Some authors suggested that SACs develop as a herniation of arachnoid membrane through the diaphragma sellae followed by cyst formation. Furthermore, Meyer *et al.* postulated that SACs are formed by splitting of the arachnoid layers. Symptomatic SACs present with headache, visual field deficit, or pituitary dysfunction. The data are limited on the indications and timing for intervention. We present a case of symptomatic SAC that was fenestrated using orbitofrontal approach.

**Case Description:** A 64-year-old female presented with chronic headaches and blurriness of vision. She was previously diagnosed with diabetes insipidus (DI) that was treated with desmopressin, magnetic resonance imaging (MRI) of her brain at that time was normal. Later on, she developed severe headaches that were managed medically. A year later, she had an episode of generalized seizure that led to the discovery of SAC on brain MRI. On examination, she had a left-sided monocular temporal hemianopia. The patient underwent an orbitofrontal craniotomy for fenestration of the SAC. At 6-month follow-up, her headaches had significantly improved with the resolution of the visual deficit. In addition, the DI had resolved, and the desmopressin was discontinued.

**Conclusion:** SACs are rare with no consensus on the indications for surgery. Our experience suggests that fenestration of SAC through transcranial approach is a valid option for patients with visual deficit and/or pituitary dysfunction.

**Keywords:** Arachnoid, Craniotomy, Cyst, Orbitofrontal, Sella

## INTRODUCTION

Sellar arachnoid cysts (SACs) constitute about 3% of all intracranial arachnoid cysts. Their pathophysiology is not well understood, and they are often asymptomatic and found incidentally. There are some reports of symptomatic SACs that required treatment.<sup>[1,3,6,8,11,18,20,21,22,25]</sup> If symptomatic, they usually present with signs and symptoms of chiasmatic or pituitary gland compression. They also can present with chronic headaches.<sup>[1,3,6,8,11,18,20,21,22,25]</sup>

They can easily be identified on magnetic resonance imaging (MRI), appear as a cystic lesion within the sella with cerebrospinal fluid signals with no obvious communication with the suprasellar subarachnoid space.<sup>[6,7,22,23]</sup> In contrast to empty sella syndrome, where the arachnoid diverticulum in the sella does communicate with subarachnoid space. Due to the rarity of this

This is an open-access article distributed under the terms of the Creative Commons Attribution-Non Commercial-Share Alike 4.0 License, which allows others to remix, tweak, and build upon the work non-commercially, as long as the author is credited and the new creations are licensed under the identical terms.

©2020 Published by Scientific Scholar on behalf of Surgical Neurology International

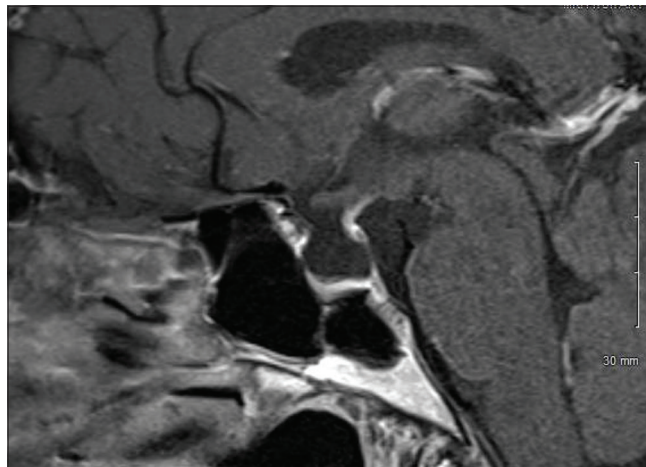
condition, there are no clear-cut guidelines on the indications and timing for surgical intervention. Visual field defects, hormonal imbalance, and chronic headache, especially with enlarging cyst, have been reported as indications for surgery.<sup>[1,3,5,7,10,17,20,21,23]</sup> Typically, the surgical treatment of these lesions requires either transsphenoidal or transcranial approach to the sella.<sup>[13,17,21]</sup>

We present a case of symptomatic SAC that was treated with orbitofrontal craniotomy for cyst fenestration.

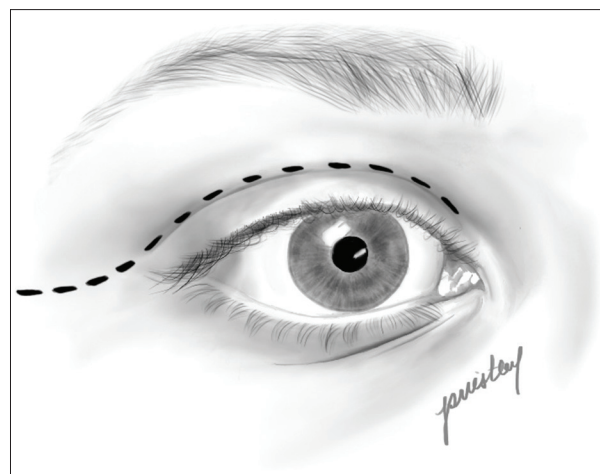
## CASE REPORT

A 64-year-old female presented with chronic severe headaches, blurriness of vision, diabetes insipidus (DI), and an MRI finding of a sellar cystic lesion. She was originally diagnosed with DI at a different institution when she presented with symptoms of polyuria and polydipsia in 2011. At the time, she had a normal MRI of the brain and was treated with desmopressin 100 mcg/day. In 2016, she developed severe, achy bifrontal headaches 2–3 times a week with no associated symptoms. These headaches were managed with ibuprofen and sumatriptan with some benefit. Then, in December 2017, she began experiencing generalized fatigue and blurring of her left-sided vision that caused her to bump into objects on her left side. She also had a single episode of generalized tonic-clonic seizure that led to the identification of a new nonenhancing  $9.4 \times 9.2 \times 6.3$  mm sellar cystic lesion on MRI of the brain consistent with a SAC [Figure 1]. She underwent testing of her pituitary function and a neurosurgical evaluation at a different institution. The managing team recommended a 1-year follow-up with a new MRI. She then presented to our institution for a second opinion. On examination, the patient had left-sided monocular temporal hemianopia. The pituitary function test revealed low levels of follicle-stimulating hormone (FSH) and luteinizing hormone (LH) for the patient's age. Due to the severity of the patient's headache and the presence of visual field defect, a surgical fenestration of the cyst was offered as an option. After discussing the risks and benefits in details, the patient elected to proceed with surgery.

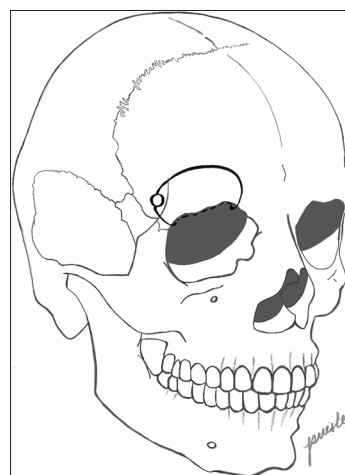
The patient underwent a right-sided orbitofrontal craniotomy for the fenestration of the SAC through an eyelid crease incision [Figures 2-6]. With the patient in supine position, the head was rotated about  $20^\circ$  toward the contralateral side to provide a straight trajectory toward the sella. A single-piece orbitofrontal craniotomy was done extending from the keyhole laterally to the supraorbital neurovascular bundle medially with 3 cm superior extension. A U-shaped durotomy was done with the base toward the orbital rim. A sharp arachnoid dissection was performed to free the frontal lobe from the anterior skull base. Then, the optic nerves and anterior cerebral arteries were identified



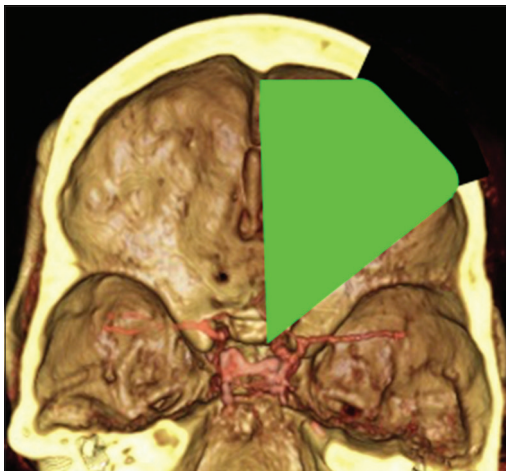
**Figure 1:** Preoperative magnetic resonance imaging brain with contrast (mid-sagittal view) shows the sellar arachnoid cysts with compression of the pituitary gland and deviation of the stalk.



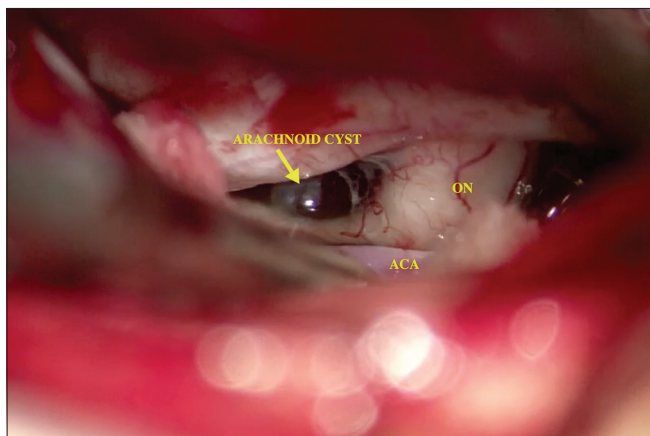
**Figure 2:** Artist's sketch depicting the eyelid crease incision for the approach.



**Figure 3:** Artist's sketch depicting the orbitofrontal craniotomy (the black circle is the burr hole at the keyhole).



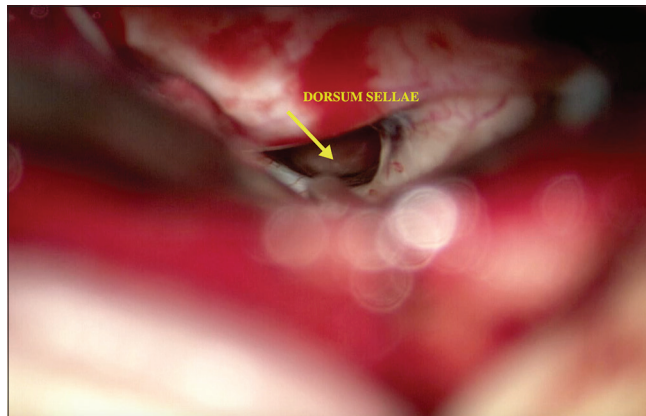
**Figure 4:** Three-dimensional rendering of the patient's computed tomography angiogram depicting the exposure obtained from the orbitofrontal approach.



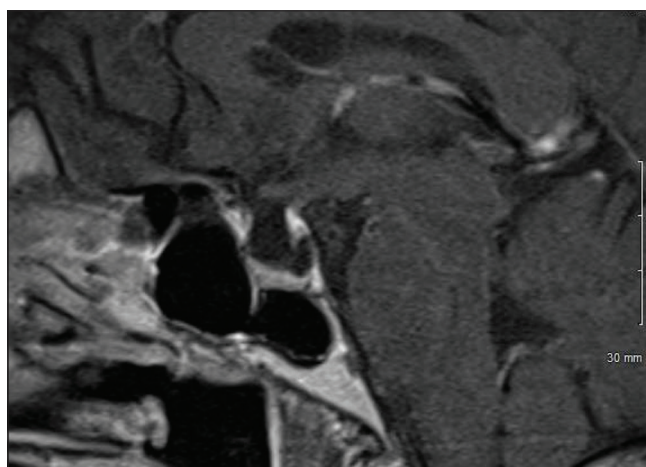
**Figure 5:** Intraoperative microscopic picture (x50) shows the right optic nerve, right anterior cerebral artery, and the arachnoid cyst within the sella (arrow).

and the chiasmatic cistern was opened. The pulsating SAC was identified, and a large window was created into the cyst wall to create a direct communication with the subarachnoid space. A watertight dural closure is important to eliminate the risk for cerebrospinal fluid (CSF) leak.

The patient postoperative course was complicated by a palpebral abscess, which was drained by ophthalmology and treated with oral clindamycin and erythromycin eye drops. At 6-month follow-up, she reported significant improvement of her headaches (1–2 times a month with less severity) with resolution of visual field deficit. In addition, her DI had resolved and was confirmed with laboratory testing and the desmopressin was discontinued by her endocrinologist. Postoperative MRI showed that the cyst was smaller in size with less deformation of the pituitary gland and the stalk [Figure 7].



**Figure 6:** Intraoperative microscopic picture (x50) shows the dorsum sellae after the fenestration of the arachnoid cyst (arrow).



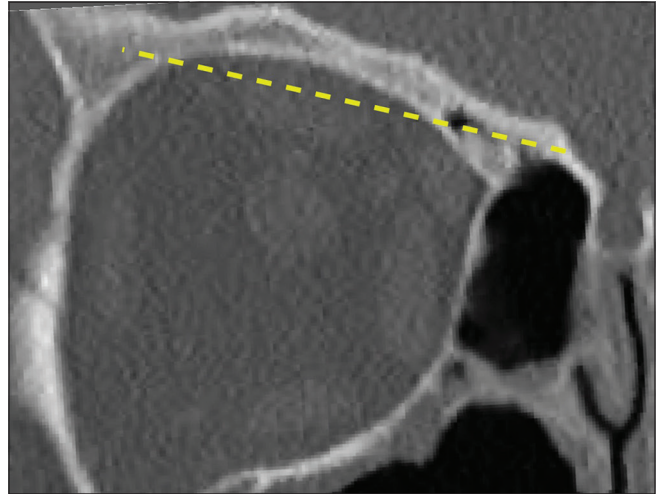
**Figure 7:** Postoperative magnetic resonance imaging brain with contrast (mid-sagittal view) shows the sellar arachnoid cysts (smaller in size) with increased thickness of the pituitary gland.

## DISCUSSION

SACs are rare lesions that often found incidentally. They usually treated conservatively with no high-level evidence regarding the indications for surgical intervention. The pathophysiology of SACs is not completely understood. One common theory suggests the development of SACs by a herniation of the basal arachnoid membrane through a defect in diaphragma sellae.<sup>[2,6,10,15]</sup> Therefore, SACs start as an intrasellar arachnoid diverticulum followed by cyst formation, due to narrowing of the diaphragma defect or the development of adhesions between the arachnoid layers. Furthermore, Meyer *et al.* postulated that SACs are formed by splitting of the arachnoid layers similar to other intracranial arachnoid cysts.<sup>[16]</sup> Naturally, these theories correlate with the known increased risk of CSF leak with SACs due to the potential for communication with the subarachnoid space.<sup>[4,14,19]</sup> The symptoms of SACs are due to

mass effect on the surrounding structures, i.e., the pituitary gland, optic chiasm, and cavernous sinuses. Symptomatic patients initially present with headaches with visual changes followed by hormonal deficits.<sup>[6,8,12,21]</sup> The cause of headaches is unknown but is thought to be related to stretch of the diaphragma dura.<sup>[9]</sup> Our patient's headaches were chronic and bifrontal in nature. The visual dysfunction associated with SAC typically presents as bitemporal hemianopia due to compression of the optic chiasm. However, in our case, the visual symptoms were unilateral which is not uncommon. The most commonly reported hormonal abnormalities were related to the gonadotroph axis and were thought to be due to the compression of the pituitary gland.<sup>[6,8,12,21]</sup> In our case, the patient was found to have low levels of FSH and LH and DI preoperatively.

The goals of surgery for SACs are decompression of the optic apparatus and the pituitary gland. Surgery is rarely indicated to treat headaches. The concept behind the fenestration of the SACs is to create a continuous communication between the cyst and the subarachnoid space. Several surgical approaches have been described to address sellar lesions, they can be grouped into transcranial and transsphenoidal approaches (TSAs). The choice of the optimal approach is affected by multiple factors including the surgeon's experience, type and size of the lesion, vascular anatomy, and position of the optic chiasm. At present, the endoscopic TSA is the most commonly used approach to treat sellar lesions. SACs represent an exception, due to the increased risk of CSF leak which can be as high as 15–20%.<sup>[4,14,19]</sup> The supraorbital and orbitofrontal approaches offer a sufficient corridor to visualize and fenestrate the cyst, minimal need for frontal lobe retraction, and have a much lower rate of CSF leak in comparison to TSA.<sup>[24]</sup> The degree of curvature of the orbital roof can guide the choice between the two approaches. In this case, we decided to use the orbitofrontal approach instead because the patient's orbital roof had a high degree of curvature (12 mm between frontoethmoidal suture and highest point of orbital roof) which limited our view [Figure 8]. DeBattista *et al.* (2014)<sup>[5]</sup> showed that in unilateral subfrontal approaches, if the orbital height is more than 11 mm then an orbitotomy can be beneficial to expand the surgical view and minimize retraction. Furthermore, they suggested that a preoperative computed tomography measurement of orbital height can be beneficial in predicting when orbitotomy is needed.<sup>[5]</sup> The improvement in the patient's headache and the resolution of her visual deficits supports the aforementioned rationale for intervening surgically to treat SACs.<sup>[7,11,13,12,20,23]</sup> On the other hand, the resolution of the patient's chronic central DI after SAC fenestration is a significant finding in our case. We think that fenestration of the cyst resulted in reduction of the pressure on the pituitary gland which might have helped with the patient DI. Although at the time of initial diagnosis of the patient DI, the MRI of the brain did not show any sellar



**Figure 8:** Computed tomography scan of the orbit (coronal view) shows the curvature of the orbital roof with the cyst marked at the level of the sphenoid planum (dashed line).

pathology. The mechanism for this improvement remains elusive. Shim *et al.*<sup>[21]</sup> reported a case series of SACs that were treated with transventricular endoscopic fenestration, patients with preoperative DI did not experience any improvement of their DI postoperatively.

## CONCLUSION

SACs are rare with unknown etiology, there is a controversy regarding the indications and timing of surgery as well as the optimal surgical approach. Our experience indicates that fenestration of SAC through a transcranial approach is safe and effective surgical option for patients who present with visual deficit and/or pituitary hormonal derangements.

## Declaration of patient consent

A patient consent was not obtained as this case report is retrospective in nature with no identifying information of the patient.

## Financial support and sponsorship

Nil.

## Conflicts of interest

There are no conflicts of interest.

## REFERENCES

1. Al-Holou WN, Terman S, Kilburg C, Garton HJ, Muraszko KM, Maher CO. Prevalence and natural history of arachnoid cysts in adults. *J Neurosurg* 2013;118:222-31.
2. Baskin DS, Wilson CB. Transsphenoidal treatment of non-

- neoplastic intrasellar cysts. A report of 38 cases. *J Neurosurg* 1984;60:8-13.
3. Cavallo LM, Prevedello D, Esposito F, Laws ER Jr., Dusick JR, Messina A, *et al.* The role of the endoscope in the transsphenoidal management of cystic lesions of the sellar region. *Neurosurg Rev* 2008;31:55-64.
  4. Ciric I, Ragin A, Baumgartner C, Pierce D. Complications of transsphenoidal surgery: Results of a national survey, review of the literature, and personal experience. *Neurosurgery* 1997;40:225-36.
  5. DeBattista JC, Andaluz N, Zuccarello M, Kerr RG, Keller JT. Refining the indications for the addition of orbital osteotomy during anterior cranial base approaches: Morphometric and radiologic study of the anterior cranial base osteology. *J Neurol Surg Rep* 2014;75:e22-6.
  6. Dubuisson AS, Stevenaert A, Martin DH, Flandroy PP. Intrasellar arachnoid cysts. *Neurosurgery* 2007;61:505-13.
  7. Gandy SE, Heier LA. Clinical and magnetic resonance features of primary intracranial arachnoid cysts. *Ann Neurol* 1987;21:342-8.
  8. Gdk M, HamitAytar M, Sav A, Berkman Z. Intrasellar arachnoid cyst: A case report and review of the literature. *Int J Surg Case Rep* 2016;23:105-8.
  9. Hayashi Y, Sasagawa Y, Oishi M, Kita D, Misaki K, Fukui I, *et al.* Contribution of intrasellar pressure elevation to headache manifestation in pituitary adenoma evaluated with intraoperative pressure measurement. *Neurosurgery* 2019;84:599-606.
  10. Hornig GW, Zervas NT. Slit defect of the diaphragma sellae with valve effect: Observation of a "slit valve". *Neurosurgery* 1992;30:265-7.
  11. Iida S, Fujii H, Tanaka Y, Hayashi S, Nagareda T, Moriwaki K. An intrasellar cystic mass and hypopituitarism. *Postgrad Med J* 1996;72:441-2.
  12. Iqbal J, Kanaan I, Al Homsy M. Non-neoplastic cystic lesions of the sellar region presentation, diagnosis and management of eight cases and review of the literature. *Acta Neurochir (Wien)* 1999;141:389-97.
  13. Kern E, Laws E. The rationale and technique of selective transsphenoidal microsurgery for the removal of pituitary tumors. In: Edward RL, editor. *Management of Pituitary Adenomas and Related Lesions with Emphasis on Transsphenoidal Microsurgery*. New York: Appleton-Century-Crofts; 1982.
  14. Laws ER. Endoscopic surgery for cystic lesions of the pituitary region. *Nat Clin Pract Endocrinol Metab* 2008;4:662-3.
  15. McLaughlin N, Vandergrift A, Ditzel Filho LF, Shahlaie K, Eisenberg AA, Carrau RL, *et al.* Endonasal management of sellar arachnoid cysts: Simple cyst obliteration technique. *J Neurosurg* 2012;116:728-40.
  16. Meyer FB, Carpenter SM, Laws ER Jr. Intrasellar arachnoid cysts. *Surg Neurol* 1987;28:105-10.
  17. Miyamoto T, Ebisudani D, Kitamura K, Ohshima T, Horiguchi H, Nagahiro S. Surgical management of symptomatic intrasellar arachnoid cysts--two case reports. *Neurol Med Chir (Tokyo)* 1999;39:941-5.
  18. Murakami M, Okumura H, Kakita K. Recurrent intrasellar arachnoid cyst. *Neurol Med Chir (Tokyo)* 2003;43:312-5.
  19. Roca E, Penn DL, Safain MG, Burke WT, Castlen JP, Laws ER. Abdominal fat graft for sellar reconstruction: Retrospective outcomes review and technical note. *Oper Neurosurg (Hagerstown)* 2019;16:667-74.
  20. Saeki N, Tokunaga H, Hoshi S, Sunada S, Sunami K, Uchino F, *et al.* Delayed postoperative CSF rhinorrhea of intrasellar arachnoid cyst. *Acta Neurochir (Wien)* 1999;141:165-9.
  21. Shim KW, Park EK, Lee YH, Kim SH, Kim DS. Transventricular endoscopic fenestration of intrasellar arachnoid cyst. *Neurosurgery* 2013;72:520-8.
  22. Shin JL, Asa SL, Woodhouse LJ, Smyth HS, Ezzat S. Cystic lesions of the pituitary: Clinicopathological features distinguishing craniopharyngioma, rathke's cleft cyst, and arachnoid cyst. *J Clin Endocrinol Metab* 1999;84:3972-82.
  23. Sze G. Diseases of the intracranial meninges: MR imaging features. *AJR Am J Roentgenol* 1993;160:727-33.
  24. Thaher F, Hopf N, Hickmann AK, Kurucz P, Bittl M, Henkes H, *et al.* Supraorbital keyhole approach to the skull base: Evaluation of complications related to CSF fistulas and opened frontal sinus. *J Neurol Surg A Cent Eur Neurosurg* 2015;76:433-7.
  25. Weil RJ. Rapidly progressive visual loss caused by a sellar arachnoid cyst: reversal with transsphenoidal microsurgery. *South Med J* 2001;94:1118-21.

**How to cite this article:** Aljuboori Z, Burke W, Yeo H, McCallum A, Clark J, Williams B. Orbitofrontal approach for the fenestration of a symptomatic sellar arachnoid cyst. *Surg Neurol Int* 2020;11:10.