

# Gastric Perforation Secondary to Ingestion of a Sharp Foreign Body

Amir Mehran, MD, David Podkameni, MD, Raul Rosenthal, MD, Samuel Szomstein, MD

## ABSTRACT

Foreign body ingestions are commonly seen by pediatricians and emergency room personnel. The majority of foreign bodies transit through the gastrointestinal system without any complications. Perforations are uncommon and usually involve peritonitis. We present a case of gastric perforation secondary to ingestion of a sharp metallic pin. Our patient did not demonstrate any of the classic findings described in the literature. His complaints, physical examination, and radiological findings all pointed to acalculous cholecystitis or biliary dyskinesia as the source of pain. Laparoscopy, however, provided the definitive diagnosis. Gastroduodenal perforation secondary to foreign body ingestion should be included in the differential diagnosis of these atypical cases of abdominal pain, especially if such history can be elicited from the patient.

**Key Words:** Laparoscopy, Foreign body, Perforation.

## INTRODUCTION

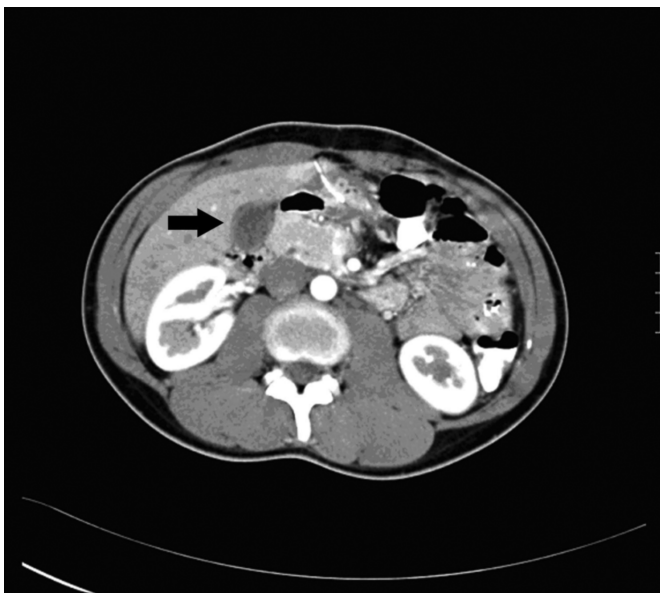A 25-year-old maritime employee presented to his ship's infirmary with a 10-day history of right upper quadrant (RUQ) abdominal pain. The pain was intermittent, occasionally postprandial, and not relieved with antacids. It was associated with nausea but no vomiting or changes in his bowel habits. A workup included serum chemistries, liver function tests, amylase levels, urinalysis, complete blood count (CBC), as well as chest and abdominal x-rays, all reportedly normal. He was referred to us when the ship arrived at port. Our physical examination was notable only for exquisite right upper quadrant (RUQ) tenderness. Repeat complete laboratory studies remained normal except for an elevated (89 U/L) serum glutamic oxaloacetic transaminase (SGOT). Repeat x-rays, however, were not performed. He was admitted for observation and placed empirically on intravenous antibiotics and famotidine. Ultrasound of the abdomen revealed no gallstones. In consultation with the radiology service, a computerized tomography (CT) scan of the abdomen was subsequently performed with oral and intravenous contrast (**Figure 1**).

The CT revealed fluid around the gallbladder. The patient did not clinically improve over the next 24 hours. A diagnostic laparoscopy was performed for a presumed diagnosis of acalculous cholecystitis. **Figure 2** best illustrates the immediate operative findings. The gallbladder appeared normal with free fluid in the subhepatic space. A sharp object could be seen protruding from the stomach and through the liver and was associated with acute and chronic local inflammatory changes. Laparoscopic removal was initially attempted (**Figure 3**) but abandoned as an intraluminal component was suspected. Obtaining an intraoperative consultation for flexible endoscopy would have significantly prolonged the patient's exposure to anesthesia. Therefore, a limited laparotomy was performed, revealing a 3-cm metallic pin (**Figure 4**). Careful inspection of the stomach did not demonstrate any further abnormalities, and the defect was closed primarily with an omental patch. Postoperative abdominal x-rays did not reveal any other foreign bodies. At the follow-up clinic visit, he remembered using a metallic pin as a toothpick a few days before the onset of the severe abdominal pain. A

Division of Minimally Invasive & Bariatric Surgery, Cleveland Clinic Florida, Weston, Florida, USA (all authors).

Address reprint requests to: Samuel Szomstein, MD, Department of Surgery, Cleveland Clinic Florida, 2950 Cleveland Clinic Blvd., Weston, FL 33331, USA. Telephone: 954 689 5000, E-mail: szomsts@ccf.org

© 2005 by JSLS, *Journal of the Society of Laparoendoscopic Surgeons*. Published by the Society of Laparoendoscopic Surgeons, Inc.

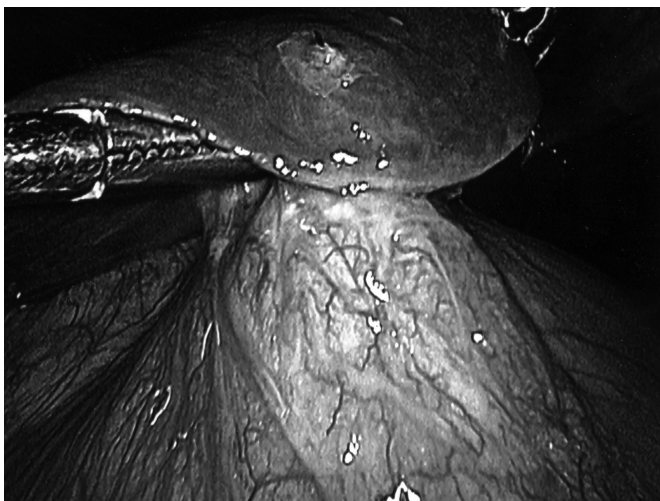


**Figure 1.** CT demonstrating pericholecystic fluid.


retrospective review of the CT confirmed the presence of the foreign body on only one of the axial cuts (**Figure 1**).

## DISCUSSION

Ingestion of foreign bodies is common in the pediatric, psychiatric, and prison populations.<sup>1,2</sup> The majority of objects, however, pass through the gastrointestinal system without any sequelae. Perforations occur in less than 1% of the cases, mostly in the esophagus and ileo-cecum.<sup>1,3</sup> Gastric perforations secondary to foreign body ingestion

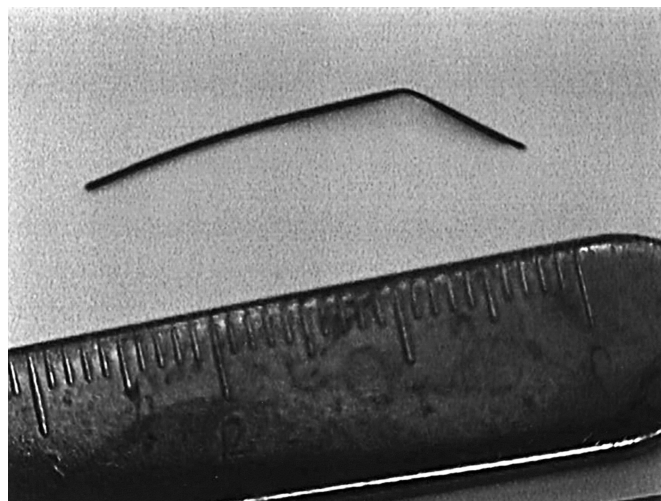


**Figure 2.** Sharp object protruding from the stomach and through the liver.

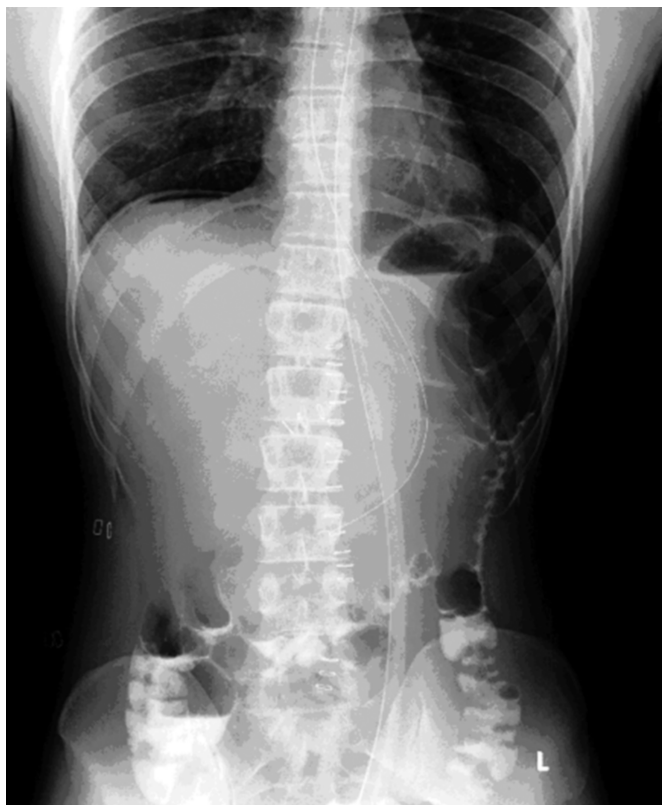

**Figure 3.** Limited attempt at laparoscopic removal.

are uncommon. They mostly present with peritonitis, but some may spontaneously seal off and remain asymptomatic or even lead to an intraabdominal abscess.<sup>1,4,5</sup> Early endoscopy, therefore, is advocated for foreign bodies lodged in the stomach.<sup>1-3</sup> In a review of over 540 such cases, Velitchkov et al<sup>2</sup> reported only 4 perforations but did not elaborate on their clinical presentation. In our patient, intermittent RUQ pain worsened by eating, and lack of relief from antacids, “normal” outpatient x-rays, an elevated SGOT level, and pericholecystic fluid on the CT scan skewed our thought process towards acalculous cholecystitis as the cause of the persistent RUQ tenderness. Gastroduodenal perforation secondary to foreign body ingestion should be included in the differential diagnosis



**Figure 4.** The 3 cm metallic pin removed during minilaparotomy.



**Figure 5.** Postoperative upright abdominal x-ray demonstrating no further ingested foreign bodies.

of these atypical cases of abdominal pain, especially if such history can be elicited from the patient. Our case further highlights both the value of the laparoscopic approach to such unusual cases, as well as the necessity for surgeon experience with flexible endoscopy.

**References:**

1. Lam PY, Marks MK, Fink AM, Oliver MR, Woodward A. Delayed presentation of an ingested foreign body causing gastric perforation. *J Pediatr Child Health*. 2001;37(3):303–304.
2. Velitchkov NG, Grigorov GI, Losanoff JE, Kjossev KT. Ingested foreign bodies of the gastrointestinal tract: retrospective analysis of 542 cases. *World J Surg*. 1996;(20):1001–1005.
3. Steenvoorde P, Moues CM, Viersma JH. Gastric perforation due to the ingestion of a hollow toothpick: report of a case. *Surg Today*. 2002;32(8):731–733.
4. Dugger K, Lebbly T, Brus M, Sahgal S, Leikin JB. Hepatic abscess resulting from gastric perforation of a foreign object. *Am J Emerg Med*. 1990;8(4):323–325.
5. Porcu A, Dessanti A, Feo CF, Dettori G. Asymptomatic gastric perforation by a toothpick. *Dig Surg*. 1999;16(5):437–438.