

increasing due to technological advancements over the last two decades (5, 6). In this paper, we present a new technique for the endovascular treatment of visceral artery pseudoaneurysm using selective arterial embolization of a cut-inflated-deflated balloon technique.

Case Report

A 65-year-old female patient presented at the emergency department with abdominal pain, nausea, and vomiting. She had a history of having undergone surgery 15 days previously due to gastrointestinal malignancy. Physical examination revealed blood pressure of 80/45 mm Hg, with 14 respirations per minute and a heart rate of 100 beats per minute. Initial blood results showed hemoglobin of 6.24 g/dL, white cell count of 12.500 mm³, and platelets of 350.000 mm³. Contrast-enhanced abdominal computed tomography (CT) showed contrast extravasation in a branch of the superior mesenteric artery. We decided to perform an endovascular treatment due to the patient's recent history of surgery and her increased mortality risk. For this, the patient was taken to the catheter laboratory. A 6-Fr sheath was inserted into the femoral artery, and a 6-Fr right Judkins guiding catheter was used to cannulate the superior mesenteric artery ostium. Superior mesenteric artery angiography showed contrast extravasation and pseudoaneurysm. An 8-Fr sheath was placed into the femoral artery after the branch of the superior mesenteric artery pseudoaneurysm was identified. Then, a 7-Fr renal double curve guiding catheter was used to engage the ostium of the superior mesenteric artery. The lesion was successfully crossed with a

A novel technique for treating visceral artery pseudoaneurysm: Selective arterial embolization with cut-inflated-deflated balloon 🎥

Yusuf Can, İbrahim Kocayigit
Department of Cardiology, Faculty of Medicine, Sakarya University;
Sakarya-Turkey

Introduction

Visceral artery pseudoaneurysm is a rare acute abdominal condition that might be caused by inflammation, infection, vasculitis, post-traumatic damage, connective tissue disease, iatrogenic damage, segmental arterial mediolysis, or malignancy (1-4). The number of cases of visceral artery pseudoaneurysm treated with new endovascular and percutaneous techniques is



Figure 1. Angiogram of the superior mesenteric artery showing a perforated segment (white arrows) and pseudoaneurysm (red arrows) in the branch of the superior mesenteric artery

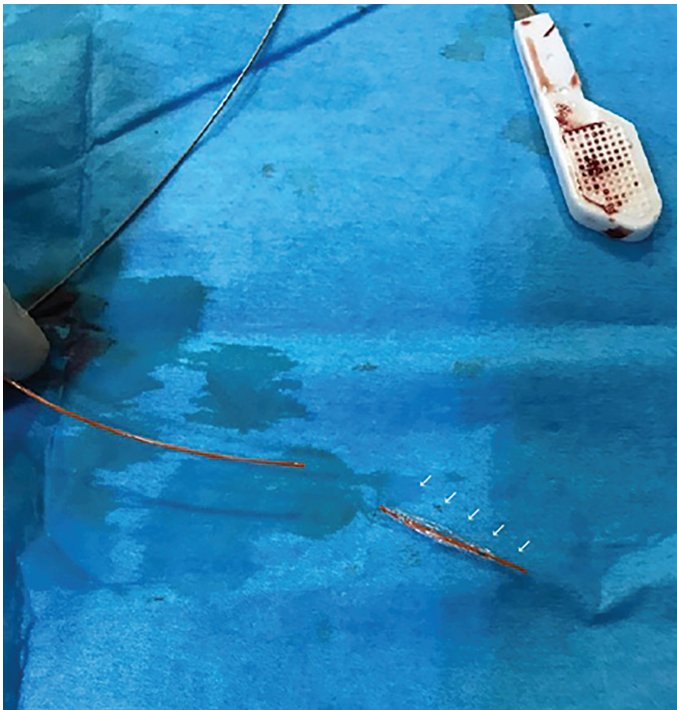


Figure 2. The balloon catheter was cut using a scalpel (white arrows) 0.014-inch wire under fluoroscopic guidance. Then, the ruptured branch of the superior mesenteric artery pseudoaneurysm was selectively visualized with a microcatheter (Video 1, Fig. 1). Next, the inflated-deflated balloon catheter was cut with a scalpel (Video 2, Fig. 2). The cut-inflated-deflated balloon was advanced into the segment of extravasation with a microcatheter over 0.014-inch wires (Videos 3 and 4). After the inflated-deflated balloon was delivered, the 0.014-inch wire was removed (Fig. 3). After embolization with the cut-inflated-deflated balloon, selective

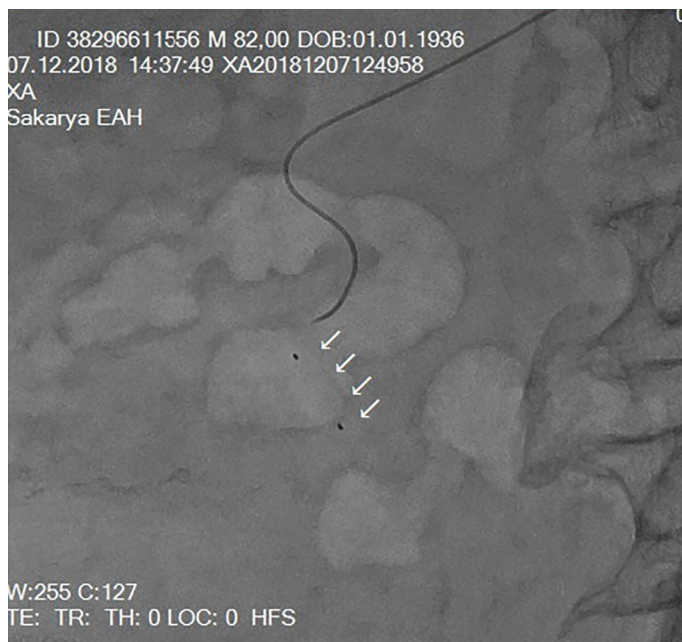


Figure 3. White arrows show the cut-inflated-deflated balloon catheter

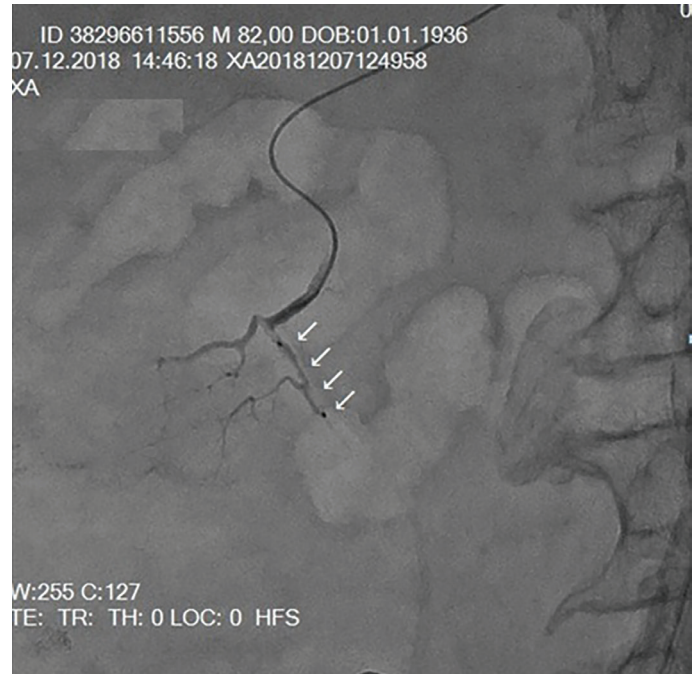


Figure 4. Angiogram displaying complete sealing of the perforation after implantation of the cut-inflated-deflated balloon catheter (white arrows)

imaging was performed with the microcatheter, again. We observed that the contrast extravasation completely disappeared after embolization with the inflated-deflated balloon (Video 5, Fig. 4). The patient was discharged uneventfully on the sixth day of hospitalization.

Discussion

The actual incidence of pseudoaneurysms is unknown. The majority of patients with visceral artery pseudoaneurysm are symptomatic, with asymptomatic patients constituting only approximately 2%–3% of the total (7). Because the risk of rupture is high, all visceral artery pseudoaneurysms must be treated promptly irrespective of their size, location, and symptom status. When left untreated, mortality rates in patients with a pseudoaneurysm can be 90%–100% (1, 8, 9).

In patients with a visceral artery pseudoaneurysm, endovascular and percutaneous techniques are effective and reliable treatment options, in addition to being minimally invasive in comparison to surgery. Patient comorbidity or anatomic suitability is important in the choice of treatment. In recent years, most patients with a pseudoaneurysm have been treated with endovascular and percutaneous methods (5, 6). If percutaneous and endovascular treatments fail, surgical treatment should be considered as an alternative. The major advantages of endovascular and percutaneous treatment techniques are the avoidance of general anesthesia, immediate post-procedure angiographic control, low risk of complications, and faster recovery.

Graft-covered stents and embolic materials are used in endovascular and percutaneous treatment techniques, either alone or in combination. The decision to perform endovascular treatment with embolic materials or stenting is based on the size of the pseudoaneurysm, the neck of the pseudoaneurysm, the parent artery, whether the artery is expendable, nonexpendable, or tortuous, the location of the pseudoaneurysm, and the patient's coagulation parameters (6, 10).

Many types of materials are used for embolization, such as coils, microcoils, cyanoacrylate glue, foam gelatin, amplatzer vascular plugs, ethylene vinyl alcohol copolymer (EVOH-Onyx®), tris-acryl gelatin microspheres, polyvinyl alcohol (PVA), or calcium alginate gel (ALGEL) particles (11). Coils may be preferred in expendable arteries or pseudoaneurysms with a narrow neck. The diameter of the coil should be 20% greater than the diameter of the vessel. Sac packing, proximal occlusion, the sandwich technique, and stent-assisted and balloon remodeling techniques can be used in coil embolization. Some risks, such as of rupture, infection, and non-target embolization, are associated with coil embolization. Liquid embolic agents are used with tortuous and small arteries in patients with a visceral artery pseudoaneurysm. The disadvantages of liquid embolic agents are the risk of catheter trapping, non-target embolization, and infection. Additionally, an allergic reaction can occur when using thrombin (6, 10).

Graft-covered stents may be more appropriate in large-diameter vessels and pseudoaneurysms. Graft-covered stent placement is not possible in small branches of the mesenteric artery, as seen in the case presented in this paper. Stenting may not be suitable if the vessel has sharp angulation or severe tortuosity. If a stent is to be implanted, balloon-expandable stents should be preferred for the straight proximal segment of the mesenteric artery and self-expandable stents should be preferred for tortuous arteries. A minimum distance of 10 mm on both sides of the pseudoaneurysm is recommended to ensure an adequate seal (10).

Detachable balloons, applied in a technique similar to the method we are proposing, are used especially in the treatment of cranial aneurysms and arteriovenous fistulas. Detachable balloons can have an instant and precise occlusive effect on large arteries and fistulae; however, unlike any other embolization technique, the occlusion is reversible until the balloon is finally detached (12). Our technique is an example of the manual construction of a similar detachable balloon technique.

Percutaneous treatment can be performed in large, superficial, relatively narrow necked and solid organ pseudoaneurysms under ultrasonography or CT guidance. Embolic materials are used in this approach, and the complications of this method are similar to those found with endovascular treatment. The patient in our case was not eligible to undergo percutaneous treatment due to the presence of a small, deep, and intestinal artery pseudoaneurysm. Since we did not have coil and embolic materials in our catheter laboratory, we successfully managed to treat the ruptured visceral artery pseudoaneurysm using the embolization technique with a cut-inflated-deflated balloon. This method is

less costly than coil embolization. Bleeding in the small vessels can be easily controlled with this method. Potential complications of this method include non-target embolization, migration after embolization, infection, and recurrence of the pseudoaneurysm. No previous study has reported on the use of the embolization technique with a cut-inflated-deflated balloon to treat a visceral artery pseudoaneurysm. This method has several advantages: it is effective, easy-to-use and affordable, and it can be used in all catheter laboratories.

Conclusion

In conclusion, embolization with a cut-inflated-deflated balloon technique is an easy, inexpensive, effective treatment option for patients with a visceral artery pseudoaneurysm.

Informed consent: Written informed consent was obtained from the patient for publication of the case report and the accompanying videos and images.

Video 1. Angiogram shows a perforated segment and pseudoaneurysm in the branch of the superior mesenteric artery.

Video 2. The balloon catheter was cut using a scalpel.

Video 3. The cut-inflated-deflated balloon loaded over the guidewire.

Video 4. The cut-inflated-deflated balloon catheter was advanced into the segment of extravasation with a microcatheter over the guidewire.

Video 5. Angiogram demonstrates complete sealing of the perforation after implantation of the cut-inflated-deflated balloon catheter.

References

1. Cordova AC, Sumpio BE. Visceral artery aneurysms and pseudoaneurysms should they all be managed by endovascular techniques? *Ann Vasc Dis* 2013; 6: 687-93.
2. Noshier JL, Chung J, Brevetti LS, Graham AM, Siegel RL. Visceral and renal artery aneurysms: a pictorial essay on endovascular therapy. *Radiographics* 2006; 26: 1687-704.
3. Belli AM, Markose G, Morgan R. The role of interventional radiology in the management of abdominal visceral artery aneurysms. *Cardiovasc Intervent Radiol* 2012; 35: 234-43.
4. Gabelmann A, Görlich J, Merkle EM. Endovascular treatment of visceral artery aneurysms. *J Endovasc Ther* 2002; 9: 38-47.
5. Zabicki B, Limphaibool N, Holstad MJV, Juszkat R. Endovascular management of pancreatitis-related pseudoaneurysms: A review of techniques. *PLoS One* 2018; 13: e0191998.
6. Madhusudhan KS, Venkatesh HA, Gamanagatti S, Garg P, Srivastava DN. Interventional Radiology in the Management of Visceral Artery Pseudoaneurysms: A Review of Techniques and Embolic Materials. *Korean J Radiol* 2016; 17: 351-63.
7. Tessier DJ, Stone WM, Fowl RJ, Abbas MA, Andrews JC, Bower TC, et al. Clinical features and management of splenic artery pseu-

- doaneurysm: case series and cumulative review of literature. *J Vasc Surg* 2003; 38: 969-74.
8. Lu M, Weiss C, Fishman EK, Johnson PT, Verde F. Review of visceral aneurysms and pseudoaneurysms. *J Comput Assist Tomogr* 2015; 39: 1-6.
 9. Guillon R, Garcier JM, Abergel A, Mofid R, Garcia V, Chahid T, et al. Management of splenic artery aneurysms and false aneurysms with endovascular treatment in 12 patients. *Cardiovasc Intervent Radiol* 2003; 26: 256-60.
 10. Hemp JH, Sabri SS. Endovascular management of visceral arterial aneurysms. *Tech Vasc Interv Radiol* 2015; 18: 14-23.
 11. Vaidya S, Tozer KR, Chen J. An overview of embolic agents. *Semin Intervent Radiol* 2008; 25: 204-15.
 12. Higashida RT, Halbach VV, Dowd C, Barnwell SL, Dormandy B, Bell J, Hieshima GB. Endovascular detachable balloon embolization therapy of cavernous carotid artery aneurysms: results in 87 cases. *J Neurosurg* 1990; 72: 857-863.

Address for Correspondence: Dr. Yusuf Can,
Sakarya Üniversitesi Tıp Fakültesi,
Kardiyoloji Anabilim Dalı,
Sakarya-Türkiye
Phone: +90 541 251 41 49



E-mail: dr.ycan@hotmail.com

©Copyright 2020 by Turkish Society of Cardiology - Available online

at www.anatoljcardiol.com

DOI:10.14744/AnatolJCardiol.2020.59507