



OPEN ACCESS

## CASE REPORT

# Fast-tracked Rehabilitation and Return to Sport of an Elite Rugby Player with a Complicated Posterolateral Corner Injury and Associated Peroneal Paralysis

L.D.A. Paget,<sup>1,2</sup> P.P.F.M. Kuijer,<sup>3</sup> M. Maas,<sup>2,4</sup> G.M.M.J. Kerkhoffs<sup>1,2</sup>

<sup>1</sup>Department of Orthopaedics, Academic Medical Center, Amsterdam, The Netherlands

<sup>2</sup>Academic Center for Evidence-Based Sports Medicine (ACES), Academic Medical Center, Amsterdam, The Netherlands

<sup>3</sup>Coronel Institute of Occupational Health, Academic Medical Center, Amsterdam, The Netherlands

<sup>4</sup>Department of Radiology, Academic Medical Center, Amsterdam, The Netherlands

**Correspondence to**

L.D.A. Paget,  
Lda.paget@gmail.com

Accepted 25 September 2017

**SUMMARY**

Acute posterolateral corner injuries of the knee with associated hamstring avulsions and peroneal paralysis are rare in rugby. Regain of motor function following a complete paralysis is documented to be 38%. To our knowledge, only one case describes return to preinjury level of competitive sport taking up to 27 months. A 24-year-old international level rugby player, a medical student, sustained an acute posterolateral knee injury with associated anterior cruciate ligament tear, biceps femoris and semimembranosus avulsions as well as a complete peroneal paralysis. The patient returned to full-time medical rotation work weeks at 5 months. At 10 months, the patient was considered to have returned to preinjury level of activity having managed a 5 km run, participated regularly in non-contact rugby and performed exercises at 140% of his preinjury maximum. This case report describes the successful outcome of a high-frequency high-intensity rehabilitation.

**BACKGROUND**

This case report describes an elite rugby player with a complex posterolateral corner (PLC) injury sustained while playing rugby. A rare occurrence in the aforementioned contact sport, with the most common knee injury comprising anterior cruciate ligament (ACL) and medial collateral ligament (MCL) tears.<sup>1–3</sup> The main contributors of stabilisation to the posterolateral corner of the knee include the lateral collateral ligament, arcuate ligament, posterolateral capsule as well as the popliteus muscle-tendon-ligament unit (including the popliteal muscle and tendon in addition to the popliteofibular ligament). The aforementioned structures provide restraint to varus and external rotation.<sup>4–8</sup> LaPrade *et al* observed a multiple ligament knee injury to be present in 87% of cases with posterolateral structure damage, of which 13% was associated with an ACL injury.<sup>9–11</sup> As the common peroneal nerve is situated in the posterolateral corner, it is understandably consistent with 26% of multiple ligament knee injuries.<sup>12</sup> Furthermore, peroneal palsy is present in 44% of cases with an associated biceps femoris avulsion fracture or tendon tear.<sup>13</sup> According to Niall *et al*, 10% of patients with peroneal palsy had complete loss of sensibility and motoric function at initial presentation of which 50% would not regain peroneal nerve function. In 29% of the aforementioned

group, partial recovery was seen. Only 21% would eventually regain full motoric function. Recovery was associated with the damaged length of the nerve being less than 7 cm, more extensive damage was met with a poorer prognosis.<sup>10</sup> Ridley *et al* observed similar statistics, with only 38% of patients recovering from an initial complete paralysis presentation.<sup>12</sup> Furthermore, it was observed that the superficial branch, innervating the peronei muscles, was the first to recover. The deep branch, facilitating dorsiflexion of the foot, would often take longer to recover if at all.<sup>10 14 15</sup> Cases comprising a biceps femoris avulsion fracture, complete peroneal palsy and multiple ligament knee injury have a poor prognosis regarding return to sports. Although return to sports is a wide concept, our goal is returning to preinjury level of sports without contact, not just being able to achieve functionality or physical exercise.<sup>16</sup> However, the obstacle is overcoming the peroneal paralysis and the manner in which it inhibits rehabilitation, and regaining proprioception, strength, speed and explosiveness associated with the preinjury level of knee functionality. To our knowledge, there is only one case report describing an actual return to elite level competitive sports taking up to 27 months.<sup>17</sup> Although the ‘figure-of-8 posterolateral knee reconstruction according to Fanelli and Larson’ is among the several techniques most frequently used, there is still no clear consensus regarding the swiftest return to sports.<sup>18 19</sup> We hypothesise that an all-out rigorous rehabilitation programme, where the athlete is pushed to his limits, will provide a faster return to work and preinjury level sports as opposed to adversely affecting the recovery.

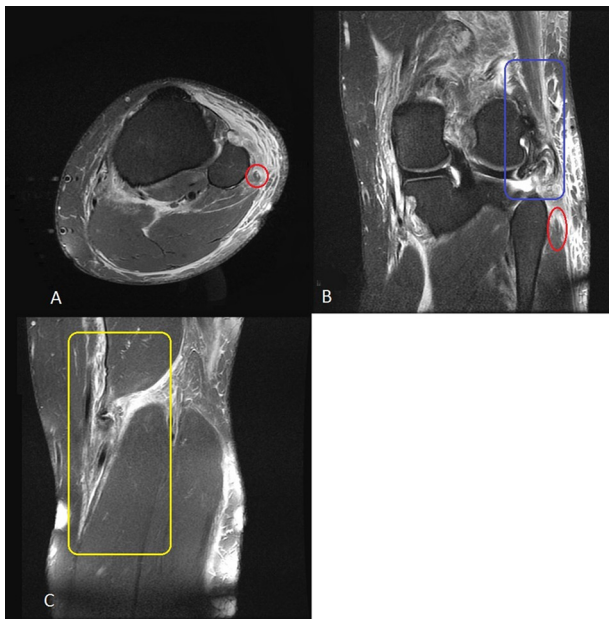
**CASE PRESENTATION**

A 24-year-old international level rugby player, fifth year medical student and an author of this paper, presented himself at the emergency department following a rugby-related trauma involving a posterolateral hyperextension of the left knee with considerable hydrops. The patient was 1.95 m in length and weighed 115 kg with a fat percentage of 16%. Examination showed a positive Lachman and varus stress test with a range of motion (ROM) noted as flexion/extension 100/0/0. Furthermore, complete loss of dorsiflexion and eversion of the left foot was observed as well as sensibility loss of the lateral half of the lower left leg and dorsum of



CrossMark

**To cite:** Paget L.D.A., Kuijer P.P.F.M., Maas M., *et al*. *BMJ Case Rep* Published Online First: [please include Day Month Year]. doi:10.1136/bcr-2017-219666



**Figure 1** Depicts the cross-sectional (A) and sagittal (B and C) view of the left knee, illustrating the extent of the damage as seen on the MRI. A and B show a longitudinal hyperintensity in the centre of an enlarged peroneal nerve encircled with red. The blue (B) and yellow (C) boxes mark areas of hyperintensity displaying marked loss and retracted muscle structure of the biceps femoris and semimembranosus, respectively.

the foot. Left knee flexion strength was graded at 2/5 on the Medical Research Council (MRC) scale for muscle power. The MRI, shown in [figure 1](#), revealed an avulsion fracture of the semimembranosus, a torn ACL and a complex complete PLC injury comprising a distal biceps femoris tendon avulsion fracture, grade 3 LCL, arcuate ligament and popliteus muscle-tendon-ligament unit tear as well as extensive injury to the peroneal nerve consisting of a longitudinal tear. An electromyography (EMG), performed the same week showed possible continuation of the peroneal nerve, yet minimal to no signal conduction. Due to the short time postinjury at which the EMG was performed, it was repeated at 6 weeks postinjury. This EMG showed denervation of the tibialis anterior and minimal movement of the peroneus brevis following stimulation. Due to the considerable haemarthrosis, the reconstruction of the PLC and ACL repair was set for 8 weeks postinjury.

## TREATMENT

### Preoperative rehabilitation

The patient underwent a rigorous training and diet programme at his own initiative, starting 6 days postinjury, to facilitate the well-known elite athlete's need to fast-track the return from injury. The following goals were set to attain this:

1. Pain management
2. Increase in ROM
3. Increase of overall leg strength and minimisation of atrophy
4. Stimulation of the elite athlete's mental drive during rehabilitation.

Goals 1, 2 and 4 were similarly applied postoperatively and will therefore be described in more detail further on. Goal 3 was considerably restricted due to the paralysis, reduced range of motion and pain. However, preoperative fitness was considered a major factor contributing to a successful postoperative

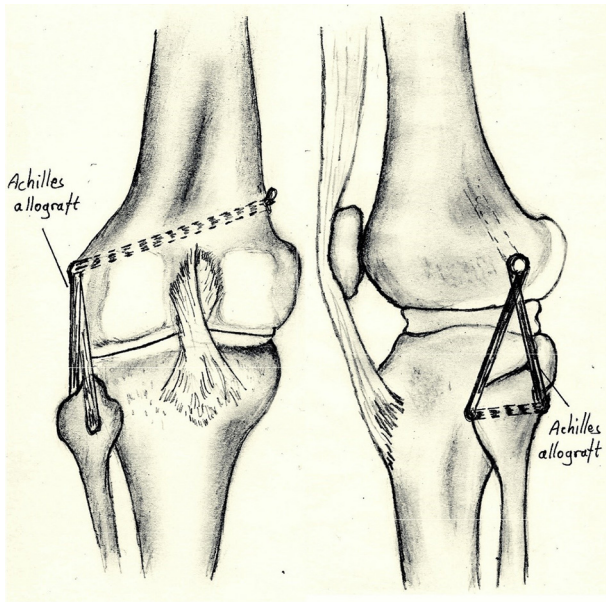
rehabilitation. In addition, training of the non-immobilised leg was deemed beneficial due to cross-education. This is a phenomenon where training of the non-immobilised limb was implicated to promote hypertrophy in the immobilised leg as well as cortical adaptations regarding functionality concerning both legs.<sup>20</sup> The paralysed peronei muscles, tibialis anterior and hallucis longus as well as the quadriceps underwent transcutaneous neuromuscular electrical stimulation (NMES) in two settings (30 min at 5 Hz, 400  $\mu$ s and 30 min at 30 Hz, 160  $\mu$ s) one to two times a day. Additionally, NMES was applied at 1–150 Hz on the posterior aspect of the fibular head to act as a neurostimulator for the paralysed peroneal nerve to stimulate function.<sup>21</sup> Ten days post-injury, the pain and strength was acceptable enough to start lower body weighted exercises in addition to the daily NMES. This included suspension cord (TRX) stabilised own body-weighted squats. Two weeks postinjury, the patient upgraded leg exercises to TRX stabilised single-leg squats to 90 degrees on the injured leg. Upper and lower body training sessions were alternated six times a week. This was eventually upgraded to eight training sessions when an increase in range of motion of the knee permitted two additional aerobic/anaerobic interval training sessions weekly in the form of outdoor cycling. Six weeks postinjury, the patient proceeded to jog a distance of 2 km twice, mainly due to the patient's own extreme stubbornness at the sudden dramatic reduced functionality. This was done using a peroneal orthosis to counter the foot-drop and tape to stabilise the knee. On both occasions, there was no subsequent swelling of the knee or pain.

To support the training regimen, a high-protein diet was undertaken.<sup>22</sup> The patient used supplements frequently used in the elite athlete world. These included 60 g of whey isolate and 10 g of Branched Chain Amino Acids (BCAA's) throughout the day in addition to magnesium, zinc as well as omega-3 supplementation. This was initiated as whey protein has been seen to increase muscle mass, performance and enhance recovery.<sup>22</sup> Although there is no medical evidence to support the use of magnesium, zinc and omega-3 supplementation, these were documented in order to remain transparent. It must be mentioned that the elite athlete used these supplements on his own initiative.

### Reconstruction of the knee

Eight weeks postinjury, an ACL reconstruction using a Bone-patellar Tendon-bone (BTB) allograft and a figure-of-8 Posterolateral Corner (PLC) reconstruction using an Achilles tendon allograft, first described by Fanelli and Larson, was performed as seen in [figure 2](#).<sup>23</sup> The latter is a fibular head-based technique where the graft is passed through a tunnel made in an anterior to posterior direction. By using the figure-of-8 construct, the graft recreates the popliteofibular-ligament-complex and Lateral Collateral Ligament (LCL) stability due to the posterior and anterior arms of the graft respectively protruding from the fibular head tunnel.

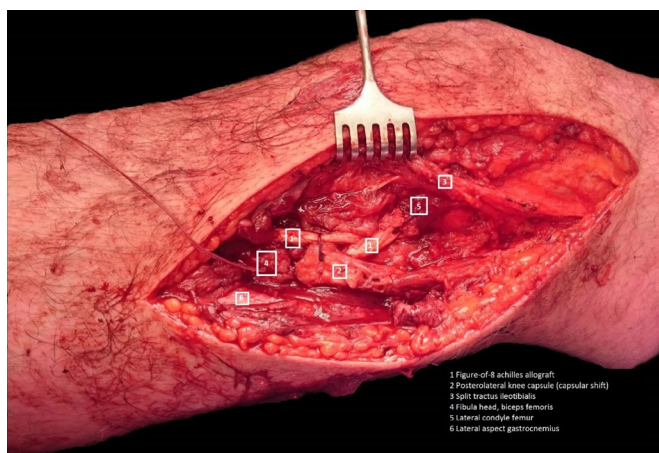
On opening the posterolateral corner, the surgeon encountered an 'exploded' area making it a complex repair as seen in [figure 3](#). A neurolysis of the peroneal nerve was performed with the injured nerve spanning a distance of 15 cm. Four centimetres proximal to the fibular head, the surgeon encountered a part of the peroneal nerve which seemed to have shown discontinuity or a longitudinal tear, as is described in the MRI report. Then, an ACL reconstruction was performed.<sup>24</sup> During the aforementioned procedure, a healed longitudinal tear of the medial meniscus was encountered.



**Figure 2** Illustration of the posterolateral reconstruction technique described by Fanelli and Larson, using an Achilles allograft which is passed through the tunnel of the fibular head. The figure-of-8 construction mimics the absent LCL and popliteofibular ligament stability.<sup>23 37</sup>

### Postoperative rigorous rehabilitation phase

Regular rehabilitation protocols for multiligament knee injuries dictate maintaining the knee, non-weight bearing, in a full extension brace for 5 weeks. From week 6 through to week 10, weight bearing is progressively increased by 20% body weight each week. Closed kinetic chain strength, ROM and proprioceptive exercises are slowly started from week 11 onwards. Return to sports and heavy labour occur at least 9 months postsurgery.<sup>18 25</sup> However, return to preinjury level of sports following multiligament knee injuries with associated hamstring avulsions and peroneal palsy has been documented to take 27 months.<sup>17</sup> As our hypothesis suggests, we strived to fast-track the recovery period and assess whether a rigorous rehabilitation protocol would benefit or adversely affect the convalescent period.



**Figure 3** The state of the posterolateral corner of the left knee, with the Achilles tendon allograft set in place in a figure-of-8 according to Fanelli.

Our patient was interned for 6 days after the PLC and ACL reconstruction, following which, the rehabilitation was started immediately according to the previously mentioned goals:

1. Pain management
2. Increase in ROM
3. Leg strength and minimisation of atrophy
4. Stimulation and support of the elite athlete's mental drive during rehabilitation.

### Goal 1: pain management

The first goal was mainly set on hydrops reduction. Ice packs, pressure bandages and lymph drainage massage were used daily to decrease swelling in the operated limb. This was supported by 10 min sessions of whole body cryotherapy to reduce swelling, alleviate muscle soreness and facilitate recovery.<sup>26 27</sup> The patient was in considerable discomfort sleeping 4 hours a night the first 8 weeks.<sup>28</sup> The pain was located primarily along the lateral part of the leg including the biceps femoris, vastus lateralis, tractus ileotibialis and peronei muscles. As the patient became increasingly active around week 9 postsurgery and the peroneal function had started to return, the paralysed peronei muscles and calve became increasingly tender. At 27 weeks, the highest area of pain once again shifted to the lateral side of the leg, involving predominantly the gluteal muscles as well as the vastus lateralis and tractus ileotibialis. At week 30, the sensation slowly started to return which resulted in sharp stabbing pains, even with light touch such as clothes or bedlinen.

Pain medication consisted of novalgin, paracetamol and oxycodone for the first couple of weeks. For severe local pain, Transcutaneous Electrical Neuro Stimulation (TENS) was applied. Sport massages and dry needling were used daily to relax sensitive trigger points in the problem muscles.<sup>29 30</sup> As the rehabilitation progressed, dry needling played an increasing role as main pain relief treatment. As many intensely painful myofascial trigger points limited the frequency and intensity at which the rigorous rehabilitation could be upheld, the patient was taught how to dry needle himself. This was deemed responsible regarding his own medical background. The patient now tended to his own sensitive trigger points permitting better pain control which possibly facilitated muscle recovery and a more unrestricted training frequency. Pain throughout the rehabilitation stemming from muscle imbalances, such as the gluteal muscles, were treated with stability exercises.

### Goal 2: increase in ROM

Particularly in the initial weeks, goal 2 focused primarily on a week by week increase in ROM. Our patient was equipped with a valgus locking brace for a period of 2 weeks at 0–30 degrees flexion at discharge. The degree of flexion was to be expanded by 15 degrees every week for 4 weeks until reaching 90-0-0. In the seventh week, the knee brace was discarded. Apart from the factors facilitating hydrops reduction as described under goal 1: pain management, ROM increase was further managed through stretching, manipulation and massage of the scar tissue, knee capsule, quadriceps and its tendon. This was performed daily by physiotherapists until ROM had progressed sufficiently to allow cycling outdoors in week 15.

### Goal 3: leg strength and minimisation of atrophy

Our patient had lost 20 kg since the injury, bringing him to 95 kg, despite the preoperative training. The postoperative training got off to a difficult start. The lack of sleep made it difficult to recover sufficiently, both physically and mentally during the rigorous rehabilitation.<sup>28</sup> Goal 3 was facilitated by way of electrical

muscle stimulation starting 2 days postoperation.<sup>31–33</sup> The same settings were used as described in the preoperative rehabilitation section. Our patient started with upper body weight training every second day 2.5 weeks postoperation. In week 5, the patient performed leg exercises from Monday to Friday, which eventually allowed him to walk without crutches by week 7. Exercises were initially done 7 min continuously while receiving electrical stimulation on the muscles being trained.<sup>31–33</sup> Therefore during leg press and squats, NMES was applied on both the quadriceps and hamstrings simultaneously. This was then upgraded to 4 sets of 10 repetitions and eventually progressed to even fewer sets and repetitions with heavier weights.<sup>34</sup> Two months following the operation, the patient started using the AlterG daily. This is an antigravity treadmill, allowing the patient to run at 65% of his own body weight. By week 7, our patient started feeling physically exhausted, suffering from severe tiredness, nausea and mood swings. Our patient opted to increase the intensity and frequency of the rehabilitation, working towards a complete break in week 11 and 12. Thus, two additional high-intensity cardio sessions consisting of several low-weighted Tabata protocols were added. The aforementioned are high-intensity interval training protocols consisting of eight sets of 100% intensity bouts of activity of 20 s followed by 10 s of rest. One protocol lasts for 4 min, with the amount of protocols (usually 4–8) depending on symptoms such as dizziness and nausea. The exercise used in the protocols varied and included low weights, cycling, rowing, heavy rope training and the use of a cross-trainer. Due to the increased intensity and ever-reducing rate of recovery, extra focus was put on nutrition and the earlier described supplements to uphold the intensity. In addition, the patient used creatine for the remaining 3 weeks. After 2 weeks of a complete rest in Greece, the patient felt mentally and physically recharged. In the meantime, peroneal function allowed the patient to perform a weak dorsiflexion of the foot several times a day. Furthermore, the patient was able to do a 90 kg single-leg press continuously for 7 min at high intensity with NMES stimulation. The progression of the exercises as well as other exercises performed are illustrated in figure 4A,B. The figure does not illustrate the weights in kg but a percentage of the preinjury level of activity. The preinjury '100%' weight is documented in the legend beside its respective exercise. So, in week 16, our patient performed a leg extension at 50% of preinjury level. In the legend, 40 kg marks the preinjury level of leg extension, making our patients level of leg extension in week 16, 20 kg.

In addition to working on hypertrophy, power and explosiveness, particular attention was paid to stability exercises, such as balancing on an unstable surface (eventually while hopping) with one leg, clamshell and Dynaband lateral walk. When ROM permitted, the patient proceeded to do an hour of outdoor cycling a day in addition to the current training regimen. The intensity was upheld, making it 5 weighted leg sessions a week, 3 upper body weighted sessions a week, 2 cardio sessions as well as 1–2 hours of cycling a day.

The paralysed muscles continued to be stimulated and the peroneal nerve at the fibular head underwent neurostimulation daily using NMES for 15 min. However, as the hallucis longus, tibialis anterior and peronei muscles did not initially react to the transcutaneous electrode pads, it was opted to conduct NMES intramuscularly. With this method, needles were inserted into the belly of the muscle allowing for a more direct stimulation of the paralysed muscles. This was done at a pulse frequency of 1/30–10 Hz. One week following the start of this intervention, the patient noticed a rapid progression in muscle growth and eventually function in the paralysed muscles.

Throughout the rehabilitation, additional sport massages, dry needling, hydration and diet were used to uphold the ever-increasing intensity and meet the demands needed for recovery. This was crucial as several periods of a marked drop in ability to maintain the intensity and recover were associated with a reduced adherence to the earlier mentioned interventions.

In figure 4A,B, all quadriceps-associated exercises seem to initially progress faster before slowing down between week 8 and week 16. In contrast, hamstring-associated exercises start slow and undergo an accelerated progression around week 16. Both muscle groups reach a comparable standard at 32 weeks. No obvious blunted progression could be seen during weeks 6–10 when the athlete suffered symptoms of exhaustion.

#### Goal 4: mental drive

With the impact of a sudden dramatic reduction in functionality in sport and work in comparison to the usual day-to-day activities of an elite athlete as well as further future uncertainties, focus on the mental state and energy levels was seen as imperative to achieve a successful rehabilitation. Emotional lability, low mood, irritability and sleep were closely monitored. Following discharge from the hospital, the patient underwent a reasonably strict daily structure, including getting up between 8:00 and 10:00 and upper body training programme. Although upper body training sessions are less relevant to the rehabilitation of the knee, it focusses on creating a sense of achievement rather than the limited functionality. Diet was deemed essential to maintaining high physical and mental energy levels, focussing on a high vitamin, mineral and protein intake. In addition, whole body cryotherapy was initially undertaken frequently when the mood and motivation was high. This intervention was then implemented during low mood and motivation episodes, acting as a conditioned reset to uphold and continue the high-intensity, high-frequency regimen.

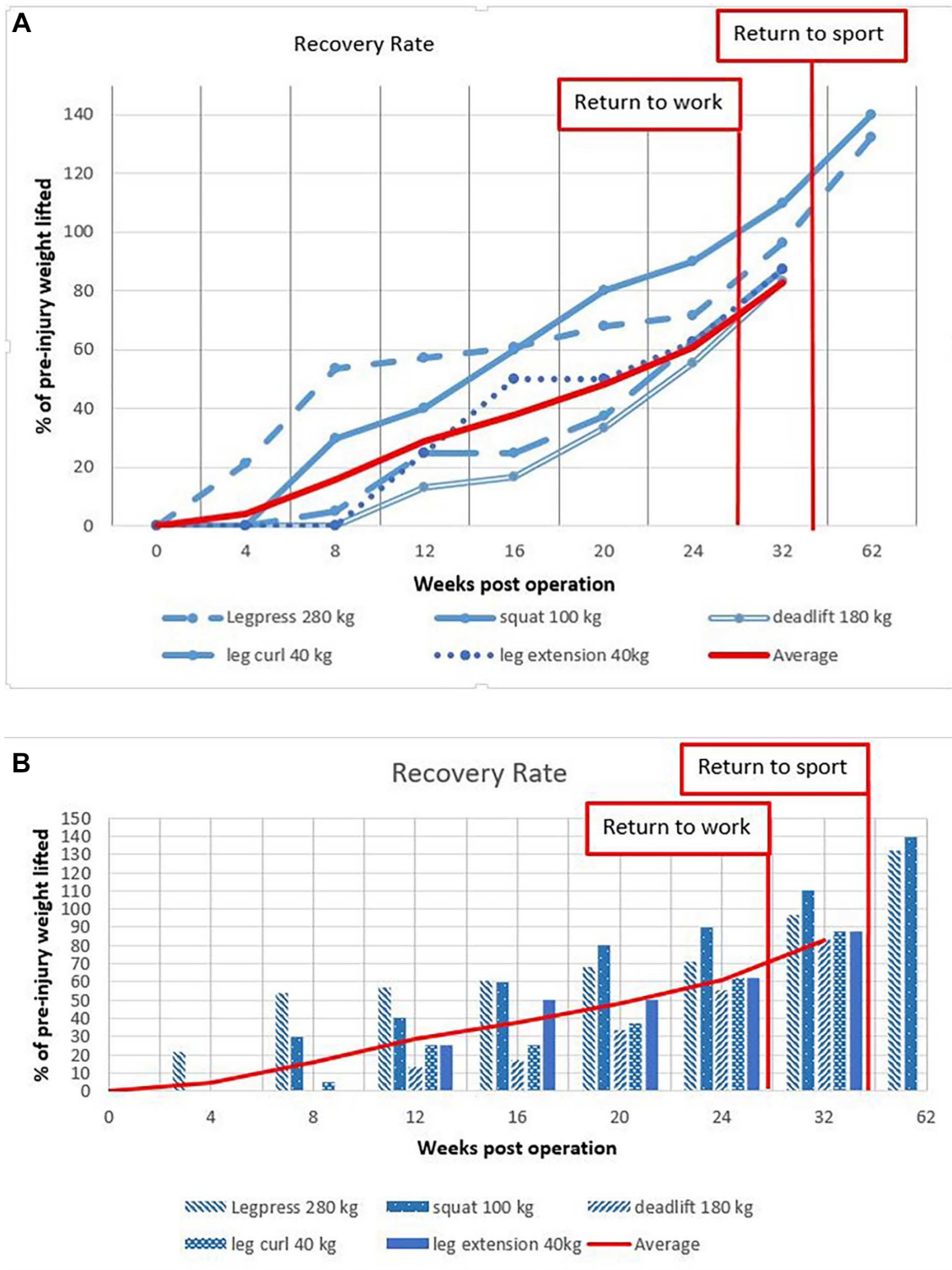
Several periods, either due to lack of sleep, over-reaching, reduced focus on dietary intake or a combination of the aforementioned, were considered mentally challenging and required considerable discipline. During these periods, the patient would suffer from physical and mental exhaustion, chronic nausea, emotional lability, irritability and a depressed mood. Whole-body cryotherapy was considered effective to reset the discipline, followed by extra attention to interventions facilitating recovery,<sup>26 35</sup> such as sport massages and diet. Furthermore, the support, attitude and involvement of partner, family, friends and medical staff played a considerable role in upholding discipline and motivation as well as training intensity and frequency.

## OUTCOME AND FOLLOW-UP

### Reintegration phase

Just over 5 months following the operation, the patient returned to work as a medical intern doing generally non-sedentary full-time rotations, including full days standing in the operation theatre. Rehabilitation was downscaled significantly to three full body sessions a week. By week 27, the patient seemed to have reacted well to the intramuscular NMES as the peroneal orthosis was no longer necessary. Although a minimal drop-foot was still evident, especially following a day of work or exercise, it was barely obvious by week 32. Sensation had recovered to half-way down the lower leg, predominantly on the lateral side.

Furthermore, the patient proceeded to undertake more dynamic exercises such as rope skipping and speed-agility-quick-ness ladder drills. In the 35th week, the patient managed to start running. This was followed by a game of touch (non-contact)



**Figure 4** Illustrate, in two different variations, the progress per exercise over the weeks with the operation taking place at week 0. The vertical axis is the percentage of the weight the patient was capable of lifting preinjury. The red function shows the average progress of all the exercises throughout the rehabilitation. The exercises presented in the legend show the amount of kilograms the patient was capable of pushing preinjury. Week 22.5 is marked as return to work. Furthermore, the 'Average of all exercises' graph shows an accelerated progression between 4–12 and 24–32 weeks.

rugby, including sudden rapid directional changes and short ranged accelerations. At 10 months postsurgery, the patient was considered to have 'returned to preinjury level of sports without contact' when a jog of 5 km was achieved, without the peroneal orthosis, with little hydrops or pain the following day. By week 39, normal sensation had expanded to the ankle on the lateral

side and just above the ankle on the anterior side. The lower anterior part of the lower leg exhibited altered but an intact sensation. The dorsum of the foot was no longer numb, yet far from normal sensation. By 15 months, our patient managed to perform a 370kg leg press and a 140kg free squat, meaning he had achieved 132% and 140%, respectively, of his preinjury

maximum. Furthermore, the patient could perform a TRX-stabilised unilateral leg squat followed by an explosive jump and 90-degree landing, something the patient was not capable of preinjury. This demonstrates the level of proprioceptive skills, strength and explosiveness acquired throughout the rehabilitation as well as the ability to take repetitive stress on the knee. Moreover, our patient had reached a similar physique as before the injury, weighing 117 kg.

## DISCUSSION

Despite the poor prognosis due to the serious associated injuries, including the peroneal palsy, PLC injury and avulsion fractures of the biceps femoris and the semimembranosus, a successful return to work and 'return to preinjury level of sports without contact' was achieved. Progress was achieved markedly faster than any other described cases of complex posterolateral knee injuries as far as the authors are aware. Ridley *et al* describes the earliest recovery from complete peroneal paralysis at 14 months.<sup>12</sup> Furthermore, the extent of muscular damage, such as additional hamstring avulsion fractures, inhibiting return to preinjury level of knee function is not taken in to account. In this case report, physical activities were assessed by performance-based tests instead of using patient-reported outcome measures as was done by Ridley *et al*.<sup>12</sup> Therefore, this case report is more comparable to the case described by Oshima *et al* but with a much faster actual return to sports: 10 versus 27 months.<sup>17</sup> However, it must be mentioned that at 27 months, the athlete described by Oshima *et al* return to competitive sport, as opposed to our athlete who returned to preinjury level of sports without contact. The following factors probably contributed to the described result, grouped according to the International Classification of Functioning model.<sup>36</sup>

Multiple clinical interventions were performed, some of them are non-evidence based and were initiated by the athlete himself. To be as transparent as possible, we also reported these non-evidence-based interventions without suggesting that these contributed to the positive outcome and therefore should be followed-up in future similar cases. First, an ACL reconstruction using a BTB allograft and a figure-of-8 PLC repair using an Achilles allograft were performed. Second, the patient underwent a rigorous training regimen. Numerous interventions were used to facilitate recovery throughout the rehabilitation, focusing on increase in ROM and pain reduction.<sup>26</sup> These were targeted by way of lymph-drainage massage, sports massage, dry needling, low-intensity training sessions and TENS.<sup>29 30</sup> In addition, protein diet and supplements like whey isolate, magnesium, zinc as well as omega-3 were taken. However, only protein supplementation has minor literary support.<sup>22</sup> Muscle tenderness was treated with pain medication, sport massages and whole body cryotherapy, yet dry needling remains unsurpassed.<sup>26 27 29 30</sup> NMES was performed to enhance muscle growth throughout the intense regimen but also to continue to stimulate the paralysed muscles, reducing atrophy.<sup>21 31-33</sup> Our patient considered the whey isolate supplementation, whole body cryotherapy, dry needling and NMES to be the most enhancing and facilitating interventions throughout the rehabilitation.

With regard to personal factors, our patient was a medical student functioning as an elite athlete, used to training six to eight times a week on top of matches in addition to his medical rotations. The rapid progression is also attributed to the state of fitness preinjury as well as the state of fitness preoperation. Not only was our patient motivated to beat the odds, he was used to a high-frequency training regimen and the important

role diet plays. Furthermore, he already had experience from many previous injuries for which he had undergone rehabilitation. The patient anticipated the training regimen to be mentally and physically challenging, including hard work and confrontational setbacks. He was pushed intrinsically even harder by the poor prognosis and the prospect of not fully recovering. The biggest motivation being that whatever the outcome, he could resign himself to it, as long as he had done everything possible.

Extrinsic factors upholding the patient's motivation are also attributed to a large contingency of family and friends as well as a professional, motivated and much involved medical staff committed to the road to recovery. The attitude, involvement and role of the medical staff as well as family and friends cannot be underestimated. In addition, the decision to go abroad during the 2 weeks of complete rest was seen as beneficial. It allowed the patient to physically recover and mentally recharge due to the completely different setting.

As a result, the patient managed to return to work as a medical intern at 5.5 months, doing full work weeks. The days included predominantly non-sedentary work with a lot of walking and standing. Return to sports without contact was achieved at 10 months, when he managed to do full-intensity non-contact rugby at preinjury level for 30–40 min and was able to jog 5 km. This is in contrast to the documented return to sport, if at all, taking up to several years. Furthermore, the achievement of 132% and 140% of the patient's preinjury leg press and squat weight, respectively, in addition to continuous unilateral single legged squat jumps, illustrates the strength, power and explosiveness acquired through rehabilitation. Our patient feels physically capable of returning to his own standard of rugby. Though mentally, due to fear of reinjury, another 6 months of receiving knocks would be needed to comfortably return. However, his retirement from rugby remains definite, as having fought back against the odds, it has allowed him to choose to retire rather than be forced to retire. Our patient feels proud he has been able to regain the ability to make that choice. In conclusion, our patient admits the rehabilitation was extremely heavy and on multiple occasions confrontational. However, with a return to work at 5.5 months and a return to preinjury level sports without contact at 10 months, this rapid road to recovery can be seen as successful showing that on this occasion a high-intensity, high-frequency regimen resulted in a successful outcome. Whether this is due to the implemented interventions, intrinsic motivation or extrinsic support from family, friends and medical staff, a considerably reduced convalescent period was achieved. Future implementation may not only be limited to elite athletes but also for weekend warriors and non-athletes.

## Patient's perspective

I found the rehabilitation extremely heavy and on multiple occasions confrontational. However, following the rehabilitation period, I felt physically capable of returning to my former standard of rugby. Mentally, mainly due to fear of reinjury, another 6 months of receiving knocks would be needed in order to comfortably return. However, my retirement from rugby remains definite, as having fought back against the odds, it has allowed me to choose to retire rather than be forced to retire. I feel proud to have been able to regain the ability to make that choice.

## Learning points

- ▶ Acute PLC injuries of the knee with associated hamstring avulsions and peroneal paralysis including nerve damage >7 cm have a poor prognosis regarding return to preinjury level sports and can take as long as 27 months if at all possible.
- ▶ A highly trained and motivated elite rugby player and medical student performing a goal-directed multifaceted high-frequency, high-intensity rehabilitation programme returned to work at 5 months after surgery and returned to preinjury level sports without contact at 10 months after surgery.
- ▶ The goals were aimed at pain reduction, increase in range of motion, increase and upkeep of overall leg strength and minimisation of atrophy as well as stimulation and support of mental drive.
- ▶ Multifaceted rehabilitation included evidence and non-evidence-based interventions—the latter initiated by the athlete himself—like stretching, manipulation and massage, neuromuscular electrical stimulation, training of the non-immobilised leg for cross-education of the immobilised leg, upper and lower body-weighted training, cycling, improvised cryotherapy, high-protein diet and active support from partner, family, friends and medical staff.
- ▶ Future studies should evaluate whether elements of this goal-directed multifaceted high-frequency, high-intensity rehabilitation programme are also applicable to and effective in more ordinary patients like weekend warriors and non-athletes.

**Acknowledgements** In memory of Terence Paget. The patient is pleased to acknowledge Keith Paget, Carmel Flood, Daphne Psaltaki, Jamie Rowell, Daan van Dongen, Yordi de Wit, Dirk Uittenbogaard, Elizabeth Flood in addition to the physiotherapists of Manual Fysion and fysio.com and the medical staff of the Radiology, Trauma and Orthopaedic department of the academic medical center—Amsterdam for their valuable contribution towards the successful rehabilitation.

**Contributors** The corresponding author, LDAP, is responsible for the acquisition of data and the drafting of the article. PK contributed to the drafting of the article. LDAP, PK, MM and GK all agreed on conception and design and contributed equally to analysis and interpretation of data and its critical revision for important intellectual content. GK is guarantor of the article. Final approval of the version for publication was agreed upon by all authors and are accountable for the article regarding its accuracy and integrity.

**Competing interests** None declared.

**Patient consent** Obtained.

**Provenance and peer review** Not commissioned; externally peer reviewed.

**Open Access** This is an Open Access article distributed in accordance with the Creative Commons Attribution Non Commercial (CC BY-NC 4.0) license, which permits others to distribute, remix, adapt, build upon this work non-commercially, and license their derivative works on different terms, provided the original work is properly cited and the use is non-commercial. See: <http://creativecommons.org/licenses/by-nc/4.0/>

© BMJ Publishing Group Ltd (unless otherwise stated in the text of the article) 2017. All rights reserved. No commercial use is permitted unless otherwise expressly granted.

## REFERENCES

- 1 Dallalana RJ, Brooks JH, Kemp SP, *et al.* The epidemiology of knee injuries in English professional rugby union. *Am J Sports Med* 2007;35:818–30.
- 2 Swenson DM, Collins CL, Best TM, *et al.* Epidemiology of knee injuries among U.S. high school athletes, 2005/2006–2010/2011. *Med Sci Sports Exerc* 2013;45:462–9.
- 3 Majewski M, Susanne H, Klaus S. Epidemiology of athletic knee injuries: a 10-year study. *Knee* 2006;13:184–8.
- 4 LaPrade RF, Ly TV, Wentorf FA, *et al.* The posterolateral attachments of the knee: a qualitative and quantitative morphologic analysis of the fibular collateral ligament, popliteus tendon, popliteofibular ligament, and lateral gastrocnemius tendon. *Am J Sports Med* 2003;31:854–60.
- 5 Gollehon DL, Torzilli PA, Warren RF. The role of the posterolateral and cruciate ligaments in the stability of the human knee. *J Bone Jt Surg* 1987;69:233–42.
- 6 Veltri DM, Deng XH, Torzilli PA, *et al.* The role of the popliteofibular ligament in stability of the human knee. *Am J Sports Med* 1995;24:19–27.
- 7 Veltri DM, Deng XH, Torzilli PA, *et al.* The role of the cruciate and posterolateral ligaments in stability of the knee. A biomechanical study. *Am J Sports Med* 1995;23:436–43.
- 8 Pasque C, Noyes FR, Gibbons M, *et al.* The role of the popliteofibular ligament and the tendon of popliteus in providing stability in the human knee. *J Bone Joint Surg Br* 2003;85:292–8.
- 9 LaPrade RF, Wentorf FA, Fritts H, *et al.* A prospective magnetic resonance imaging study of the incidence of posterolateral and multiple ligament injuries in acute knee injuries presenting with a hemarthrosis. *Arthroscopy* 2007;23:1341–7.
- 10 Niall DM, Nutton RW, Keating JF. Palsy of the common peroneal nerve after traumatic dislocation of the knee. *J Bone Joint Surg Br* 2005;87:664–7.
- 11 Shaw KA, Dunoski BS, Mardis NJ, *et al.* Combined posterolateral corner and acute anterior cruciate ligament injuries in an adolescent cohort: a magnetic resonance imaging analysis. *Int Orthop* 2016;40:555–60.
- 12 Ridley TJ, McCarthy MA, Bollier MJ, *et al.* The incidence and clinical outcomes of peroneal nerve injuries associated with posterolateral corner injuries of the knee. *Knee Surg Sport Traumatol Arthrosc* 2017. doi: 10.1007/s00167-016-4417-2 [Epub ahead of print 3 Feb 2017].
- 13 Bottomley N, Williams A, Birch R, *et al.* Displacement of the common peroneal nerve in posterolateral corner injuries of the knee. *J Bone Joint Surg Br* 2005;87:1225–6.
- 14 Rios A, Villa A, Fahandezh H, *et al.* Results after treatment of traumatic knee dislocations: a report of 26 cases. *J Trauma* 2003;55:489–94.
- 15 Lustig S, Leray E, Boisrenoult P, *et al.* Dislocation and bicruciate lesions of the knee: epidemiology and acute stage assessment in a prospective series. *Orthop Traumatol Surg Res* 2009;95:614–20.
- 16 van der Made AD, Reurink G, Gouttebauge V, *et al.* Outcome After Surgical Repair of Proximal Hamstring Avulsions. *Am J Sports Med* 2015;43:2841–51.
- 17 Oshima T, Nakase J, Numata H, *et al.* Common peroneal nerve palsy with multiple-ligament knee injury and distal avulsion of the biceps femoris tendon. *Case Rep Orthop* 2015;2015:1–6.
- 18 Fanelli GC, Stannard JP, Stuart MJ, *et al.* Management of complex knee ligament injuries. *J Bone Joint Surg Am* 2010;92:2235–46.
- 19 Crespo B, James EW, Metsavaht L, *et al.* Injuries to posterolateral corner of the knee: a comprehensive review from anatomy to surgical treatment. *Rev Bras Ortop* 2015;50:363–70.
- 20 Hendy AM, Lamson S. The cross-education phenomenon: brain and beyond. *Front Physiol* 2017;8:297.
- 21 Gordon T, English AW. Strategies to promote peripheral nerve regeneration: electrical stimulation and/or exercise. *Eur J Neurosci* 2016;43:336–50.
- 22 Hulmi JJ, Lockwood CM, Stout JR. Effect of protein/essential amino acids and resistance training on skeletal muscle hypertrophy: A case for whey protein. *Nutr Metab* 2010;7:51.
- 23 Fanelli GC, Larson RV. Practical management of posterolateral instability of the knee. *Arthroscopy* 2002;18:1–8.
- 24 Fanelli GC, Fanelli DG, Edson CJ, *et al.* Combined anterior cruciate ligament and posterolateral reconstruction of the knee using allograft tissue in chronic knee injuries. *J Knee Surg* 2014;27:353–8.
- 25 Fanelli GC, Edson CJ, Beck JD. How i treat the multiple-ligament injured knee. *Oper Tech Sports Med* 2010;18:198–210.
- 26 Gill ND, Beaven CM, Cook C. Effectiveness of post-match recovery strategies in rugby players. *Br J Sports Med* 2006;40:260–3.
- 27 White GE, Wells GD. Cold-water immersion and other forms of cryotherapy: physiological changes potentially affecting recovery from high-intensity exercise. *Extrem Physiol Med* 2013;2:26.
- 28 Halson SL. Sleep in elite athletes and nutritional interventions to enhance sleep. *Sports Med* 2014;44(Suppl 1):13–23.
- 29 Astokorki AH, Mauger AR. Transcutaneous electrical nerve stimulation reduces exercise-induced perceived pain and improves endurance exercise performance. *Eur J Appl Physiol* 2017;117:483–92.
- 30 Dunning J, Butts R, Mourad F, *et al.* Dry needling: a literature review with implications for clinical practice guidelines. *Phys Ther Rev* 2014;19:252–65.
- 31 Hasegawa S, Kobayashi M, Arai R, *et al.* Effect of early implementation of electrical muscle stimulation to prevent muscle atrophy and weakness in patients after anterior cruciate ligament reconstruction. *J Electromyogr Kinesiol* 2011;21:622–30.
- 32 Kim KM, Croy T, Hertel J, *et al.* Effects of neuromuscular electrical stimulation after anterior cruciate ligament reconstruction on quadriceps strength, function,

- and patient-oriented outcomes: a systematic review. *J Orthop Sports Phys Ther* 2010;40:383–91.
- 33 Imoto AM, Peccin S, Almeida GJ, *et al.* Effectiveness of electrical stimulation on rehabilitation after ligament and meniscal injuries: a systematic review. *Sao Paulo Med J* 2011;129:414–23.
- 34 Lorenz DS, Reiman MP, Walker JC. Periodization: current review and suggested implementation for athletic rehabilitation. *Sports Health* 2010;2:509–18.
- 35 Stacey DL, Gibala MJ, Martin Ginis KA, *et al.* Effects of recovery method after exercise on performance, immune changes, and psychological outcomes. *J Orthop Sports Phys Ther* 2010;40:656–65.
- 36 Slebus FG, Sluiter JK, Kuijjer PP, *et al.* Work-ability evaluation: a piece of cake or a hard nut to crack? *Disabil Rehabil* 2007;29:1295–300.
- 37 Panzica M, Janzik J, Bobrowitsch E, *et al.* Biomechanical comparison of two surgical techniques for press-fit reconstruction of the posterolateral complex of the knee. *Arch Orthop Trauma Surg* 2015;135:1579–88.

Copyright 2017 BMJ Publishing Group. All rights reserved. For permission to reuse any of this content visit <http://group.bmj.com/group/rights-licensing/permissions>.  
BMJ Case Report Fellows may re-use this article for personal use and teaching without any further permission.

Become a Fellow of BMJ Case Reports today and you can:

- ▶ Submit as many cases as you like
- ▶ Enjoy fast sympathetic peer review and rapid publication of accepted articles
- ▶ Access all the published articles
- ▶ Re-use any of the published material for personal use and teaching without further permission

For information on Institutional Fellowships contact [consortiasales@bmjgroup.com](mailto:consortiasales@bmjgroup.com)

Visit [casereports.bmj.com](http://casereports.bmj.com) for more articles like this and to become a Fellow