

Received: 2019.12.15

Accepted: 2020.02.11

Available online: 2020.02.21

Published: 2020.04.07

Aortoenteric Fistula through a Thrombosed Graft

Authors' Contribution:
 Study Design A
 Data Collection B
 Statistical Analysis C
 Data Interpretation D
 Manuscript Preparation E
 Literature Search F
 Funds Collection G

ABCDEF 1,2 **Mahdi Malekpour**
 AE 1 **Jeremy L. Irvan**
 BD 1 **Ammar Hashmi**
 BC 2 **Kenneth A. Widom**
 ABCDEF 1 **Evan J. Ryer**

1 Department of Endovascular and Vascular Surgery, Geisinger Medical Center, Danville, PA, U.S.A.

2 Department of Trauma and Emergency General Surgery, Geisinger Medical Center, Danville, PA, U.S.A.

Corresponding Author: Evan J. Ryer, e-mail: ejryer@geisinger.edu

Conflict of interest: None declared

Patient: Male, 75-year-old
Final Diagnosis: Aortoenteric fistula through a thrombosed graft
Symptoms: Hematochezia • melena
Medication: —
Clinical Procedure: Excision of the aortic graft, pyloric exclusion and loop gastrojejunostomy
Specialty: Surgery

Objective: Unusual clinical course

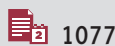Background: Aortoenteric fistula is a dreadful and uncommon complication after abdominal aortic aneurysm repair. Continuous friction against the intestine and the aortic graft along with local inflammation is thought to be the major cause of aortoenteric fistula formation, although it is unexpected to have fistula formation with a thrombosed aortic graft.

Case Report: Here, we report a case of an aortoenteric fistula between a thrombosed aortoiliac bypass graft and the duodenum in a 75-year-old male patient who presented with a 2-month history of melena. In this case, the aorto-duodenal fistula was repaired with excision of the aortic graft, proximal and distal oversewing of the aorta, omental flap coverage, pyloric exclusion and loop gastrojejunostomy creation.

Conclusions: An aortoenteric fistula can form through a thrombosed graft. Since this is not an expected route of fistula formation, there may be a delay in identification.

MeSH Keywords: Aortic Aneurysm, Abdominal • Fistula • Gastrointestinal Hemorrhage

Full-text PDF: <https://www.amjcaserep.com/abstract/index/idArt/922153>



1077



—



4



9



Background

Secondary aortoenteric fistula can develop after any aortic reconstruction via a connection between the repaired aorta and any part of the gastrointestinal tract. It can happen after both open and endovascular repair with an incidence rate of up to 4% [1,2]. Thrombotic occlusion of the aortic graft is a known complication that can necessitate an extra-anatomical bypass to establish distal perfusion [3,4]. It has not been previously reported, and one would not expect a fistula to form between a thrombosed graft and the gastrointestinal tract. In this case report, we describe an aortoenteric fistula in an elderly male through a thrombosed aorta-iliac bypass graft, his treatment, and his hospital course. The patient consented to publication of his case information.

Case Report

A 75-year-old male with a history of abdominal aortic aneurysm and right axillary-bifemoral bypass (for 10 years) after thrombosis of an aortoiliac bypass was transferred to our institution with hematochezia and a concern for aortoenteric fistula (Figure 1). His problem was initiated as persistent melena 2 months prior to his current admission. At that time, esophagogastroduodenoscopy (EGD) had shown bleeding and clots at the fourth segment of the duodenum (D4) for which a clip had been placed for what endoscopically appeared as a large Dieulafoy's lesion (Figure 2A, 2B). The patient symptoms persisted, and he underwent a second EGD 1 month later that identified a large clot on top of the previously placed Endoclip.

After transfer to our institution, the patient underwent a computed tomography scan with intravenous contrast which revealed contrast extravasation into the duodenum and effacement of the soft tissue between the thrombosed aortic graft and D4 (Figure 3A, 3B). With a presumed diagnosis of an aortoduodenal fistula, the patient underwent exploratory laparotomy with extensive lysis of adhesions secondary to his previous abdominal surgeries. The fourth portion of the duodenum was adherent to the old Dacron graft where the aortoenteric fistula was identified (Figure 4). The main body of the previous Dacron aortoiliac graft was excised down to bilateral iliac limbs with oversewing of native infra-renal aorta and distal iliac limbs. The previously placed Endoclip was identified at the site of fistula and the duodenotomy was repaired in 2 layers. We then performed pyloric exclusion and created a retrocolic loop gastrojejunostomy. An omental flap was performed to buttress the proximal aortic stump. The patient was successfully extubated and taken to the intensive care unit. After a prolonged hospital course, the patient was discharged in stable condition on postoperative day 24 following the index operation.

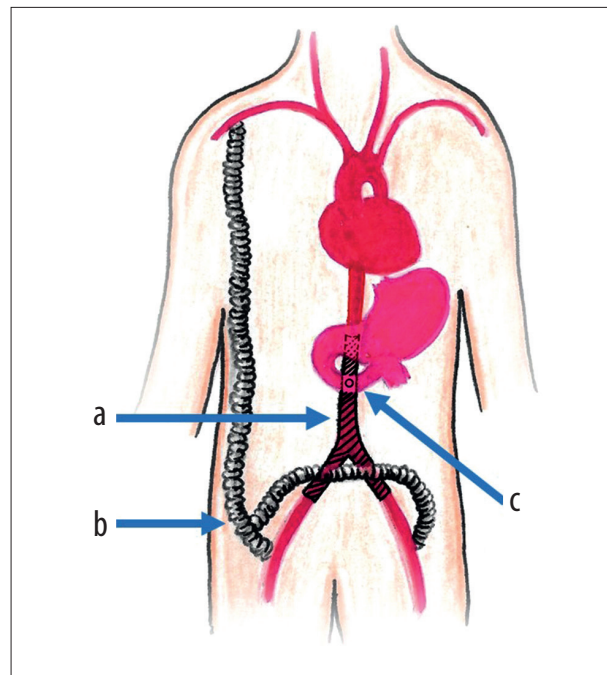


Figure 1. Schematic presentation of previous surgeries.
a) Aortoiliac bypass. b) Right axillary-bifemoral bypass.
c) Site of the aortoenteric fistula.

Discussion

Aortoenteric fistula is the deadliest complication after an abdominal aortic aneurysm repair with mortality rates reaching 50% even in most experienced hands and at high-volume centers [5]. Since a fistula through a thrombosed graft has not been previously described, any comparison would be limited to existing literature on aortoenteric fistula through a patent graft. Explantation of the graft and an extra-anatomical bypass has traditionally been the treatment of choice. Our patient had an existing right axillary-bifemoral bypass secondary to his thrombosed aortoiliac bypass graft and only required graft explantation and bowel repair. As this is solely a case report, discussion about the mechanism of fistula formation through the thrombosed graft would be speculative; though a likely explanation would be continued movement of the graft with each cardiac cycle which ultimately lead to fistula formation.

A study by Grande et al. conducted 28 autopsies on aortoenteric fistula patients and found that the majority of patients (23 patients) had died from exsanguination [6]. The majority of patients had a Dacron graft (12 out of 16 patients) and the majority of fistulas (94%) had developed near the proximal anastomosis with the duodenum being the most common enteric site of fistula development [6]. A later study following 42 patients found a mortality rate of 58% with the most common cause being blow out of the aortic stump [7]. Recurrence of the fistula was found in 16 out of 34 patients

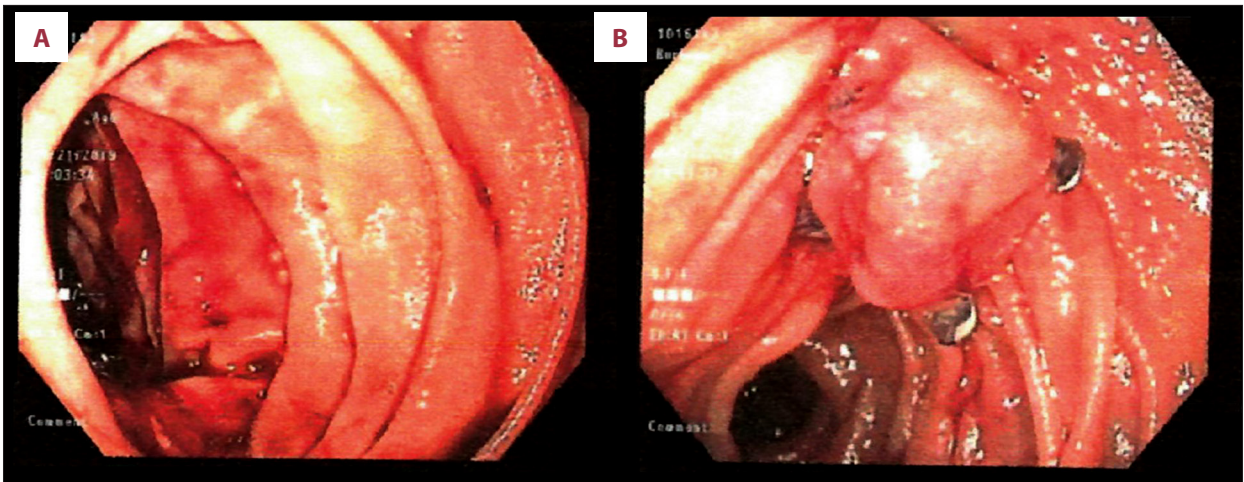


Figure 2. Esophagogastroduodenoscopy before presentation to our center. (A) Bleeding site at fourth segment of the duodenum; D4. (B) Application of a clip at the bleeding site.

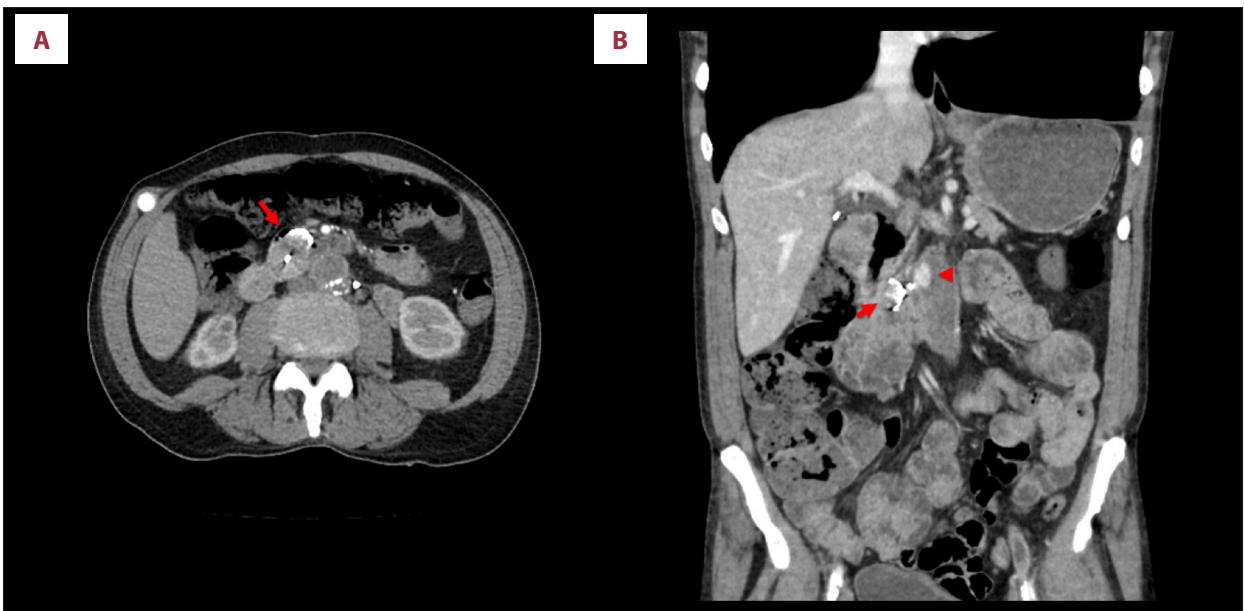


Figure 3. (A) Abdominal axial computed tomography (CT) scan with intravenous contrast demonstrating air and extravasated contrast in the duodenum (arrow). (B) Abdominal coronal CT scan with intravenous contrast in the duodenum (arrow) and in the thrombosed aortoiliac bypass graft (arrowhead). Note the loss of fat plane between the thrombosed graft and the adjacent duodenum.

who survived surgery, and at the 12-month follow-up, only 7 patients were still alive [7].

In the study by Batt et al. [5], 37 aortoenteric fistula patients were followed with a mean of 41 months follow-up. More than half of these patients had an acute presentation and more than 70% of patient had a form of hemorrhage. In this cohort, extra-anatomical reconstruction was performed only in 24% of the patients. They reported a 30-day mortality rate of 43% with age >75 years being the sole predictive factor of mortality [5]. Our patient met this age criteria for significantly

increased peri-operative mortality. They also reported the peri-operative complication rate of 59% and the mean hospitalization of 20 days, which was similar to our patient experience.

More favorable outcomes had been reported with endovascular repair in a study comparing endovascular versus open repair of the aortoenteric fistulas [8]. Kakkos et al. followed 25 patients with aortoenteric fistula among which 8 patients were treated with endovascular repair and 12 patients were treated with open repair [8]. Morbidity was significantly higher with open repair (77% versus 25%) with no mortality in the

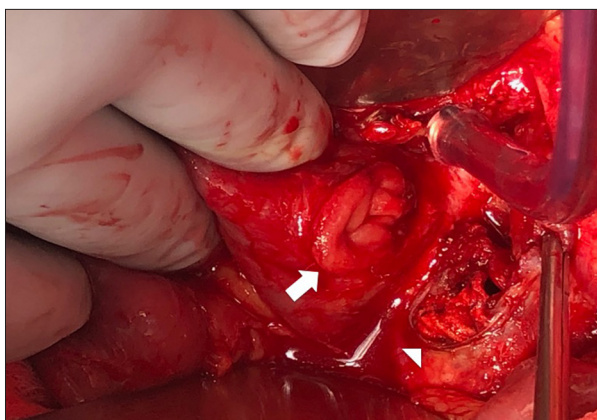


Figure 4. The aortoenteric fistula is opened with evident duodenotomy (arrow) and eroded thrombosed graft (arrowhead).

endovascular group. The early survival benefit in the endovascular group later faded away since the 2 groups were not different in the long-term survival at 2 years [8]. Kakkos et al. [8] found that the worse outcome was only associated with the number of symptoms at presentation. Apparently, our patient did not have an endovascular repair option.

In another study investigating the optimal method of enteric repair, significantly higher rates of fistula recurrence were

reported with simple repair as opposed to diversion or resection [9]. We repaired the duodenotomy in 2 layers and performed pyloric exclusion with retrocolic loop gastrojejunostomy. Our patient did not have any local recurrence at the site of the aortoenteric fistula through his course. The aforementioned study also found that omental interposition was associated with lower mortality independent from the repair technique [9]. We had interposed the omentum at the duodenotomy, gastrojejunostomy, and the proximal and distal oversewn ends of the resected graft.

Conclusions

An aortoenteric fistula can form through a thrombosed graft. Since this is not an expected route of fistula formation, there may be a delay in identification. Work-up and treatment modality would not be different from an aortoenteric fistula through a patent graft, and as in the presented case, it may still have significant morbidity and a prolonged hospitalization.

Acknowledgement

We wish to thank Samaneh Allahyari for her help in preparing the schematic presentation in Figure 1.

References:

1. Wilson WR, Bower TC, Creager MA et al: Vascular graft infections, mycotic aneurysms, and endovascular infections: A scientific statement from the American Heart Association. *Circulation*, 2016; 134(20): e412–60
2. Hallett JW, Marshall DM, Petterson TM et al: Graft-related complications after abdominal aortic aneurysm repair: Reassurance from a 36-year population-based experience. *J Vasc Surg*, 1997; 25(2): 277–84; discussion 285–86
3. Maleux G, Koolen M, Heye S, Nevelsteen A: Limb occlusion after endovascular repair of abdominal aortic aneurysms with supported endografts. *J Vasc Interv Radiol*, 2008; 19(10): 1409–12
4. Fairman RM, Baum RA, Carpenter JP et al: Limb interventions in patients undergoing treatment with an unsupported bifurcated aortic endograft system: A review of the Phase II EVT Trial. *J Vasc Surg*, 2002; 36(1): 118–26
5. Batt M, Jean-Baptiste E, O'Connor S et al: Early and late results of contemporary management of 37 secondary aortoenteric fistulae. *Eur J Vasc Endovasc Surg*, 2011; 41(6): 748–57
6. Grande JP, Ackermann DM, Edwards WD: Aortoenteric fistulas. A study of 28 autopsied cases spanning 25 years. *Arch Pathol Lab Med*, 1989; 113(11): 1271–75
7. Bergqvist D, Alm A, Claes G et al: Secondary aortoenteric fistulas – an analysis of 42 cases. *Eur J Vasc Surg*, 1987; 1(1): 11–18
8. Kakkos SK, Antoniadis PN, Klonaris CN et al: Open or endovascular repair of aortoenteric fistulas? A multicentre comparative study. *Eur J Vasc Endovasc Surg*, 2011; 41(5): 625–34
9. Rodrigues dos Santos C, Casaca R, Mendes de Almeida JC, Mendes-Pedro L: Enteric repair in aortoduodenal fistulas: A forgotten but often lethal player. *Ann Vasc Surg*, 2014; 28(3): 756–62