

## Outcome review on the percutaneous release of the proximal interphalangeal joint accessory collateral ligaments

Sonja Cerovac and John Stanley

Wrightington Hospital, Upper Limb Division, Wigan, UK

### Abstract

The percutaneous release of accessory collateral ligaments was introduced in 1986 as a safe and quick procedure to be attempted before open, more extensive joint release in the treatment of proximal interphalangeal joint flexion contracture. Our study analyzed the long-term results and patient satisfaction following a percutaneous release in 30 joints after a mean follow-up period of 34 months. In one half of cases the preoperative joint flexion deformity was reduced from 78° to 34°. The best results were observed in patients with osteoarthritis and stiff, immobilized joints. In patients with inflammatory arthritides, marked intraoperative correction was maintained rarely, joint contractures recurred early, and patients were unsatisfied. There were no intraoperative complications. Percutaneous release of the accessory collateral ligaments can produce a long lasting correction of the joint contracture, but careful patient selection and strict postoperative rehabilitation are essential for favorable outcome.

### Introduction

The flexion contracture of the proximal interphalangeal joint (PIPJ) is one of the most challenging problems in hand surgery. The precipitating conditions vary from trauma and adhesions to rheumatoid arthritis and Dupuytren's disease. Regardless of the primary cause, it is essentially a prolonged period of flexion imposed upon the PIPJ that almost invariably leads to the secondary capsuloligamentous contracture.<sup>1</sup> Pathological tissues contributing to such an entity are the volar plate with the "check rein" ligaments, the accessory collateral ligaments (ACL), the flexor tendon sheath, and intra-articular adhesions.<sup>2,3</sup>

The conventional treatment for chronic flexion contracture of PIPJ has been an open joint release. Joint distraction with an external fixator represents a less invasive alternative advocated by some authors,<sup>4,5</sup> which

avoids considerable tissue dissection and periarticular scarring associated with even the simplest form of open joint surgery.

In 1986, Stanley *et al.* described a quick and less aggressive approach to the treatment of PIPJ capsuloligamentous contracture.<sup>6</sup> The procedure consists of a percutaneous release of the ACL performed via two small incisions made on the dorsal aspect of the joint. In a selected group of patients, this minor procedure proved to be enough to allow manipulative correction of the joint, reducing the need for a radical, open procedure. However, since the descriptive publication of this technique and encouraging preliminary results based on a small pilot study, there has been no assessment of the long-term results of percutaneous release of PIPJ. Our study included not only the patients with post-traumatic and rheumatoid arthritis as before, but also those with psoriatic arthritis and PIPJ stiffness caused by prolonged immobilization for forearm fractures.

The aim of our study was to revisit benefits, longevity, and patient satisfaction with percutaneous arthrolysis of PIPJ in a larger and more diverse group of patients, after a longer follow-up period.

### Materials and Methods

The patient group was defined retrospectively by reviewing the Wrightington Hospital, Wigan, U.K. database on all patients undergoing percutaneous release of PIPJ-ACL over a period of 10 years (1997-2007). The patients included in the study have had a PIPJ capsuloligamentous flexion contracture of at least 30° that was not passively correctable, have failed to respond to further conservative measures, and have not undergone surgical release of the affected joint previously. Conservative treatment by means of a finger splint or serial casting and active and passive finger mobilization was started in all patients diagnosed with a contracture. This protocol was carried out as long as improvements could be recorded, and it continued for a minimum of three months from the last change. However, in the majority of patients, the response to the percutaneous release (favorable or otherwise) seemed to be apparent early, only a few weeks after the procedure. Ten people underwent PIPJ arthrolysis in more than one digit. In these patients, a similar outcome pattern (i.e., improvement or otherwise) was observed when either individual fingers or the patient as a whole were taken into consideration.

Following ethical approval granted by the Research Ethics Committee of the North West Strategic Health Authority in the United

Correspondence: Sonja Cerovac,  
17 Hendon Grove, Epsom, Surrey, KT19 7LH, UK.  
E-mail: scerovac@doctors.org.uk

Key words: proximal interphalangeal joint, arthrolysis, flexion contracture, percutaneous release.

Contributions: JS is responsible for conception and design of the study and he performed all patients' operations; SC obtained the ethical approval for the study, and compiled and interpreted the data. The authors contributed equally in critically reviewing and approving the final version of the manuscript.

Conflict of interest: the authors reported no potential conflicts of interests.

Ethical Committee approval for the study was obtained on 2 October 2007 by North Manchester Research Ethics Committee (REC reference number: 7/H1006/82).

This paper includes previously published material and permission to publish it was obtained from Elsevier Limited on 26 February 2008 (licence number 1896670880188).

Received for publication: 28 June 2009.

Revision received: 17 August 2009.

Accepted for publication: 17 August 2009.

This work is licensed under a Creative Commons Attribution 3.0 License (by-nc 3.0)

©Copyright S. Cerovac *et al.*, 2009

Licensee PAGEPress, Italy

Orthopedic Reviews 2009; 1:e19

doi:10.4081/or.2009.e19

Kingdom, the candidates were invited to take part in this project by attending the Outpatients department to be examined for the purposes of our study.

Each finger was assessed clinically by comparing the preoperative and postoperative angles of PIPJ flexion contracture and the total arcs of motion. Radiographs were obtained preoperatively only and were not used intraoperatively or postoperatively in the assessment of finger function. The evidence on preoperative and intraoperative positions and functions of the joint was collected from the patients' medical records. The postoperative angle and active range of motion were recorded during the clinical assessment. The objective was to establish the benefits and longevity of this procedure and to confirm that improved joint position and range of motion have been maintained over the follow-up period. Participants' demographics, distribution of PIPJ contracture in the hand, and the severity of the preoperative contracture are shown in Table 1.

There were four main causes of PIPJ stiffness in this cohort: rheumatoid arthritis (11 digits), psoriatic arthritis, (6) osteoarthritis,

(6) and stiffness following prolonged immobilization (7). In the latter group, the prolonged hand immobilization was required following fractures of the elbow, distal forearm and wrist, but not of the finger itself.

Patients' satisfaction with the outcome of percutaneous release was marked on a 0-10 point scale with 0 signifying the most dissatisfied and 10 the most satisfied. In addition, participants were asked whether they would undergo the same operation again. Except for two patients, the preoperative pain was not a prominent symptom and was therefore not measured formally. Most patients complained about awkwardness of the existing finger deformity and inconvenience in performing daily activities. The statistical significance of differences in outcome measures between various groups was assessed by using *p* values and Student-t test.

### Percutaneous joint release the surgical technique

The percutaneous release of PIPJ was described originally by Stanley *et al.*<sup>6</sup> The procedure is performed under local anesthesia using a Beaver blade which has sharp edges on both sides of its tip (Beaver Mini-Blade™). Incisions are made on the dorsum of the finger, at a point just lateral to the head of the proximal phalanx. Attention should be paid so that the blade enters the space between the central and lateral slip of the extensor tendon to avoid damage to them. The angle between the Beaver knife and the middle phalanx should be 90°, as shown in Figure 1.

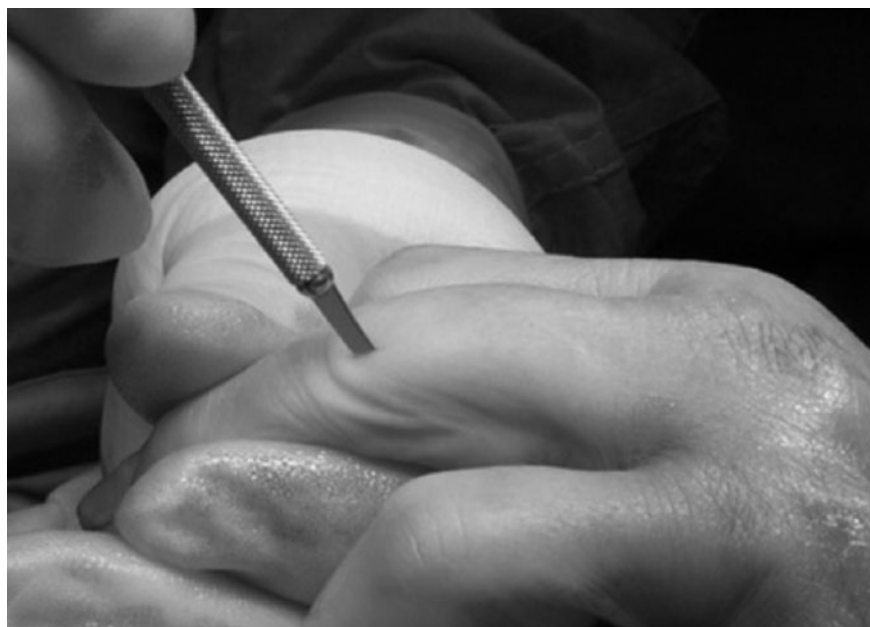When bone is reached, the blade is slipped over the edge of the phalangeal head so that it passes between the head and the collateral ligament (Figure 2). It is essential to stay strictly in the sagittal plane of the finger to protect the neurovascular bundles. Some resistance is felt as the blade penetrates the volar capsule and ACL. To divide the ACL along its entire length, the blade handle has to be swung in a proximal-distal direction as shown in Figure 3.

The procedure is repeated on the other (radial or ulnar) side of the phalanx. The correction of the flexion deformity is achieved finally by passive stretching of the joint. The force applied should be sufficient to break intra-articular adhesions and split the flexor tendon sheath, but not disrupt the volar plate. At the end of the procedure, the joint is checked for lateral stability, intactness of the true collateral ligaments, and integrity of the volar plate.

Postoperatively, the finger is dressed lightly and splinted in the position that supports extension, using either serial splinting or the joint jack. If there is a residual deformity, stretching of the joint is increased gradually over the next few weeks. Supervised active

**Table 1. Patient demographics and distribution, and severity of flexion contracture in affected digits.**

Number of patients	12
Males	3 (25%)
Females	9 (75%)
Age (range) (years)	59 (40-79)
Number of digits	30
Mean preoperative flexion deformity (°)	60
Index finger (n=3)	64
Middle finger (n= 10)	70
Ring finger (n= 8)	71
Little finger (n=9)	67
Mean preoperative active range of motion (°)	10



**Figure 1. Beaver knife is inserted through the dorsal skin just lateral to the head of the proximal phalanx. Care must be taken not to injure the lateral slip of the extensor tendon at this point. The starting position of the blade handle should be at 90° to the middle phalanx.**

and passive exercises are commenced on an outpatient basis on the second postoperative day and are continued three times per week. The objective is to achieve full correction of the flexion deformity, which can be maintained without splintage. In our study, such an outcome usually required three to four months of supervised physiotherapy. All percutaneous releases were performed by JS.

## Results

Of the 21 patients who underwent a percutaneous release of PIPJ-ACL at Wrightington Hospital over the last 10 years, 16 met the inclusion criteria and were invited to partici-

pate in the study. Twelve patients agreed to take part in the study (response rate: 75%), requiring release of 30 contracted joints. The average follow-up period for this cohort was 34 months (range 4-120 mo). This wide range for follow-up was partly because of inclusion of one patient who underwent percutaneous release only four months prior to completion of our study and in whom the flexion contracture recurred as early as six weeks after the procedure. Although his follow-up period was short, the clearly unfavorable clinical outcome was considered to be conclusive enough to justify inclusion of this patient in our study. No complications were encountered in this cohort. There were no infections and no evidence of intraoperative damage of the neurovascular bundles. None of the joints showed

**Table 2. Patient demographics and perioperative measurements.**

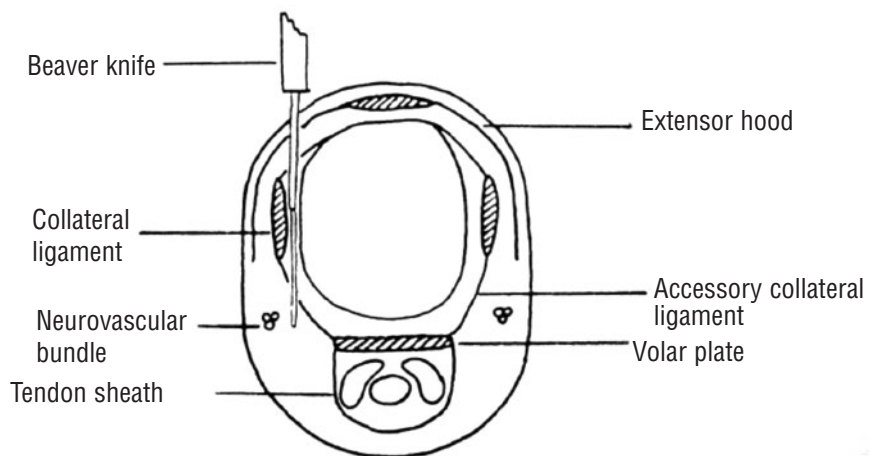
Patient ID	1			2			3			4			5			6			7			8			9			10			11			12		
Age (years)	69			62			65			51			75			41			59			79			40			58			79			62		
Sex	F			F			F			F			M			M			F			F			F			F			F			M		
Pathology	OA			OA			OA			Stiffness			Stiffness			Stiffness			PSA			PSA			PSA			RA			RA			RA		
Digit	M	M	R	L	R	L	M	R	L	M	R	L	M	I	M	M	L	R	L	I	M	R	L	I	M	R	L	M	R	L	I	M	R	L		
Preoperative joint contracture(°)	60	80	90	80	70	80	100	100	100	100	30	40	30	40	80	80	90	90	90	90	90	90	90	90	90	90	90	90	90	90	90	90				
Joint contracture at follow-up(°)	10	25	30	30	10	20	30	30	30	30	45	70	75	10	40	40	75	80	90	90	90	90	90	90	90	90	90	90	90	90	90					
Preop. AROM(°)	20	5	0	0	20	15	0	0	0	0	10	32	15	40	5	5	0	25	0	0	0	20	15	20	10	15	30	15	25	15	20	15				
Intraoperative PROM(°)	70	80	80	80	90	80	90	90	90	90	100	100	100	70	40	40	90	90	60	60	60	80	90	90	70	60	60	40	40	30	40	70				
AROM at follow-up(°)	55	50	55	55	70	70	30	25	20	10	10	15	90	25	25	20	0	0	0	0	10	0	5	0	10	20	0	25	20	20	10					
Follow-up (months)	10			25			120			18			7			59			8			13			8			56			92			4		
Level of satisfaction	8			10			9			7			3			8			2			1			1			2			1			2		
Would have surgery again (Yes/No)	Y			Y			Y			Y			N			Y			N			N			N			N			N			Y		

Demographics, and perioperative measurements for every patient and each finger are presented and grouped according to the underlying pathology for easier comparison. Less favorable outcome is apparent towards the right side of the table which represents patients with psoriatic and rheumatoid arthritis as primary pathology (preoperative values are in shaded rows). AROM: active range of motion; PROM: passive range of motion; OA: osteoarthritis; Stiffness: applies to postimmobilisation stiffness; PSA: psoriatic arthritis; RA: rheumatoid arthritis; M: middle finger; R: ring finger; L: little finger; I: index finger.

signs of postoperative instability.

Preoperatively, 10 patients presented with a fixed flexion deformity of PIPJ and two with minimal, less than 20° of total active range of motion. Finger radiographs were obtained preoperatively only. No radiological staging was done in our study. Most fingers were almost normal radiologically except for a few with rheumatoid arthritis in which slight loss of joint space was accepted. Fingers that showed signs of advanced disease (i.e., significant loss of bone substance, joint subluxations, and destruction leading to malrotation and axial deviation of the finger) and/or with deformities of the neighboring metacarpophalangeal (MCP) and distal interphalangeal (DIP) joints (i.e., Boutonniere and swan-neck deformity) were not considered appropriate for percutaneous arthrolysis. Advanced disease is unlikely to be helped by this minor procedure and altered periarticular anatomy in such cases exposes the neurovascular bundles and extensor apparatus to iatrogenic injury.

A percutaneous release of the ACL together with careful intraoperative stretching of the joint and the tendon sheath achieved immediate and marked improvement in all fingers. Full passive extension of PIPJ was obtained intraoperatively in 19 fingers (63%). In the remaining 11 fingers, although the joints could not have been straightened fully, the range of motion was improved by 51° and the deformity reduced by at least 60%. The change in the joint contracture following percutaneous release of PIPJ and in relation to the underlying pathology is presented in Table 2 and Figure 4. In general, the best outcome was



**Figure 2. Cross-section through the proximal interphalangeal joint to show position of Beaver blade. The cutting edges of the blade should not be deviated from the sagittal plane of the finger by twisting movements. The incising maneuver must be performed strictly in the sagittal plane. Reproduced with kind permission of Elsevier Limited from Stanley JK, Jones WA, Lynch MC. Percutaneous accessory collateral ligament release in the treatment of proximal interphalangeal joint flexion contracture. *J Hand Surg Br* 1986;11-B(3):360-3.**

observed in patients with osteoarthritis and stiff (immobilized) joints in contrast to patients with rheumatoid arthritis whose deformities often were accentuated. Therefore two distinct groups of patients were identified: one half with improved outcome, favorable and lasting results following percutaneous release, and the other half in whom this procedure was of no benefit (labeled as “unchanged” and “deteriorated” in Table 3).

In the group of patients with an improved

outcome overall, the best outcome by far was observed in four cases with no recurrence of the flexion deformity. In this group, preoperative deformity was reduced from 71.4° to 21°, the range of joint movement was improved by 44°, and such outcome preserved over time (54 months) (Table 3). On the other side of the spectrum were four patients with rheumatoid arthritis in whom the preoperative flexion contracture deteriorated from 51° to 74° following a percutaneous arthrolysis of PIPJ. Two



patients from this group, however, showed a poor compliance with the postoperative rehabilitation regime: one patient abandoned splintage earlier than advised, and another suffered additional medical problems and was prevented from attending the physiotherapy as frequently as necessary. There was no statistical difference in the mean age between patients with improved and worsened outcome (56 vs. 63 y;  $p>0.01$ ).

Level of satisfaction recorded for the whole group was 4.5 (0-10 point scale) (Table 2). As could be expected, patient satisfaction was dependent on the outcome and longevity of treatment. Overall, 50% of patients said that they would undergo the same procedure again, and principally these were the patients with a favorable long-term outcome, particularly those who did not have evidence of recurrence of flexion deformity. Their satisfaction score was 8.7 and they all would have the same procedure again. Understandably patients with recurrence were less happy, with an average satisfaction score of 2; hence they would not be willing to undergo a percutaneous joint release again.

## Discussion

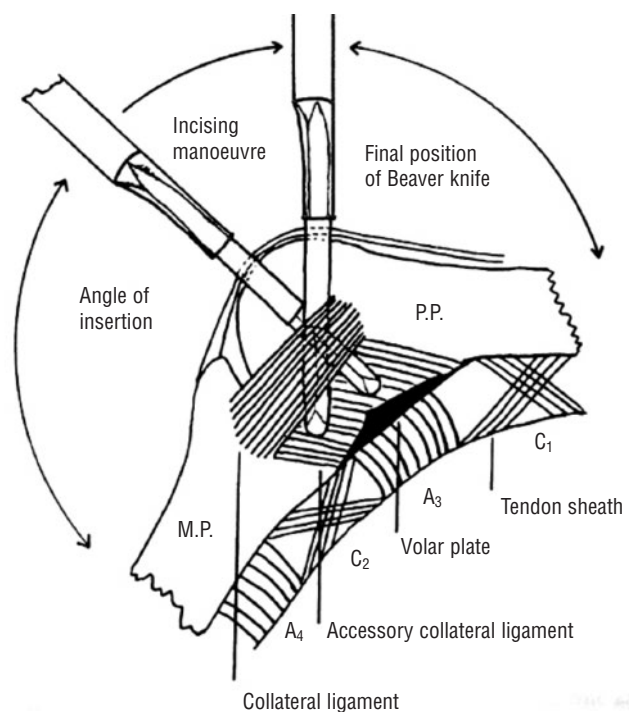
Surgical options for the treatment of chronically contracted PIPJ range from the release of the “check rein” ligaments alone to the radical excision of the volar plate, the “check rein”, and ACL. The gain in the joint arc of movement has been reported to be 12° after volar capsulectomy,<sup>7</sup> 18° following arthrolysis,<sup>8</sup> up to 37° after the sequential capsular release,<sup>9</sup> and up to 50° following a total excision of the collateral ligaments<sup>10</sup> or division of the proximal attachments of the volar plate and ACL.<sup>11</sup> Gradual dynamic extension and/or joint distraction with an external fixator has been reported to be an effective, less invasive alternative.<sup>4,12</sup> Naturally, the outcomes of these procedures vary with respect to the degree and longevity of the improvement. What seems to be common for all of them, however, is an innate risk of scarring and intracapsular adhesions triggered by surgical violation of the joint itself.

To limit the extent of surgery inflicted upon the PIPJ, Stanley *et al.* described a percutaneous release of ACL over two decades ago.<sup>6</sup> The idea arose in an attempt to improve a fixed joint deformity by a minor and quick procedure before embarking on an extensive, scar-prone open release. Results of their pilot study showed a full intraoperative correction of the flexion deformity in 87% of fingers, and revealed a high satisfaction rate among six patients. After a follow-up period of 10 months, the original flexion contracture

**Table 3. Comparison between proximal interphalangeal joint angle and active range of motion before and after percutaneous release of accessory collateral ligaments and in relation to recurrence of flexion contracture.**

Outcome	Recurrence	Number of patients (digits)	PIPJ angle (°) (range)		Range of motion (°) (range)		Follow-up (months)
			Before	After	Before	After	
Improved		7 (15)	78 (40-100)	33.6 (10-60)	16.5 (0-32)	38.6 (10-90)	40
	No	4 (7)	71.4	21	25	69.2	54
	Yes	2 (7)	81.4	70	<10	15.7	31
Unchanged	No	-	-	-	-	-	-
	Yes	2 (6)	73.6 (30-90)	70 (30-90)	<10	11.6	7
Deteriorated	No	-	-	-	-	-	-
	Yes	4 (10)*	51 (30-70)	74 (45-95)	18 (0-25)	11 (0-25)	38
Overall		13 (31)	68.4	55.3	10	23.7	34

\*Two patients expressed a poor compliance with the postoperative rehabilitation regime. PIPJ: proximal interphalangeal joint.



**Figure 3. Diagrammatic representation of the lateral aspect of the proximal interphalangeal joint and its capsuloligamentous structures. The position of the Beaver knife in relation to the true collateral ligaments and phalanx as well as the arc of motion required for the knife to release ACL completely are demonstrated. Reproduced with kind permission of Elsevier Limited from Stanley JK, Jones WA, Lynch MC. Percutaneous accessory collateral ligament release in the treatment of proximal interphalangeal joint flexion contracture. *J Hand Surg (Br)* 1986;11-B(3):360-3.**

remained corrected by 64% but in two thirds of fingers the flexion deformity recurred to 25°.

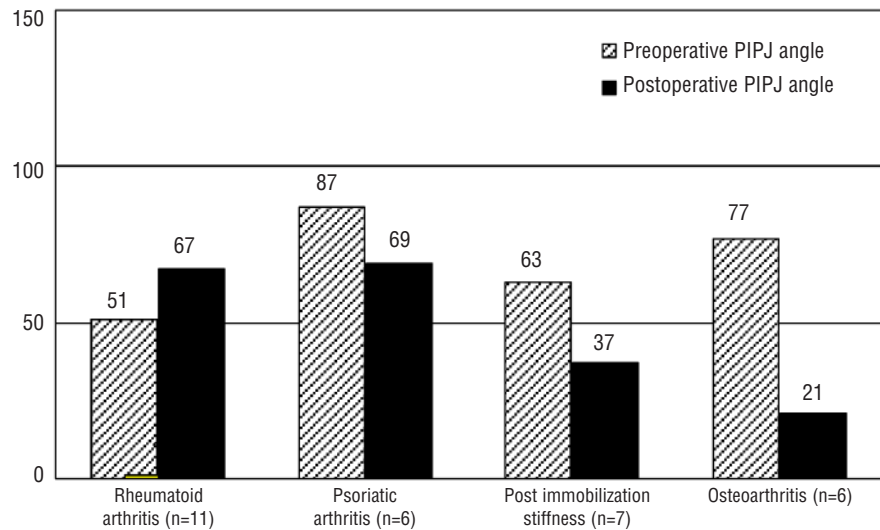
The results from our study, based on a longer follow-up period and more diverse preoperative pathology, were not as uniformly favorable. Patients with osteoarthritis and postimmobilization stiffness did better than those with inflammatory arthritides. In the former group (seven patients), a percuta-

neous release alleviated joint contracture by 57% and improved range of motion by 45°. A particularly significant improvement was observed in six fingers with osteoarthritis. There was no recurrence of the contracture in this group, PIPJ position remained improved by 70% (preoperative deformity of 71° decreased to 21°) and the range of motion improved almost three times after a follow-up

period of 54 months. The level of satisfaction in this group was 8.5. In the other half of the cohort suffering from rheumatoid and psoriatic arthritis (six patients), the outcome was not as favorable. The improvement in PIPJ position and function was short-lived only, superseded by the recurrence early and ultimately resulting in either unchanged or impaired finger function compared to the preoperative status. The level of satisfaction in this group was only 2, unsurprisingly. It could be that the inflammatory process associated with the rheumatoid and psoriatic arthritis promotes more vigorous scar (re)formation following even a limited surgical interference with affected joints. These conditions, unlike osteoarthritis and joint stiffness because of inactivity, involve multiple tissues, are not confined to the joint itself, and therefore are more likely to compromise a good long-term outcome.

Although PIPJ contracture can be caused by different anatomical structures, percutaneous release of ACL only is often sufficient to straighten the joint by manipulation because a contracture of ACL is considered to be one of the most important contributors to flexion deformity. During open arthrolysis, finger straightening usually is most notable following incision of a contracted ACL. By sequentially releasing various anatomical structures in cadaveric fingers with severely contracted PIPJ as a result of Dupuytren's disease, Andrew showed that the release of the ACL resulted in complete extension in the majority of fingers.<sup>13</sup> The incision of ACL relieves tension imposed upon the volar plate sufficiently to allow correction and breaking of intra-articular adhesions by passive stretching of the joint. In addition, cadaveric dissections confirmed that the ACL is the only structure that can be safely and consistently incised percutaneously.<sup>6</sup>

Analysis of preoperative variables likely to affect the outcome showed that neither age nor degree of preoperative PIPJ deformity was significantly different between the two groups. The distribution of patients with one or more affected digits was equal between the two groups. The compliance with postoperative immobilization and hand therapy was satisfactory, with the exception of two patients. The main difference between the two groups in outcome appears to be the underlying pathology. The recurrence of the contracture was high (67%), yet clinically detrimental only in patients with rheumatoid arthritis as their joint position deteriorated following the joint release. This recurrence is thought to have been caused by several factors: the intracapsular scarring triggered by surgery, residual tightness of periarticular structures, which could not be overcome by force of passive extension, and an often



**Figure 4.** This graph illustrates the differences in outcome in relation to the underlying (preoperative) pathology: in patients with the rheumatoid arthritis postoperative joint contracture worsened after the percutaneous release ( $p < 0.05$ ); the position of the joints affected by psoriatic arthritis was improved overall, but this was not statistically significant ( $p > 0.01$ ); a significant correction of the contracture was, however, noted in patients suffering from postimmobilisation stiffness and osteoarthritis ( $p < 0.01$ ).

incompetent extensor mechanism.<sup>13,14</sup> The loss of joint movement over time after the surgical procedure has been observed in other studies as well.<sup>9,14-16</sup> More sustainable improvement was reported following more radical releases: a total excision of the collateral ligaments,<sup>10</sup> and total excision of the volar plate and "check rein" ligaments in addition to incision of the ACL and flexor sheath.<sup>17</sup>

Although in 39% of fingers treated in our study the PIPJ could not be straightened completely by percutaneous arthrolysis, the joint contracture was markedly reduced and patients were pleased with the improved function of the finger. It should be noted that, even with only partial correction of the finger deformity, the overall function of the hand could be improved notably because a finger with residual PIPJ flexion deformity still permits full flexion and contributes more to the power grip than the straighter, stiffer PIPJ.<sup>18,20</sup> Therefore we believe that even a partial correction to less than 30° of the joint deformity achieved by this minor surgical procedure is worthwhile. We do not recommend the percutaneous release of PIPJ as an alternative to the conventional, open joint release, but as a minor procedure to be attempted in a selected group of patients before resorting to a more extensive, open approach. Patients in whom we expect the best outcome following a percutaneous release are those who have not had surgery to the affected finger before, with the capsuloligamentous disease limited to the PIPJ that is almost normal radiologically.

Often many of these patients are very frail and benefit from the short operative time. Percutaneous arthrolysis should be attempted only by an experienced hand surgeon (as was the case in our study) to reduce the risk of inappropriate manipulation of the joint, damage to the lateral slip or neurovascular bundle, incomplete release of ACL, etc. The risk of causing such iatrogenic injuries is much higher in fingers with postoperative adhesions, marked skeletal changes and malalignment, concomitant changes of MCP and DIP joints, etc., and in such patients this technique should not be attempted.

Our study has limitations because of the small number of cases and retrospective data collection based on those participants that are a risk for possible selection bias. However, our findings indicate that the percutaneous arthrolysis can be done safely and that it can straighten even the severely contracted finger effectively. In patients with noninflammatory joint changes where the pathology is limited to the joint itself; namely in patients with osteoarthritis and postimmobilization stiffness, this technique can provide a marked and sustainable improvement in the joint position and finger function.

On the contrary, the percutaneous arthrolysis does not appear to be a justified treatment option in patients with inflammatory arthritides; that is, rheumatoid and psoriatic arthritis, as finger improvement is temporary only and the risk of recurrent contracture appears to be high.

## References

1. Curtis RM. Capsulectomy of the interphalangeal joints of the fingers. *J Bone J Surg Am* 1954;36-A:1219-32.
2. Kaplan EB. *Functional and Surgical Anatomy of the Hand*. 2nd ed. Philadelphia and Montreal: JB Lippincott Company 1965,39-45.
3. Watson HK, Light TR, Johnson TR. Check-rein resection for flexion contracture of the middle joint. *J Hand Surg Am* 1979; 4:67-71.
4. Houshian S, Chikkamuniyappa C, Schroeder H. Gradual joint distraction of post-traumatic flexion contracture of the proximal interphalangeal joint by a mini-external fixator. *J Bone J Surg Br* 2007; 89:206-9.
5. Patel MR and Joshi BB. Distraction method for chronic dorsal fracture dislocation of the proximal interphalangeal joint. *Hand Clin* 1994;10:327-37.
6. Stanley JK, Jones WA, Lynch MC. Percutaneous accessory collateral ligament release in the treatment of proximal interphalangeal joint flexion contracture. *J Hand Surg Br* 1986;11:360-3.
7. Gould JS, Nicholson BG. Capsulectomy of the metacarpophalangeal and proximal interphalangeal joints. *J Hand Surg Am* 1979;4:482-6.
8. Mansat M, Delprat J. Contractures of the proximal interphalangeal joint. *Hand Clin* 1992;8:777-86.
9. Ghidella SD, Segalman KA, Murphey MS. Long term results of surgical management of proximal interphalangeal joint contracture. *J Hand Surg Am* 2002;27:799-805.
10. Diao E and Eaton RG. Total collateral ligament excision for contractures of the proximal interphalangeal joints. *J Hand Surg Am* 1993;18:395-402.
11. Brüser P, Poss T, Larkin G. Results of proximal interphalangeal joint release for flexion contractures: midlateral versus palmar incision. *J Hand Surg Am* 1999;24: 288-94.
12. Houshian S, Gynning B, Schroder HA. Chronic flexion contracture of proximal interphalangeal joint treated with the compass hinge external fixator. A consecutive series of 27 cases. *J Hand Surg Br* 2002;27:356-8.
13. Andrew JG. Contracture of the proximal interphalangeal joint in Dupuytren's disease. *J Hand Surg Br* 1991;16:446-8.
14. Weinzwieg N, Culver JE, Fleegler EJ. Severe contractures of the proximal interphalangeal joint in Dupuytren's disease: combined fasciectomy with capsuloligamentous release versus fasciectomy alone. *Plast Reconstr Surg* 1996;97:560-6, discussion 567.
15. Sprague BL. Proximal interphalangeal joint contractures and their treatment. *J Trauma* 1976;16:259-65.
16. Tonkin MA, Burke FD, Varian JPW. The proximal interphalangeal joint in Dupuytren's disease. *J Hand Surg Br* 1985;10:358-64.
17. Abbiati G, Delaria G, Saporiti E, et al. The treatment of chronic flexion contractures of the proximal interphalangeal joint. *J Hand Surg Br* 1995;20:385-9.
18. Draviraj KP, Chakrabarti I. Functional outcome after surgery for Dupuytren's contracture: a prospective study. *J Hand Surg Am* 2004;29:804-8.
19. Sinha R, Creswell TR, Mason R, et al. Functional benefit of Dupuytren's surgery. *J Hand Surg Br* 2002;27:378-81.
20. McFarlane RM, Botz JS. The results of treatment. In McFarlane RM, McGrouther DA, Flint MH (eds) *Dupuytren's disease*. Edinburgh: Churchill-Livingstone; 1990:393.