

Bertrand Lioger, MD
Nicole Ferreira-Maldent,
MD
Jean Philippe Cottier,
MD, PhD
S everine Debiais, MD
Emmanuel Gyan, MD,
PhD
Fran ois Maillot, MD,
PhD

*Neurol Neuroimmunol
Neuroinflamm*
2016;3:e253; doi: 10.1212/
NXL.0000000000000253

RITUXIMAB FOR SJ GREN SYNDROME- ASSOCIATED TYPE II MIXED CRYOGLOBULINEMIC CEREBRAL VASCULITIS

OPEN

Mixed cryoglobulinemia (MC) is caused by the precipitation of polyclonal immunoglobulin (Ig)M or IgG below 37°C. This condition is mainly associated with hepatitis C virus (HCV) but also with autoimmune diseases, such as Sj gren syndrome.¹ CNS involvement is usually described in MC associated with HCV infection² and in a recent study, only in 2% of 242 patients with noninfectious MC vasculitis.³ Treatment of the underlying disease, corticosteroids, and immunosuppressive drugs are essential for the management of cryoglobulinemic vasculitis. The use of rituximab, a monoclonal chimeric IgG1κ anti-CD20 antibody targeting B lymphocytes, seems promising both for the treatment of MC manifestations and cerebral vasculitis.⁴ Herein, we describe 2 cases of cerebral cryoglobulinemic vasculitis associated with Sj gren syndrome successfully treated with rituximab.

Case 1. A 64-year-old woman was admitted for persistent headache and asthenia. She had had hypertension, chronic seronegative arthritis, and an intraparotid mucosal-associated lymphoid tissue indolent lymphoma. She received methotrexate for her chronic rheumatism. MRI demonstrated multifocal subcortical/deep white matter hyperintensities and residual parenchymal hematoma in the right frontal lobe (figure 1A; figure e-1 at Neurology.org/nn). Magnetic resonance angiography showed segmental areas of arterial narrowing (figure 1B) of cortical branches of the left middle cerebral artery. Laboratory tests showed a negative HCV serology, hypogammaglobulinemia 3.2 g/L (N 8–14), hypocomplementemia C4 0.02 g/L (N 0.13–0.39), and the presence of anti-SSA antibodies 121 IU/mL (N <10), and a type II MC with a monoclonal IgGκ. CSF contained 25 cells/mm³ and 0.8 g/dL protein. Salivary gland biopsy showed chronic sialadenitis with a focus score at IV. Overall, these data strongly suggested cryoglobulinemic cerebral vasculitis secondary to Sj gren syndrome. Prednisone 1 mg/kg/d was initiated. Shortly afterward, the patient was admitted again for seizures, purpura, nephrotic syndrome, and renal failure

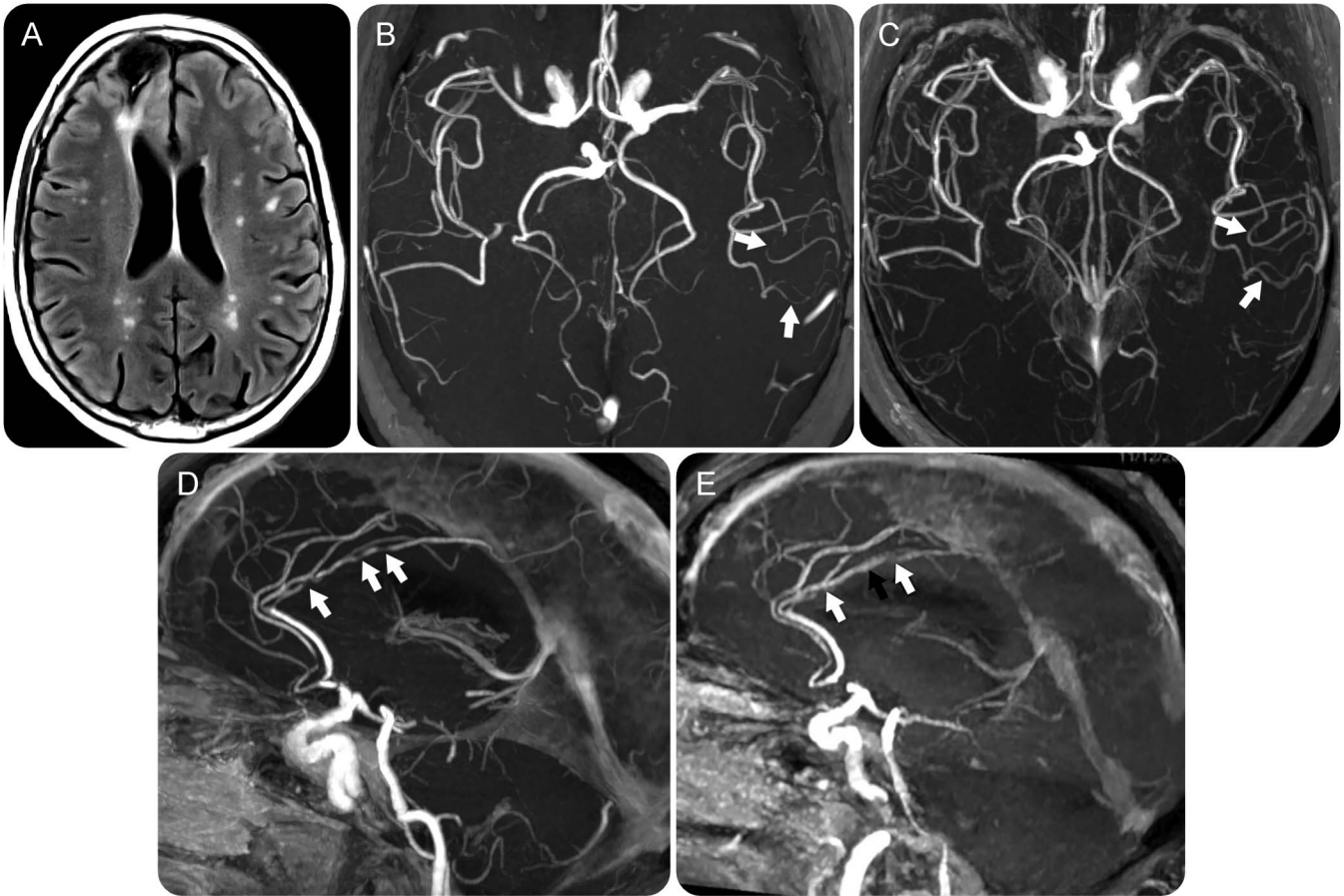
secondary to membranoproliferative glomerulonephritis type 1, as determined on renal biopsy. High-dose steroids and rituximab, 375 mg/m² once weekly for 4 weeks, were prescribed. Repeat brain MRI revealed improvement of arterial lesions (figure 1C) and the patient remained free of neurologic, cutaneous, and renal symptoms during the 48 months of follow-up.

Case 2. An 81-year-old woman was admitted for headaches and blurred vision. Her medical history was marked by a stroke associated with a patent foramen ovale and atrial septal aneurysm in 2009, and sensorimotor neuropathy and cutaneous vasculitis caused by MC secondary to Sj gren syndrome in 2012. Diagnosis of Sj gren syndrome was based on a sicca syndrome with xerostomia, dryness with a positive Schirmer tear test, anti-SSA antibodies, and a positive salivary gland biopsy. At admission, brain MRI revealed acute and subacute cerebral infarctions, micro-bleeding in the posterior territory, and multiple stenosis of cerebral arteries leading to the diagnosis of vasculitis (figure 1D). High-dose IV steroid therapy followed by oral prednisone was prescribed. Her condition worsened with dysarthria and purpura of the lower limbs. Her history of cryoglobulinemia and hypocomplementemia suggested an active disease; therefore, rituximab infusions were initiated after exclusion of hepatitis C. The patient rapidly improved and only mild dysarthria persisted after treatment. Subsequent MRIs showed no relapse and the patient remained free of steroid therapy at 16 months following rituximab therapy.

Discussion. Herein, we report a favorable outcome following rituximab therapy in 2 patients with presumed cerebral vasculitis secondary to MC associated with Sj gren syndrome. Vasculitis of the brain was not histologically proven in both cases. Therefore, diagnosis relied on their clinical history of cryoglobulinemia and the imaging of cerebral artery stenosis, both of which were reversible following rituximab infusion. Other causes of cerebral vasculitis, such as cerebral lymphoma or Sj gren-specific CNS involvement, were discussed but excluded in our patients.^{5,6}

Steroid therapy was ineffective and second line treatment was considered. In primary CNS vasculitis,

Supplemental data
at Neurology.org/nn



In case 1, axial T2-weighted image (A) demonstrates multifocal subcortical/deep white matter hyperintensities and residual parenchymal hematoma in the right frontal lobe, whereas MR angiography (B) shows segmental areas of arterial narrowing (arrows) of the cortical branches of the left middle cerebral artery. Three months after rituximab infusion, MR angiography (C) shows normalization of arterial calibre of the cortical branches of the left middle cerebral artery (arrows). In case 2, MR angiography (D) shows multifocal stenosis of the pericallosal artery (arrows). Three years after rituximab infusion, MR angiography (E) shows persistent stenosis (white arrows) and a mild dilatation of the previous narrow arterial segment (black arrow). MR = magnetic resonance.

cyclophosphamide is usually proposed based on limited evidence.⁵ Patients successfully treated with azathioprine, methotrexate, mycophenolate mofetil, and rituximab have been reported.⁵ Rituximab is becoming more frequently prescribed for both systemic vasculitis and MC vasculitis.^{4,7} In a French study, 84 patients with MC received rituximab plus corticosteroids leading to a complete clinical response in 64%, but none had cerebral MC.³ Therefore, we considered the use of rituximab after the consent of our patients. The condition of both patients rapidly improved and corticosteroid therapy was tapered. MRI also showed improvement of cerebral artery stenosis during follow-up. The treatment was safe regarding noninfectious or infectious adverse effects, despite prolonged hypogammaglobulinemia and B cell depletion.

In conclusion, rituximab as an add-on therapy may lead to remission and may spare side effects of corticosteroids in patients with MC cerebral vasculitis.

From the Service de Médecine Interne (B.L., N.F.-M., F.M.), Service de Radiologie Générale, Diagnostique et Thérapeutique Neuro-radiologie (J.P.C.), Service de Neurologie (S.D.), and Service d'Hématologie et Thérapie Cellulaire (E.G.), CHRU de Tours; CNRS UMR 7292 (B.L.), INSERM U 930 (J.P.C.), and INSERM U 1069 (F.M.), Université François Rabelais de Tours; and CIC INSERM U1415 (E.G.), Tours, France.

Author contributions: B.L., N.F.-M., S.D., E.G.: taking care of the patients. J.P.C.: acquisition of the images. B.L.: acquisition and interpretation of the data. B.L., F.M.: writing and editing of the manuscript. B.L., N.F.-M., J.P.C., S.D., E.G., F.M.: revising the manuscript.

Study funding: No targeted funding reported.

Disclosure: B. Lioger, N. Ferreira-Malden, J.P. Cottier, and S. Debais report no disclosures. E. Cijan served on the scientific advisory board for Amgen, Celgene, Fresenius Kabi, Sanofi, Teva Pharma; received gifts from Takeda, Chigai, received speaker honoraria from Gilead, Mundipharma, served on the speakers bureau for Gilead, received research support from Cancen, Force Hemato, Tours Auto-greffé. F. Maillot reports no disclosures. Go to Neurology.org/nm for full disclosure forms. The Article Processing Charge was paid by the authors.

This is an open access article distributed under the terms of the Creative Commons Attribution-NonCommercial-NoDerivatives License 4.0 (CC BY-NC-ND), which permits downloading and

sharing the work provided it is properly cited. The work cannot be changed in any way or used commercially.

Received January 8, 2016. Accepted in final form May 11, 2016.

Correspondence to Dr. Lioger: bertrand.lioger@univ-tours.fr

1. Ramos-Casals M, Stone JH, Cid MC, Bosch X. The cryoglobulinaemias. *Lancet* 2012;379:348–360.
2. Erro Aguirre ME, Ayuso Blanco T, Tuñón Alvarez T, Herrera Isasi M. Brain hemorrhage as a complication of chronic hepatitis C virus-related vasculitis. *J Neurol* 2008;255:944–945.
3. Terrier B, Krastinova E, Marie I, et al. Management of non-infectious mixed cryoglobulinemia vasculitis: data from 242 cases included in the CryoVas survey. *Blood* 2012;119:5996–6004.
4. Terrier B, Launay D, Kaplanski G, et al. Safety and efficacy of rituximab in nonviral cryoglobulinemia vasculitis: data from the French Autoimmunity and Rituximab Registry. *Arthritis Care Res* 2010;62:1787–1795.
5. Salvarani C, Brown RD, Hunder GG. Adult primary central nervous system vasculitis. *Lancet* 2012;380:767–777.
6. Morreale M, Marchione P, Giacomini P, et al. Neurological involvement in primary Sjögren syndrome: a focus on central nervous system. *PLoS One* 2014;9:e84605.
7. Guillevin L, Pagnoux C, Karras A, et al. Rituximab versus azathioprine for maintenance in ANCA-associated vasculitis. *N Engl J Med* 2014;371:1771–1780.