

Available online at [www.sciencedirect.com](http://www.sciencedirect.com)

ScienceDirect

journal homepage: [www.elsevier.com/locate/radcr](http://www.elsevier.com/locate/radcr)

## Case Report

# CT findings of Meckel's diverticulum perforation in a geriatric patient ☆,☆☆

Grace Yi, DO\*, Kiran Chavda, DO, Melvin Omodon, MD

Regional Medical Center Bayonet Point, 14000 Fivay Road, Hudson, FL 34667, USA

### ARTICLE INFO

#### Article history:

Received 16 January 2020

Revised 17 February 2020

Accepted 20 February 2020

#### Keywords:

Meckel's diverticulum

Small bowel

Perforation

Geriatric

Computed tomography (CT)

### ABSTRACT

Meckel's diverticulum is a remnant of the omphalomesenteric duct, found only in approximately 2% of the population. Although Meckel's diverticulum is often diagnosed in non-symptomatic patients as incidental radiologic findings, complications of Meckel's diverticulum can also be seen on radiologic evaluation. We present a rare case of perforated Meckel's diverticulum in a geriatric patient demonstrated on contrast computed tomography. This was later confirmed during laparoscopic surgery with pathologic evaluation.

© 2020 The Authors. Published by Elsevier Inc. on behalf of University of Washington.

This is an open access article under the CC BY-NC-ND license.

(<http://creativecommons.org/licenses/by-nc-nd/4.0/>)

## Introduction

Meckel's diverticulum is a congenital malformation often containing ectopic mucosa that is present in 2% of the population, less commonly found in adults. It is more often found in children less than 2 years of age [1]. Meckel's diverticula is found commonly within 100 cm of the ileocecal valve and is typically 50.8 cm in length [1]. Complications include but are not limited to perforation, diverticulitis, intestinal obstruction, hemorrhage, and neoplasm. However, due to the low lifetime complication rate of 4% [1], many times the finding is incidental in asymptomatic patients [2]. These complications should

be considered in patients with computed tomography studies with inflammatory change surrounding a location characteristic of Meckel's diverticulum.

## Case report

A 71-year-old female with no significant medical history, and surgical history of cholecystectomy and caesarean section, presented to the Emergency Department with progressive abdominal pain located in the left lower quadrant for 1 day. Pain was described as sharp with radiation to the back. Despite pa-

☆ **Consent:** The patient provided informed consent.

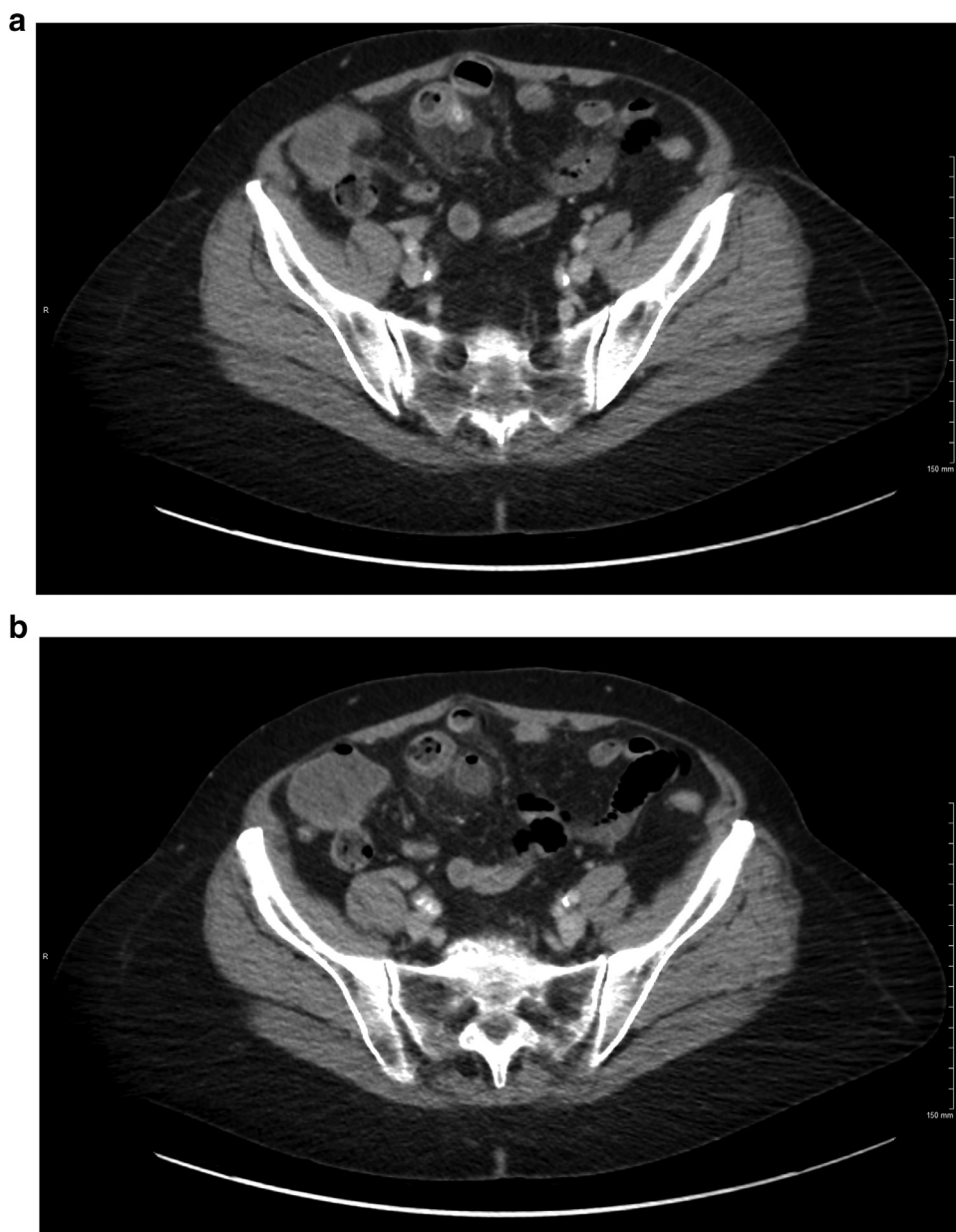
☆☆ **Disclaimer:** This research was supported in part by HCA Healthcare and/or an HCA Healthcare affiliated entity. The views expressed in this publication represent those of the author(s) and do not necessarily represent the official views of HCA Healthcare or any of its affiliated entities.

\* Corresponding author.

E-mail address: [Grace.Yi@HCAhealthcare.com](mailto:Grace.Yi@HCAhealthcare.com) (G. Yi).

<https://doi.org/10.1016/j.radcr.2020.02.016>

1930-0433/© 2020 The Authors. Published by Elsevier Inc. on behalf of University of Washington. This is an open access article under the CC BY-NC-ND license. (<http://creativecommons.org/licenses/by-nc-nd/4.0/>)



**Fig. 1 – Preoperative transverse CT scan of abdomen and pelvis. Inflammatory changes surrounding Meckel’s diverticulum is seen.**

patient’s painful presentation, vital signs were within normal range. Examination of the abdomen showed soft abdomen with no guarding, hernia, or masses; however, it was tender to palpation diffusely.

Laboratory results were significant for leukocytosis with neutrophil predominance, as well as mildly elevated direct bilirubin of 0.23 mg/dL.

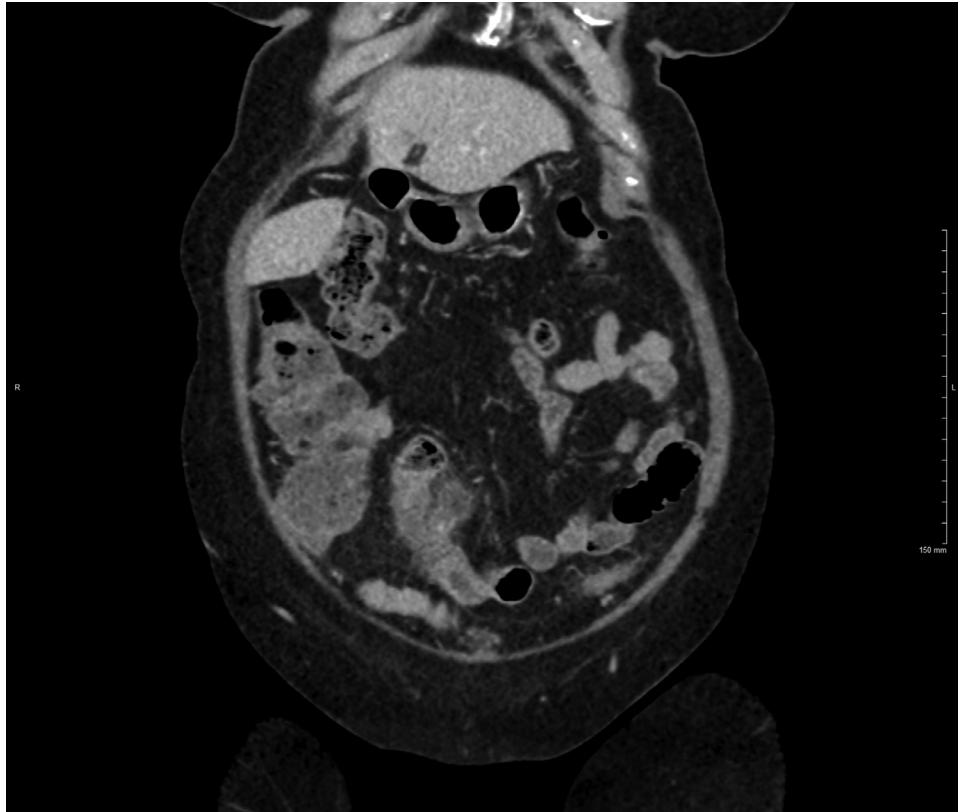
Computed tomography (CT) abdomen and pelvis with intravenous contrast revealed an approximately 2 cm diverticulum arising from the ileum with surrounding fat infiltration and mucosal thickening of the ileum, suggestive of Meckel’s diverticulum (Fig. 1).

A robotic-assisted laparoscopic small bowel resection was performed. Laparoscopy revealed inflammation approxi-

mately 2 ft from the ileocecal valve with contained perforation walled off by another segment of small bowel. Histopathology of the diverticulum showed perforated Meckel’s diverticulum with abscess formation and serositis, without neoplastic changes (Fig. 2).

## Discussion

Meckel’s diverticulum is the most common gastrointestinal congenital small bowel abnormality secondary to incomplete involution of the omphalomesenteric duct during the gestational period [3]. Meckel’s diverticulum is more likely to



**Fig. 2 – Preoperative coronal CT scan of abdomen pelvis. Meckel's diverticulum arising from the thickened wall from the ileum is seen.**

be found in males. Meckel's diverticulum can often contain ectopic mucosa, most frequently from gastric mucosa [6].

Meckel's diverticulum can be seen on various imaging modalities including barium studies, ultrasonography, computed tomography, and scintigraphy. Often times, Meckel's diverticulum is an incidental finding in asymptomatic patients; however, complications can be seen preoperatively during CT. In a study involving 202 patients, the lifetime risk of developing complications from Meckel's diverticulum in patients younger than 20 was 4%, patients younger than 40 was 2%, and in the elderly was 0% [4]. Patients with complications of Meckel's diverticulum present with acute right lower quadrant abdominal pain, similarly to the presentation of patients with appendicitis [5]. One of the most common preoperative diagnoses of complication of Meckel's diverticulum is appendicitis [9].

CT has a lower sensitivity for the diagnosis of Meckel's diverticulum when there are with no complications. The findings include a diverticulum arising from the ileum measuring 2 cm with fat infiltration and thickening of the ileal mucosa. Laparoscopic findings may reveal a perforation or torsion of the diverticulum. Causes of Meckel's diverticulum perforation include diverticulitis, ulceration, increased pressure from foreign body, trauma, or could be spontaneous [7,8]. In our patient, the most likely cause of her abdominal pain was due to spontaneous perforation.

Despite the deviation of typical epidemiologic factors and presentation of patient's with complications of Meckel's diverticulum, CT abdomen played a significant diagnostic role in our patient. Feller et al reported 2 out of 7 radiographic studies of symptomatic patients age 65 or more were suggestive Meckel's diverticulum [9]. According to the authors, this may have been due to a combination of insensitivity of radiologic scans and clinician's lack of understanding that Meckel's diverticulum complication can occur at any age [9]. In another study by Parvanescu et al, CT scans were able to diagnose complicated Meckel's diverticulum in 24% of study participants (9 of 37 cases) [10]. Therefore, it is important to raise awareness that complications of Meckel's diverticulum should be considered in elderly patients with nonspecific symptoms at presentation.

In conclusion, Meckel's diverticulum and its complications, although uncommon in adults, should be considered in those who present with progressive abdominal pain when coupled with inflammatory changes arising from the ileum as revealed by CT.

### Supplementary materials

Supplementary material associated with this article can be found, in the online version, at [doi:10.1016/j.radcr.2020.02.016](https://doi.org/10.1016/j.radcr.2020.02.016).

## REFERENCES

- 
- [1] Dumper J, Mackenzie S, Mitchell P, Sutherland F, Quan ML, Mew D. Complications of Meckel's diverticula in adults. *Can J Surg* 2006;49(5):353–7.
- [2] Kotha VK, Khandelwal A, Saboo SS, Shanbhogue AK, Virmani V, Marginean EC, et al. Radiologist's perspective for the Meckel's diverticulum and its complications. *Br J Radiol* 2014;87(1037):20130743. doi:10.1259/bjr.20130743.
- [3] Dames E, Hamouda E. Radiologic imaging in Meckel's diverticulum complications. *J Med Ultrasound* 2015;23:133–41.
- [4] Soltero MJ, Bill AH. The natural history of Meckel's diverticulum and its relation to incidental removal: a study of 202 cases of diseased Meckel's diverticulum found in King County, Washington, over a fifteen year period. *Am J Surg* 1976;132(2):168–73.
- [5] Levy AD, Hobbs CM. From the archives of the AFIP. *RadioGraphics* 2004;24(2):565–87. doi:10.1148/rg.242035187.
- [6] Elsayes KM, Menias CO, Harvin HJ, Francis IR. Imaging manifestations of Meckel's diverticulum. *AJR Am J Roentgenol* 2007;189(1):81–8.
- [7] Farah RH, Avala P, Khaiz D, Bensardi F, Elhattabi K, Lefriyehk R, et al. Spontaneous perforation of Meckel's diverticulum: a case report and review of literature. *Pan Afr Med J* 2015;20:319 Published 2015 Apr 1. doi:10.11604/pamj.2015.20.319.5980.
- [8] Sharma RK, Jain VK. Emergency surgery for Meckel's diverticulum. *World J Emerg Surg* 2008;3(27). doi:10.1186/1749-7922-3-27.
- [9] Feller AA, Movson J, Shah SA. Meckel diverticulum: a geriatric disease masquerading as common gastrointestinal tract disorders. *Arch Intern Med* 2003;163(17):2093–6. <https://www.ncbi.nlm.nih.gov/pubmed/14504124>. doi:10.1001/archinte.163.17.2093.
- [10] Parvanescu A, Bruzzi M, Voron T, Tilly C, Zinzindohoué F, Chevallier JM, et al. Complicated Meckel's diverticulum: presentation modes in adults. *Medicine (Baltimore)* 2018;97(38):e12457. doi:10.1097/MD.00000000000012457.