

CASE REPORT

Open Access

# Factor V Leiden mutation triggering four major complications to standard dose cisplatin-chemotherapy for testicular seminoma: a case report

Klaus-Peter Dieckmann<sup>1\*</sup>, Petra Anheuser<sup>1</sup>, Ralf Gehrckens<sup>2</sup>, Sven Philip Aries<sup>3</sup>, Raphael Ikogho<sup>1</sup> and Wiebke Hollburg<sup>4</sup>

## Abstract

**Background:** Major life-threatening complications secondary to cisplatin-based chemotherapy are rare in patients with testicular germ cell tumour (GCT). The incidence of complications increases with dosage of chemotherapy and with a variety of patient-related as well as disease-related conditions. We here report the first case of GCT experiencing as many as four major complications most of which can be explained by the conjunction of several predispositions.

**Case presentation:** A 48 year old patient with testicular seminoma and bulky retroperitoneal and mediastinal metastases underwent cisplatin based chemotherapy. During the third cycle of chemotherapy, he developed thrombosis of the central venous port device, subtotal splenic infarction, and Bleomycin induced pneumonitis (BIP). Three months after completion of therapy, he was struck by thalamic infarction. Genetic testing then revealed heterozygote mutation of Factor V Leiden (FVL). He received full-dose warfarin anticoagulation treatment and steroid treatment for BIP. 18 months thereafter, the patient is still disease-free, oncologically. Neurological symptoms have disappeared, but pulmonary dysfunction persists with a vital capacity of 50%.

**Conclusion:** The unique co-occurrence of four major complications occurring in this patient were obviously triggered by the genetically determined predisposition of the patient to thrombotic events (FVL). Additionally, several patient-related and disease-related conditions contributed to the unique pattern of complications, i.e. (1) the slightly advanced age (48 years), (2) the prothrombotic condition caused by the disease of cancer, (3) the central venous port device, (4) retroperitoneal bulky metastasis, and (5) cisplatin chemotherapy. Whether or not FVL contributed to the pulmonary fibrosis as well, remains elusive. Practically, in the case of one major vascular complication during cisplatin chemotherapy at standard dose, genetic testing for hereditary thrombophilia should be considered. Thus, precautions for preventing further complications could be initiated.

**Keywords:** Seminoma, Cisplatin chemotherapy, Thrombosis, Thrombophilia, Factor V Leiden, Bleomycin induced pneumonitis

\* Correspondence: DieckmannKP@t-online.de

<sup>1</sup>Albertinen-Krankenhaus, Department of Urology, Suentelstrasse 11a, D-22457 Hamburg, Germany

Full list of author information is available at the end of the article

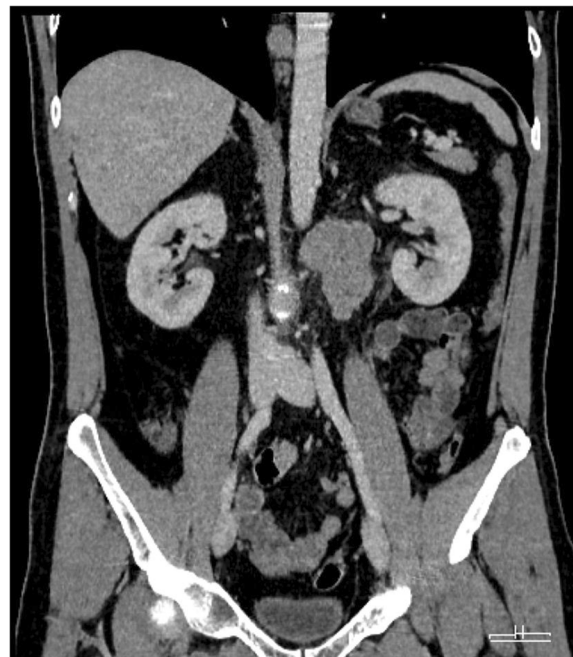
## Background

Testicular germ cell tumours (GCTs) represent a paradigm for a curable neoplasm [1]. Combination chemotherapy with cisplatin, etoposide and bleomycin (PEB) can cure metastasized disease and even far advanced disease (i.e. poor prognosis according to the IGCCCG classification) can be salvaged in about 50% [2]. However, systemic treatment is quite toxic even by application of standard doses and it involves the potential of numerous adverse reactions arising acutely at the time of treatment and other sequels developing in the long term [3]. The most frequent untoward reactions occurring at the time of treatment or immediately thereafter encompass myelodepression with neutropenic fever, alopecia, gastrointestinal toxicity, peripheral neurotoxicity, and impairment of fertility. These side-effects are experienced by almost all of the patients with varying degrees of severity, and usually, these events can be managed successfully. However occasionally, more serious and even life threatening complications may ensue mainly involving vascular and pulmonary events. Deep venous thrombosis (DVT) is encountered in about 8% of GCT patients receiving cisplatin-based chemotherapy for metastatic disease [4]. Pulmonary embolism secondary to DVT may occur in up to 6% of cases [5,6]. Arterial complications e. g. peripheral arterial thrombotic occlusion, myocardial infarctions, and cerebral vascular events are reported in about 0.3% of GCT patients receiving chemotherapy [7]. Pulmonary fibrosis represents the most important complication involving the lungs. This complication is also called bleomycin induced pneumonitis (BIP) because it is clearly associated with bleomycin if given in cumulative dosages of more than 300 mg [8,9]. About 7% of chemotherapy cases will experience BIP with 1% being fatal [10].

Multiple complications occurring synchronously or metachronously in one patient have been reported [4,7]. But rarely, more than three serious complications will be encountered in one individual [11]. Here we report a case who experienced as many as four serious complications secondary to cisplatin-combination chemotherapy, three vascular events and one pulmonary.

## Case presentation

This 48 years old patient with uneventful history presented with a left sided testicular seminoma. Beta Human chorionic gonadotropin (bHCG) was elevated to 247 U/l (normal range to 2 U/l) while Alpha fetoprotein and Lactate dehydrogenase were within normal limits. Computed tomography of chest and abdomen revealed a retroperitoneal mass of 6 cm in size (Figure 1) and another one of 2 cm size in the mediastinum corresponding to clinical stage III (Lugano Classification) and



**Figure 1** Abdominal computed tomography, coronary section view showing the large retroperitoneal metastasis of seminoma before initiation of chemotherapy.

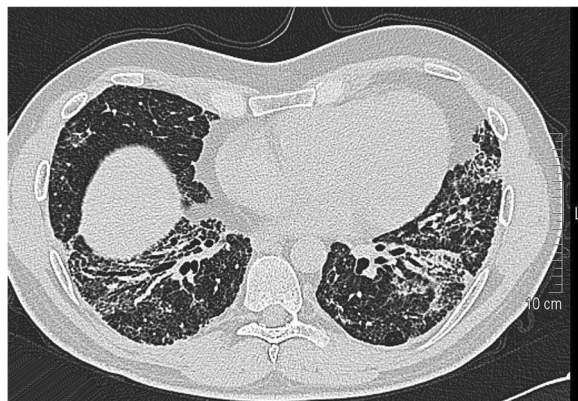to the good prognosis group according to IGCCCG classification [12].

The patient underwent inguinal orchiectomy and according to the patient's wish, a central venous port system with access to the right subclavian vein was implanted at the same time. Low-dose anticoagulation treatment was instituted thereafter with low molecular weight heparin (Enoxiparin 40 mg daily). Three cycles of the cisplatin/etoposide/ bleomycin chemotherapy regimen (PEB) were administered without delay between the cycles. Acute side effects involved recurrent singultus during all cycles, complete alopecia after the third cycle. Routine laboratory examinations done weekly during chemotherapy revealed transient increase of gamma glutamate dehydrogenase, as well anemia with hemoglobin of 8.9 g/dl. Serum creatinine increased during the application of the third cycle of treatment to 1.5 mg/dl indicating a considerable impairment of renal function. Also during the third cycle, the patient reported of increasing dyspnea upon slight exercise. In addition, at the end of the third cycle, the patient experienced a sudden episode of left upper abdominal pain. Routine restaging with computed tomography of chest and abdomen after completion of the second cycle of chemotherapy revealed partial remission of the lymphadenopathy but no other significant findings. Final restaging after the third cycle documented complete remission of the mediastinal mass and subtotal remission of the retroperitoneal mass.

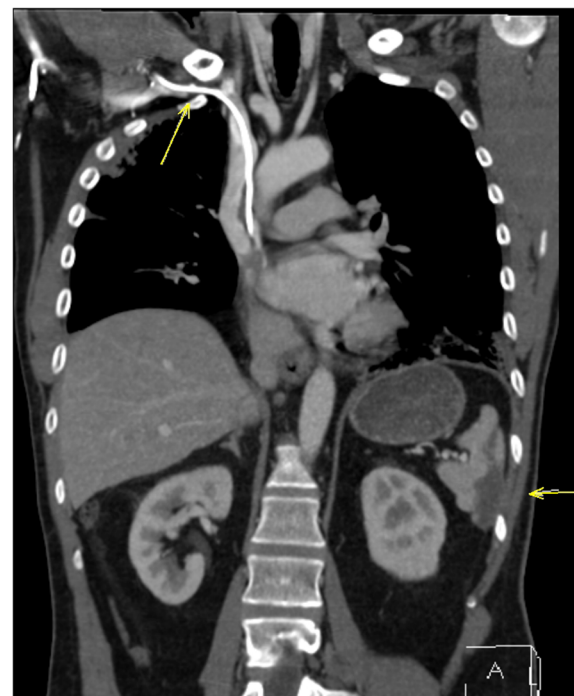
Accordingly, serum bHCG had returned to normal. Thus, cure had been achieved, oncologically. However, chest CT also revealed fibrotic changes bilaterally in the caudal parts of the lungs consistent with the typical findings in Bleomycin induced pneumonitis (Figure 2). Accordingly, pulmonary function testing revealed a decrease of vital capacity to 44%. Also, the chest CT revealed thrombosis of the central venous port system with extension of thrombotic material into the subclavian vein (Figure 3). In addition, the abdominal CT revealed splenic infarction involving approximately one third of the organ (Figure 3). Therapeutically, anticoagulation therapy was increased to 80 mg Enoxaparin daily and the venous port system was removed surgically. In addition, corticosteroid therapy with 50 mg Prednisolone p/o was applied for treatment of BIP resulting in some improvement of dyspnea, subsequently. Three months after completion of chemotherapy and despite ongoing full dose heparin-based anticoagulation therapy, the patient experienced a sudden loss of speech and amnesic aphasia. Magnetic resonance imaging of the brain disclosed infarction of the right-sided thalamic region (Figure 4) as well as several additional small older ischemic regions in the temporal and occipital cortex, respectively.

After all these complications genetic testing for inherited thrombophilia documented heterozygote mutation of factor V Leiden (FVL).

The patient was placed on life-long warfarin anticoagulation therapy. 18 months after completion of chemotherapy, follow-up examinations revealed ongoing complete remission, oncologically. The neurological symptoms had resolved totally. The corticosteroid therapy had been terminated 14 months after onset of BIP. Exertional dyspnea has improved meanwhile, however, vital capacity is still no more than 50%.



**Figure 2** Chest Computed tomography performed after third cycle of chemotherapy showing diffuse interstitial infiltrates, bilaterally, consistent with Bleomycin induced pneumonitis.

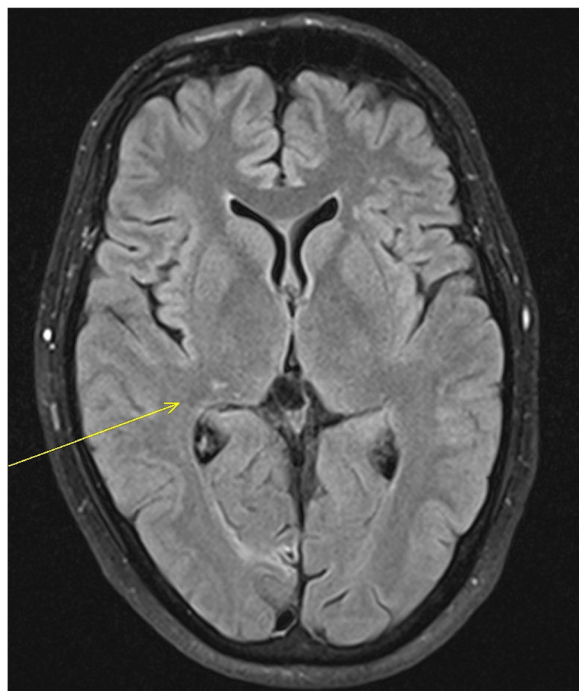


**Figure 3** Computed tomography of chest and abdomen, coronary section, performed after third cycle of chemotherapy, showing the central venous port device with thrombosis (arrow) and subtotal splenic infarction (arrow).

## Conclusion

Generally, the occurrence of complications secondary to a chemotherapeutic agent is dependent on both the applied dosage of the drug and the predisposition of the individual patient to acquire particular complications. Accordingly, high dose chemotherapy is associated with a much higher frequency of major complications. With respect to the susceptibility of the patient to acquire complications, older age is clearly one general predisposing factor as well as pre-existing chronic diseases e.g. Diabetes mellitus, renal insufficiency, chronic vascular disease. As most of the patients with testicular GCT are young and otherwise healthy, and as most of the metastasized cases only require standard dose chemotherapy, major complications are rather infrequent. Two or more critical events arising simultaneously or consecutively in one such patient are even more infrequent. Thus, the conjunction of four serious events as experienced by our patient is truly exceptional. O'Reilly reported a 26 year old patient with testicular seminoma and no significant comorbidity who sequentially experienced cerebral stroke, deep vein thrombosis and pulmonary embolism during PVB chemotherapy [11]. A 33 year old Dutch patient with GCT who was otherwise healthy developed cerebral stroke and myocardial infarction upon cisplatin-based therapy [13]. Likewise, in a German series, two





**Figure 4** Axial Magnetic resonance Imaging (MRI) of the Brain with Fluid Attenuated Inversion Recovery (FLAIR sequence), three months after completion of chemotherapy: Hyperintense lesion in the right thalamic region (arrow) indicating thalamic infarction.

patients (36 and 44 years of age) with both, myocardial infarction and cerebral stroke were reported. Also in that report, five cases with multivessel myocardial infarction as well as two cases with pulmonary embolism occurring in conjunction with cerebral stroke and with peripheral arterial thrombosis, respectively, were documented [7].

With respect to the present patient, it is probably the unique combination of a number of particular conditions that instigated this extraordinary pattern of untoward events.

Undoubtedly, the thrombophilic predisposition of this patient documented by the mutation of Factor V Leiden (FVL) represents the paramount pathogenetic factor that triggered the major vascular complications. Heterozygote status of FVL mutation is prevalent in around 5% of the Caucasian population involving a seven-fold increase of the thrombogenic risk in afflicted subjects [14]. Evidently, FVL does also modestly increase the risk of arterial thrombosis [15-17], at least in the presence of additional prothrombotic conditions [18]. Even splenic infarction, one of the events of our patient, has been documented in a case with FVL mutation [19].

Thus, our patient was bearing a genetically determined significantly increased risk of thrombosis which was superimposed by at least four additional synergistic thrombogenic factors: age, cancer, central venous port

system, and cisplatin chemotherapy. (I) Firstly, the slightly advanced age of 48 years confers a minor increase of general thrombotic risk by comparison to the average GCT patient. (II) Cancer itself generally increases the risk of thrombosis [20,21]. Moreover, there is also clear evidence of further increased thrombotic risk in those individuals who have both, cancer and FVL mutation [14]. On top of that, our patient had a huge retroperitoneal mass that potentially might compromise venous backflow from the lower limbs thus predisposing to intravascular clotting [4]. (III) Central venous port devices generally involve a high potential of thrombosis due to contact and irritation of vascular walls with the synthetic port material [22]. In the presence of FVL mutation, an additional 3 – 6 fold thrombotic risk has been documented [23,24]. (IV) Cisplatin combination chemotherapy involves considerable thrombogenic risk [25] possibly caused by endothelial damage [6,26,27]. Whether or not anti-emetic steroid therapy and BIP-related corticoid administration may have advanced the thrombotic risk in our patient is at least conceivable [28]. In all, our patient experienced three thrombotic events during or immediately after cisplatin-based chemotherapy. Obviously these complications were initiated and promoted by the conjunction of the patient's genetically determined increased risk of thrombosis on the one side, and several disease-related as well as treatment related synergistic prothrombotic factors on the other side.

With regard to the Bleomycin-related pulmonary fibrosis the patient used to be a non-smoker and he had no apparent predisposing pulmonary conditions. Yet, two minor precipitating factors could be noted, i.e. the slightly advanced age of 48 years and the impaired renal function developing during the third cycle of chemotherapy, both of these conditions are known to be associated with the occurrence of BIP [8]. At least on the experimental level there is some evidence that FVL mutation may promote pulmonary fibrosis, too [29]. Thus conceivably, the pulmonary and the vascular complications occurring in the present patient may share predisposing factors.

From a clinical point of view, it must be asked how and if at all these events could have been prevented. Probably, the pulmonary complication represents much of a chance event that had not been predictable at the time of treatment. Two of the three vascular complications were endo-arterial events. So, low dose heparin anticoagulation would probably not have been sufficient to prevent further vascular events. If acetylic salicylic acid (ASA) would have been beneficial in this case remains elusive. However, what should be learned from this extraordinary case is that genetic testing for hereditary clotting disorders should be considered in all those

GCT patients experiencing one major vascular complication. Then, life-threatening further complications could be prevented by full dose warfarin medication or other modern oral anticoagulation treatment.

## Consent

Written informed consent was obtained from the patient for publication of this Case report and the accompanying images. A copy of the written consent is available for review by the Editor of this journal.

## Abbreviations

GCT: Germ cell tumour; PEB: Cisplatin, Etoposide, Bleomycin (chemotherapy); IGCCCG: International germ cell cancer consensus group; BIP: Bleomycin induced pneumonia; CT: Computed tomography; FVL: Factor V Leiden; DVT: Deep vein thrombosis; BHCG: Beta human chorionic gonadotropin; p/o: Per oral (medication).

## Competing interests

The authors declare that they have no competing interests.

## Authors' contributions

KPD conceived the study, wrote the manuscript. PA co-conceived the study, did most of the literature research. RG did most of the radiological examinations, assisted in drafting the manuscript. SPA did the pulmonary examinations, guided particular parts of the clinical management. RI guided particular parts of the clinical management, co-conceived the study. WH did most of the clinical management, assisted in drafting the manuscript. All authors have critically revised and finally approved the manuscript.

## Acknowledgements

Dr. Saskia Kleier, Humangenetik at Gynaekologikum, Hamburg, gave valuable advice regarding the diagnosis of Factor V Leiden mutation. Dr. Hendrik Job, Department of Radiology, Albertinen-Krankenhaus Hamburg, assisted in selecting appropriate imaging material for publication. The present study did not receive any funding.

## Author details

<sup>1</sup>Albertinen-Krankenhaus, Department of Urology, Suentelstrasse 11a, D-22457 Hamburg, Germany. <sup>2</sup>Albertinen-Krankenhaus, Department of Diagnostic Radiology, Hamburg, Germany. <sup>3</sup>Elbpneumologie, Mörkenstrasse 47, D-22767 Hamburg, Germany. <sup>4</sup>Hämatologisch-onkologische Praxis Altona (HOPA), Mörkenstrasse 47, D-22767 Hamburg, Germany.

Received: 28 November 2014 Accepted: 20 February 2015

Published online: 17 March 2015

## References

- Hanna N, Einhorn LH. Testicular cancer: a reflection on 50 years of discovery. *J Clin Oncol*. 2014;32(28):3085–92.
- Calabrò F, Albers P, Bokemeyer C, Martin C, Einhorn LH, Horwich A, et al. The contemporary role of chemotherapy for advanced testis cancer: a systematic review of the literature. *Eur Urol*. 2012;61:1212–21.
- Abouassaly R, Fossa SD, Giwercman A, Kollmannsberger C, Motzer RJ, Schmoll HJ, et al. Sequelae of treatment in long-term survivors of testis cancer. *Eur Urol*. 2011;60(3):516–26.
- Piketty AC, Flechon A, Laplanche A, Nouyrigat E, Droz JP, Theodore C, et al. The risk of thrombo-embolic events is increased in patients with germ-cell tumours and can be predicted by serum lactate dehydrogenase and body surface area. *Br J Cancer*. 2005;93:909–14.
- Weijl NI, Rutten MF, Zwinderman AH, Keizer HJ, Nooy MA, Rosendaal FR, et al. Thromboembolic events during chemotherapy for germ cell cancer: a cohort study and review of the literature. *J Clin Oncol*. 2000;18:2169–78.
- Nuver J, Smit AJ, van der Meer J, van den Berg MP, van der Graaf WT, Meinardi MT, et al. Acute chemotherapy-induced cardiovascular changes in patients with testicular cancer. *J Clin Oncol*. 2005;23:9130–7.
- Dieckmann KP, Gerl A, Witt J, Hartmann JT, German Testicular Cancer Study Group. Myocardial infarction and other major vascular events during chemotherapy for testicular cancer. *Ann Oncol*. 2010;21:1607–11.
- Sleijfer S. Bleomycin-induced pneumonitis. *Chest*. 2001;120:617–24.
- O'Sullivan JM, Huddart RA, Norman AR, Nicholls J, Dearnaley DP, Horwich A. Predicting the risk of bleomycin lung toxicity in patients with germ-cell tumours. *Ann Oncol*. 2003;14:91–6.
- Efstathiou E, Logothetis CJ. Review of late complications of treatment and late relapse in testicular cancer. *J Natl Compr Canc Netw*. 2006;4:1059–70.
- O'Reilly A, Maceneaney P, Mayer N, O'Reilly SP, Power DG. Testicular cancer and platinum: a double-edged sword. *J Clin Oncol*. 2014;32(12):e46–8.
- International Germ Cell Cancer Consensus Group. International germ cell consensus classification: a prognostic factor-based staging system for metastatic germ cell cancers. *J Clin Oncol*. 1997;15(2):594–603.
- Brouha ME, Bloemendaal HJ, Kappelle LJ, Winter JB. Cerebral infarction and myocardial infarction due to cisplatin-containing chemotherapy.[Article in Dutch. *Ned Tijdschr Geneesk*. 2003;147:457–60.
- Blom JW, Doggen CJ, Osanto S, Rosendaal FR. Malignancies, prothrombotic mutations, and the risk of venous thrombosis. *JAMA*. 2005;293(6):715–22.
- Voetsch B, Loscalzo J. Genetic determinants of arterial thrombosis. *Arterioscler Thromb Vasc Biol*. 2004;24(2):216–29.
- Page C, Rubin LE, Gusberg RJ, Dardik A. Arterial thrombosis associated with heterozygous factor V Leiden disorder, hyperhomocysteinemia, and peripheral arterial disease: importance of synergistic factors. *J Vasc Surg*. 2005;42(5):1014–48.
- de Paula Sabino A, Ribeiro DD, Carvalho M, Cardoso J, Dusse LM, Fernandes AP. Factor V Leiden and increased risk for arterial thrombotic disease in young Brazilian patients. *Blood Coagul Fibrinolysis*. 2006;17(4):271–5.
- Mandegar MH, Saidi B, Roshanali F. Extensive arterial thrombosis in a patient with factor V Leiden mutation. *Interact Cardiovasc Thorac Surg*. 2010;11(1):127–9.
- Lopez F, Mega A, Schiffman F, Sweeney J. Splenic infarction from factor V Leiden mutation. *Am J Hematol*. 1999;62(1):62–3.
- De Cicco M. The prothrombotic state in cancer: pathogenic mechanisms. *Crit Rev Oncol Hematol*. 2004;50:187–96.
- Blann AD, Dunmore S. Arterial and venous thrombosis in cancer patients. *Cardiol Res Pract*. 2011;2011:394740.
- Honecker F, Koychev D, Luhmann AD, Langer F, Dieckmann KP, Bokemeyer C, et al. Venous thromboembolic events in germ cell cancer patients undergoing platinum-based chemotherapy. *Onkologie*. 2013;36(11):663–8.
- Mandalà M, Curigliano G, Bucciarelli P, Ferretti G, Mannucci PM, Colleoni M, et al. Factor V Leiden and G20210A prothrombin mutation and the risk of subclavian vein thrombosis in patients with breast cancer and a central venous catheter. *Ann Oncol*. 2004;15(4):590–3.
- Van Rooden CJ, Rosendaal FR, Meinders AE, Van Oostayen JA, Van Der Meer FJ, Huisman MV. The contribution of factor V Leiden and prothrombin G20210A mutation to the risk of central venous catheter-related thrombosis. *Haematologica*. 2004;89(2):201–6.
- Starling N, Rao S, Cunningham D, Iveson T, Nicolson M, Coxon F, et al. Thromboembolism in patients with advanced gastroesophageal cancer treated with anthracycline, platinum, and fluoropyrimidine combination chemotherapy: a report from the UK national cancer research institute upper gastrointestinal clinical studies group. *J Clin Oncol*. 2009;27(23):3786–93.
- Dieckmann KP, Struss WJ, Budde U. Evidence for acute vascular toxicity of cisplatin-based chemotherapy in patients with germ cell tumour. *Anticancer Res*. 2011;31(12):4501–5.
- Nuver J, De Haas EC, Van Zweeden M, Gietema JA, Meijer C. Vascular damage in testicular cancer patients: a study on endothelial activation by bleomycin and cisplatin in vitro. *Oncol Rep*. 2010;23(1):247–53.
- Johannesdottir SA, Horváth-Puhó E, Dekkers OM, Cannegieter SC, Jørgensen JO, Ehrenstein V, et al. Use of glucocorticoids and risk of venous thromboembolism: a nationwide population-based case-control study. *JAMA Intern Med*. 2013;173(9):743–52.
- Xu Z, Westrick RJ, Shen YC, Eitzman DT. Pulmonary fibrosis is increased in mice carrying the factor V Leiden mutation following bleomycin injury. *Thromb Haemost*. 2001;85(3):441–4.