



Case Report

Language lateralization in a patient with temporal lobe epilepsy and callosal agenesis

Taoufik Alsaadi ^{a,*}, Tarek M. Shahrour ^b^a Department of Neurology, SKMC, United Arab Emirates^b Department of Psychiatry, SKMC, United Arab Emirates

ARTICLE INFO

Article history:

Received 11 July 2014

Accepted 14 July 2014

Available online 24 December 2014

Keywords:

Callosal agenesis

Language lateralization

fMRI

Epilepsy

ABSTRACT

The corpus callosum has been proposed as a mechanism of interhemispheric inhibition that allows language dominance to develop [1]. Callosal agenesis or dysgenesis provides a test of this hypothesis, as patients lacking a normal corpus callosum should also lack normal language lateralization [2]. We report pre- and postoperative functional magnetic resonance imaging (fMRI) and neuropsychological testing in a patient with partial callosal agenesis who underwent a right temporal lobectomy for medically refractory seizures.

© 2014 The Authors. Published by Elsevier Inc. This is an open access article under the CC BY-NC-ND license (<http://creativecommons.org/licenses/by-nc-nd/3.0/>).

1. Case report

A 33-year-old right-handed male sought treatment for medically refractory seizures. He was a product of normal pregnancy and delivery with no history of febrile seizures, meningitis, encephalitis, or head injury. No specific learning disabilities were identified, despite poor school grades and behavioral problems. Seizures started at the age of 25. He described an aura consisting of an epigastric rising sensation occurring up to five times daily. The aura was followed by a generalized seizure occurring once monthly. The seizures were refractory to treatment with several antiepileptic medications. Neurological examination was normal except for mild left-hand posturing with stress gait. He had a normal routine EEG. Structural brain MRI revealed partial agenesis of the corpus callosum (Fig. 1). No other brain abnormalities or hippocampal asymmetries were noted. Video-EEG monitoring revealed right temporal onset seizures, and a PET scan showed right temporal hypometabolism. The Wada procedure (intracarotid amytal test) suggested that language was bilaterally represented, with some advantage for the left hemisphere. Memory testing revealed better recall after right carotid injection versus left carotid injection, a finding consistent with a suspected right temporal abnormality. Functional magnetic resonance imaging showed bilateral language representation with slightly more activation in the left hemisphere. An auditory sentence task produced a laterality index (LI) of 0.2 within the inferior frontal region of interest (ROI) containing anterior language areas (LIs can range from 1.0 to

–1.0, with 1.0 indicating strong left-hemisphere language dominance) (Fig. 2, yellow). Routine neuropsychological assessment revealed borderline overall intellectual functioning (full-scale IQ of 71), with relative weakness in verbal abilities compared with more nonverbal skills (VIQ of 68, PIQ of 79).

The patient was determined to be an adequate surgical candidate and underwent a standard right anterior temporal lobectomy with intraoperative electrocorticography. At one year postoperative, the patient was seizure-free except for rare auras (Engel class IB) on the same preoperative antiepileptic medications. Right temporal lobe pathology showed mild gliosis. Repeat fMRI analysis three months after surgery revealed slightly increased left-hemisphere language representation using the same fMRI task. The postoperative fMRI laterality index for inferior frontal ROI was 0.6 (Fig. 2, red). Three-month postoperative neuropsychological testing showed mild improvements in attention and expressive language. The most notable improvement was on the confrontation naming test. Although the mild gains in test scores may reflect practice effects, the performance across other measures was generally stable.

2. Discussion

Prior to the use of fMRI to assess language lateralization, these patients were assessed with controversial indirect methods like dichotic listening [3,4] or discrepancies in VIQ/PIQ scores [5]. In clinical practice settings, many studies have shown strong correlations between fMRI and the intracarotid amobarbital technique (Wada) test. In fact, a recent

* Corresponding author.

E-mail address: talsadi@skmc.ae (T. Alsaadi).

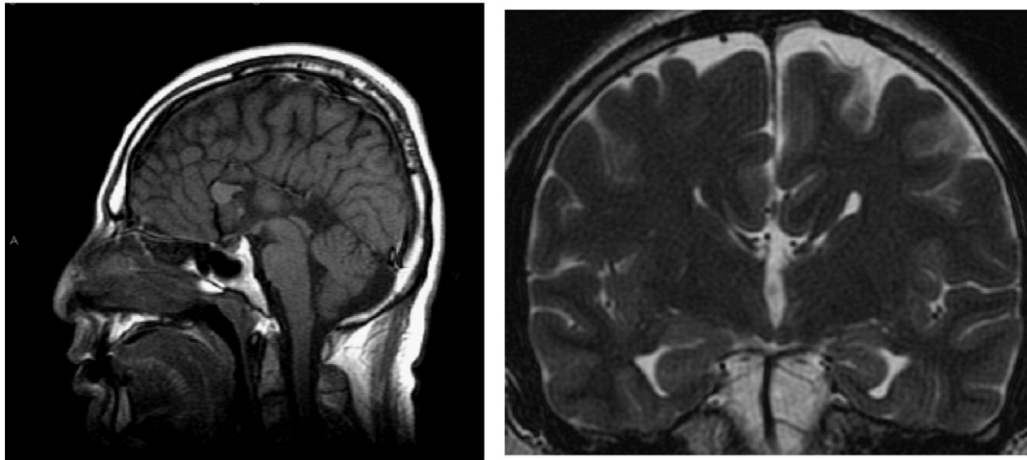


Fig. 1. Structural MRI with images revealing partial agenesis of the corpus callosum with missing body and splenium. Part of the genu of the corpus callosum is seen.

well-designed study has suggested that fMRI may be more sensitive than the Wada test to right-hemisphere language processing [6].

In this case, both fMRI and Wada results provide evidence of bilateral language representation, which may help explain his relative weakness in language functions compared with nonverbal abilities. Wada and PET studies have also reported bilateral language representation in other cases of callosal agenesis [2,7]. Moreover, language dysfunction has been noted in other populations with specific callosal atrophy [8].

Our finding is in agreement with a recently published case of a patient with history of headaches and agenesis of the corpus callosum as confirmed by MRI and diffusion tensor imaging (DTI). The latter case showed bilateral language activation by fMRI without lateralization during speech production and perception [9].

However, given the large anatomic and functional variability in the population of subjects with agenesis of the corpus callosum, this finding needs to be more extensively replicated. A recent study explored language lateralization in six individuals with agenesis of the corpus callosum and in a control group using an fMRI protocol which included a syntactic decision task and a subvocal verbal fluency task. In that study, there were no differences found between language lateralization of the subjects with agenesis of the corpus callosum and that of the control group in the receptive speech task. The authors concluded that the corpus callosum is not essential for the establishment of lateralized language functions [10]. There are several limitations to this study, including a small sample size and the dichotomy of the control group. As a matter of fact and in that same study, the acallosal participants showed bilateral pattern of activation for expressive speech compared with the high-IQ participants only. Additional studies using a larger sample size need to be replicated to address the questions the above study has raised.

3. Conclusions

In conclusion, we propose that bilateral language representation is abnormal in this patient and may be the result of compensation for a

lack of interhemispheric communication via the corpus callosum. The shift in language lateralization after surgery is intriguing because it is associated with a modest improvement in language testing. The improvement could be the result of the surgical removal of an inhibitory influence from the right hemisphere. This inhibition may have been a result of the epileptogenic focus or competing language representation in the right hemisphere. Future fMRI and neuropsychological testing in patients with varying degrees of callosal dysgenesis may reveal additional information about important functions that are mediated by the corpus callosum.

Conflict of interest

None.

References

- [1] Moscovitch M. The development of lateralization of language functions and its relation to cognitive and linguistic development: a review and some theoretical considerations. In: Segalowitz SJ, Gruber FA, editors. *Language development and neurological theory*. New York: Academic Press; 1977.
- [2] Komaba Y, Senda M. Bilateral representation of language function. Agenesis of corpus callosum by Wada and PET activation. *J Neuroimaging* 1998;8:246–9.
- [3] Lassonde M, et al. The corpus callosum and cerebral speech lateralization. *Brain Lang* 1990;38:195–206.
- [4] Cook, N.D. et al. On the role of the corpus callosum in cerebral laterality: a comment on Lassonde, Bryden, and Demers. *Brain Lang*; 39:471–474.
- [5] Paul LK, et al. Communicative deficits in agenesis of the corpus callosum: nonlateral language and affective prosody. *Brain Lang* 2003;85:313–24.
- [6] Janecek Julie K, et al. Language lateralization by fMRI and Wada testing in 229 epilepsy patients: rates and predictors of discordance. *Epilepsia* 2013;54(2):314–22.
- [7] Kessler J, et al. Complex sensory cross integration deficits in a case of corpus callosum agenesis with bilateral language representation: positron emission tomography and neuropsychological findings. *Int J Neurosci* 1991;58:275–82.
- [8] Baynes K, et al. Pyroxidine-dependent seizures and cognition in adulthood. *Dev Med Child Neurol* 2003;45:782–5.
- [9] Riecker A, et al. Bilateral language function in callosal agenesis: an fMRI and DTI study. *J Neurol* 2007 Apr;254(4):528–30.
- [10] Pelletier I, et al. Language lateralization in individuals with callosal agenesis: an fMRI study. *Neuropsychologia* 2011 Jun;49(7):1987–95.

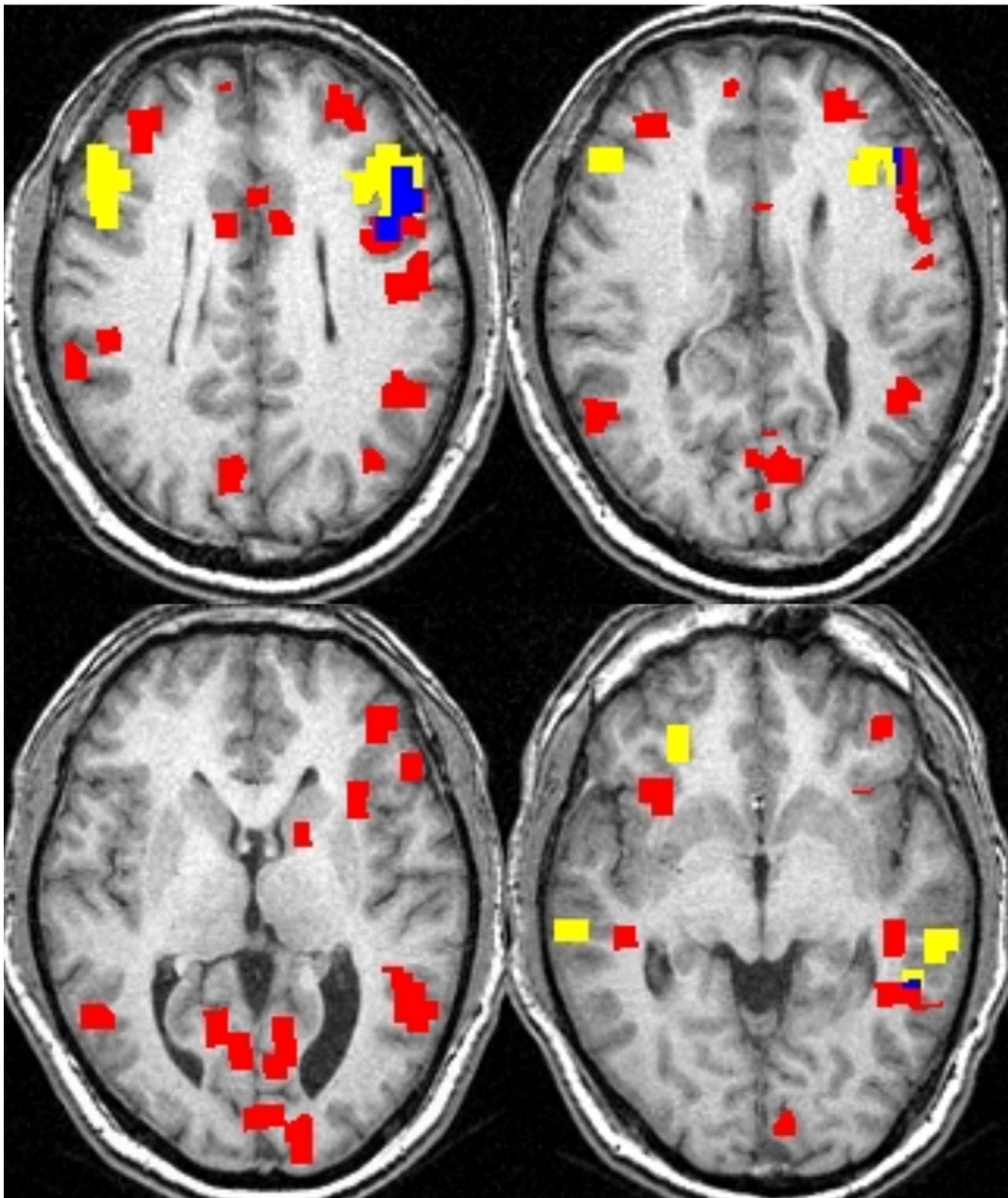


Fig. 2. Functional MRI axial images showing pre- and postoperative activation from the audio sentence task. Areas of preoperative activation are depicted in yellow; areas of postoperative activation in red and overlap in blue.