

Clinical features and treatment outcomes of human immunodeficiency virus-associated cryptococcal meningitis: a 2-year retrospective analysis

Wei Song, Yin-Zhong Shen, Zhen-Yan Wang, Tang-Kai Qi, Li Liu, Ren-Fang Zhang, Jiang-Rong Wang, Yang Tang, Jun Chen, Jian-Jun Sun, Hong-Zhou Lu

Department of Infection and Immunity, Shanghai Public Health Clinical Center, Fudan University, Shanghai 201508, China.

Abstract

Background: Cryptococcal meningitis (CM) is one of the most common opportunistic infections caused by *Cryptococcus neoformans* in human immunodeficiency virus (HIV)-infected patients, and is complicated with significant morbidity and mortality. This study retrospectively analyzed the clinical features, characteristics, treatment, and outcomes of first-diagnosed HIV-associated CM after 2-years of follow-up.

Methods: Data from all patients ($n = 101$) of HIV-associated CM hospitalized in Shanghai Public Health Clinical Center from September 2013 to December 2016 were collected and analyzed using logistic regression to identify clinical and microbiological factors associated with mortality.

Results: Of the 101 patients, 86/99 (86.9%) of patients had CD4 count < 50 cells/mm³, 57/101 (56.4%) were diagnosed at ≥ 14 days from the onset to diagnosis, 42/99 (42.4%) had normal cerebrospinal fluid (CSF) cell counts and biochemical examination, 30/101 (29.7%) had concomitant *Pneumocystis (carinii) jiroveci* pneumonia (PCP) on admission and 37/92 (40.2%) were complicated with cryptococcal pneumonia, 50/74 (67.6%) had abnormalities shown on intracranial imaging, amongst whom 24/50 (48.0%) had more than one lesion. The median time to negative CSF Indian ink staining was 8.50 months (interquartile range, 3.25–12.00 months). Patients who initiated antiretroviral therapy (ART) before admission had a shorter time to negative CSF Indian ink compared with ART-naïve patients (7 vs. 12 months, $\chi^2 = 15.53$, $P < 0.001$). All-cause mortality at 2 weeks, 8 weeks, and 2 years was 10.1% (10/99), 18.9% (18/95), and 20.7% (19/92), respectively. Coinfection with PCP on admission (adjusted odds ratio [AOR], 3.933; 95% confidence interval [CI], 1.166–13.269, $P = 0.027$) and altered mental status (AOR, 9.574; 95% CI, 2.548–35.974, $P = 0.001$) were associated with higher mortality at 8 weeks.

Conclusion: This study described the clinical features and outcomes of first diagnosed HIV-associated CM with 2-year follow-up data. Altered mental status and coinfection with PCP predicted mortality in HIV-associated CM.

Keywords: Clinical features; Cryptococcal meningitis; HIV; Intracranial lesions; Mortality

Introduction

Cryptococcal meningitis (CM), a central nervous system (CNS) infection caused by *Cryptococcus neoformans*, is one of the common opportunistic infections in human immunodeficiency virus (HIV)-infected patients. A recent systematic review found a pooled global cryptococcal antigen prevalence of 6.5% among patients with CD4 < 100 cells/mm³.^[1] It was estimated that 70% (range 56%–84%) of HIV-infected people positive for *Cryptococcal antigenaemia* would progress to develop cryptococcal disease or died without a diagnosis; 15% of acquired immunodeficiency syndrome (AIDS)-related

deaths were caused by CM.^[2] We previously found that CM was the most common CNS disease after analyzing the disease spectrum of 339 cases of AIDS complicated with CNS diseases in our hospital from January 2010 to January 2015.^[3] This was comparable to findings from sub-Saharan Africa.^[4-6] In order to improve patient prognosis and quality of life, it is essential to fully understand its clinical features for early identification and diagnosis. This study retrospectively analyzed the clinical features, characteristics, treatment, and outcomes of HIV-associated CM with a 2-year follow-up, to shed light on its diagnosis and treatment.

Access this article online

Quick Response Code:



Website:

www.cmj.org

DOI:

10.1097/CM9.0000000000001191

Correspondence to: Dr. Yin-Zhong Shen, Department of Infection and Immunity, Shanghai Public Health Clinical Center, Fudan University, Shanghai 201508, China
E-Mail: shenyinzhong@shphc.org.cn

Copyright © 2020 The Chinese Medical Association, produced by Wolters Kluwer, Inc. under the CC-BY-NC-ND license. This is an open access article distributed under the terms of the Creative Commons Attribution-Non Commercial-No Derivatives License 4.0 (CCBY-NC-ND), where it is permissible to download and share the work provided it is properly cited. The work cannot be changed in any way or used commercially without permission from the journal.

Chinese Medical Journal 2020;133(23)

Received: 30-05-2020 Edited by: Qiang Shi

Methods

Ethics approval

The study protocol was approved by the Shanghai Public Health Clinical Center Ethics Committee (No. 2017-S024-02). It was a secondary data analysis and did not involve contact with individual patients so consent to participate was not applicable.

Patients

Data from all patients with firstly diagnosed HIV-associated CM hospitalized in Shanghai Public Health Clinical Center from September 2013 to December 2016 was collected.

All selected patients had a blood test and were confirmed positive by Western blotting for HIV antibody, and cerebrospinal fluid (CSF) positive for Indian ink staining or fungal culture positive for *C. neoformans*. *Pneumocystis (carinii) jiroveci* pneumonia (PCP) was diagnosed by typical clinical symptoms, imaging manifestations, and effective trimethoprim-sulfamethoxazole therapy. All patients with mycobacterial infection had positive acid fast smears in sputum and positive culture of mycobacteria in blood or sputum. Diagnosis of cryptococcal pneumonia was made on the basis of imaging findings and follow-up results after treatment (excluding the bacterial and mycobacterium infection).

Treatment regimen

All patients were treated with an intravenous infusion of conventional amphotericin B (AMB, $0.5 \text{ mg}\cdot\text{kg}^{-1}\cdot\text{d}^{-1}$), the only amphotericin B preparation available in our center, plus flucytosine (5-FC; $100 \text{ mg}\cdot\text{kg}^{-1}\cdot\text{d}^{-1}$) oral induction regimen for at least 4 weeks, followed by fluconazole 400 mg/d oral consolidation regimen until the CSF Indian ink staining turned negative. Patients continued to take fluconazole 200 mg/d maintenance regimen until CD4 count $>100 \text{ cells}/\text{mm}^3$. All patients received anti-fungal therapy for more than 1 year. Some patients received voriconazole (VOR) intravenous infusion in the first 2 weeks of anti-cryptococcal therapy (6 mg/kg every 12 h for the first 24 h followed by 4 mg/kg q12h) according to both the treating physician's discretion and the patient's economic status. VOR is relatively expensive in China, which is why we use it for only 2 weeks. Since there were no other amphotericin B formulations in Shanghai Public Health Clinical Center, no alternative could be provided.

Antiretroviral therapy (ART) was continued for those who had initiated ART before the onset of CM; and for those who were ART-naïve on admission, ART was initiated at 4 weeks after anti-fungal treatment.

All patients underwent lumbar puncture at admission before or after the use of mannitol, so the first cranial pressure could not be compared. Mannitol was used 3 to 6 times a day according to the clinical situation. During the hospitalization, lumbar puncture was performed about

every two weeks. After discharge, patients were required to undergo the lumbar puncture every 3 months.

Outcomes

The demographics and baseline clinical characteristics on admission (age, sex, time interval between onset to diagnosis, clinical manifestations, CSF manifestations, presence of intracranial lesions, positivity on blood culture, cryptococcal-related tests, HIV viral load, and CD4 cell count), treatment and outcomes of all patients were comprehensively described. Presence of abnormalities in intracranial imaging on admission, new intracranial lesions or progression/exacerbation of initial lesions during treatment, and time to CSF Indian ink staining negativity were studied. All-cause mortality of HIV-associated CM at 2, 8 weeks, and 2 years was analyzed. Patients were further stratified by VOR use status to evaluate the safety of the two regimens (3-drug *vs.* 2-drug) by the occurrence of adverse events. The definition criteria of adverse events were referred to the Division of AIDS Table for Grading the Severity of Adult and Pediatric Adverse Events.^[7] The all-cause mortality between the two groups was compared.

Statistical analysis

Data were analyzed using SPSS statistics, version 25.0 (IBM, Armonk, NY, USA). Median and interquartile range (IQR) were used to describe the measurement data. Chi-square test (or Fisher exact test) and logistic single factor regression analysis were used for comparison between groups. Relevant factors with $P < 0.06$ found in the single factor analysis of 8-week mortality were included in Logistic multivariate regression analysis. Kaplan-Meier survival curves were used to describe the overall outcomes of these patients. The CSF negative Indian ink staining was defined as an event. Log-rank method was used to test differences in CSF Indian ink staining between two groups according to ART-treatment status before the onset of HIV-associated CM.

Results

Baseline clinical characteristics

Totally, 101 first diagnosed HIV-associated CM patients were included. The median age was 35 years, and 88/101 (87.1%) were male, 86 were ART-naïve, 57/101 (56.4%) were diagnosed in ≥ 14 days from symptom onset. The median CD4 count was $20 \text{ cells}/\text{mm}^3$, and 86/99 (86.9%) had CD4 count less than $50 \text{ cells}/\text{mm}^3$. In terms of cryptococcal-related tests, 96/96 (100%) of patients had CSF tested positive for cryptococcal antigen, 98/99 (99%) had CSF cultured positive for *C. neoformans*, 98/101 (98%) had CSF tested positive for Indian ink staining, 60/82 (73.2%) of patients had a positive test for blood culture of cryptococcus, but 42/99 (42.4%) of these had normal CSF routine [Table 1] and biochemical examination; 30/101 (29.7%) of the patients were coinfecting with PCP on admission and 37/92 (40.2%) were complicated with cryptococcal pneumonia, 50/74 (67.6%) had abnormal intracranial imaging, and 24/50 (48.0%) of them had more than one lesion. These CNS lesions were most commonly

Table 1: Baseline characteristics of patients.

Characteristics	n (%)	Median (interquartile range)
Age (years)	n = 101	35 (29.5–43.0)
<50	86 (85.1)	
≥50	15 (14.9)	
Sex	n = 101	
Female	13 (12.9)	
Male	88 (87.1)	
ART status	n = 101	
ART-naïve	86 (85.1)	
ART-treated	15 (14.9)	
CD4 cell count (cells/mm ³)	n = 99	20 (9–34)
<50	86 (86.9)	
≥50	13 (13.1)	
HIV viral load (copies/mL)	n = 67	80,400 (41,500–246,000)
<1000	3 (4.5)	
≥1000	64 (95.5)	
Hemoglobin (g/L)	n = 99	120 (108–131)
≥90	91 (91.9)	
<90	8 (8.1)	
CSF white cell count (cells/mL)	n = 99	6 (2–28)
<20	69 (69.7)	
≥20	30 (30.3)	
CSF protein (mg/L)	n = 98	286.0 (181.5–542.0)
<500	70 (71.4)	
≥500	28 (28.6)	
CSF glucose (mmol/L)	n = 99	2.23 (1.57–3.03)
≥2.00	62 (62.6)	
<2.00	37 (37.4)	
Both CSF routine and biochemical examinations were normal*	n = 99	
Yes	42 (42.4)	
No	57 (57.6)	
CSF India ink staining	n = 100	
Negative	2 (2)	
Positive	98 (98)	
CSF culture of <i>Cryptococcus neoformans</i>	n = 99	
Negative	1 (1)	
Positive	98 (99)	
CSF cryptococcal antigen screening	n = 96	
Negative	0	
Positive	96 (100)	
Blood culture of <i>Cryptococcus neoformans</i>	n = 82	
Negative	22 (26.8)	
Positive	60 (73.2)	
Time interval between onset and diagnosis of CM (days)	n = 101	

(continued)

Table 1

(continued).

Characteristics	n (%)	Median (interquartile range)
<14	44 (43.6)	
≥14	57 (56.4)	
Coinfection with PCP on admission	n = 101	
No	71 (70.3)	
Yes	30 (29.7)	
Altered mental status on admission (Glasgow coma score <15)	n = 101	
No	84 (83.2)	
Yes	17 (16.8)	
Complicated with Cryptococcal pneumonia on admission	n = 92	
No	55 (59.8)	
Yes	37 (40.2)	
Presence of abnormalities on intracranial imaging before treatment	n = 74	
No	24 (32.4)	
Yes	50 (67.6)	

* Both CSF routine and biochemical examination were normal if the following conditions were met: CSF cell number <20 cells/mL, CSF protein <500 mg/L, CSF sugar ≥2.0 mmol/L. ART: Antiretroviral therapy; HIV: Human immunodeficiency virus; CSF: Cerebrospinal fluid; CM: Cryptococcal meningitis; PCP: *Pneumocystis (carinii) jiroveci* pneumonia.

found around the ventricles and lateral ventricles (40%), basal ganglia (38%), and frontal lobe (38%) [Tables 1 and 2].

Treatment outcomes and prognosis

Intravenous infusion of conventional AMB combined with oral administration of 5-FC was used for all patients as induction regimen. The median duration of AMB used was 43 days (IQR, 31.5–68.5 days), and 70 days (36.5–116.5 days) for 5-FC. 55.4% (56/101) of patients received VOR intravenous infusion in the first 2 weeks of treatment. 10.9% (11/101) of patients underwent V-P shunt surgery [Table 3]. The median time to negative CSF culture for *C. neoformans* was 20 days (IQR, 15–30 days), and to negative CSF Indian ink staining was 8.5 months (IQR, 3.25–12.00 months). However, only 43.6% (44/101) of patients had a negative test for Indian ink staining in CSF obtained at the last possible lumbar puncture during the study period. We found strong evidence that median time to CSF Indian ink staining negativity in ART-treated patients on admission was shorter than that of ART-naïve patients (7 vs. 12 months, $\chi^2 = 15.53, P < 0.001$) [Table 3 and Figure 1]. Mycobacterium infection was found in 30.7% (27/88) of patients during the entire anti-fungal treatment course within the study period. Appearance of

Table 2: Location of intracranial lesions, n = 50.

Location	n (%)
Single lesion	23 (46)*
Multiple lesions (>1)	24 (48)
Around the ventricles and lateral ventricles	20 (40)
Basal ganglia	19 (38)
Frontal lobe	19 (38)
Parietal lobe	14 (28)
Occipital lobe	9 (18)
Cerebellum	3 (6)
Temporal lobe	3 (6)
Ventricular dilatation, hydrocephalus and brain swelling	3 (6)
Corona radiata	2 (4)
Sub-cortex	2 (4)
Thalamus	1 (2)
Junction of gray matter and white matter of brain parenchyma	1 (2)
Centrum semiovale	1 (2)

* One case of ventricular dilatation, one case of brain swelling, and one case of cysts of Mega cisterna magna were removed.

new intracranial lesions or progression/exacerbation of initial lesion during treatment occurred in 29.4% (15/51) of the patients [Table 3]. During the study period, two patients had been lost in 2 weeks, six patients in 8 weeks, and nine patients in 2 years for treatment and follow-up. The all-cause mortality at 2, 8 weeks, and 2 years were 10.1%, 18.9%, and 20.7%, respectively [Table 3].

Factors associated with 8-week mortality

There was strong evidence for associations between 8-week mortality and two factors (coinfection with PCP on admission, and altered mental status on admission). The 8-week mortality of patients coinfecting with PCP than those without co-infection (35.5% vs. 11.9%, adjusted odds ratio [AOR] 3.933, 95% confidence interval [CI] 1.166–13.269, P = 0.027), and was higher among those with altered mental status compared with normal mental status (52.9% vs. 11.5%, AOR 9.574, 95% CI 2.548–35.974, P = 0.001) [Table 4].

Treatment-related adverse events

The common adverse events included elevated alanine transaminase (ALT), hypokalemia, anemia, neutropenia, and thrombocytopenia. Patients who received 3-drug regimen had significantly higher ALT elevation than those with 2-drug regimen. But there were no significant differences in grade 3 and grade 4 events between the two groups. The incidence of other adverse events was similar in both groups [Table 5].

Discussion

This retrospective study focused on 2-year prognosis and clinical features of HIV-associated CM patients. All-cause

Table 3: Treatment and outcomes.

Characteristics	Data
Treated with voriconazole at the first 2 weeks	
No	45 (44.6)
Yes	56 (55.4)
Duration of conventional Amphotericin B (days)	43.0 (31.5–68.5)
Duration of 5-FC (days)	70.0 (36.5–116.5)
V-P shunt was performed	
No	90 (89.1)
Yes	11 (10.9)
Time to negative CSF culture of <i>Cryptococcus neoformans</i> (days)	n = 83 20 (15–30)
Time to negative CSF Indian ink staining (months)* (n = 44)	8.5 (3.25–12.00)
Complicated with Mycobacterium infection†	n = 88
No	61 (69.3)
Yes	27 (30.7)
New intracranial lesions appearing or progression/exacerbation of initial ones during treatment	n = 51
No	36 (70.6)
Yes	15 (29.4)
Outcomes (2 weeks)	
Survivors	89 (89.9)
Deaths	10 (10.1)
Patients lost to follow-up	2
Outcomes (8 weeks)	
Survivors	77 (81.1)
Deaths	18 (18.9)
Patients lost to follow-up	6
Outcomes (2 years)	
Survivors	73 (79.3)
Deaths	19 (20.7)
Patients lost to follow-up	9

Data are n, n (%), or median (interquartile range). *Two patients were followed up for more than 2 years because of the long term positive CSF Indian ink staining. One patient turned negative at 26 month's follow-up and the other was still positive at 36 month's CSF test. †It refers to any diagnosed *Mycobacterium tuberculosis* or non-tuberculosis mycobacteria infection during the whole treatment period. 5-FC: Flucytosine; V-P shunt: Ventriculo-peritoneal shunt; CSF: Cerebrospinal fluid.

mortality at 8 weeks and 2 years were 18.9% and 20.7%, respectively, which were lower than as compared to other studies (10-week mortality was 25%–43%).^[8-11] Nevertheless, the almost 20% mortality at 8 weeks demonstrated that HIV-associated CM carries high mortality even with standardized treatment, and further improvement in clinical management and clinical outcomes are needed. CSF fungal burden, altered mental status, and rate of yeast clearance have been shown to predict mortality in many studies.^[12-15] Consistent with previous studies, we found altered mental status as a risk factor for 8-week mortality. In addition, coinfection with PCP was associated with mortality at 8 weeks. This study found that mortality among HIV-associated CM patients with adequate treatment mainly occurred in the first 8 weeks, after which the mortality did not increase significantly. Therefore, measures taken to reduce mortality in the first 8 weeks after symptom onset are crucial to improve the prognosis.

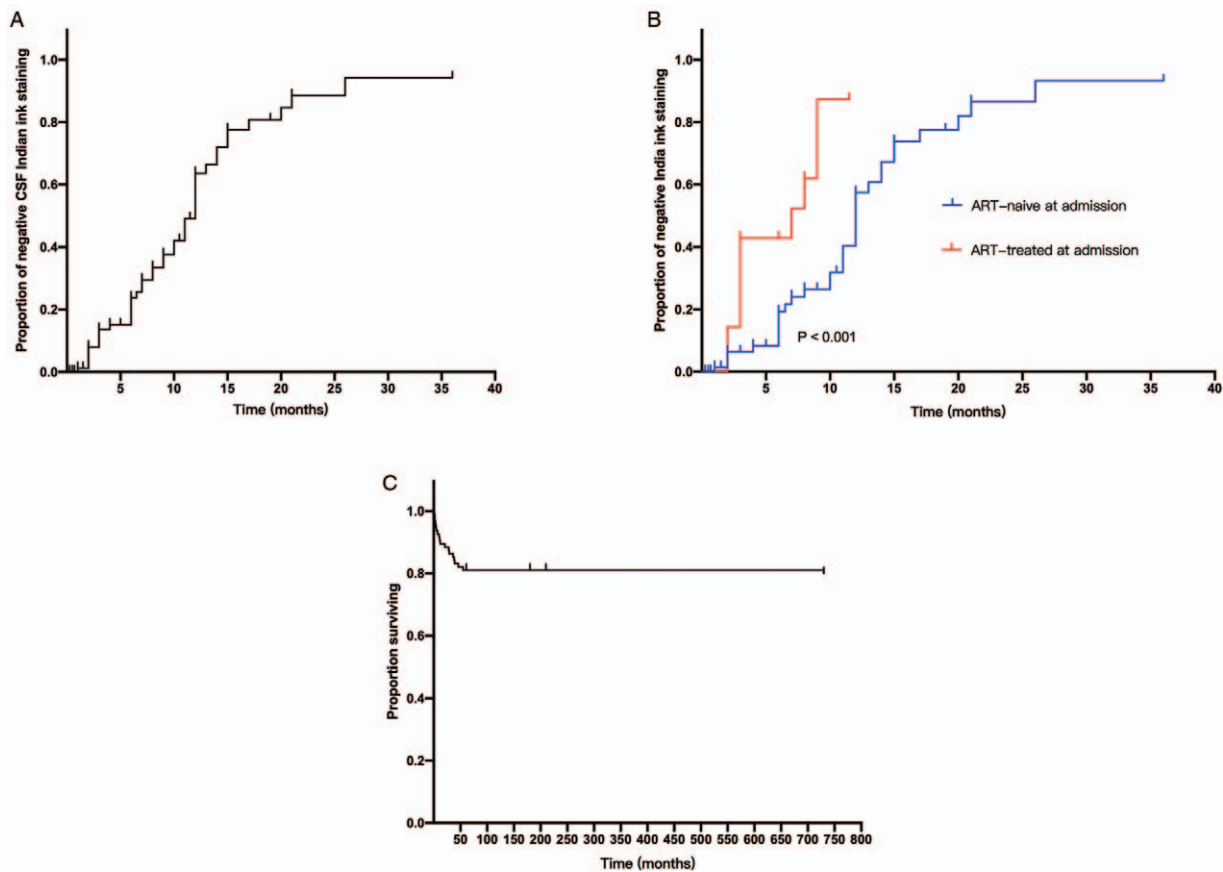


Figure 1: (A) After CSF Indian ink staining turning negative was defined as an event, Kaplan-Meier survival curve method was used to describe the duration of CSF Indian ink staining positive; (B) Proportion of negative India ink staining after treatment, grouped by whether patients had started ART on admission ($\chi^2 = 15.531$, $P < 0.001$); (C) Kaplan-Meier survival curve of 101 patients followed up for 2 years. ART: Antiretroviral therapy; CSF: Cerebrospinal fluid.

Early identification and diagnosis are critical for prompt treatment and better clinical outcomes. In our study, more than half of the patients were diagnosed at ≥ 14 days after the onset of CM, which may be an important cause of poor outcomes. High positivity rate of CSF cryptococcal antigen, CSF culture of *C. neoformans*, and CSF Indian ink staining were found in these patients, but most of them had concomitant normal CSF routine and biochemical examination. These findings suggest that identification of *Cryptococcus* species as a cause of meningitis and diagnosis of CM in these patients is feasible with appropriate specimens and diagnostic tests under compatible clinical context; while CSF routine and biochemical examination appear to have limited value in diagnosis. Neutrophil migration and fungistatic activity are impaired during HIV infection.^[16] Paucity of inflammatory response predisposes to normal CSF routine and biochemical examination results in these patients. Other studies have found that the levels of CSF white cell count and protein in HIV-associated CM patients are significantly lower than that of non-HIV-associated CM patients.^[17-21] The high positive rate of cryptococcaemia in blood culture of HIV-associated CM patients is another characteristic of the disease. Given that CSF fungal smear and fungal culture may have been limited by the availability of laboratory equipment and expertise, cryptococcal antigen test is a better choice for health care institutions with limited

resources. Cryptococcal antigen test is also recommended by the World Health Organization guidelines as screening to identify at-risk patients for cryptococcal infection when managing people presenting with advanced HIV disease.^[22]

In our study, low CD4 count is a salient feature of HIV-associated CM patients, most of whom were ART-naïve. Due to poor CSF cytokine responses, the time to negative CSF Indian ink staining in these patients is much longer, due to poor cryptococcus clearance, compared with non-HIV-associated CM patients. But these long-term fungal carriers have a good prognosis under maintenance of oral fluconazole. Therefore, time to the negativity of CSF culture for *C. neoformans* rather than Indian ink staining would be more appropriate to evaluate the efficacy of induction regimen, thereby guiding the treatment course of Low-dose AMB (25 mg/day). Of 15 ART-treated patients who developed HIV-associated CM, five were in virological failure with decreased CD4 count, and nine had ART-treated transiently (less than 12 weeks) after which they failed to rebuild immunity. Only one patient had ART-treated more than 1 year with 255 cells/mm³ CD4 count and 40 copies/mL viral load. Nevertheless, time to negative CSF Indian staining in ART-treated patients was significantly shorter than that of ART-naïve patients. This suggests that patients could still benefit from ART even

Table 4: Associations between demographics, clinical characteristics, and 8-week mortality.

Variables	n	8-week mortality	OR (95% CI), Univariable	P	AOR (95% CI), Multivariable	P
Age						
<50 years	81	14 (17.3)	1	0.326		
≥50 years	14	4 (28.6)	1.914 (0.524–6.987)			
Sex						
Female	13	4 (30.8)	1	0.250		
Male	82	14 (17.1)	0.463 (0.125–1.718)			
ART status						
ART-naïve	80	18 (22.5)	*	0.066		
ART-treated	15	0 (0.0)				
CD4 cell count						
<50 cells/ mm ³	81	16 (19.8)	*	0.119		
≥50 cells/ mm ³	12	0 (0.0)				
Hemoglobin						
≥90 g/L	85	13 (15.3)	1	0.128		
<90 g/L	8	3 (37.5)	3.323 (0.706–15.632)			
CSF white cell count						
<20 cells/mL	64	13 (20.3)	1	0.247		
≥20 cells/mL	29	3 (10.3)	0.453 (0.118–1.731)			
CSF protein						
<500 mg/L	65	11 (16.9)	1	0.854		
≥500 mg/L	27	5 (18.5)	1.116 (0.347–3.586)			
CSF glucose						
≥2.0 mmol/L	58	12 (20.7)	1	0.258		
<2.0 mmol/L	35	4 (11.4)	0.495 (0.146–1.675)			
Both CSF routine and biochemical examination were normal						
Yes	39	7 (17.9)	1	0.872		
No	54	9 (16.7)	0.914 (0.308–2.711)			
Time interval between onset and diagnosis of CM						
<14 days	41	4 (9.8)	1	0.055	1	0.055
≥14 days	54	14 (25.9)	3.237 (0.977–10.725)		3.787 (0.971–14.764)	
Coinfection with PCP on admission						
No	67	8 (11.9)	1	0.010	1	0.027
Yes	28	10 (35.7)	4.097 (1.407–11.934)		3.933 (1.166–13.269)	
Altered mental status on admission						
No	78	9 (11.5)	1	<0.001	1	0.001
Yes	17	9 (52.9)	8.625 (2.654–28.035)		9.574 (2.548–35.974)	
Complicated with cryptococcal pneumonia on admission						
No	52	4 (7.7)	1	0.170		
Yes	34	6 (17.6)	2.571 (0.669–9.902)			
Presence of abnormalities on intracranial imaging before treatment						
No	23	2 (8.7)	1	0.374		
Yes	48	8 (16.7)	2.100 (0.409–10.794)			
Treated with voriconazole at the first 2 weeks						
No	41	6 (14.6)	1	0.353		
Yes	54	12 (22.2)	1.667 (0.567–4.897)			
V-P shunt was performed						
No	84	16 (19.0)	1	0.945		
Yes	11	2 (18.2)	0.944 (0.186–4.801)			

* Since the death count within 8 weeks is zero, Fisher exact test was used. OR: Odds ratio; AOR: Adjusted odds ratio; CI: Confidence interval; ART: Antiretroviral therapy; CSF: Cerebrospinal fluid; CM: Cryptococcal meningitis; PCP: *Pneumocystis (carinii) jirovecii* pneumonia; V-P shunt: Ventriculo-peritoneal shunt.

Table 5: Comparison of adverse events between patients received 2-drug and 3-drug regimens.

Events	AMB + 5-FC (n = 42)*	VOR + (AMB + 5-FC) (n = 53)*	χ^2	P
Any event				
At least one event	41 (97.6)	51 (96.2)	0.15	0.699
No. of events	107	148		
Hypokalemia				
All grades	27 (62.8)	31/51 (60.8)	0.12	0.728
Grades 3 and 4	4 (9.3)	7/51 (13.7)	0.44	0.506
Elevated creatinine level				
All grades	7 (6.6)	4/52 (7.6)	0.06	0.800
Grades 3 and 4	2 (4.7)	2/52 (3.8)	0.04	0.834
Anemia				
All grades	31 (72.1)	37/51 (72.5)	0.02	0.891
Grades 3 and 4	15 (34.9)	14/51 (27.5)	0.70	0.401
Neutropenia				
All grades	9 (21.4)	14/51 (27.5)	0.38	0.537
Grades 3 and 4	4 (9.5)	5/51 (9.8)	0.00	0.963
Thrombocytopenia				
All grades	16 (37.2)	25/51 (49.0)	1.12	0.291
Grades 3 and 4	6 (13.9)	10/51 (19.6)	0.46	0.498
Elevated ALT level				
All grades	15 (34.8)	47/52 (90.4)	28.99	<0.001
Grades 3 and 4	5 (11.6)	5/52 (9.6)	0.18	0.672
Elevated total bilirubin level				
All grades	2 (4.6)	0/50 (0)	0.57	0.449
Grades 3 and 4	0 (0)	0/50 (0)		

Data are shown as n, n (%). *In all 101 cases, six patients died or left our hospital within 3 days (one died within 24 h after being hospitalized, two died within 2 days, two died within 3 days, and one left within 2 days). Since they had not been adequately treated and could not be used for evaluation, they were excluded. The final number of included cases was 95. AMB: Amphotericin B; 5-FC: Flucytosine; VOR: Voriconazole.

after treatment failure or transience. For patients with HIV-associated CM who have not yet started ART, current guidelines clearly state that ART should be started 4 to 6 weeks after anti-fungal treatment to reduce mortality.^[22]

HIV infected patients with severely impaired immune systems are susceptible to multiple infections. High rate of co-infection of PCP, cryptococcal pneumonia, and mycobacterium infection was found in patients of our study. High positive rate of cryptococcaemia in blood culture suggests that cryptococcal infection tends to result in systemic infection. All these factors affect patient's prognosis and increase the disease burden.

There are limited reports available on the impact of intracranial lesions in patients with HIV-associated CM on prognosis. In our retrospective data, as most patients had intracranial imaging abnormalities on admission, cryptococcal infection had to be excluded. The location of intracranial lesions on imaging may hint at diagnosis but is not specific nor diagnostic. Appearance of new intracranial lesions or progression/exacerbation of initial lesions occurred in some patients even with adequate treatment and a negative CSF culture. Some had aggravated or worsened clinical symptoms. Prior studies have shown that 8% to 49% of patients with HIV-associated CM developed immune reconstitution inflammatory syndrome (IRIS) after starting ART. The most common manifestations include aseptic meningitis and intracranial crypto-

coccomas.^[23] Therefore, most of these new intracranial lesions or exacerbated lesions may be the manifestation of HIV-associated CM-IRIS. In this study, lesion patients required maintenance anti-cryptococcal therapy and most resolved with good outcomes. Some studies have reported that 4.6% to 21.0% of intracranial lesions in patients with HIV-associated CM are caused by cryptococcal infection.^[24-27] We presume that the etiology of intracranial lesion is due to cryptococcal infection according to clinical symptoms and therapeutic response in our study. But definitive diagnosis of this finding needs pathological examination. Although many HIV-associated CM patients experienced new intracranial lesions or exacerbated intracranial lesions during the whole treatment course, it is not shown to have been associated with mortality in our study.

Intravenous infusion of conventional AMB (0.7–1.0 mg·kg⁻¹·d⁻¹) combined with oral administration of 5-FC (100 mg·kg⁻¹·d⁻¹) is the internationally recognized standard treatment for induction regimen.^[28,29] Nevertheless, more appropriate therapies in line with the realistic situation of each country and individualized treatment should be considered.^[30] Due to the relatively high adverse reactions of conventional AMB (especially nephrotoxicity) and no other choice of AMB formulation available in our hospital, low-dose conventional AMB (0.5–0.7 mg·kg⁻¹·d⁻¹) combined with standard dose of 5-FC for at least 4 weeks as induction therapy is recommended by Chinese expert consensus.^[31] The

efficacy of this regimen has been shown to be non-inferior to standard regimens in terms of mortality.^[32] Unfortunately, we did not find that additional usage of VOR in the first two weeks could reduce 8-week mortality. This could be due to bias in retrospective study related to regimen selection for patients. At the same time, there was no significant difference in adverse events between two groups with or without VOR. The major adverse events include hypokalemia, anemia, neutropenia, and thrombocytopenia. Although these events were frequently observed, development of grades 3 and 4 events leading to treatment interruption was rare, suggesting that the safety of low-dose AMB regimen with or without VOR during the induction phase is acceptable. Further clinical studies are needed to confirm if additional usage of VOR in the induction regimen can improve the outcomes of HIV-associated CM patients.

The limitation of this study includes the retrospective study design, which may have also limited the statistical significance of factors such as CSF fungal clearance that could be used in the evaluation of treatment efficacy. The sample size may have limited the power of study to uncover statistical significance of factors associated with mortality. During the 2-year follow-up, less than half of the patients were CSF negative for CSF Indian ink staining at the last possible lumbar puncture; clinically improved patients refused to proceed with further invasive examination. Therefore, it is difficult to assess time to CSF clearance of cryptococcus and its related factors. Meanwhile, the causes of intracranial lesions and exacerbation of initial lesions after treatment in patients with HIV-associated CM are yet to be elucidated in prospective randomized controlled trials.

In conclusion, this study described the clinical features and outcomes of first-diagnosed HIV-associated CM with 2-year follow-up data. Low CD4 count, long time interval between onset to diagnosis, common abnormal findings in intracranial imaging, poor inflammatory changes in CSF, high positive rate of cryptococcaemia in blood culture, and high mortality at the first 8 weeks have been shown in our study. The time to clearance of cryptococcus in CSF is long. ART treatment before disease onset helps to shorten such duration. Altered mental status and coinfection with PCP are risk factors for mortality.

Acknowledgements

The authors acknowledge Joshua B. Mendelsohn (College of Health Professions, Pace University, New York, USA) for reviewing this manuscript.

Funding

This work was supported by grants from the Medical Guidance Support Project of Shanghai Science and Technology Commission (No. 17411969600), "Tomorrow Star" Famous Medical Clinicians' Cultivation Project of Fudan University (No. RC-QT-2019-01), and Key Research Grant from the Ministry of Science and Technology, the People's Republic of China (No. 2017ZX10202101).

Conflicts of interest

None.

References

- Ford N, Shubber Z, Jarvis JN, Chiller T, Greene G, Migone C, *et al.* CD4 cell count threshold for cryptococcal antigen screening of HIV-infected individuals: a systematic review and meta-analysis. *Clin Infect Dis* 2018;66 (Suppl_2):S152–S159. doi: 10.1093/cid/cix1143.
- Rajasingham R, Smith RM, Park BJ, Jarvis JN, Govender NP, Chiller TM, *et al.* Global burden of disease of HIV-associated cryptococcal meningitis: an updated analysis. *Lancet Infect Dis* 2017;17:873–881. doi: 10.1016/S1473-3099(17)30243-8.
- Guan L, Lu H, Shen Y, Liu L, Qi T, Song W, *et al.* Spectrum of central nervous system disorders in the first hospitalized HIV/AIDS patients. *Chin J AIDS STD* 2016;22:510–513. doi: 10.13419/j.cnki.aids.2016.07.07.
- Durski KN, Kuntz KM, Yasukawa K, Virnig BA, Meya DB, Boulware DR. Cost-effective diagnostic checklists for meningitis in resource-limited settings. *J Acquir Immune Defic Syndr* 2013;63:e101–e108. doi: 10.1097/QAI.0b013e31828e1e56.
- Jarvis JN, Meintjes G, Williams A, Brown Y, Crede T, Harrison TS. Adult meningitis in a setting of high HIV and TB prevalence: findings from 4961 suspected cases. *BMC Infect Dis* 2010;10:67. doi: 10.1186/1471-2334-10-67.
- Siddiqi OK, Ghebremichael M, Dang X, Atadzhanov M, Kaonga P, Khoury MN, *et al.* Molecular diagnosis of central nervous system opportunistic infections in HIV-infected Zambian adults. *Clin Infect Dis* 2014;58:1771–1777. doi: 10.1093/cid/ciu191.
- Division of AIDS (DAIDS) Table for Grading the Severity of Adult and Pediatric Adverse Events, Corrected Version 2.1. U.S. Department of Health and Human Services, National Institutes of Health, National Institute of Allergy and Infectious Diseases, Division of AIDS, 2017. Available from: <https://rsc.niaid.nih.gov/sites/default/files/daidsgradingcorrectedv21.pdf>. [Accessed August 15, 2020].
- Loyse A, Wilson D, Meintjes G, Jarvis JN, Bicanic T, Bishop L, *et al.* Comparison of the early fungicidal activity of high-dose fluconazole, voriconazole, and flucytosine as second-line drugs given in combination with amphotericin B for the treatment of HIV-associated cryptococcal meningitis. *Clin Infect Dis* 2012;54:121–128. doi: 10.1093/cid/cir745.
- Day JN, Chau TTH, Wolbers M, Mai PP, Dung NT, Mai NH, *et al.* Combination antifungal therapy for cryptococcal meningitis. *N Engl J Med* 2013;368:1291–1302. doi: 10.1056/NEJMoa1110404.
- Molloy SF, Kanyama C, Heyderman RS, Loyse A, Kouanfack C, Chanda D, *et al.* Antifungal combinations for treatment of cryptococcal meningitis in Africa. *N Engl J Med* 2018;378:1004–1017. doi: 10.1056/NEJMoa1710922.
- Beardsley J, Wolbers M, Kibengo FM, Ggayi AB, Kamali A, Cuc NT, *et al.* Adjunctive dexamethasone in HIV-associated cryptococcal meningitis. *N Engl J Med* 2016;374:542–554. doi: 10.1056/NEJMoa1509024.
- Jarvis JN, Bicanic T, Loyse A, Namarika D, Jackson A, Nussbaum JC, *et al.* Determinants of mortality in a combined cohort of 501 patients with HIV-associated Cryptococcal meningitis: implications for improving outcomes. *Clin Infect Dis* 2014;58:736–745. doi: 10.1093/cid/cit794.
- Bicanic T, Muzoora C, Brouwer AE, Meintjes G, Longley N, Taseera K, *et al.* Independent association between rate of clearance of infection and clinical outcome of HIV-associated cryptococcal meningitis: analysis of a combined cohort of 262 patients. *Clin Infect Dis* 2009;49:702–709. doi: 10.1086/604716.
- Pitisuttithum P, Tansuphasawadikul S, Simpson AJ, Howe PA, White NJ. A prospective study of AIDS-associated cryptococcal meningitis in Thailand treated with high-dose amphotericin B. *J Infect* 2001;43:226–233. doi: 10.1053/jinf.2001.0916.
- Dromer F, Mathoulin-Pélissier S, Launay O, Lortholary O. Determinants of disease presentation and outcome during cryptococcosis: the CryptoA/D study. *PLoS Med* 2007;4:e21. doi: 10.1371/journal.pmed.0040021.
- Coffey MJ, Phare SM, George S, Peters-Golden M, Kazanjian PH. Granulocyte colony-stimulating factor administration to HIV-infected subjects augments reduced leukotriene synthesis and anticryptococcal activity in neutrophils. *J Clin Invest* 1998;102:663–670. doi: 10.1172/JCI2117.

17. Bicanic T, Meintjes G, Rebe K, Williams A, Loyse A, Wood R, *et al*. Immune reconstitution inflammatory syndrome in HIV-associated cryptococcal meningitis: a prospective study. *J Acquir Immune Defic Syndr* 2009;51:130–134. doi: 10.1097/QAI.0b013e3181a56f2e.
18. Chang CC, Dorasamy AA, Gosnell BI, Elliott JH, Spelman T, Omarjee S, *et al*. Clinical and mycological predictors of cryptococcosis-associated immune reconstitution inflammatory syndrome. *AIDS* 2013;27:2089–2099. doi: 10.1097/QAD.0b013e3283614a8d.
19. Boulware DR, Bonham SC, Meya DB, Wiesner DL, Park GS, Kambugu A, *et al*. Paucity of initial cerebrospinal fluid inflammation in cryptococcal meningitis is associated with subsequent immune reconstitution inflammatory syndrome. *J Infect Dis* 2010;202:962–970. doi: 10.1086/655785.
20. Lee YC, Wang JT, Sun HY, Chen YC. Comparisons of clinical features and mortality of cryptococcal meningitis between patients with and without human immunodeficiency virus infection. *J Microbiol Immunol Infect* 2011;44:338–345. doi: 10.1016/j.jmii.2010.08.011.
21. Liu Y, Kang M, Wu SY, Ma Y, Chen ZX, Xie Y, *et al*. Different characteristics of cryptococcal meningitis between HIV-infected and HIV-uninfected patients in the Southwest of China. *Med Mycol* 2017;55:255–261. doi: 10.1093/mmy/myw075.
22. Guidelines for the Diagnosis, Prevention, and Management of Cryptococcal Disease in HIV-Infected adults, Adolescents and Children: Supplement to the 2016 Consolidated Guidelines of the Use of Antiretroviral Drugs for Treating and Preventing HIV Infection. Geneva: World Health Organization; 2018. Available from: <https://apps.who.int/iris/handle/10665/260399>. [Accessed August 15, 2020]
23. Haddow LJ, Colebunders R, Meintjes G, Lawn SD, Elliott JH, Manabe YC, *et al*. Cryptococcal immune reconstitution inflammatory syndrome in HIV-1-infected individuals: proposed clinical case definitions. *Lancet Infect Dis* 2010;10:791–802. doi: 10.1016/S1473-3099(10)70170-5.
24. Chen S, Sorrell T, Nimmo G, Speed B, Currie B, Ellis D, *et al*. Epidemiology and host- and variety-dependent characteristics of infection due to *Cryptococcus neoformans* in Australia and New Zealand. Australasian Cryptococcal Study Group. *Clin Infect Dis* 2000;31:499–508. doi: 10.1086/313992.
25. Kure K, Llana JF, Lyman WD, Soeiro R, Weidenheim KM, Hirano A, *et al*. Human immunodeficiency virus-1 infection of the nervous system: an autopsy study of 268 adult, pediatric, and fetal brains. *Hum Pathol* 1991;22:700–710. doi: 10.1016/0046-8177(91)90293-x.
26. Charlier C, Dromer F, Lévêque C, Chartier L, Cordoliani YS, Fontanet A, *et al*. Cryptococcal neuroradiological lesions correlate with severity during cryptococcal meningoencephalitis in HIV-positive patients in the HAART era. *PLoS One* 2008;3:e1950. doi: 10.1371/journal.pone.0001950.
27. Choe PG, Park WB, Song JS, Song KH, Jeon JH, Park SW, *et al*. Spectrum of intracranial parenchymal lesions in patients with human immunodeficiency virus infection in the Republic of Korea. *J Korean Med Sci* 2010;25:1005–1010. doi: 10.3346/jkms.2010.25.7.1005.
28. Makadzange AT, McHugh G. New approaches to the diagnosis and treatment of cryptococcal meningitis. *Semin Neurol* 2014;34:47–60. doi: 10.1055/s-0034-1372342.
29. Perfect JR, Dismukes WE, Dromer F, Goldman DL, Graybill JR, Hamill RJ, *et al*. Clinical practice guidelines for the management of cryptococcal disease: 2010 update by the Infectious Diseases Society of America. *Clin Infect Dis* 2010;50:291–322. doi: 10.1086/649858.
30. Wu X, Shen Y. Management of human immunodeficiency virus-associated cryptococcal meningitis: current status and future directions. *Mycoses* 2019;62:874–882. doi: 10.1111/myc.12977.
31. Liu ZY, Wang GQ, Zhu LP, Lyu XJ, Zhang QQ, Yu YS, *et al*. Expert consensus on the diagnosis and treatment of cryptococcal meningitis (in Chinese). *Chin J Intern Med* 2018;57:317–323. doi: 10.3760/cma.j.issn.0578-1426.2018.05.003.
32. Yan D, Huang JR, Lian JS, Li LJ. Treatment of cryptococcal meningitis with low-dose amphotericin B and flucytosine. *Chin Med J* 2012;125:385–387. doi:10.3760/cma.j.issn.0366-6999.2012.02.038.

How to cite this article: Song W, Shen YZ, Wang ZY, Qi TK, Liu L, Zhang RF, Wang JR, Tang Y, Chen J, Sun JJ, Lu HZ. Clinical features and treatment outcomes of human immunodeficiency virus-associated cryptococcal meningitis: a 2-year retrospective analysis. *Chin Med J* 2020;133:2787–2795. doi: 10.1097/CM9.0000000000001191