

Cryospray ablation using pressurized CO₂ for ablation of Barrett's esophagus with early neoplasia: early termination of a prospective series

Authors

Romy E. Verbeek¹, Frank P. Vleggaar¹, Fiebo J. ten Kate², Jantine W.P.M. van Baal¹, Peter D. Siersema¹

Institutions

¹ Department of Gastroenterology and Hepatology, University Medical Center Utrecht, Utrecht, The Netherlands
² Department of Pathology, University Medical Center Utrecht, Utrecht, The Netherlands

submitted 29. May 2014
accepted after revision
27. August 2014

Bibliography

DOI <http://dx.doi.org/10.1055/s-0034-1390759>
Published online: 27.2.2015
Endoscopy International Open 2015; 03: E107–E112
© Georg Thieme Verlag KG
Stuttgart · New York
E-ISSN 2196-9736

Corresponding author

Romy E. Verbeek, MD
Department of
Gastroenterology and
Hepatology (F02.618)
University Medical Center
Utrecht
P.O. Box 85500
3508 GA Utrecht
The Netherlands
Fax: +31-88-755533
R.E.Verbeek@umcutrecht.nl

Background: Cryotherapy is a relatively novel ablation modality for the endoscopic ablation of Barrett's esophagus (BE). Data on the use of pressurized carbon dioxide (CO₂) gas for cryoablation are scarce.

Study aim: To determine the efficacy and safety of cryospray ablation using pressurized CO₂ gas in the treatment of BE with early neoplasia.

Methods: In this prospective single center case series, we aimed to include 30 patients with BE and early neoplasia. Nodular neoplastic lesions were treated with endoscopic mucosal resection (EMR). Residual BE mucosa was treated with cryospray ablation every 4 weeks until the complete BE segment was eliminated or up to seven treatment sessions. If no reduction of the BE segment was observed after two subsequent treatment sessions, cryoablation was terminated. Patients were contacted at days 1 and 4 post-treatment to evaluate the level of discomfort. Endoscopic and histologic follow-up evaluations were performed up to 24 months post-treatment.

Results: After the inclusion of 10 patients, insuffi-

cient effect of cryoablation was observed, resulting in early termination of the study. In total, seven patients with intramucosal carcinoma (IMC) and three with high grade dysplasia (HGD) were included. Prior EMR was performed in nine patients. A median of 2.5 (IQR 2.0–4.0) cryoablation sessions were performed. At 6 months of follow-up, complete eradication of intestinal metaplasia was observed in 11% (1/9); one patient died, not treatment or disease related) of the patients and complete eradication of dysplasia in 44% (4/9). In three patients, HGD or IMC was detected during follow-up, and was endoscopically treated. Apart from a gastric perforation as a result of gastric distension caused by CO₂ gas during the first treatment, cryospray treatments were well tolerated.

Conclusion: After a short learning curve, cryoablation using CO₂ gas was found to be a safe and well tolerated treatment modality. However, in our experience, the efficacy of CO₂ cryoablation combined with EMR for nodular lesions is disappointing for the treatment of BE associated neoplasia.

Introduction

Barrett's esophagus (BE), defined as the presence of specialized intestinal metaplasia (IM) in the distal esophagus, is associated with an increased risk of neoplastic progression [1]. In the past decades, endoscopic modalities have been developed to treat early neoplastic lesions in order to prevent progression to invasive esophageal adenocarcinoma [2]. Nodular lesions can be treated successfully with endoscopic mucosal resection (EMR) [3]. Various ablative techniques, including radiofrequency ablation (RFA), photodynamic therapy, and argon plasma coagulation (APC), have been introduced to eradicate the BE mucosa, which is harmful to the original normal squamous epithelium, however, there is still room for improvement [4–6].

Cryotherapy is a relatively new modality for the endoscopic ablation of BE. Results based on a device using liquid nitrogen as cryogen have been shown to be promising, with high rates of eradication of high grade dysplasia (HGD) and IM [7, 8]. Data on the use of pressurized carbon dioxide (CO₂) gas for cryoablation are scarce. Promising results have been presented during conferences [9, 10]; however, apart from one pilot study including patients with BE with or without low grade dysplasia (LGD) [11], no results have been published. The aim of this study was to determine the efficacy and safety of cryospray ablation using pressurized CO₂ gas in the treatment of BE with early neoplasia.

License terms





Fig. 1 The Polar Wand CO₂ cryotherapy system. **a** The front of the portable system. **b** The tank with the compressed CO₂ gas and the disposable suction bottle at the back of the system, and the foot pedal to apply the gas flow. **c** The 7-French flexible cryospray catheter, which is introduced through the working channel of the endoscope.

Patients and methods

In this prospective single center case series, we aimed to include 30 consecutive treatment naive patients with BE and HGD or intramucosal carcinoma (IMC). The sample size of this pilot study was not optimized for hypothesis testing but was based on previous cryoablation studies [7, 11, 12]. Since this is a post-market study of a Food and Drug Administration approved device, which was used in accordance with its “instructions for use” under conditions of standard medical practice, no additional institutional review board approval or trial registration was required according to Dutch regulations.

Exclusion criteria were prior ablative or radiation therapy, and surgery involving the esophagus. Nodular-appearing abnormalities or lesions were first removed by a cap-assisted EMR procedure.

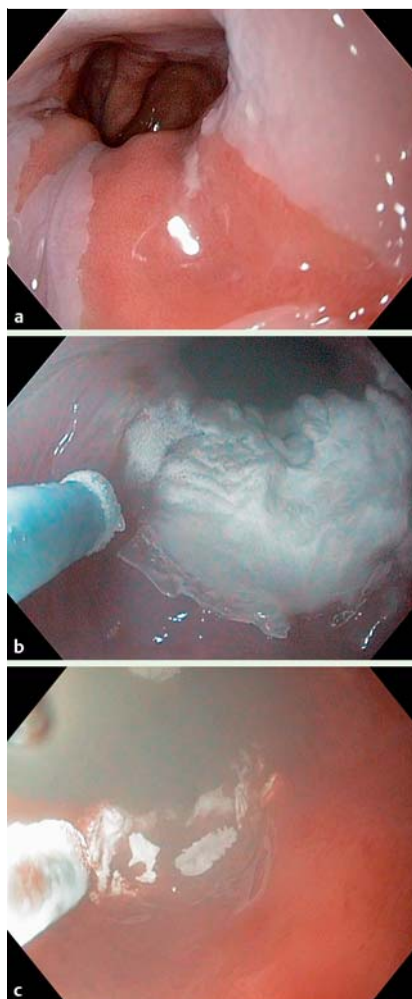


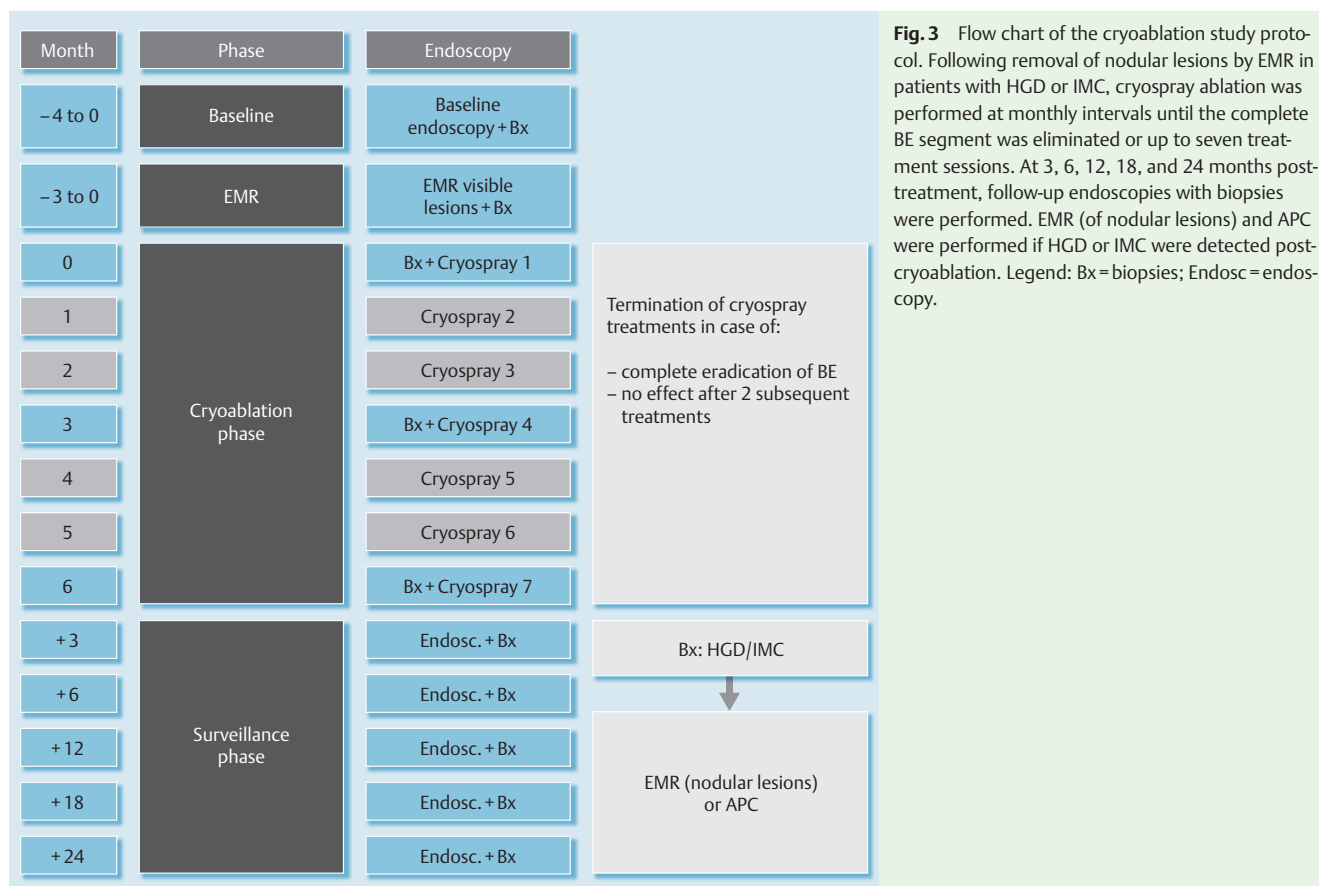
Fig. 2 Application of the pressurized CO₂ gas. **a** Endoscopic view of the BE segment. **b** The release of the pressurized CO₂ gas results in freezing of the mucosa. **c** After 20 seconds of freezing, the CO₂ release is interrupted, resulting in thawing of the mucosa.

The residual BE mucosa was treated with cryospray ablation using pressurized CO₂ gas as cryogen (Polar Wand, GI Supply, Camp Hill, Pennsylvania, United States; ● Fig. 1) within 3 months following EMR. The Polar Wand cryoablation device is Food and Drug Administration approved for treatment of esophageal lesions. Informed consent was obtained from each patient. The principle of CO₂ cryoablation is based on repeated cycles of rapid freezing and thawing, resulting in apoptosis and destruction of the BE mucosa. The compressed CO₂ gas is stored at room temperature. A 7-French cryospray catheter is introduced through the working channel and a suction catheter is attached to the tip of the endoscope. The release of the pressurized CO₂ gas at the mucosal surface results in a rapid temperature drop to -78°C (Joule Thompson effect) and subsequent freezing of the mucosa (● Fig. 2). Cryospray ablation was performed at monthly intervals until the complete BE segment was eliminated or up to seven treatment sessions (● Fig. 3). If no reduction of the BE segment

Video 1

The tip of the cryospray catheter, introduced through the working channel of the endoscope, is shown on the left. The release of the CO₂ gas at the mucosal surface results in freezing of the BE tissue. Cryoablation for 20 seconds is followed by active suctioning of the stomach to avoid extensive gastric distension.

online content including video sequences viewable at:
www.thieme-connect.de



was observed after two subsequent treatment sessions, cryoablation was terminated to minimize the burden to patients. Cryoablation treatments consisted of six applications with a CO₂ catheter per 2–3 cm hemi-circumferential BE segment during 20 seconds, with active suctioning of the stomach between applications (▶ **Video 1**, Supplementary Material). Midazolam or propofol were used as sedative agents during the cryospray treatments. All procedures were performed by two experienced endoscopists (PS and FV). During the cryoablation phase, proton pump inhibitors were prescribed in a dose of 40mg twice daily. Patients were contacted on day 1 and day 4 post-treatment to evaluate the level of discomfort using a questionnaire, which was based on previous cryoablation studies [7,12]. Biopsies of BE and neo-squamous epithelium were obtained from four quadrants at 1–2 cm distance along the whole BE segment, either existent and/or ablated, before the 1st (following EMR), 4th, and 7th treatment and at 3, 6, 12, 18, and 24 months post-treatment using a disposable large capacity forceps. All histopathological sections were evaluated by an expert pathologist (FK). EMR (of nodular lesions) and APC were performed in the case of HGD or IMC detection post-cryoablation. The primary outcome measure was complete eradication of IM at 6 months of follow-up. Additional outcome measures were complete eradication of dysplasia (including indefinite for dysplasia (IFD), LGD and HGD) at 6 months of follow-up, complete eradication of IM and dysplasia at 12 and 24 months of follow-up, endoscopic reduction of the BE segment length, progression, and occurrence of adverse events. Patients with complete eradication of IM also had dysplasia completely eradicated and were included in both end points.

Results

After the inclusion of 10 patients between January 2011 and September 2011, insufficient effect of cryoablation was observed, which resulted in the decision to terminate the inclusion of patients early. In total, seven patients with IMC and three with HGD were included with a mean age (± standard deviation (SD)) of 71 (±9) years. Before cryoablation, a single EMR procedure was performed in nine patients. No nodular lesions were observed following EMR, before cryospray treatments. Pre-cryoablation diagnoses were IM (n=4), LGD (n=5), and HGD (n=1). A median of 2.5 (interquartile range (IQR) 2.0–4.0) cryoablation sessions were performed. Cryoablation treatments were terminated when the BE segment was completely eradicated in two patients, when the maximum of seven treatments was performed in two patients, when no effect was observed after two subsequent treatment sessions in five patients, and when treatment was complicated by a gastric perforation in one patient. Propofol was used in 9 of the 32 cryospray procedures in a total of three patients. In the remaining cryoablation treatments, patients were sedated with Midazolam. A non-significant reduction of the BE segment length was observed following cryoablation treatments 5.0 (IQR 1.8–7.3) cm pre-cryoablation vs. 2.5 (IQR 0.9–6.3) cm 3 months post-cryoablation, *P*=0.08). Three patients died and were subsequently censored and excluded from data analysis at 6 (n=1) and 24 months (n=2) of follow-up. Their causes of death were not related to esophageal neoplasia or cryoablation treatment but were the result of pneumonia, primary lung cancer, and necrotizing fasciitis after resection of a skin lesion. Complete eradication of IM was observed in 11% (1/9; one patient died) and complete eradication of dysplasia in 44%

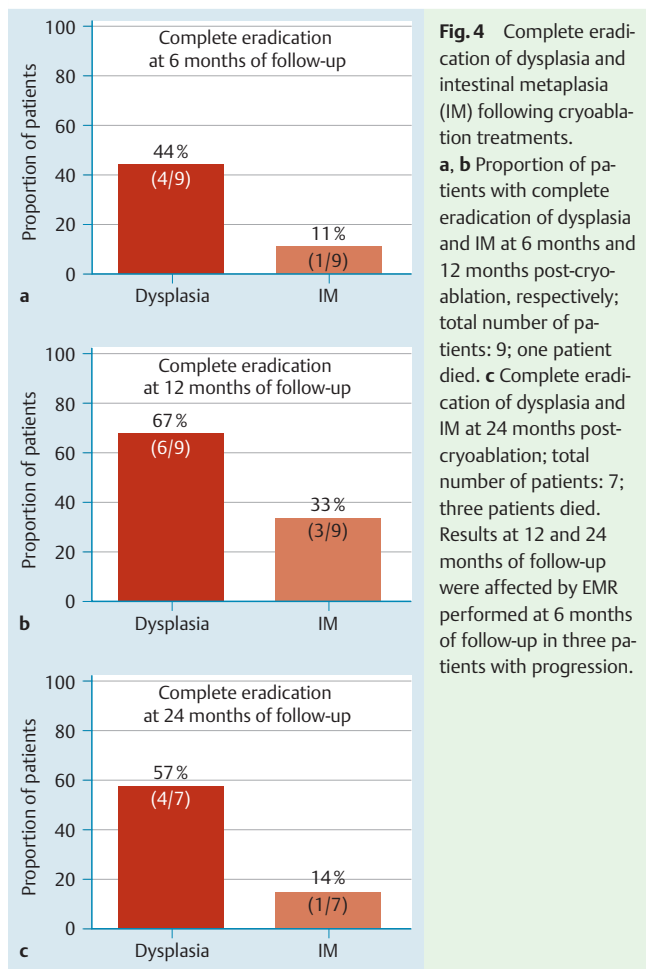


Fig. 4 Complete eradication of dysplasia and intestinal metaplasia (IM) following cryoablation treatments.

a, b Proportion of patients with complete eradication of dysplasia and IM at 6 months and 12 months post-cryoablation, respectively; total number of patients: 9; one patient died. **c** Complete eradication of dysplasia and IM at 24 months post-cryoablation; total number of patients: 7; three patients died. Results at 12 and 24 months of follow-up were affected by EMR performed at 6 months of follow-up in three patients with progression.

(4/9) of the patients at 6 months of follow-up (● Fig. 4). In three patients, HGD or IMC was detected during follow-up, which was treated with EMR ($n=3$; at 6 months of follow-up) and APC ($n=1$; at 24 months of follow-up) (● Table 1). Complete eradication of IM and dysplasia at 12 and 24 months of follow-up was affected by treatment performed in these three patients with progression (● Fig. 4). No buried BE glands were detected in the ablated segments during follow-up. In one patient, a longitudinal perforation along the lesser curvature of the stomach was detected 1 day after the first ablation treatment, comprising six cryospray applications of a hemi-circumferential BE segment of 1 cm. Following surgical intervention, no further cryoablation was applied in this patient. In another two patients, the first cryoablation treatment was complicated by a superficial esophageal laceration without the need for intervention. In 6/32 (19%) cryospray treatments, patients complained of mild retrosternal pain and in 6/32 (19%) and 7/32 (22%) of self-limiting odynophagia and dysphagia, respectively, in the first 1 to 4 days post-treatment. No strictures were detected.

Discussion

Various endoscopic therapies have been developed for the ablation of BE. Cryotherapy is a relatively new non-contact ablative modality with two different systems based on liquid nitrogen or pressurized CO₂ gas. This is the first report on the use of cryoablation based on pressurized CO₂ combined with EMR for nodular

lesions in the treatment of BE associated neoplasia. In our experience, the effect of CO₂ cryotherapy was disappointing, with complete eradication of IM and dysplasia at 6 months of follow-up in only 11% and 44% of the patients, respectively. Additionally, HGD or IMC was detected at 6 months of follow-up in 33% of patients. Based on the time after initial treatment, these are most likely “incident” cancers as a result of progression during and after cryoablation. However, it cannot be excluded that these may have been missed during prior endoscopy despite extensive endoscopic and biopsy protocols; in that case, these lesions should be classified as “prevalent cancers”. The inclusion of patients was terminated prematurely because of insufficient efficacy.

Only one previous study has been published using pressurized CO₂ for the ablation of BE and associated LGD [11]. Xue et al. reported complete eradication of LGD in 100% (6/6) and complete eradication of IM in 85% (17/20) of the cases at 6 months of follow-up in a prospective case series. Possible explanations for the better outcome in the study by Xue et al. may be the inclusion of cases with only BE and LGD with shorter BE segments, which may be, at least theoretically, easier to ablate, the relatively short follow-up period, the less thorough follow-up biopsy protocol, the presence of persistent endoscopic signs of BE in the majority of cases but with eradication of IM at histologic evaluation, and the younger and Asian study population. Additionally, CO₂ dosimetry was not clearly documented by Xue et al.

In contrast, results based on the liquid nitrogen device (CSA Medical Inc, Baltimore, Maryland, United States) are promising. Three studies using this system, both single-center and multi-center with relatively large patient samples ($n=30-98$), have been published [7,8,12]. Dumot et al. included inoperable patients with BE and HGD or IMC and demonstrated downgrading of the histopathology stage in 68% of HGD and 80% of IMC patients after cryoablation treatment during a median follow-up period of 12 months [12]. Others showed complete eradication of HGD in 97–100% of the patients, complete eradication of all dysplasia in 87% and complete eradication of IM in 57–84% during a median follow-up of 10 months to 24 months [7,8].

The device used in these studies delivers liquid nitrogen at a temperature of -196°C at the mucosa [7,8,12], while mucosal freezing is achieved at -78°C using the pressurized CO₂ system. It may well be that the relatively “less cold” temperature with CO₂ cryoablation affects the depth and degree of mucosal injury. Studies comparing the two types of cryoablation devices have not been performed.

CO₂ dosimetry in our study was based on previous cryoablation studies and on testing experiments in a pig model resulting in mucosal, submucosal, and transmural necrosis following 15, 30, and 120 seconds, respectively, of cryoablation [7–13]. We assumed that repeated cycles of 20 seconds of cryospray treatment would ablate the complete mucosal layer in BE. A longer period of continuous CO₂ cryospray ablation is not recommended as the gas inflated at a flow of 8L/min results in considerable gastric distension. The effect of the suction catheter attached to the tip of the endoscope is only minimal.

The first treatment session in our study was complicated by gastric perforation and a gastric and esophageal laceration. We are convinced that this can be attributed to the learning curve, with extra time needed to adequately position the catheter to achieve the ice-effect, which resulted in the accumulation of more CO₂ gas and increased gastroesophageal distension. Perforation may be prevented by accurate positioning of the cryospray catheter

Table 1 Characteristics of patients undergoing CO₂ cryoablation

Case	Age, y	Sex	Pre-cryoablation		Cryoablation		Post-cryoablation		6 Months		12 Months		24 Months		Adverse event
			EMR	Length, cm	Length, cm	Histology	No. of Tx	Length, cm	Histology	Length, cm	Histology	Length, cm	Histology	Length, cm	
1	59	M	IMC	2	IM	3	0.5	GM	0.5	HGD>EMR	0.5	GM	0.5	IM	-
2	72	M	IMC	7	LGD	2	7	LGD	7	IFD	8	LGD	8	LGD	-
3	73	M	HGD	1.7	IM	7	7	IM	7	IMC>EMR	9	IFD	8	HGD>APC	-
4	72	M	IMC	1	IM	1	1	IM	1	IM	1	IM	1	IM	Perforation
5	59	M	IMC	6	LGD	7	1	IM	1	IM	1	IM	2	IM	Laceration
6	81	M	IMC	1	IM	2	1	IM	1	IM	1	GM	†	-	Laceration
7	83	M	IMC	8	LGD	3	6	LGD	6	IMC>EMR	6	IM	†	-	-
8	60	F	-	6	HGD	2	6	LGD	6	LGD	6	LGD	6	LGD	-
9	81	M	IMC	4	IM	2	4	IM	†	-	†	-	†	-	-
10	69	F	HGD	4	IM	3	0.5	IM	0.5	GM	1	GM	1	GM	-

APC, argon plasma coagulation; EMR, endoscopic mucosal resection; F, female; GM, gastric metaplasia/gastric type of epithelium in the distal esophagus; HGD, high grade dysplasia; IFD, indefinite for dysplasia; IM, intestinal metaplasia; IMC, intramucosal carcinoma; LGD, low grade dysplasia; M, male; Tx, treatments; †, deceased patient. All adverse events occurred during the first cryoablation treatment. Progression to HGD or IMC during follow-up was treated with EMR or APC.

before activation of the gas flow, and by limiting the duration of CO₂ spraying to 20 seconds per application, which reduces accumulation of CO₂ gas and subsequent distension of the esophagus and stomach. Active suctioning of the stomach between cryospray applications was included in the study protocol to limit the perforation risk. Besides gastric perforation, cryospray treatments were well tolerated, with only mild retrosternal pain, odynophagia, and dysphagia in a minority of the patients, which is comparable to the number of adverse events reported by Xue et al. [11]. Additionally, no strictures were detected in both CO₂ cryotherapy studies. In studies using liquid nitrogen cryoablation, strictures and severe retrosternal pain were reported in a small number of patients [7, 8], again suggesting more severe mucosal injury with liquid nitrogen cryoablation compared to CO₂ cryoablation.

The advantages of CO₂ cryoablation are the lower costs and the ease in controlling the endoscope because of less stiffness and cold when compared to the liquid nitrogen device. Advantages of cryoablation above RFA are the non-contact method facilitating ablation of the irregularly lined mucosa, the adjustable dosimetry, the lower costs and, by no means least, cryoablation is considered less painful [14, 15].

In conclusion, after a short learning curve, cryoablation using CO₂ gas was found to be a safe and well-tolerated treatment modality. However, in our experience, the efficacy of CO₂ cryoablation combined with EMR for nodular lesions is disappointing for the treatment of BE associated neoplasia.

Competing interests: PD Siersema has received unrestricted research grant support from Astra Zeneca BV and Shire BV, The Netherlands. The other authors have nothing to disclose.

Acknowledgments

The authors thank GI Supply (Camp Hill, Pennsylvania, USA) for providing the Polar Wand CO₂ cryoablation system.

References

- Guillem PG. How to make a Barrett esophagus: pathophysiology of columnar metaplasia of the esophagus. *Dig Dis Sci* 2005; 50: 415–424
- Konda VJ, Waxman I. Endotherapy for Barrett's esophagus. *Am J Gastroenterol* 2012; 107: 827–833
- Tomizawa Y, Iyer PG, Wong Kee Song LM et al. Safety of endoscopic mucosal resection for Barrett's esophagus. *Am J Gastroenterol* 2013; 108: 1440–1447
- Manner H, Rabenstein T, Pech O et al. Ablation of residual Barrett's epithelium after endoscopic resection: a randomized long-term follow-up study of argon plasma coagulation vs. surveillance (APE study). *Endoscopy* 2014; 46: 6–12
- Orman ES, Li N, Shaheen NJ. Efficacy and durability of radiofrequency ablation for Barrett's Esophagus: systematic review and meta-analysis. *Clin Gastroenterol Hepatol* 2013; 11: 1245–1255
- Overholt BF, Wang KK, Burdick JS et al. Five-year efficacy and safety of photodynamic therapy with Photofrin in Barrett's high-grade dysplasia. *Gastrointest Endosc* 2007; 66: 460–468
- Gosain S, Mercer K, Twaddell WS et al. Liquid nitrogen spray cryotherapy in Barrett's esophagus with high-grade dysplasia: long-term results. *Gastrointest Endosc* 2013; 78: 260–265
- Shaheen NJ, Greenwald BD, Peery AF et al. Safety and efficacy of endoscopic spray cryotherapy for Barrett's esophagus with high-grade dysplasia. *Gastrointest Endosc* 2010; 71: 680–685
- Canto MI, Dunbar KB, Okolo P et al. Low flow CO₂-cryotherapy for high risk Barrett's esophagus (BE) patients with high grade dysplasia and early adenocarcinoma: a pilot trial of feasibility and safety. *Gastrointest Endosc* 2008; 67: AB179–AB180

- 10 *Canto MI, Gorospe EC, Shin EJ et al.* Carbon dioxide (CO₂) cryotherapy is a safe and effective treatment of Barrett's esophagus (BE) with HGD/intramucosal carcinoma. *Gastrointest Endosc* 2009; 69: AB341
- 11 *Xue HB, Tan HH, Liu WZ et al.* A pilot study of endoscopic spray cryotherapy by pressurized carbon dioxide gas for Barrett's esophagus. *Endoscopy* 2011; 43: 379–385
- 12 *Dumot JA, Vargo JJ, Falk GW et al.* An open-label, prospective trial of cryospray ablation for Barrett's esophagus high-grade dysplasia and early esophageal cancer in high-risk patients. *Gastrointest Endosc* 2009; 70: 635–644
- 13 *Raju GS, Ahmed I, Xiao SY et al.* Graded esophageal mucosal ablation with cryotherapy, and the protective effects of submucosal saline. *Endoscopy* 2005; 37: 523–526
- 14 *Dumot JA, Greenwald BD.* Argon plasma coagulation, bipolar cautery, and cryotherapy: ABC's of ablative techniques. *Endoscopy* 2008; 40: 1026–1032
- 15 *Dumot JA, Greenwald BD.* Cryotherapy for Barrett's esophagus: does the gas really matter? *Endoscopy* 2011; 43: 432–433