

A Technical Guide for Sciatic Nerve Targeted Muscle Reinnervation in a Transfemoral Amputee

Rachel C. Lister, BS, BA*†
Jane M. Tsui, MD‡
Aparajit Naram, MD, FACCS§

Background: There are approximately 2 million people living with the loss of a major limb in America. It is estimated that 95% of these will have some form of pain associated with their amputation. Phantom limb pain, related to symptomatic neuromas, contributes to amputation morbidity and can be difficult to treat. Studies have shown that targeted muscle reinnervation (TMR), by giving symptomatic neuromas “somewhere to go and something to do,” can be an effective therapy. However, a large proportion of surgeons still treat symptomatic neuromas by burying them in nearby tissue.

Methods: We treated a patient with previous above-the-knee amputation, complicated by a symptomatic neuroma, with TMR. We identified and described nine steps to the procedure. Our description is accompanied by illustrative, intraoperative photographs and technical pearls.

Results: This article provides a description of TMR technique involving a neuroma of the sciatic nerve and its branches, to treat an above-the-knee amputation, with the aim of making this approach more accessible. At 9-month follow-up, the patient had active firing of the recipient muscles with donor nerve stimulation indicating successful reinnervation. The patient continued to report stump pain, but with intermittent pain-free days.

Conclusions: TMR has proven potential as a therapy for amputation-related, neuropathic pain. With this technical guide to TMR, surgeons should feel more comfortable adding this technique to their armamentarium, to be utilized either at the time of amputation or as a secondary measure. (*Plast Reconstr Surg Glob Open* 2022;10:e4525; doi: [10.1097/GOX.0000000000004525](https://doi.org/10.1097/GOX.0000000000004525); Published online 28 September 2022.)

INTRODUCTION

In 2005, there were 1.6 million people living without a major limb in the USA.¹ The primary causes for major amputation are due to vascular disease, diabetes, peripheral artery disease, and trauma.¹ As our population continues to age and the incidence of vascular disease increases, we can only expect the number to grow. One study estimated that by 2050, there would be 3.6 million living with loss of a major limb.¹

For those living with an amputation of a major limb, pain is an exceedingly common complication.^{2,3} The two major categories of amputation-related pain are differentiated

according to the reported site of the pain. Residual limb pain (RLP) is experienced at the site of the amputation and can often be attributed to an underlying condition, such as nerve entrapment, infection, and prosthesis use.³ Phantom limb pain (PLP), in contrast, is perceived in the absent limb and does not have a clear pathophysiology. It is proposed that mixed nerves severed during amputation form neuromas and contribute to both PLP and RLP.^{4,5} These painful neuromas generally develop within 28 days postamputation.⁶ In a national survey, 95% of amputees reported experiencing some form of amputation-related pain, with 79.9% reporting PLP and 67.7% reporting RLP.²

Although there are multiple proposed ways to prevent or treat neuromas, the most conventional is to excise the neuroma and “bury” the implicated nerve in nearby muscle or bone.^{4,5} Targeted muscle reinnervation (TMR) is a technique that was originally created to allow for more sophisticated control of myoelectric prostheses.⁷ Rather than simply burying the offending nerve, the nerve is given “somewhere to go and something to do.” Motor nerves supplying muscles made redundant by the amputation are divided. The “donor” (mixed) nerve is given a fresh end by removing the neuroma and then coapted to the divided “recipient” (motor) nerve, entering the

From the *Department of Surgery, University of Massachusetts Chan Medical School, Worcester, Mass.; †Baystate Medical Center, Springfield, Mass.; ‡Department of Surgery, Baystate Medical Center, Springfield, Mass.; and §Division of Plastic Surgery, Baystate Medical Center, Springfield, Mass.

Received for publication May 27, 2022; accepted July 18, 2022.

Copyright © 2022 The Authors. Published by Wolters Kluwer Health, Inc. on behalf of The American Society of Plastic Surgeons. This is an open-access article distributed under the terms of the [Creative Commons Attribution-Non Commercial-No Derivatives License 4.0 \(CCBY-NC-ND\)](https://creativecommons.org/licenses/by-nc-nd/4.0/), where it is permissible to download and share the work provided it is properly cited. The work cannot be changed in any way or used commercially without permission from the journal.

DOI: [10.1097/GOX.0000000000004525](https://doi.org/10.1097/GOX.0000000000004525)

Disclosure: The authors have no financial interest to declare in relation to the content of this article.

muscle. As it regenerates, it assumes a role in the motor unit, reinnervating the muscle. It is found that the divided motor nerve itself does not form a neuroma.⁷

Foundational studies by Dumanian et al⁴ have since explored TMR as a treatment for pain and created anatomical roadmaps for surgeons to more easily identify potential motor targets.^{5,8–11} Despite TMR's growing popularity, the conventional method is still used by the majority of surgeons for both prevention and treatment of neuromas.¹² Here, we outline our approach for TMR of the sciatic nerve in an above-the-knee amputation. We elucidate how to identify and isolate the sciatic nerve and its branches—the tibial nerve and common peroneal nerve. The biceps femoris, semitendinosus, and semimembranosus muscles are supplied by motor nerves that are excellent candidates for tension-free coaptation. Our method is accompanied by intraoperative photographs from a single procedure.

METHODS

Step 1: Positioning: Position in prone with bump placed under the ipsilateral anterior thigh to keep hip in extension (Fig. 1).

Step 2: Incision: Place a 10-cm incision longitudinally within the midline of the extremity in-between the inferior gluteal crease and the end of the stump.

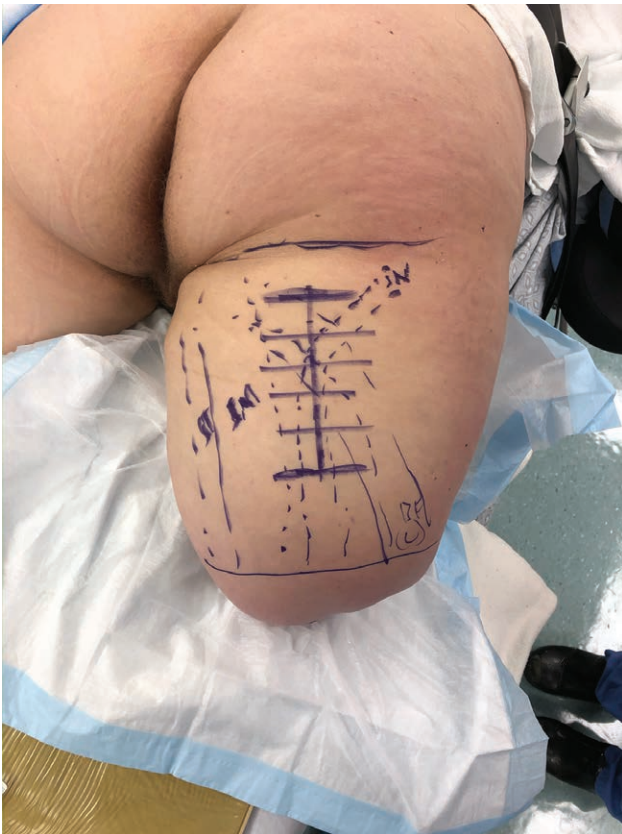

Fig. 1. Prone position with bump beneath thigh to keep hip in extension. Biceps femoris and semitendinosus identified and marked. A 10-cm incision is marked in the midline of the posterior thigh. The proximal aspect of the incision is made a few centimeters distal to the gluteal fold.

Takeaways

Question: Are there step-by-step descriptions of alternative techniques to conventional treatment of phantom limb pain described in the literature?

Findings: We provide a detailed description for the technique of targeted muscle reinnervation in an above-the-knee amputee, including surgical pearls and intraoperative photographs.

Meaning: This article means to make this technique more accessible to surgeons not yet comfortable or familiar with the use of TMR for symptomatic neuromas or phantom limb pain.

Identify the biceps femoris laterally and semitendinosus medially distally, noting that anatomy can be distorted depending on proximity of amputation (Fig. 1).

Pinching the soft tissue will allow you to find the orientation of these muscles in relationship to the posterior superior iliac spine, the ischium, and the medial and lateral femoral condyles.

The sciatic nerve can also be outlined with regard to its course. It will start lateral to the biceps femoris proximally, and then curve underneath the biceps femoris to lie between the biceps femoris and semitendinosus muscles distally, which is approximately midline between the lateral and medial aspects of the thigh.

Step 3: Superficial dissection: The superficial dissection can be done rapidly. Epinephrine diluted in saline (1 amp in 50–100 mL injectable saline) can be injected along the incision. Incise the skin and dissect through the subcutaneous tissue, until reaching the fascia overlying the musculature of the thigh (Fig. 2). Use of retractors proximally and distally will allow for maximal exposure. Underneath this fascia, you may encounter a fat pad overlying the hamstring muscles (Fig. 3). Bovie electrocautery can be used to expediently dissect within this fat pad to identify the biceps femoris muscle laterally. This fat pad can then be reflected laterally to expose the interval between the biceps femoris and semitendinosus (Fig. 4).

Step 4: Deep Dissection: The Kolbel shoulder retractor is a helpful instrument to retract these muscular components as the dissection can be deep in larger thighs. Another fat pad may be encountered between the biceps femoris and semitendinosus muscle in this deep dissection. Dissection should slow in this location, and bipolar electrocautery should be used for dissection as nerve branches will quickly appear on the proximal extent of this dissection entering into the musculature (Fig. 5).

Step 5: Identification of sciatic nerve: Between the biceps femoris and semitendinosus muscle, a finger can be used to digitally palpate along the soft tissues for the cord-like sciatic nerve. The sciatic nerve will be found deep to the biceps femoris muscle proximally (Fig. 6). Going distally, the sciatic nerve will reside in a position medial to the biceps femoris (Fig. 7). Once identified, dissection along the nerve can be performed to distal extent (Fig. 8), approximately 4–5 cm, or as much as will be needed for later tension-free coaptation.

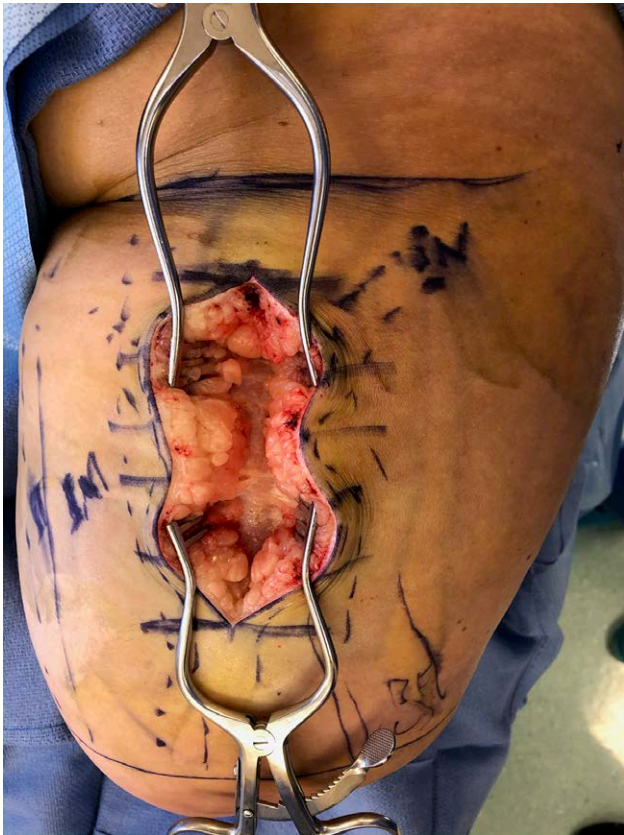

Fig. 2. After dividing skin and subcutaneous tissue, posterior fascia of leg musculature is encountered.

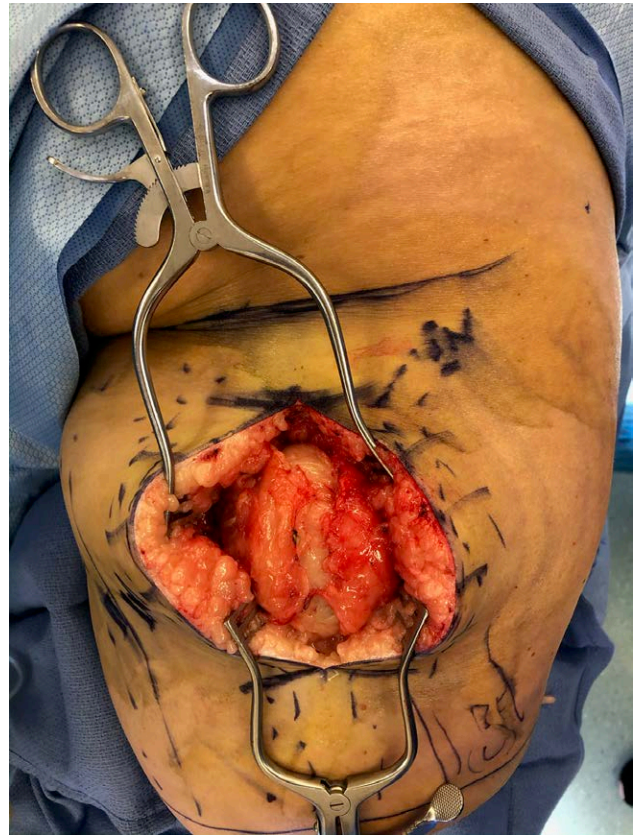


Fig. 3. Division of fascia may reveal fatty deposition on superficial to hamstring musculature, which is also then divided.

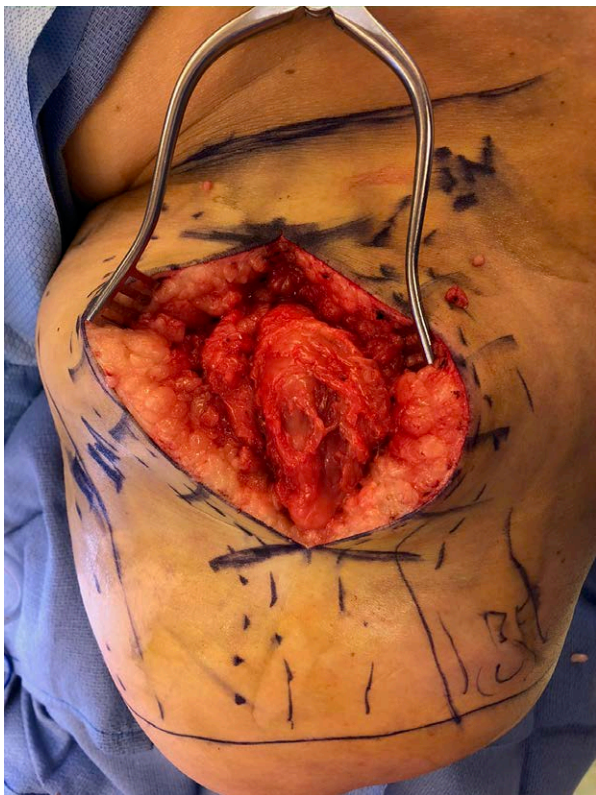

Fig. 4. Biceps femoris is identified after division of the subfascial fat layer and is mobilized and retracted laterally.

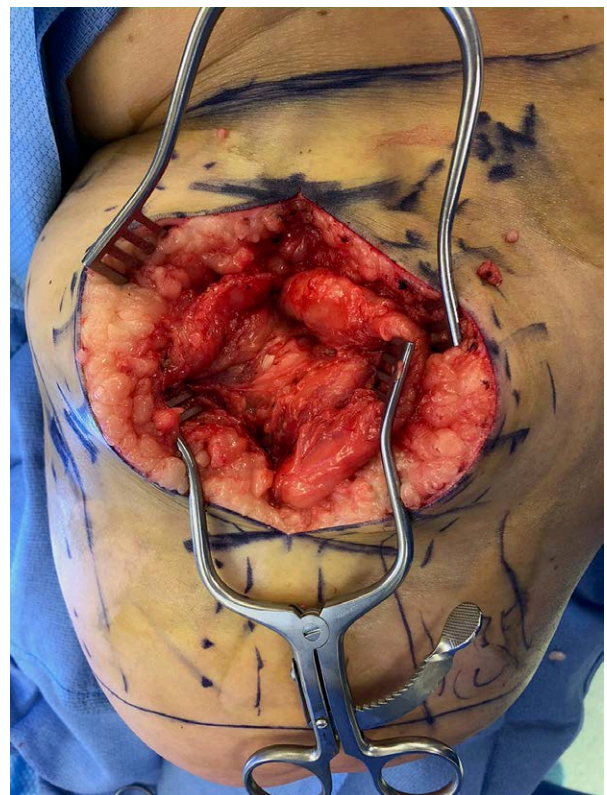

Fig. 5. Lateral retraction of the biceps femoris at the proximal aspect of the incision will reveal some motor fibers terminating in the hamstring musculature.

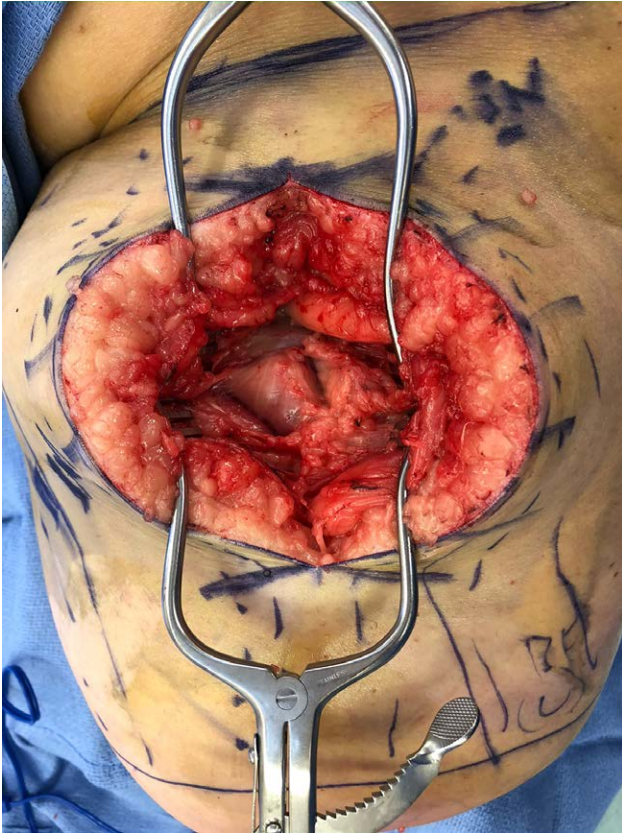


Fig. 6. Further retraction and dissection deeply will reveal multiple motor targets covered in a thin fascial layer that can be carefully divided for preparation of recipient nerve targets. Further dissection will distally reveal the sciatic nerve in the midline of the posterior thigh.

Step 6: Identification of recipient nerve branches: After identifying the sciatic nerve, proximal dissection along the nerve can be performed. The nerve stimulator can be used along this dissection where nerve branches enter into the semitendinosus, biceps femoris, and semimembranosus and can be identified just superficial to the plane of the sciatic nerve at the proximal end of the incision (Figs. 9, 10). Vessel loops can be placed around the selected nerves and dissection carried to the proximal extent of the incision (3–4 cm).

Step 7: Nerve preparation and coaptation: The donor sciatic nerve can be cut distally. Neurolysis with tenotomy scissors can be performed to divide the sciatic nerve into its proper tibial nerve and common peroneal nerve bundles (Fig. 11). The recipient nerves to the biceps femoris, semitendinosus, or semimembranosus muscles can be cut proximally and brought into the middle of the incision for tension-free coaptation. Coaptation can be performed with 9-0 nylon and fibrin glue. We prefer 2–3 sutures to loosely coapt the nerves accounting for the size mismatch by placing the recipient nerves within the center of the sciatic, followed by fibrin glue (Fig. 12). After microsurgical coaptation, the nerves may be positioned in the submuscular position.

Step 8:

Skin closure and wound management: We use an On-Q pain pump that is positioned along the coaptation site

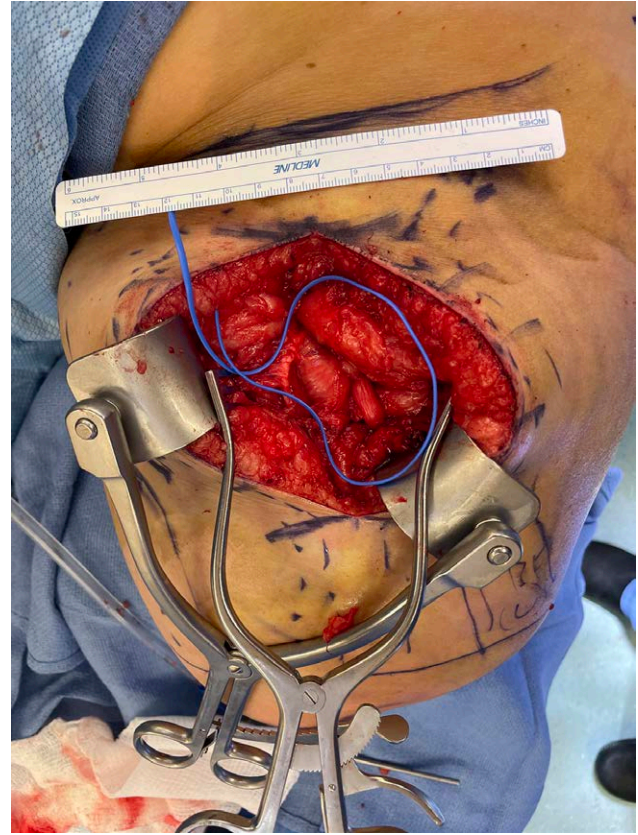


Fig. 7. On the distal aspect of the incision, the large sciatic nerve comes into view.

exiting laterally at the skin level. Closure is performed with 3-0 PDS in the deep dermis followed by 3-0 or 4-0 Monocryl in a running subcuticular fashion. A dressing is applied to the incision, and the amputation site is dressed with web roll and Ace wrap for gentle compression.

Step 9: Pain management: Postoperative sciatic and femoral block can be helpful to diminish acute pain following surgery.

RESULTS

At final follow-up at 9 months postoperative, the patient demonstrated active firing of the reinnervated target muscles with patient signaling foot movement. This demonstrates technical success of reinnervation. With regard to pain, the patient reported initial worsening of pain, which gradually changed in intensity and frequency. At final follow-up, the patient described persistent episodes of pain with intermittent pain-free days.

DISCUSSION

In the US today, there are nearly 2 million people living with a major limb amputation, with around 95% of amputees reporting some form of amputation-related pain.² PLP is reported by nearly 80% of amputees, and effective treatment has been elusive.²

A randomized control trial performed by Dumanian et al⁴ compared TMR to the conventional method of “burying” to treat PLP and RLP. They found that TMR

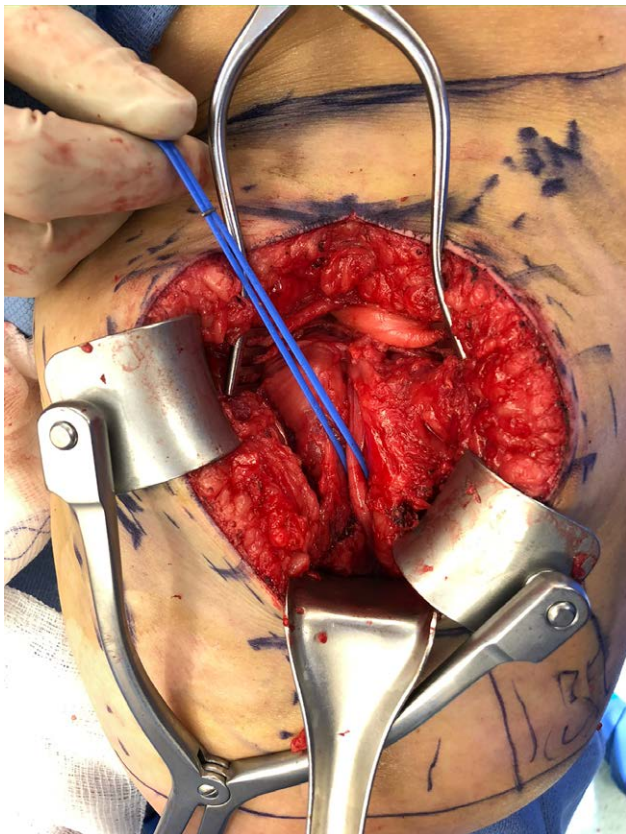


Fig. 8. A vessel loop is placed around the sciatic nerve, which is then traced distally to obtain length for tension-free coaptation. Kolbel retractor is demonstrated, providing excellent visualization.

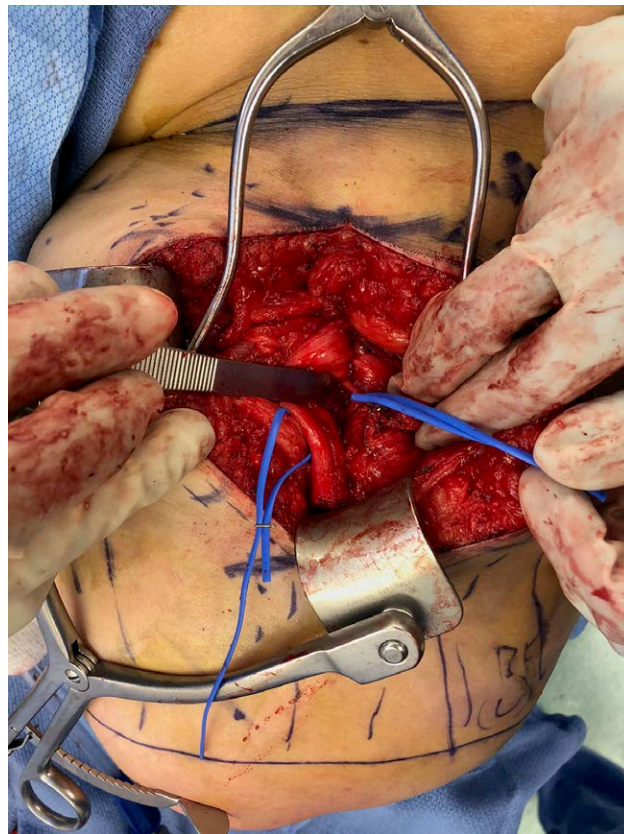


Fig. 9. Recipient nerves are identified within the proximal aspect of the incision. A nerve stimulator is used for identification and selection of motor targets. Demonstrated in the right vessel loop is a nerve to the biceps femoris.

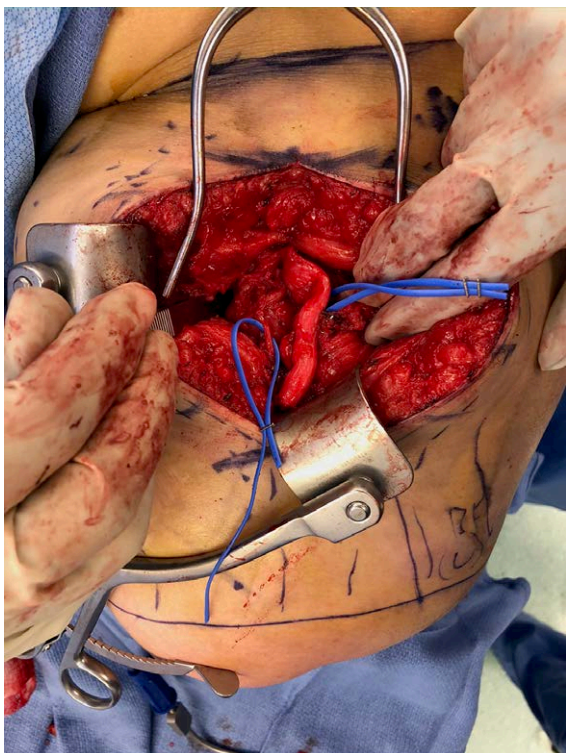


Fig. 10. A second motor nerve fascicle is selected on the medial aspect of the incision. A semimembranosus or semitendinosus motor branch can be selected based on location and geometry of coaptation.

showed promise to be a better method to treat amputation-related pain. Subsequent studies have looked at its effectiveness as an intervention near or at the time of amputation (primary TMR) and as a secondary measure. In either case, TMR was found to reduce pain compared with standard treatment.^{9,11}

In this article, we have described technical pearls for obtaining adequate exposure and identifying donor and recipient nerves for the transfemoral amputee. The exposure allows for clear identification of numerous recipient nerves as well as exposure to relevant posteriorly located major nerves for coaptation.

Previous anatomical studies have mapped motor nerve branches and their entry points to potential target muscles and found variation between individuals.⁸ Incision placement and avoiding unnecessary extension of the incision will be influenced by the selected motor target and individual anatomical variation.

TMR was originally developed as a technique to allow for sophisticated control of myoelectric upper limb prostheses.⁷ While lower limb amputations require less fine motor control, an above-the-knee amputation can negatively impact quality of life.¹³ Prosthetic functionality is found to be a strong predictor of quality of life.¹³ Consideration of the subsequent prosthetic device fit and utility may also limit potential incision locations.

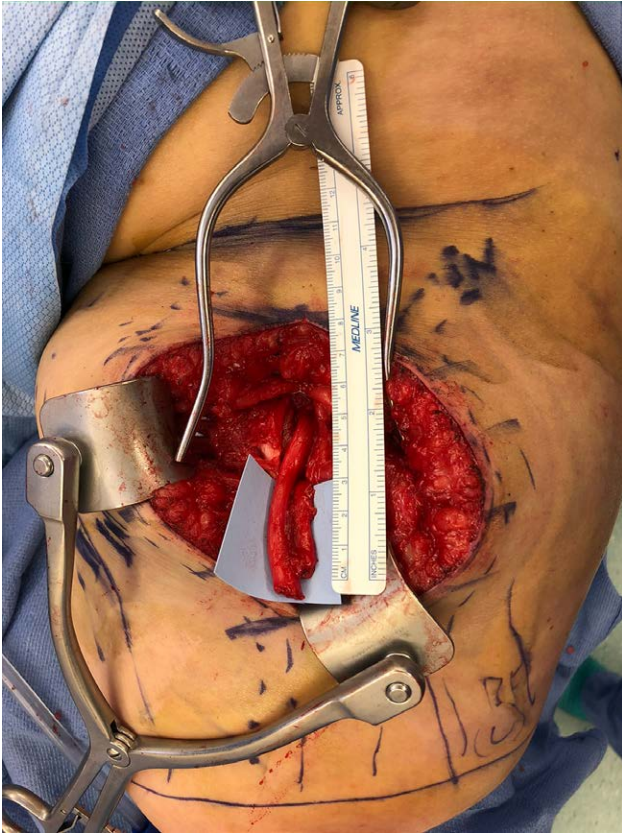

Fig. 11. The sciatic nerve is divided distally, demonstrating the cleavage plane of the common peroneal nerve laterally and the tibial nerve medially. This cleavage plane is variable and may be less pronounced.

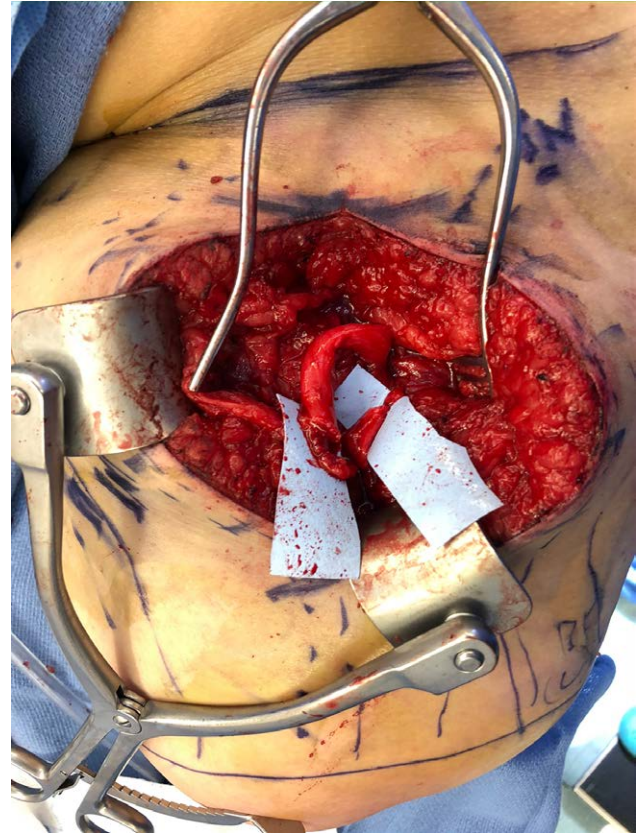


Fig. 12. Dividing the sciatic nerve distally and recipient nerves proximally, tension-free coaptation is performed with 9-0 nylon and fibrin glue.

While the posterior femoral cutaneous nerve may also be accessed through the same incision described in this article, we did not feel this was a necessary donor nerve and did not perform reinnervation in this case. An anterior or medial approach to the femoral and saphenous nerves may be necessary in some patients, and a technical description for optimal incision planning in those cases would be of great benefit.

We suggest motor nerves of the biceps femoris, semitendinosus, and semimembranosus muscles as ideal recipients for the sciatic nerve and its branches. However, in cases where these recipient nerves are inaccessible or damaged, alternative approaches and targets would also merit description.

In addition to TMR, regenerative peripheral nerve interface is an emerging technique that shows promise for both prosthetic control and neuropathic pain treatment. Regenerative peripheral nerve interface secures an autologous denervated muscle graft around the free end of an excised neuroma, providing it with regenerating axons and a muscle target.¹⁴ Recent studies have explored how to combine the two techniques,^{15–17} although there is not yet enough evidence to support whether a combination of the techniques is reliably better than either technique alone.

Aparajit Naram, MD, FACS

Department of Surgery, Division of Plastic and
Reconstructive Surgery
Baystate Medical Center
2 Medical Center Dr, 206
Springfield, MA 01107
E-mail: aparajit.naram@baystatehealth.org

REFERENCES

1. Varma P, Stineman MG, Dillingham TR. Epidemiology of limb loss. *Phys Med Rehabil Clin N Am.* 2014;25:1–8.
2. Ephraim PL, Wegener ST, MacKenzie EJ, et al. Phantom pain, residual limb pain, and back pain in amputees: results of a national survey. *Arch Phys Med Rehabil.* 2005;86:1910–1919.
3. Hanyu-Deutmeyer AA, Cascella M, Varacallo M. Phantom limb pain. *StatPearls.* Treasure Island, Fla.: StatPearls Publishing; 2022.
4. Dumanian GA, Potter BK, Mioton LM, et al. Targeted muscle reinnervation treats neuroma and phantom pain in major limb amputees: a randomized clinical trial. *Ann Surg.* 2019;270:238–246.
5. Souza JM, Cheesborough JE, Ko JH, et al. Targeted muscle reinnervation: a novel approach to postamputation neuroma pain. *Clin Orthop Relat Res.* 2014;472:2984–2990.
6. Oliveira KMC, Pindur L, Han Z, et al. Time course of traumatic neuroma development. *PLoS One.* 2018;13:e0200548.
7. Kuiken TA, Barlow AK, Hargrove L, et al. Targeted muscle reinnervation for the upper and lower extremity. *Tech Orthop.* 2017;32:109–116.

8. Fracol ME, Janes LE, Ko JH, et al. Targeted muscle reinnervation in the lower leg: an anatomical study. *Plast Reconstr Surg*. 2018;142:541e–550e.
9. Bowen JB, Ruter D, Wee C, et al. Targeted muscle reinnervation technique in below-knee amputation. *Plast Reconstr Surg*. 2019;143:309–312.
10. Agnew SP, Schultz AE, Dumanian GA, et al. Targeted reinnervation in the transfemoral amputee: a preliminary study of surgical technique. *Plast Reconstr Surg*. 2012;129:187–194.
11. Valerio IL, Dumanian GA, Jordan SW, et al. Preemptive treatment of phantom and residual limb pain with targeted muscle reinnervation at the time of major limb amputation. *J Am Coll Surg*. 2019;228:217–226.
12. Loewenstein SN, Cuevas CU, Adkinson JM. Utilization of techniques for upper extremity amputation neuroma treatment and prevention. *J Plast Reconstr Aesthet Surg*. 2021;75:S1748-6815(21)00620-3.
13. Asano M, Rushton P, Miller WC, et al. Predictors of quality of life among individuals who have a lower limb amputation. *Prosthet Orthot Int*. 2008;32:231–243.
14. Kubiak CA, Adidharma W, Kung TA, et al. “Decreasing postamputation pain with the regenerative peripheral nerve interface (RPNI)”. *Ann Vasc Surg*. 2022;79:421–426.
15. Bhashyam AR, Liu Y, Kao DS. Targeted peripheral nerve interface: case report with literature review. *Plast Reconstr Surg Glob Open*. 2021;9:e3532.
16. Valerio I, Schulz SA, West J, et al. Targeted muscle reinnervation combined with a vascularized pedicled regenerative peripheral nerve interface. *Plast Reconstr Surg Glob Open*. 2020;8:e2689.
17. Kurlander DE, Wee C, Chepla KJ, et al. TMRpni: combining two peripheral nerve management techniques. *Plast Reconstr Surg Glob Open*. 2020;8:e3132.