

Ovarian hyperstimulation syndrome as a rare cause of acute bilateral limb and renal ischemia

Anita Quintas, MD,^{a,b} Maria Emilia Ferreira, MD,^a Frederico Bastos Gonçalves, MD, PhD,^{a,b} José Aragão de Morais, MD,^a Joao Albuquerque e Castro, MD,^a and Luís Mota Capitaio, MD,^a
Lisbon, Portugal

ABSTRACT

Ovarian hyperstimulation syndrome (OHS) is a rare and potentially fatal condition, particularly when it is associated with arterial thromboembolic events. We present a case of acute ischemia of both lower limbs and left kidney due to OHS. The clinical presentation included voluminous ascites, pleural effusion, and significant ovarian enlargement. Subsequently, bilateral severe acute limb ischemia and left kidney segmental infarction were established. Surgical thromboemblectomy and muscle débridement of the lower limbs were necessary, and the patient recovered with partial limitations. A high index of suspicion and timely treatment are essential to minimize consequences of arterial thrombosis associated with OHS. (*J Vasc Surg Cases and Innovative Techniques* 2017;3:105-7.)

The ovarian hyperstimulation syndrome (OHS) is a rare but well-defined complication¹ that in its severe form may complicate 1% to 2% of in vitro fertilizations.² It is characterized by excessive ovarian growth with release of vasoactive substances,³ leading to increased capillary permeability and fluid extravasation from the vascular compartment to the interstitial space.^{4,5}

In in vitro fertilization cycles, the incidence of vascular thrombosis is 0.2%, but it may reach 10% in the severe form of OHS.⁶ In general, the venous territory is affected. Rarely, arterial thrombosis may also occur and carries the worst prognosis as it can reach the cerebral territory in 60% of the cases.^{2,4}

With the patient's consent, we report a case of bilateral lower limb arterial thrombosis resulting in severe ischemia in a patient with OHS.

CLINICAL CASE

A 37-year-old woman with polycystic ovaries, infertility, and hypothyroidism was under a medically assisted reproduction program, composed of a suppressive cycle with triptorelin followed by ovarian stimulation with 100 IU of follitropin, recombinant human chorionic gonadotropin (rhCG), and intravaginal progesterone

300 mg twice daily. Thirty-six hours after the rhCG injection, an intravaginal ovarian puncture recovered 13 oocytes for in vitro fertilization, followed by the uneventful transfer of two viable embryos.

Eleven days after the rhCG injection and 6 days after the embryo transfer, the patient presented to an emergency department at a regional hospital with hypotension, severe dehydration, and acute right lower limb pain. In addition, she manifested dizziness, dyspnea, nausea, vomiting, and significant increase of the abdominal circumference. The laboratory workup identified hemoglobin concentration (hemoglobin concentration of 20 g/dL), leukocytosis (31,730/ μ L), transaminase elevation, lactate dehydrogenase level of 1795 U/L, and creatinine concentration of 1 mg/dL. Significant rhabdomyolysis was also present, with a creatine kinase level of 43,003 U/L. The serum estradiol reached levels of >4300 pg/mL, and a β -hCG level of 67.9 μ m/mL confirmed pregnancy.

Abdominal computed tomography detected bilateral pleural effusion, voluminous ascites, and increased ovarian volume (right ovary with 10 cm and left with 7.5 cm; Fig 1).

The patient was admitted to an intensive care unit with the diagnosis of the severe form of OHS for hemodynamic stabilization with fluid therapy, diuretic reinforcement, albumin supplementation, and anticoagulation. At admittance, the right lower limb was not evaluated, but 5 days later, after progressive general recovery and worsening of the right lower limb complaints with additional involvement of the contralateral lower limb, a formal vascular assessment was requested.

At the time of the first evaluation, severe rest pain affecting both limbs was present, along with coldness and pallor. Increased muscle tension was identified in both legs, and a compartment syndrome was suspected. Neurologic deficits were present with a right dropfoot, hypoesthesia in the lower third of both limbs, and inability to mobilize the toes and the right tibiotarsal

From the Department of Angiology and Vascular Surgery, Santa Marta Hospital, CHLC^a; and the NOVA Medical School.^b

Author conflict of interest: none.

This case has been presented as a poster at Charing Cross Symposium 2014, London, United Kingdom, April 5-8, 2014.

Correspondence: Anita Quintas, MD, Hospital de Santa Marta, Centro Hospitalar Lisboa Central, Serviço de Angiologia e Cirurgia Vascular, Rua Santa Marta nr 50, Lisboa 1169-024, Portugal (e-mail: anitaquintas@gmail.com).

The editors and reviewers of this article have no relevant financial relationships to disclose per the Journal policy that requires reviewers to decline review of any manuscript for which they may have a conflict of interest.

2468-4287

© 2017 Published by Elsevier Inc. on behalf of Society for Vascular Surgery. This is an open access article under the CC BY-NC-ND license (<http://creativecommons.org/licenses/by-nc-nd/4.0/>).

<http://dx.doi.org/10.1016/j.jvscit.2017.02.004>

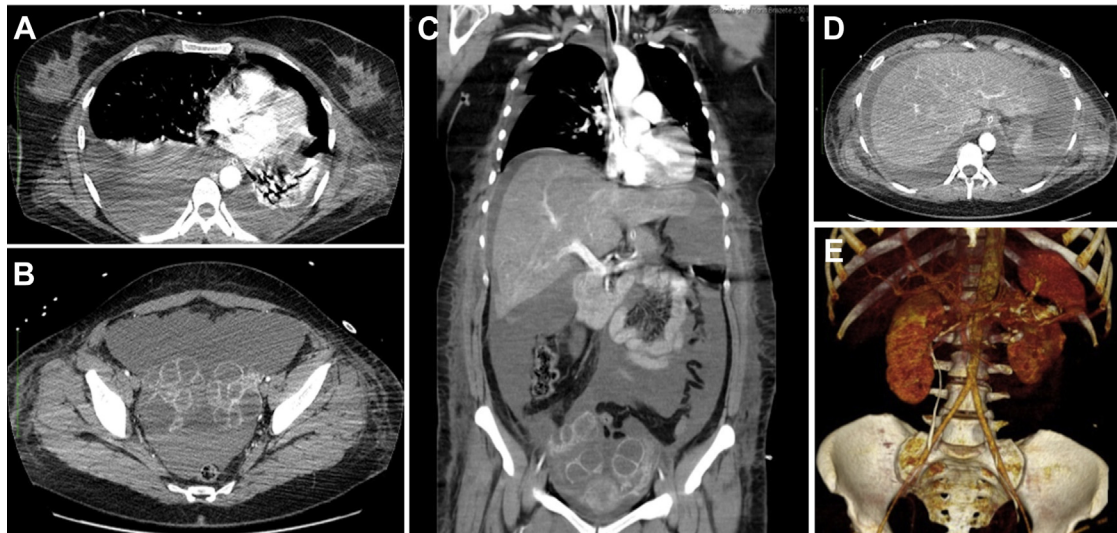


Fig 1. Computed tomography angiography in axial and coronal views showing bilateral pleural effusion (A), voluminous ascites (B-D), and increased ovarian volume (B and C). E, Three-dimensional volume rendering reconstruction with evidence of the segmental infarction in the lower pole of the left kidney.

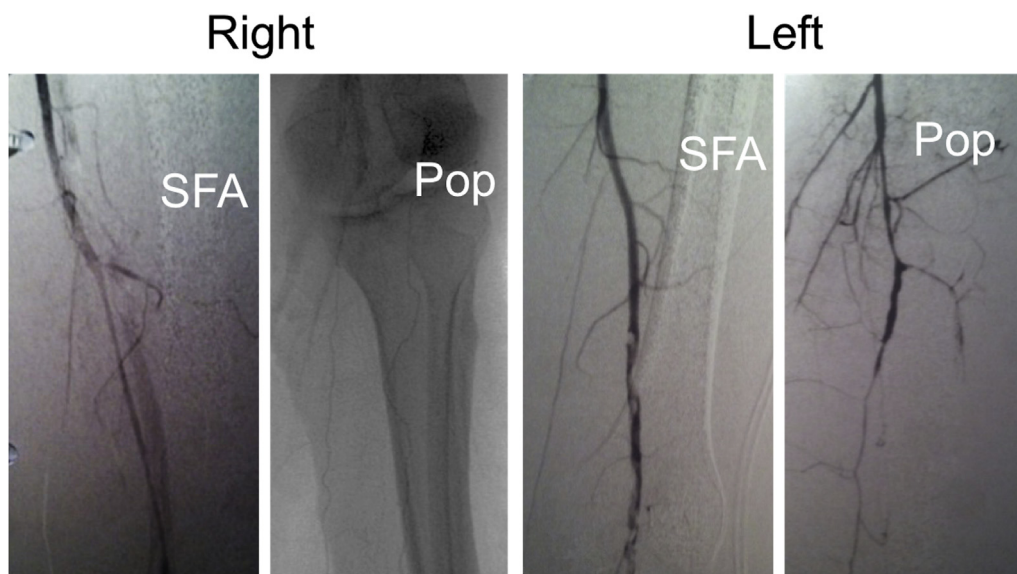


Fig 2. Intraoperative angiography. *Pop*, Popliteal artery; *SFA*, superficial femoral artery.

joint. Only femoral pulses were palpable. A duplex ultrasound examination confirmed the diagnosis, revealing an occlusion of the right superficial femoral, popliteal, and tibial arteries and a partial occlusion of the left superficial femoral and popliteal arteries. Computed tomography angiography also revealed a segmental infarction in the lower pole of the left kidney (Fig 1).

Intraoperative angiography confirmed thrombosis of the superficial femoral and popliteal arteries, partial on the left side (Fig 2). The patient underwent bilateral leg compartment fasciotomies and bilateral thromboembolectomy with a Fogarty catheter from a femoral approach. No action was taken to resolve the segmental

renal infarction as the patient had no related symptoms and renal function was not altered.

Despite the recovery of palpable pulses in both feet, successive débridements of devitalized muscle tissue were required, including the bilateral soleus, right fibularis longus, and right brevis muscles.

Lower limb electromyography confirmed multiple axonal mononeuropathies. Thrombophilia including protein C and protein S deficiency, antithrombin III deficiency, antiphospholipid antibodies, and myeloproliferative disorders were ruled out with appropriate testing. Despite confirmation of a viable gemellary intrauterine pregnancy, the pregnancy was interrupted at the sixth

week. The patient was kept on antiplatelet therapy with acetylsalicylic acid.

After 4 months of intensive physical rehabilitation, the patient recovered significantly. Although still presenting with loss of proprioceptive sensibility and a pendent foot in the right lower limb, she was able to walk with use of an ankle-foot orthosis.

At 16 months of follow-up, the patient became pregnant without any medical stimulation. The pregnancy was complicated by HELLP syndrome (hemolysis, elevated liver enzymes, and low platelet count), but she gave birth to a healthy infant through a cesarean section at 34 weeks of gestation.

At 2 years of follow-up, the patient sustains dorsalis pedis palpable pulses in both feet and is able to walk autonomously.

DISCUSSION

OHS is a rare entity associated with medically assisted reproduction. Defined by a massive transudation of protein-rich fluid from the vascular space,⁷ the most severe cases may present with large effusions (peritoneal, pleural, pericardial) and organ dysfunction.² The first case of thromboembolism associated with OHS was published in 1965.⁸

Thrombotic events complicating OHS more commonly affect the venous territory, involving unusual locations such as jugular and subclavian-axillary veins.^{6,9} Arterial thrombosis is rare and occurs generally within the first 2 weeks after the embryo transfer.⁶ More than 60% of the reported cases involve cerebral arteries, both intracranial and extracranial.^{9,10} In 2014, Mor and Schenker⁷ reviewed 36 arterial thrombotic events related to OHS in the literature, involving limb arteries in 17% of the cases. Arterial thrombosis was reported in the upper extremity in two cases and in the lower extremity in four cases only.⁷ Of these, two cases of limb amputation have been reported.⁷ Our case is particular because of the concomitant involvement of different arterial territories: both lower limbs and the lower pole of the right kidney.

A multifactorial etiology has been accepted in the pathophysiologic mechanism of thrombosis in OHS, with the concurrent effects of supraphysiologic levels of estradiol, hemoconcentration, endothelial damage, and imbalance of the coagulation-fibrinolysis process to be accounted for. However, the precise mechanism through which a prothrombotic state is established remains unclear.

Whenever thrombosis is diagnosed in the context of severe OHS, treatment should include hemodilution and infusion of crystalloids along with institution of anticoagulation with heparin.⁶ However, in 7.5% of OHS cases, thrombosis progression can occur despite therapeutic or prophylactic anticoagulation.⁶

Thrombophilia has been reported in up to 40% of the cases, but data are still lacking as to which risk factors predispose certain subgroups of women to arterial

thrombosis.^{7,9} In the particular case of our patient, she presented with multiple risk factors for OHS: she had polycystic ovaries, underwent a protocol with hCG, and presented with elevated serum estradiol concentration. However, other prothrombotic risk factors, such as thrombophilia, could not be identified. Although screening of thrombophilia cost-effectiveness remains dubious in the in vitro fertilization general population, it may be important in women with a family or personal history of hypercoagulability or previous severe OHS.⁶ Given the potential severe consequences of arterial thrombosis associated with OHS, thromboprophylaxis should be considered in patients with thrombophilia and moderate to severe OHS.⁷

CONCLUSIONS

We present a rare and severe case of bilateral lower limb and renal arterial thrombosis associated with OHS. Given the clinical nature of the syndrome, a high clinical awareness and timely diagnosis of arterial complications are necessary to minimize clinical sequelae. More investigation is required to clarify the etiopathogenesis of the OHS-associated prothrombotic state. Thromboprophylaxis may prevent thrombotic complications in patients diagnosed with OHS.

REFERENCES

1. Vloeberghs V, Peeraer K, Pexsters A, D'Hooghe T. Ovarian hyperstimulation syndrome and complications of ART. *Best Pract Res Clin Obstet Gynaecol* 2009;23:691-709.
2. Grossman LC, Michalakis KG, Browne H, Payson MD, Segars JH. The pathophysiology of ovarian hyperstimulation syndrome: an unrecognized compartment syndrome. *Fertil Steril* 2010;94:1392-8.
3. Jozwik M. The mechanism of thromboembolism in the course of ovarian hyperstimulation syndrome. *Dev Period Med* 2012;16:269-71.
4. Chan WS, Dixon ME. The "ART" of thromboembolism: a review of assisted reproductive technology and thromboembolic complications. *Thromb Res* 2008;121:713-26.
5. Garcia-Benítez CQ, Aviés-Cabrera RN. Trombosis arterial en el síndrome de hiperestimulación ovárica. *Ginecol Obstet Mex* 2011;79:152-5.
6. Kasum M, Danolić D, Orešković S, Ježek D, Beketić-Orešković L, Pekez M. Thrombosis following ovarian hyperstimulation syndrome. *Gynecol Endocrinol* 2014;30:764-8.
7. Mor YS, Schenker JG. Ovarian hyperstimulation syndrome and thrombotic events. *Am J Reprod Immunol* 2014;72: 541-8.
8. ESHRE Capri Workshop Group. Venous thromboembolism in women: a specific reproductive health risk. *Hum Reprod Update* 2013;19:471-82.
9. Chan WS. The "ART" of thrombosis: a review of arterial and venous thrombosis in assisted reproductive technology. *Curr Opin Obstet Gynecol* 2009;21:207-18.
10. Girolami A, Scandellari R, Tezza F, Paternoster D, Girolami B. Arterial thrombosis in young women after ovarian stimulation: case report and review of the literature. *J Thromb Thrombolysis* 2007;24:169-74.