



Percutaneous Drainage and Povidone-Iodine Sclerotherapy of Cervical Lymphatic Malformation

Seung Hyoung Kim¹, Mu Sook Lee¹, Gil Chai Lim², and Chan Il Song²

Departments of ¹Radiology and ²Otorhinolaryngology-Head and Neck Surgery, Jeju National University School of Medicine, Jeju, Korea.

Lymphatic malformations in cases with macrocystic lesions can be treated with surgical excision or sclerotherapy using alcohol, bleomycin, doxycycline, or OK-432. We report a case of a 24-year-old woman who underwent percutaneous drainage and povidone-iodine sclerotherapy as primary treatment for cervical lymphatic malformation. The patient underwent povidone-iodine sclerotherapy for 3 consecutive days. After 8 months, ultrasonography of the lesion in the neck revealed complete resolution of the cervical lymphatic malformation without any complication. Povidone-iodine sclerotherapy can be a safe and cost-effective treatment option for cervical lymphatic malformation.

Key Words: Lymphatic malformation, povidone-iodine, sclerotherapy

INTRODUCTION

Lymphatic malformations are benign congenital malformations of lymphatic vessels and channels that are caused by the failure of lymph spaces to connect to the rest of the lymphatic system. They are lined by endothelial cells and separated by a scant intervening connective tissue stroma that often contains lymphoid aggregates.¹ Classical treatment is surgical excision. However, complications such as damage to the nervous and vascular structures, incomplete excision, fistula formation, wound infection, or wound dehiscence may occur. Thus, sclerotherapy using ethanol, bleomycin, doxycycline, or OK-432 was the preferred treatment of macrocystic lymphatic malformation. Currently, the two most extensively investigated sclerosing agents are bleomycin and OK-432.²⁻⁴

We present herein a case of a patient with cervical lymphatic malformation who was cured with sclerotherapy using povidone-iodine. To our best knowledge, this is the first report of

the use of povidone-iodine sclerotherapy for cervical lymphatic malformation.

CASE REPORT

A 24-year-old woman with a 1-week history of neck swelling visited our outpatient clinic. The patient had no significant medical or family history. On physical examination, the patient was found to have a soft, smooth, non-tender mass at the right posterior neck area. Computed tomography revealed a fluid-filled cyst in the right posterior fossa, extending to the right omohyoid muscle, compatible with lymphatic malformation. The cyst was 5.5×3.8×5.4 cm in size and had a heterogeneous density, suggesting blood in the cyst (Fig. 1). Ultrasonography-guided percutaneous drainage and sclerotherapy were performed because the size of the cyst did not change after 2 months of observation. Daily povidone-iodine sclerotherapy was performed for 3 days. Before the procedure, authors checked the patient's history of allergic reaction to povidone-iodine. Because povidone-iodine is one of the easily obtainable antiseptics, the patient had the experience of povidone-iodine usage and denied allergic reaction. In the supine position, the patient underwent percutaneous puncture of the cystic lymphatic malformation and drainage of fluid content with an 8.5 F pigtail catheter (Cook, Bloomington, IN, USA). After aspiration of clear and yellow fluid (70 mL), a mixture of 0.5% lidocaine (10 mL), contrast medium (15 mL), and normal saline (15 mL) was in-

Received: August 29, 2016 **Revised:** November 9, 2016

Accepted: November 24, 2016

Corresponding author: Dr. Chan Il Song, Department of Otorhinolaryngology-Head and Neck Surgery, Jeju National University School of Medicine, 102 Jejudaehak-ro, Jeju 63243, Korea.

Tel: 82-64-717-2108, Fax: 82-64-717-1097, E-mail: songchanil@gmail.com

•The authors have no financial conflicts of interest.

© Copyright: Yonsei University College of Medicine 2017

This is an Open Access article distributed under the terms of the Creative Commons Attribution Non-Commercial License (<http://creativecommons.org/licenses/by-nc/4.0>) which permits unrestricted non-commercial use, distribution, and reproduction in any medium, provided the original work is properly cited.

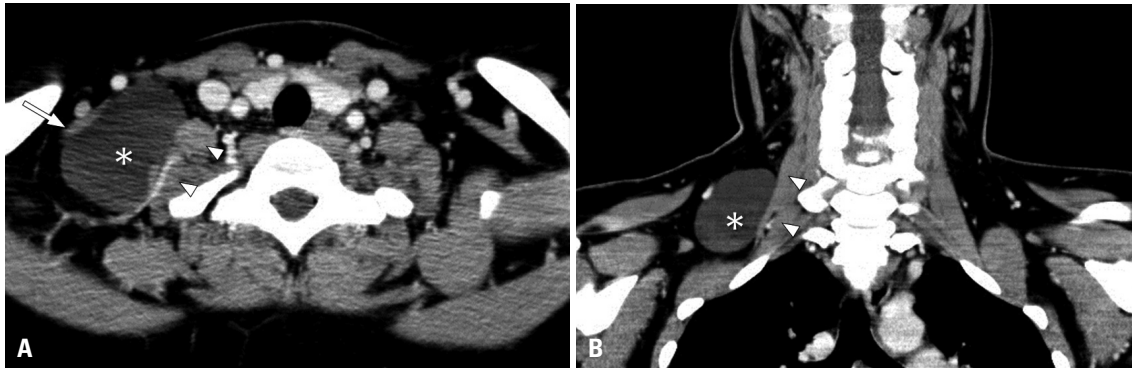


Fig. 1. Computed tomographic images of 24-year-old woman showed a 5.5 cm-sized unilocular thin-walled cystic lymphatic malformation (asterisk) in the posterior triangle of the right neck. The cyst is located between the Inferior belly of omohyoid muscle (arrow) and scalene muscles (arrowheads). (A) Axial view. (B) Coronal view.

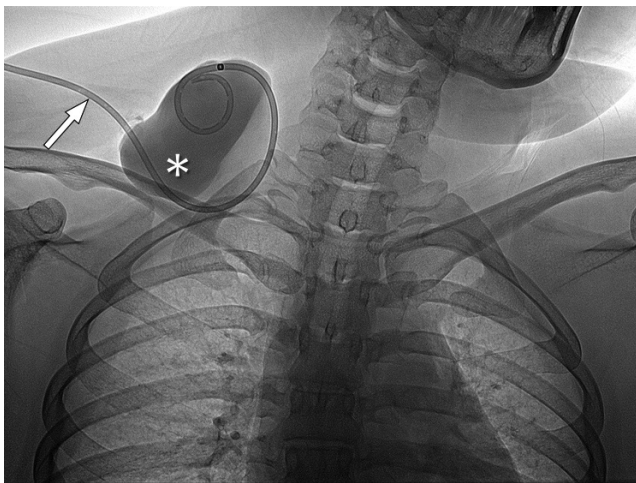


Fig. 2. A catheter (arrow) was inserted in the cystic lymphatic malformation (asterisk), through which a mixture of contrast medium and lidocaine was injected in order to induce intracystic anesthesia and ensure no fluid leak from the cyst.

jected in the cyst in order to do intracystic anesthesia and ensure that there is no fluid leak from the cyst (Fig. 2). After making sure that there is no pericatheter contrast leakage, 40 mL of a 10% povidone-iodine was injected through the catheter, and then the percutaneous catheter drainage (PCD) was locked. The PCD was unlocked after 6 hours, and fluid was drained naturally. The same procedures were repeated on the second and third day. The content of the cyst was drained naturally for 2 days after completion of the 3-day sclerotherapy, until a 24-hour total drainage volume of less than 10 mL was collected. During admission and after hospital discharge, the patient had no fever, only mild pain and tenderness (visual analogue scale score for pain, <2) in the lesion area for several days. No bacterium was isolated in the bacterial culture of fluid from the cyst. After 8 months, the lesion was no longer palpable, and the patient felt no pain and tenderness in the right neck. Ultrasonography of the right neck revealed complete shrinkage of the cervical lymphatic malformation without finding of any complication (Fig. 3).

DISCUSSION

Classical treatment for lymphatic malformation consists of surgical excision with preservation of the nervous and vascular structures. However, this is not always possible because damage to these structures may occur during surgery, and post-operative events such as fistula formation, infection, and wound dehiscence may develop. The limitation of surgical treatment led to the development of other forms of therapy, such as application of sclerosing agents, that aim to achieve total or partial regression of lymphatic malformations.⁵⁻⁷

Bleomycin was first described as an anticancer drug. It was also shown to have a sclerosing effect on endothelial cells via a non-specific inflammatory reaction and was used for the first time as a sclerosing agent for lymphatic malformation in 1977.² The adverse effects of this agent are described as minimal, including local swelling and inflammation. However, bleomycin is a less attractive sclerosing agent because it confers a risk of pulmonary fibrosis and the reported deaths related to bleomycin sclerotherapy.^{4,8}

OK-432 is a lyophilized incubation mixture of group 1 *Streptococcus pyogenes* of human origin, which has been used as an immunopotentiating anticancer drug since 1975.⁹ The clinical effect occurs via damage to the endothelium of the lymphatic malformation, secondary to activation of the immune system (macrophages, NK cells, and LAK cytotoxic T lymphocytes).² Thus, its injection initially results in an inflammatory response associated with swelling, erythema, pain, and fever for several days. Consequently, these systemic reactions restricted the use of OK-432 in the United States.

Doxycycline has some advantages over other sclerosing agents. It has been well tolerated with minimal side effects and is widely available. However, complications reported after doxycycline sclerotherapy in the head and neck lymphatic malformation include cellulitis, scarring, skin excoriation, and Horner's syndrome. Tooth discoloration and medication allergies are also potential risks.¹⁰

Compared with other sclerosing agents, povidone-iodine is

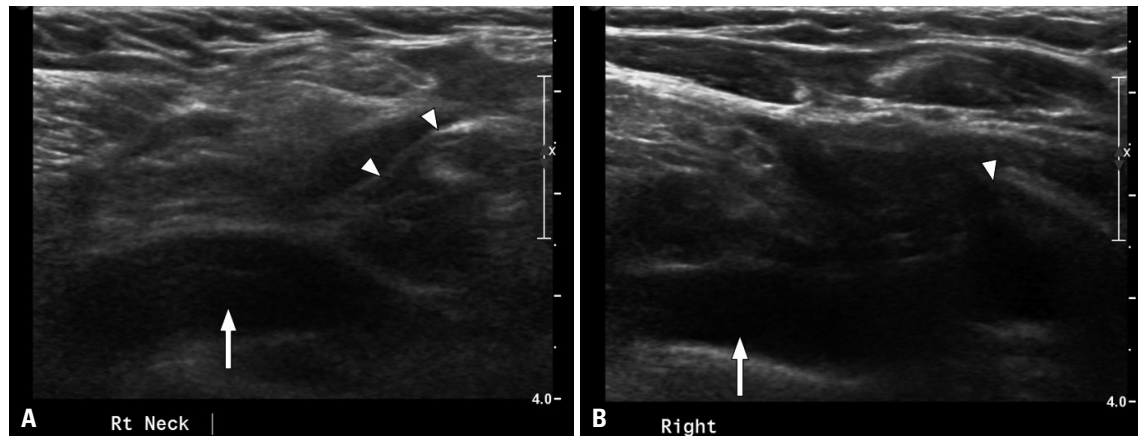


Fig. 3. One month and 8 month follow-up ultrasonographic images of the right supraclavicular fossa revealed complete shrinkage and non-visualization of the cervical lymphatic malformation which was located adjacent to the scalene muscles (arrowheads) and the right subclavian vein (arrows). (A) One month follow-up. (B) Eight month follow-up.

less toxic, less irritant, economical, and easily available. It has local sclerosing action and antiseptic, antibacterial, and anti-fungal actions, and it is easy to prepare in the desired concentration.¹¹ A 10% povidone-iodine solution contains 1% available iodine but free-iodine is at 0.1% concentration. It is well demonstrated that skin exposure causes irritant rather than allergic dermatitis. Rare cases of allergic dermatitis to povidone-iodine have been reported in the literature.¹² In a well-documented study, only 2 of 500 patients were allergic to povidone-iodine (prevalence: 0.4%).¹³ In a systemic review, no harmful effect of iodine on thyroid function and no major adverse effects were seen with iodine regarding allergic responses or cytotoxicity.¹⁴ In previous studies, povidone-iodine was injected and left for 30 minutes twice daily, and then spontaneous drainage was allowed for the treatment of postoperative lymphoceles.^{15,16} The total time that the catheter was left in the lesions ranged from 15 to 37 days in these studies. In our patient, however, the catheter was placed only for 5 days. Although it is difficult to compare postoperative lymphoceles directly with lymphatic malformation, we employed the protocol of clamping for 6 hours after povidone-iodine injection daily to be more effective than that of clamping for 30 minutes twice daily as in the previous studies.

The optimal sclerosing agent has not been elucidated yet. It should induce total shrinkage of the lymphatic malformation, have no systemic toxicity, and minimize the damage to surrounding tissue. Here, we propose povidone-iodine as an alternative means of treating cervical lymphatic malformations. However, further research in this direction is necessary and a long-term, large-scale prospective study to compare the efficiency and complications of povidone-iodine as a sclerosing agent is greatly needed.

REFERENCES

1. Kumar V, Abbans AK, Fausto N. Robbins and Cotran pathologic basis of disease. 7th ed. Philadelphia (PA): Elsevier Saunders; 2005.
2. Olímpio Hde O, Bustorff-Silva J, Oliveira Filho AG, Araujo KC. Cross-sectional study comparing different therapeutic modalities for cystic lymphangiomas in children. *Clinics (Sao Paulo)* 2014;69:505-8.
3. Lee BB, Kim YW, Seo JM, Hwang JH, Do YS, Kim DI, et al. Current concepts in lymphatic malformation. *Vasc Endovascular Surg* 2005; 39:67-81.
4. Acevedo JL, Shah RK, Brietzke SE. Nonsurgical therapies for lymphangiomas: a systematic review. *Otolaryngol Head Neck Surg* 2008; 138:418-24.
5. Kim KH, Sung MW, Roh JL, Han MH. Sclerotherapy for congenital lesions in the head and neck. *Otolaryngol Head Neck Surg* 2004; 131:307-16.
6. Mathur NN, Rana I, Bothra R, Dhawan R, Kathuria G, Pradhan T. Bleomycin sclerotherapy in congenital lymphatic and vascular malformations of head and neck. *Int J Pediatr Otorhinolaryngol* 2005;69:75-80.
7. Orford J, Barker A, Thonell S, King P, Murphy J. Bleomycin therapy for cystic hygroma. *J Pediatr Surg* 1995;30:1282-7.
8. Bloom DC, Perkins JA, Manning SC. Management of lymphatic malformations. *Curr Opin Otolaryngol Head Neck Surg* 2004;12:500-4.
9. Wiegand S, Eivazi B, Zimmermann AP, Sesterhenn AM, Werner JA. Sclerotherapy of lymphangiomas of the head and neck. *Head Neck* 2011;33:1649-55.
10. Cheng J. Doxycycline sclerotherapy in children with head and neck lymphatic malformations. *J Pediatr Surg* 2015;50:2143-6.
11. Shrestha A, Shrestha PM, Verma R. Is single dose povidone iodine sclerotherapy effective in chyluria? *Int Urol Nephrol* 2014;46:1059-62.
12. Lachapelle JM. A comparison of the irritant and allergenic properties of antiseptics. *Eur J Dermatol* 2014;24:3-9.
13. Lachapelle JM. Allergic contact dermatitis from povidone-iodine: a re-evaluation study. *Contact Dermatitis* 2005;52:9-10.
14. Vermeulen H, Westerbos SJ, Ubbink DT. Benefit and harm of iodine in wound care: a systematic review. *J Hosp Infect* 2010;76:191-9.
15. Gilliland JD, Spies JB, Brown SB, Yrizarry JM, Greenwood LH. Lymphoceles: percutaneous treatment with povidone-iodine sclerosis. *Radiology* 1989;171:227-9.
16. Seelig MH, Klingler PJ, Oldenburg WA. Treatment of a postoperative chylous lymphocele by percutaneous sclerosing with povidone-iodine. *J Vasc Surg* 1998;27:1148-51.