

Combined infection of ocular tuberculoma and cytomegalovirus retinitis in the same eye of a patient with human immunodeficiency virus

Sridharan Sudharshan, Rajesh B Babu¹, Nivedita Nair, Jyotirmay Biswas

Key words: Choroidal tuberculoma, Cytomegalovirus retinitis, HIV, Ocular TB, Highly active antiretroviral therapy

Opportunistic infections (OI) are common ocular manifestations in patients with human immunodeficiency virus (HIV). Lower the CD4 counts, higher the risk, especially if patients not on highly active anti-retroviral therapy (HAART). While cytomegalovirus retinitis (CMVR), the most common ocular OI, is usually seen when CD4 <50 cells/cu.mm, tuberculosis (TB) in the eye can occur at all ranges of CD4 counts. It is rare for a patient to harbor both infections in the same eye presenting with ocular manifestations together. We present one such patient with HIV with combined CMVR and ocular TB in the same eye.

A 34-year-old male with human immunodeficiency virus (HIV) infection since 4 years on irregular HAART, complained of decreased vision (DV) in the left eye (OS) since 2 weeks. He was treated with anti-tubercular therapy (ATT) for pulmonary tuberculosis (TB) 2 years ago and was on treatment for oral candidiasis and anemia at presentation. He had pancytopenia, elevated liver enzymes and low CD4 counts-25 cells/cu.mm. His best corrected visual acuity (BCVA), in the right eye (OD) was 6/6 and OS was 6/60. Anterior chamber (AC) was quiet in both eyes (OU). Fundus-OD revealed healed choroidal tubercles [Fig. 1]; OS showed necrotizing retinitis with hemorrhages arising from disc supero-temporally and a choroidal granuloma [Fig. 2]. Clinical diagnosis of bilateral ocular TB (OTB) with active cytomegalovirus retinitis (CMVR)-OS-was made. Chest X-ray confirmed pulmonary TB [Fig. 3]. Sputum showed extensive acid fast bacilli (AFB) on Ziehl-Neelsen stain [Fig. 4]. Patient was

re-initiated on ATT consisting of Isoniazid (H), Rifampicin (R), Ethambutol (E), Pyrazinamide (Z), and Levofloxacin (L), systemic ganciclovir and HAART. Unfortunately, within few days of ocular presentation, he succumbed to his systemic illness.

Discussion

Severe immunodeficiency in HIV can lead to multi-organ involvement.^[1,2] Uncommonly there is increased risk of multiple simultaneous systemic and/or ocular infections in the same patient.^[2-4] Occurrence of both CMVR and OTB simultaneously with bilateral involvement of TB, as seen in our patient, is uncommon and can be an indicator of severe immunodeficiency state. Such patients are more prone for disseminated systemic infections. Our patient who had completed ATT in the past, presented again with active radiologically proven, sputum positive disseminated TB, along with multiple ocular infections. Abnormal liver enzymes and pancytopenia, which were seen in our patient could be indicative of tuberculous invasion of liver and bone marrow (BM) which by itself can be fatal.

CMV retinitis, oral candidiasis, disseminated and extrapulmonary TB, seen in our patient are all AIDS defining illnesses. He belonged to World Health Organisation (WHO) clinical stage IV based on his systemic status.^[5]

Rapid course leading to death suggests that multiple ocular OIs are poor prognostic factors and can be an indicator of high mortality risk.^[6] Our report stresses the importance of a comprehensive multidisciplinary approach in the management of all patients with HIV. Ophthalmologists can aid HIV physicians in the early recognition and identification of severity of immune-deficiency state thus helping to reduce morbidity and mortality. Compliance to HAART and the need to identify resistance to ongoing treatment regime based on clinical status, CD4 counts, and/or HIV load is of paramount importance. Our patient was on irregular HAART resulting in a severe immunodeficiency state and AIDS. The patient developed multiple systemic infections, including disseminated systemic TB leading to death. National AIDS Control Organisation (NACO) recommends 2 H R Z E S + 1 H R Z E + 5 H R E as first line ATT while fluoroquinolones are preferred as second line drugs in case of resistance and/or intolerance to first line agents.^[7,8] Presence of asymptomatic choroidal tubercles reinforces the importance of regular ophthalmic screening. Late presentation of this patient with advanced HIV, disseminated TB and multiple OIs is a scenario faced even now in resource constrained settings especially if non-compliant to treatment.

Access this article online	
Quick Response Code:	Website: www.ijjo.in
	DOI: 10.4103/ijjo.IJO_1321_20

Medical Research Foundation, Sankara Nethralaya, ¹Drishti Eye Hospital, Bengaluru, Karnataka, India

Correspondence to: Dr. Sridharan Sudharshan, Medical Research Foundation, 18, College Road, Chennai - 600 006, Tamil Nadu, India. E-mail: drdharshan@gmail.com

Received: 05-May-2020

Revision: 21-May-2020

Accepted: 27-Jun-2020

Published: 20-Aug-2020

This is an open access journal, and articles are distributed under the terms of the Creative Commons Attribution-NonCommercial-ShareAlike 4.0 License, which allows others to remix, tweak, and build upon the work non-commercially, as long as appropriate credit is given and the new creations are licensed under the identical terms.

For reprints contact: WKHLRPMedknow_reprints@wolterskluwer.com

Cite this article as: Sudharshan S, Babu RB, Nair N, Biswas J. Combined infection of ocular tuberculoma and cytomegalovirus retinitis in the same eye of a patient with human immunodeficiency virus. *Indian J Ophthalmol* 2020;68:1965-7.

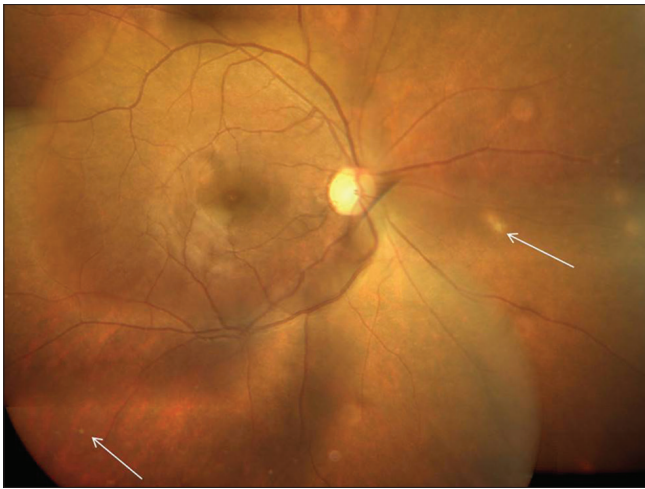


Figure 1: Color fundus montage photograph of the right eye; showing multiple small choroidal lesions suggestive of healed choroidal tubercles (white arrows)

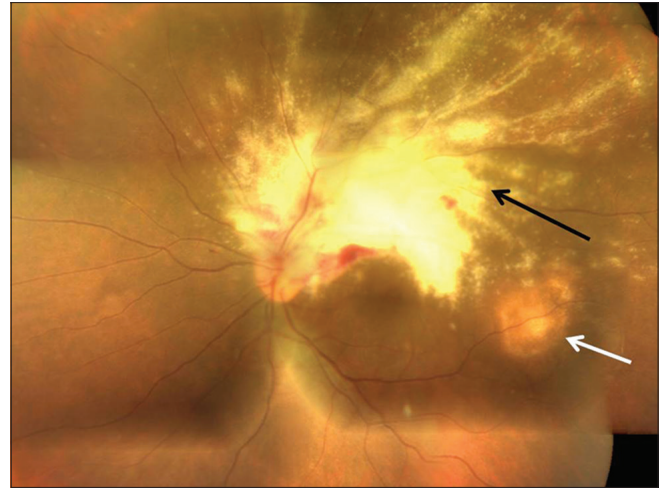

Figure 2: Color fundus montage photograph of the left eye; showing necrotizing retinitis due to cytomegalovirus along the supero-temporal arcade (black arrow) with adjacent tubercular choroidal granuloma in the posterior pole (white arrow)

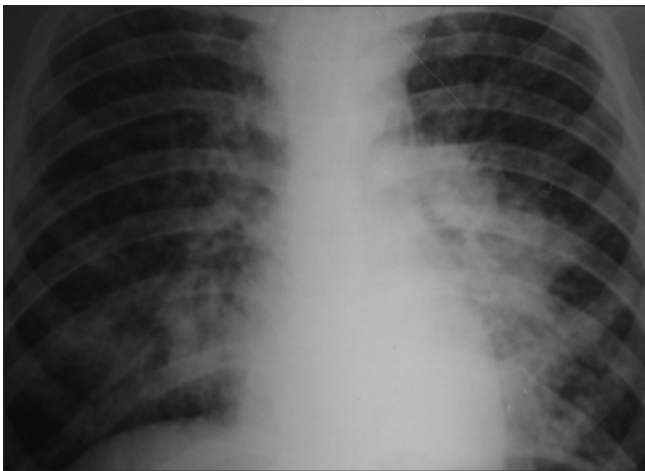


Figure 3: Chest X-ray PA view showing extensive, bilateral, mottled infiltrates in lung fields accompanied by mediastinal widening and prominent bronchovascular markings

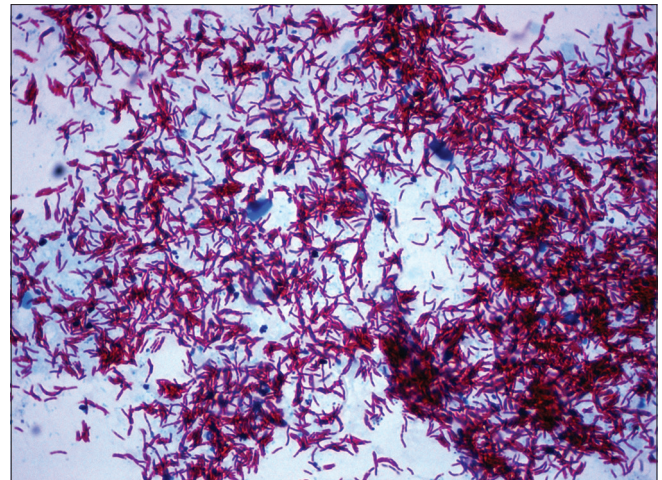


Figure 4: Ziehl-Neelsen staining of the sputum specimen showing numerous acid fast bacilli suggestive of active pulmonary tuberculosis (x200)

Declaration of patient consent

The authors certify that they have obtained all appropriate patient consent forms. In the form the patient(s) has/have given his/her/their consent for his/her/their images and other clinical information to be reported in the journal. The patients understand that their names and initials will not be published and due efforts will be made to conceal their identity, but anonymity cannot be guaranteed.

Financial support and sponsorship

Nil.

Conflicts of interest

There are no conflicts of interest.

References

- Holland GN. AIDS and ophthalmology: The first quarter century. *Am J Ophthalmol* 2008;145:397-408.
- Jabs DA, Van Natta ML, Holbrook JT, Kempen JH, Meinert CL, Davis MD, *et al.* Longitudinal study of the ocular complications of AIDS: 2. Ocular examination results at enrollment. *Ophthalmology* 2007;114:787-93.
- Shankar EM, Kumarasamy N, Rajan R, Balakrishnan P, Solomon S, Devaleenol B, *et al.* Aspergillus fumigatus, Pneumocystis jiroveci, Klebsiella pneumoniae & Mycoplasma fermentans co-infection in a HIV infected patient with respiratory conditions from Southern India. *Indian J Med Res* 2006;123,181-4.
- Artini W, Sjamsoe S, Susiyanti M. Challenging treatment of bilateral multiple infection panuveitis in HIV/AIDS patients. *Int J Ophthalmol* 2018;11:1066-70.
- WHO case definitions of HIV for surveillance and revised clinical staging and immunological classification of HIV-related disease in adults and children. Available from: <https://www.who.int/hiv/pub/guidelines/HIVstaging150307.pdf?ua=1>. [Last assessed on 2006 Aug 07].
- Jabs DA, Holbrook JT, Van Natta ML, Clark R, Jacobson MA, Kempen JH, *et al.* Risk factors for mortality in patients with AIDS in the era of highly active antiretroviral therapy. *Ophthalmology* 2005;112:771-9.

-
7. The Guidelines on Prevention and Management of TB in PLHIV at ART Centres. Available from: http://naco.gov.in/sites/default/files/Guidelines%20on%20Prevention%20%26%20Management%20TB%20in%20PLHIV_08Dec16%20%281%29.pdf. [Last assessed on 2016 Nov 25].
 8. Pranger AD, van der Werf TS, Kosterink JGW, Alffenaar JWC. The role of fluoroquinolones in the treatment of tuberculosis in 2019. *Drugs* 2019;79:161-71.
-