

Cytomegalovirus-associated esophageal ulcer in an immunocompetent infant: When should ganciclovir be administered?

Hyo-Jeong Jang, MD¹, Ae Suk Kim, MD², Jin-Bok Hwang, MD¹

¹Department of Pediatrics, Keimyung University School of Medicine, Daegu, ²Department of Pediatrics, Dongguk University College of Medicine, Gyeongju, Korea

Received: 24 May, 2012, Revised: 20 July, 2012
 Accepted: 20 August, 2012

Corresponding author: Jin-Bok Hwang, MD
 Department of Pediatrics, Keimyung University Dongsan Medical Center, Keimyung University School of Medicine, 56 Dalseong-ro, Jung-gu, Daegu 700-712, Korea
 Tel: +82-53-250-7331, Fax: +82-53-250-7783
 E-mail: pedgi@kmu.ac.kr

Copyright © 2012 by The Korean Pediatric Society

Cytomegalovirus (CMV)-associated esophageal ulcer is rare in immunocompetent infants. The presence of inclusion bodies and immunohistochemical staining for CMV in biopsy specimens obtained during esophagogastroduodenoscopy (EGD) indicate that such ulcers occur because of CMV infection. A 7-week-old female infant who experienced frequent vomiting and feeding intolerance was diagnosed with a massive CMV-associated ulcer in the distal esophagus. The ulcer improved after conservative treatment using proton-pump inhibitors; however, ganciclovir was not administered. In a follow-up EGD biopsy specimen, no CMV inclusion bodies were present, and immunohistochemical staining results for this virus were negative. The presence of CMV inclusion bodies indicates active viral replication. If persistent inclusion bodies or positive immunohistochemical staining for CMV is observed in follow-up biopsy specimens, ganciclovir may be used to treat CMV-associated esophageal ulcers.

Key words: Cytomegalovirus, Esophageal ulcer, Ganciclovir

This is an open-access article distributed under the terms of the Creative Commons Attribution Non-Commercial License (<http://creativecommons.org/licenses/by-nc/3.0/>) which permits unrestricted non-commercial use, distribution, and reproduction in any medium, provided the original work is properly cited.

Introduction

Postnatally acquired cytomegalovirus (CMV) infection is a common finding for opportunistic viral infections, especially in immunocompromised patients, and can manifest as severe disease. Localized disease due to CMV causes significant morbidity and mortality exclusively among patients in the late phase of a severe debilitating condition, but may rarely occur in the immunocompetent^{1,2)}.

In a report published in the *J Pediatr Gastroenterol Nutr*³⁾, one of the authors (JBH) presented the first case of an esophageal ulcer associated with CMV infection in an immunocompetent infant.

In this case, symptoms and the esophageal ulcer were not improved by 2 weeks of conservative treatment with proton pump inhibitor (PPI), and inclusion bodies and immunohistochemical staining for CMV persisted in follow-up endoscopic mucosal biopsy specimens. However, the use of ganciclovir for three weeks resulted in the rapid improvement in vomiting and oral intake and a marked reduction in the lesion of the esophageal ulcer.

Recently, we experienced another case of esophageal ulcer due to CMV infection in a 7-week-old immunocompetent infant. However, this ulcer responded to conservative treatment with PPI without ganciclovir. Thus, we asked the question; ‘When should ganciclovir therapy be administered to immunocompetent infants with a CMV

esophageal ulcer?

Case report

A previously healthy 7-week-old female infant presented with aggravated vomiting (4 to 5 times daily) and feeding intolerance of 10 days duration. Her perinatal course was uneventful, and she thrived with formula feeding. A physical examination revealed generalized lethargy with mild dryness of oral mucosa. Her body weight was in the 25 percentile (birth weight was in the 50 percentile). The abdomen revealed no hepatosplenomegaly. Laboratory data showed a white blood cell count of $12,740/\text{mm}^3$ with a normal differential cell count, hemoglobin of 9.3 g/dL , and a platelet count of $311,000/\text{mm}^3$. The serum electrolytes, creatinine and blood urea nitrogen, aspartate aminotransferase, and alanine aminotransferase were normal. Cultures of blood, urine, and stool were negative. A stool examination showed negativity for occult blood, and the rotavirus stool test was negative. C-reactive protein was 2.26 mg/dL . Ultrasonography showed no evidence of abnormally thickened pyloric muscle or of an elongated pyloric canal. A barium meal study showed gastroesophageal reflux (GER) grade II and an ulcer-like lesion in the distal esophagus (Fig. 1A). Esophagogastroduodenoscopy (EGD) revealed a huge ulcer with multiple erosions (Fig. 1B). A cow's milk elimination test with protein hydrolysate was performed, but no clinical response was observed. Eosinophilic esophagitis was excluded by microscopic findings. The frequency of vomiting improved to 2 to 3 times per day after starting PPI. Serology for human immunodeficiency virus, Toxoplasma, herpesvirus, and Epstein-Barr virus infections were all negative. However, enzyme-linked immunosorbent assay titers were positive for CMV immunoglobulin M and urine polymerase chain reaction also indicated positivity for CMV. A second EGD performed 2 weeks after the initiation of PPI

showed that the erosions had disappeared and the esophageal ulcer was improved in terms of size and depth. First and second endoscopic biopsy specimens from the esophageal ulcer were reviewed and inclusion bodies and immunohistochemical staining for CMV were positive in the 1st specimens but negative in the 2nd specimens. Both lymphocyte subset and immunoglobulins were within normal limits, and brain magnetic resonance imaging, an auditory evoked potential test, and ophthalmological examination showed normal findings. PPI was prescribed for a total of 1 month, but ganciclovir was not administered. After discharge, the patient showed good weight gain and no symptoms of vomiting or feeding intolerance. A follow-up barium meal study performed at 8 months of age showed normal findings and no evidence of an esophageal ulcer, stricture, or GER.

Discussion

CMV infections can affect any part of the body, including the gastrointestinal tract, central nervous system, eyes, and liver⁴. Inflammation of the gastrointestinal tract is associated with clinical manifestations, and if the opportunity for treatment is missed, ulcers eventually aggravate and can be led to potentially fatal complications, such as, gastrointestinal bleeding and perforation develop⁵.

Although rare, immunocompetent infants may develop a CMV-associated esophageal ulcer³. Hepatosplenomegaly, increased aminotransferase, or failure to gain weight with vomiting may be manifestations of a CMV infection. Identification of the virus in biopsy specimens using histological or immunohistological techniques indicates the presence of organ disease and may lead to diagnosis. Thus, though an infant may have been previously considered healthy with a normal immune status, active endoscopic evaluation and the use of these techniques could aid the diagnosis of undetermined or unique gastrointestinal lesions⁶.

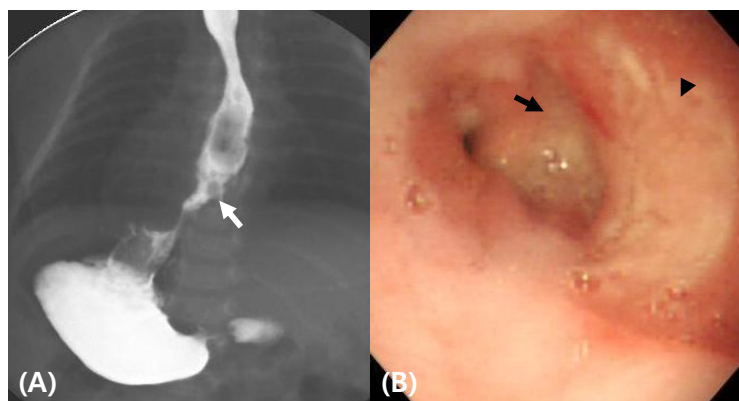


Fig. 1. A barium meal study showing an ulcer-like lesion (arrow) in the distal esophagus (A). Esophagogastroduodenoscopy reveals a massive ulcer (arrow) with esophagitis (arrowhead) (B).

Due to the possible side effects of ganciclovir therapy, its use in infants with a CMV infection is indicated only under limited conditions, notably when a patient has an immunocompromised status or an immunocompetent patient follows an unstable or deteriorating course⁷. Ganciclovir as a guanosine analog selectively inhibits CMV DNA polymerase. Its side effects include myelosuppression with leucopenia, thrombocytopenia, hepatotoxicity, and azoospermia and teratogenesis in males, whereas foscarnet, which is a competitive inhibitor of the viral DNA polymerase, can perturb mineral and electrolyte homeostasis and induce nephrotoxicity. Furthermore, the long-term administration of these medications may lead to the emergence of resistant viral strains⁴.

In the first reported case of CMV-associated esophageal ulcer in an infant³ and also in the present case, hosts were not immunocompromised and their conditions were stable. Nevertheless, in the first reported case, cure was achieved with ganciclovir, whereas our patient responded to conservative treatment with PPI. We wondered whether any histopathologic factor indicates the use of ganciclovir in immunocompetent patients. The presence of CMV inclusion bodies implies active viral replication leading to pathological lesions⁸.

In a previous study by Kim et al.⁹, although an immunocompetent adult with CMV colitis did not improve on conservative treatment, improvement was achieved by ganciclovir after the presence of specific inclusion bodies had been confirmed by sigmoidoscopic biopsy specimens during follow-up. On the base of this adult case and of our two cases, we suggest that the presence of persistent inclusion bodies and positive immunohistochemical staining in follow-up biopsy specimens are clinical indicators favoring ganciclovir treatment for a CMV esophageal ulcer. Furthermore, it should be borne in mind that multiple biopsies in the margin and base of lesions are needed to

detect CMV inclusion bodies and immunohistochemical staining positivity¹.

References

1. Alanazi AH, Aldekhail WM, Jewell L, Huynh HQ. Multiple large gastric ulcers as a manifestation of cytomegalovirus infection in a healthy child. *J Pediatr Gastroenterol Nutr* 2009;49:364-7.
2. Arnar DO, Gudmundsson G, Theodors A, Valtysson G, Sigfusson A, Jonasson JG. Primary cytomegalovirus infection and gastric ulcers in normal host. *Dig Dis Sci* 1991;36:108-11.
3. Hwang JB, Park MH, Lee BY, Choi WJ, Kim CS, Lee SL, et al. Clinical quiz. Cytomegalovirus infection. *J Pediatr Gastroenterol Nutr* 2006;42:607-8.
4. Rafailidis PI, Mourtzoukou EG, Varbobitis IC, Falagas ME. Severe cytomegalovirus infection in apparently immunocompetent patients: a systematic review. *Viol J* 2008;5:47.
5. Ukarapol N, Chartapisak W, Lertprasertsuk N, Wongsawasdi L, Kattipattanapong V, Singhavejsakul J, et al. Cytomegalovirus-associated manifestations involving the digestive tract in children with human immunodeficiency virus infection. *J Pediatr Gastroenterol Nutr* 2002;35:669-73.
6. Galiatsatos P, Shrier I, Lamoureux E, Szilagyi A. Meta-analysis of outcome of cytomegalovirus colitis in immunocompetent hosts. *Dig Dis Sci* 2005;50:609-16.
7. Tezer H, Devrim I, Kara A, Cengiz AB, Secmeer G. Ganciclovir therapy in an immunocompetent child with resistant fever and hepatosplenomegaly due to cytomegalovirus infection. *Who and when to treat? Int J Infect Dis* 2008;12:340-2.
8. Patra S, Samal SC, Chacko A, Mathan VI, Mathan MM. Cytomegalovirus infection of the human gastrointestinal tract. *J Gastroenterol Hepatol* 1999;14:973-6.
9. Kim SH, Kim YS, Kim HW, Yoon HE, Kim HK, Kim YO, et al. A case of cytomegalovirus colitis in an immunocompetent hemodialysis patient. *Hemodial Int* 2011;15:297-300.