





# Treating Aging Changes of Facial Anatomical Layers with Hyaluronic Acid Fillers

Krishan Mohan Kapoor <sup>1,2</sup>

Deasy Indra Saputra <sup>3</sup>

Catherine Ellen Porter <sup>4</sup>


Ligia Colucci <sup>5</sup>

Catherine Stone <sup>6</sup>

Elian Elisabeth Anne

Brenninkmeijer <sup>7</sup>

Jake Sloane <sup>8</sup>

Karim Sayed <sup>9</sup>

Ketut Kwartantaya Winaya<sup>10</sup>

Dario Bertossi <sup>11</sup>

<sup>1</sup>Anticlock Clinic, Chandigarh, India;

<sup>2</sup>Department of Plastic Surgery, Fortis Hospital, Mohali, India; <sup>3</sup>Project Skin BMDerma Clinic, Jakarta, Indonesia; <sup>4</sup>All Saints Skin Clinic, Darlinghurst, NSW, Australia; <sup>5</sup>Clinica Ligia Colucci, Belo Horizonte, MG, Brazil; <sup>6</sup>The Face Place Medspa, Auckland, New Zealand; <sup>7</sup>Elian Brenninkmeijer Cosmetic Dermatology, Amsterdam, the Netherlands; <sup>8</sup>Infinity Skin Clinic, Surry Hill, NSW, Australia; <sup>9</sup>Faculty of Health and Social Sciences, University of South-East Norway, Drammen, Norway; <sup>10</sup>Department of Dermatology, Udayana Public University Hospital, Bali, Indonesia; <sup>11</sup>Department of Maxillo-Facial Surgery, University of Verona, Verona, Italy

**Abstract:** The aging process affects every anatomical layer of the face. Improved knowledge of how aging occurs in each anatomical layer of the face has helped evolve the facial rejuvenation strategies with HA fillers. Understanding the age-related changes in the anatomical facial layers, including their time of onset and how the changes occur in the different tissue layers, an injector can provide much more targeted and refined HA filler treatments. As fillers' use has increased, there has been a distinct shift away from procedures lifting the skin and SMAS. We can selectively target the anatomical facial layers with HA fillers for more refined and predictable outcomes. An extensive range of HA filler variants is now available. Each filler type is optimized and designed to be injected into specific tissue planes for the best results. Knowing the predictable aging changes in the different tissue layers of the face is crucial as this guides the optimum filler choice. Working knowledge of the individual characteristics of the numerous HA-based products allows for their effective placement in the correct layer. Familiarity with the correct HA product may also help to minimize the downtime and risk of adverse events.

**Keywords:** facial aging, facial anatomy, filler injections, filler procedures, fillers, hyaluronic acid, filler complications

## Introduction

The human face has a complicated and layered arrangement consisting of skin, subcutaneous fat, muscles, deep fat compartments, retaining ligaments, and bones. While the skin's aging changes are visible, changes at the bone level can only be fully appreciated radiologically. When HA fillers were first used for cosmetic rejuvenation, aging of the fat pads, muscle layer, and retaining ligaments were largely ignored, and treatments were targeted in the skin layer. Recent studies have outlined changes in the remaining layers of the face, including superficial fat, deep fat, the muscle layer, and retaining ligaments. All of the facial layers change with age, and people in different age groups have individual needs. These broadly include correcting fine lines and wrinkles, improving skin sagging, and restoring facial volume loss. Treatments for facial aging should offer corrective techniques that address skin sagging, the repositioning, and restoration of fat pad volumes, impact the functioning of the muscles, and the reversal of fat and bone atrophy, tailored to each patient's needs.<sup>1,2</sup> The use of HA fillers has revolutionized the management of age-related changes in various layers of the face. We now have numerous subtypes of HA fillers with varying characteristics that can be used in each specific anatomical layer of the face.

Correspondence: Krishan Mohan Kapoor  
Anticlock Clinic, #1508, Sector 33 D,  
Chandigarh, 160022, India  
Tel +91-9814600600  
Email kmkapoor@gmail.com

In this narrative review, the available evidence to identify the aging changes of the facial layers and the role of HA filler injections are summarised. For each facial layer, the appropriate literature has been outlined and discussed.

## Discussion

### Age-Related Changes in Various Facial Layers

#### Aging Changes in the Skin Layer of the Face (Layer 1)

The biological clock affects the skin in the same way as it affects the internal organs. However, as the external and most visible layer, the skin shows the most commonly recognized aging signs. It is affected by intrinsic and chronological aging and extrinsic aging<sup>3</sup> factors, including UV radiation, infrared and visible light, smoking, and nutrition. All these stimuli combined are called the aging skin exposome.<sup>4</sup>

HA is one of the prominent skin glycosaminoglycans produced by fibroblasts and keratinocytes. It can hold water molecules up to 1000 times the molecular weight<sup>5</sup> and is found in the epidermis, dermis, and extracellular matrix (ECM). Skin HA accounts for almost 50% of the total body HA. Skin HA cross-links with other ECM proteins, including collagen, improving the tissues' robustness and has a shock-absorbing role in the skin.<sup>5,6</sup>

Reduced HA during aging manifests as dry, thin, and wrinkled skin. The significant findings related to aging skin are progressive fragmentation of the dermal ECM and decreased production of crucial ECM components, such as type I collagen. The dermal elastic fibers become disorganized, and the epidermal mitochondrial network becomes more fragmented with age.<sup>7</sup> These changes result in a loss of skin elasticity and the formation of drier, thinner skin<sup>8</sup> with more rhytids.

Loss of volume is a hallmark of aging and results from age-dependent degradation of ECM components, namely, HA and collagen. In addition to the skin changes mentioned above, sagging and irregularities in the skin tone and texture are key signs of aging.<sup>9,10</sup> Functionally, the skin barrier function is also compromised.

#### Aging Changes in Superficial Fat Layer of the Face (Layer 2)

The superficial fat of the face is found between the skin and the SMAS layer. It consists of the subcutaneous fat (adipocytes and extracellular matrix), which provides volume, and the fibrous network of collagenous fibers or retinacula cutis (RC) binding the dermis to the underlying

SMAS. Rohrich and Pessa have shown that the superficial fat is arranged into distinct compartments defined within septal boundaries that correspond to the retaining ligaments' location, which pass superficially to insert into the dermis.<sup>12,13</sup> These fibrous septae serve as sheltered transit pathways for cutaneous nerves, vessels, and lymphatics. The subcutaneous fat compartments vary in size and extent and are continuous with the general fat in the body.<sup>14</sup> The superficial fat compartments seem to have different morphological characteristics to the deep fat compartments.<sup>15</sup>

In youth, there is a smooth non-discernible transition between the compartments. With age, a series of concavities and convexities develop, which separate these compartments.<sup>16</sup> It is proposed that with age, selective deflation of the deep fat and bony skeleton along with ligamentous fatigue leads to loss of support and the appearance of the descent of the overlying superficial fat, thereby contributing to the ptotic appearance of the aging face.<sup>11,14</sup> It has been postulated that age-related volume loss begins in the superficial compartment laterally and transitions medially.<sup>17</sup> However, there is no convincing research to suggest that aging affects any superficial compartment preferentially.<sup>18</sup> The perioral area's superficial fat has small numbers of fat cells interwoven within a meshwork of collagen fibers that is much more adherent to the skin,<sup>14</sup> and the septae separating the compartments in this region manifest as perioral rhytids.<sup>17</sup> The change in the subcutaneous arrangement between the firm perioral attachment and the loose, layered arrangement of the remaining facial regions underlies the formation of the nasolabial and labiomandibular sulci.<sup>19</sup>

#### Aging Changes in the SMAS/ Muscle Layer of the Face (Layer 3)

The SMAS layer plays an integral part in facial aging due to its relationship with the mimetic muscles. In many regions of the face, the facial vasculature demonstrates an intimate relationship with the SMAS, particularly in the jawline, perioral, nasolabial fold, infrabrow, and temple regions.<sup>20</sup> The mimetic muscles connect the dermis to the deep facial structure and function to create facial expressions by contraction. The masticatory muscles connect bone to bone and influence the mandible movement.<sup>21</sup>

Dynamic (expression) lines of the skin are the result of muscle contraction in the SMAS layer. The skin, superficial fat, and muscle layers are tightly bound to each other, and muscle contraction gives rise to wrinkles in

the skin, perpendicular to muscle fibers' direction. These are transient in youth but become permanent due to skin atrophy, superficial fat loss in some areas, and muscle hyperactivity. Wrinkles due to muscle actions are predictably observed in the glabella, forehead, periocular, and perioral regions, the chin, and depressor anguli oris (DAO) territories. The clinical effect of these changes is due to a general tightening of the facial muscles, with a limited amplitude of facial expression. These permanent contractions result in a potential shifting of fat, an accentuation of skin creases, and permanent skin wrinkling. The dynamic facial lines eventually evolve into lines of a static nature.<sup>14</sup> It is essential to know a muscles' location and depth to understand the dynamic movements of the face that displace the filler and make it visible with the action of the muscles.<sup>22</sup>

#### Aging Changes in Deep Fat Layer of the Face (Layer 4)

The deep fat layer appears to have a different tissue structure compared to the superficial fat pads. Deep facial fat pads include the deep pyriform, deep medial cheek, deep nasolabial (in the premaxillary space), retro-orbicularis oculi (ROOF), and both medial and lateral suborbicularis oculi (SOOF).

Volume deflation of the deep fat compartments with age is thought to be the primary mechanism that causes the loss of deep support of the face,<sup>13,24–27</sup> leading to “pseudoptosis” of the overlying superficial soft tissues. While inferior migration of the fat compartments and increased distance between the fat pads are thought to contribute to aging changes,<sup>12,13,23</sup> more recently, it was found that the location and extent of the deep fat compartments remain relatively stable with age, once adjusted for age-related skeletal changes.<sup>26</sup>

Loss of volume in the deep compartments in the upper third - the retro-orbicularis oculi fat (ROOF), deep temporal fat, and temporal extension of the deep buccal fat pad – are thought to result in the hollowing of the temple and descent of the brow. The middle third displays the most visible signs of aging, primarily attributed to deflation of the deep medial cheek fat compartment (DMCFC). These changes result in loss of anterior projection of the cheek, sagging of the superficial compartments, deepening the nasolabial fold and nasojugal groove, and revealing the tear trough.<sup>13,23,25</sup> The elasticity of the DMCFC gets reduced with age and increased BMI, suggesting changes to the fat ultrastructure and metabolism.<sup>27</sup> Volume loss in

the deep fat pads of the lower third of the face leads to loss of support for the lips (via the upper and lower sub-orbicularis oris fat pads) and deepening of the labiomental crease.<sup>23</sup> Buccal fat descent and extension of the buccal space with age contribute to the jowls.<sup>28,29</sup>

#### Aging Changes in Retaining Ligaments of the Face

The facial retaining ligaments are strong and deep fibrous attachments that originate from the periosteum or deep facial fascia and travel perpendicularly through facial layers to insert onto the dermis.<sup>30</sup> These ligaments are located in specific anatomic locations where they separate facial spaces and compartments. Their superficial extensions form the subcutaneous septa that separate facial fat compartments.<sup>31</sup>

As the skin of the face has consistent attachments to the underlying structures through the retaining ligaments, these points of attachment define most of the shadows that develop on the face due to age-related facial volume deflation.<sup>32</sup> It has been postulated that ligaments might not undergo age-related changes.<sup>33</sup> Most of the ligament-related change is in the multiple fine retinacular ligaments, which branch from the SMAS through the subcutaneous layer to the dermis, which is more prone to being weakened over time by repetitive movement.

The zygomatic and mandibular ligaments - two ligament structures that support the facial soft tissues - develop minimal, if any, laxity between their origin and their connection with the SMAS, although some weakening of the mandibular ligament occurs superficially to the SMAS. Minimal aging change has been seen in the upper masseteric ligaments, in contrast to the masseteric ligaments below the oral commissure. Since these are located in the most mobile area associated with jaw opening, they tend to weaken and stretch relatively early in the aging process.<sup>34</sup> Due to age-related bone changes, the points of origin of ligaments and their firm adhesions to the skin and other adjacent structures are affected. These changes lead to alteration in the position of the ligament and its course. The lack of stability in the ligament, which serves as a hammock for the fat, promotes sagging of the respective fat compartment.<sup>14</sup>

#### Aging Changes in the Bones of the Face (Layer 5)

Bone forms the deepest layer of the face and provides the structural framework for the soft tissues. This structural component of the face creates a unique three-dimensional contour<sup>35</sup> and is covered by the periosteal layer. The facial

bones, like the rest of the skeleton, undergo continual and lifelong remodelling.<sup>14</sup> Aging of the facial skeleton can be observed to start, independent of gender, between 20 and 29. This aging process continues throughout our lifespan.<sup>36</sup> Bone remodeling, irrespective of changes to the more superficial layers of the face, will directly correlate to facial aging signs.

Many studies have demonstrated bony aging observations but have often reported varying conclusions. Such studies are prone to high variability due to small sample numbers, inter-individual, gender-related differences,<sup>36</sup> and ethnic considerations.<sup>37</sup> However, it is now agreed that several predictable signs can be seen in facial bone aging and occur in sequential order. These include changes to the facial angles, the maxilla, the pyriform aperture, and the mandible.<sup>38</sup> Aging of the facial skeleton involves selective remodeling at specific sites, including a change in the size and the contour of the orbit; a reduction in the glabellar angle (maximal prominence of glabella to nasofrontal suture), and maxillary angle (superior to inferior maxilla at the articulation of the inferior maxillary wing and alveolar arch); and an enlargement of the size of the pyriform aperture.<sup>39</sup>

The changes which can be observed in the facial skeleton morphology are directly linked to the cosmetic changes of the face. The visible signs of skeletal aging include flattening of the mid-face bones, a gradual retrusion of the bony chin and pyriform fossa, and blunting of the mandible angle and jawline shape. Indirectly, it follows suit that if the bony foundation of the face changes, the retaining ligaments' position, the overlying fat compartments, and the other tissue layers will also be influenced.

## Hyaluronic Acid Fillers and Their Role in Treating Various Anatomical Layers of the Face

Hyaluronic acid (HA) is a glycosaminoglycan (GAG), widely present in the extracellular matrix (ECM) of the connective tissue and epithelial tissue in the body. This mucopolysaccharide consists of repeating disaccharide units, which form long coiling threads that vary in length and molecular weight, ranging from 10 to 1000 kDa. HA is a biodegradable compound with hydrophilic properties and has very low immunogenicity.<sup>40</sup> It has a cycle of synthesis and degradation, with a half-life in the dermis of about one day.

Viscoelastic and hydrophilic properties make HA a gel-like substance, and therefore HA is highly suitable for use as an injectable filler in aesthetic treatments. In manufacturing, the individual chains of HA can be linked with chemical bonds in a process known as cross-linking. The degree of cross-linking affects the viscoelastic properties and lengthens the half-life of the HA filler compared to endogenous HA.<sup>41</sup> In addition to the degree and type of cross-linking, HA fillers can also vary in concentration and particle size. These properties affect the viscoelastic characters and the half-life and, thus, the aesthetic treatments' outcome and longevity. It means that the manufacturer can tailor the fillers to suit different types of aesthetic treatments.<sup>42</sup>

HA fillers exhibit both viscous and elastic behaviour. The science of deformation and flow of matter is known as rheology. The rheology of HA fillers is complex, but it can be simplified as the filler's resistance to compression/stretching, its resistance to shear forces, its ability to retain its shape after being subjected to these forces, its flow properties, and the stiffness of the filler.<sup>43</sup>

The elastic modulus is known as  $G'$  and determines the filler's ability to retain its original shape after being subjected to stretching. A rubber band is likely to return to its original shape after being stretched; this is elastic behaviour. The viscous modulus is known as  $G''$  and determines the material's flow while it is deformed. A piece of chewing gum will not return to its original form after it has been stretched, which is related to the viscous flow property. Fillers tend to have a relatively low  $G''$  as they are not subjected to high forces in the tissue. However,  $G''$  is crucial as it will determine the extrusion force, which is the force needed to expel the filler from the syringe.<sup>44</sup>  $G^*$  is the complex modulus, the total energy needed to deform the HA gel using shear stress. The complex modulus can be considered the "hardness" of the filler and determined by  $G'$  and  $G''$ . Cohesivity is the gel "stickiness" determined by the forces between the chains of HA. A filler with high cohesivity will be able to maintain its shape even when subjected to compression.

The clinician must understand the HA filler's rheological properties to choose the correct filler for the aesthetic treatment at hand (Table 1). The results must also last for a reasonable amount of time to have an acceptable cost-benefit for the patient. A filler placed superficially must be softer and smoother than a filler placed deep on the bone for volumization, which must be "stiff" to have a lifting effect for the overlying tissue. When using fillers more superficially,

**Table 1** Filler Procedure, Target Facial Layer Injected, and Type of HA Filler Used

HA Filler Procedure	Outcome	Layer	Type of Filler Used	Example
Skin Boosting	Enhancing skin quality	Dermis	Very Low viscosity; Low elasticity G'; Low cohesivity; Non or low crosslinked materials	Restylane vital, Juvederm volite, Teosyal RD1, Belotero Hydra
Smoothing	Fine wrinkle correction	Dermis, Superficial fat	Medium viscosity; Moderate elasticity G'; Low-medium cohesivity.	Juvederm Volite, Juvederm Volbella, Belotero soft, Restylane refine, Teosyal RHA1-2
Volumization	Replacing the volume loss associate with aging	Superficial fat, Deep Fat Layer	Low viscosity; Low-medium G'; Low-medium cohesivity	Juvederm Volift, Juvederm Voluma, Teosyal RD3-4, Belotero Balance, Belotero volume, Restylane Define, Restylane Volyme
Lifting	To give support for sagging facial layer associate with gravity	Deep Fat, Supraperiosteal, Retaining Ligaments	Low-medium viscosity; Medium-high elasticity (G'); Medium-high cohesivity.	Juvederm Voluma, Juvederm Volux, Teosyal RD 4, Teosyal Ultradeep, Belotero Volume, Belotero Intense, Restylane Define, Restylane
Contouring	Make a better face shape by taking light and shadow into consideration	Deep Fat, Supraperiosteal	Medium to high viscosity; High elasticity high G'; High cohesivity.	Juvederm Voluma, Juvederm Volux, Teosyal Ultradeep, Belotero Intense, Restylane

for example, for fine lines, a filler with a relatively low cohesivity is needed; otherwise, the filler will not spread, and will not be mouldable, which will increase the chance of uneven results and superficial nodules in the skin.

Fillers placed deep in areas like the midface, the temporal fossa, or the jawline must have the high elasticity to retain their shape even when subjected to shear forces and the force of gravity (Table 2). Deeply placed fillers also require medium to high cohesivity to give the desired lifting effect and withstand the compression from the overlying tissue. Similarly, to have a long-lasting lifting effect, fillers placed in tight areas like the chin must have high cohesivity to withstand compression. Otherwise, the filler will spread laterally, losing the initial lift and resulting in poor longevity of effect, not because the filler is gone but because the filler has spread out. Fillers placed in highly mobile areas like the

marionette lines must have a relatively high elasticity to withstand the shear forces due to the tissue's movement. If a filler used in these areas has high cohesivity, very precise injections must be performed as this less mouldable filler may cause surface irregularities.

### Role of Hyaluronic Acid Fillers in the Skin Layer of the Face

Hyaluronic acid fillers have a role in reversing the unwanted visible signs of aging and improving skin quality. With age, there is less collagen and a more significant proportion of fragmented collagen in the skin. These changes lead to a reduction in mechanical tension of ECM and less collagen synthesis. With HA's addition to the dermis of the aging skin, nearby fibroblasts become morphologically stretched and activated and produce

**Table 2** Impact of HA Filler Injection Procedure for Different Facial Layers

Layer Injected	Injected Volume	Depth	Device	Outcome	Layer Elevated
Skin	Small	Very superficial	Mostly needle	Localised	0
Superficial fat	Small to medium	Superficial	Needle/cannula	Localised	1
Deep fat	Large	Deep	Needle/cannula	Diffuse	3
Supra periosteal	Large	Very deep	Mostly needle	Diffuse	4 except temple, lateral cheek/ jawline

extracellular matrix components, including new collagen. Increased mechanical tension in the ECM has also been shown to induce morphologic stretching of fibroblasts and initiation of collagen and HA synthesis.<sup>45</sup>

Kerscher proposed the term “skin-boosting”, a skin quality enhancement concept without directly targeting wrinkle/volume loss with HA injection into the dermis.<sup>46</sup> NASHA 20mg (Restylane Vital) or 12mg (Restylane Vital light) monthly for three sessions has been found to improve skin quality for up to 6 months.<sup>47</sup> Also, digital photographic analysis has revealed objective skin quality improvement with low HA concentration, low G' filler, VYC-12 HA (Juvederm Volite)<sup>48</sup> (Figures 1 and 2). The hydration retention effect was found to last for as long as nine months after a single treatment with VYC-12 HA (Juvederm Volite).<sup>49,50</sup> Collagen density, Brillin-1, and AQP3 (Aquaporin 3)<sup>51</sup> expression, and acidic GAG content, were found to increase following VYC-12L injection.<sup>52</sup>

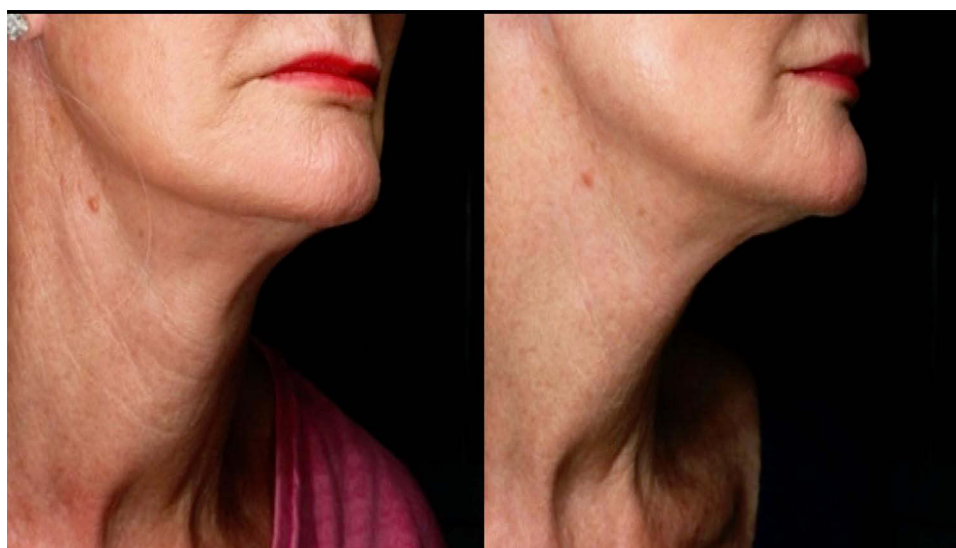It was previously thought that HA-based skin-boosting acts by directly adding dermal volume and the ability of this newly injected HA to attract water from the surrounding tissue. Injected NASHA was shown to enhance the extracellular matrix's structural support, resulting in fibroblast elongation, a subsequent increase in procollagen I, collagens I, and III production, and an increase in keratinocyte and fibroblast proliferation. The net result was overall epidermal thickening and the formation of new dermal vasculature.<sup>53,54</sup> HA injected in

the skin layer leads to the synthesis of new collagen, elastin, HA, and improved hydration, better texture or less roughness, less appearance of fine lines, and enhanced skin elasticity. As the restoration of structural ECM is the primary mechanism for rejuvenating the dermal component and its function, HA's degradation is not the primary determinant of the treatment's longevity.

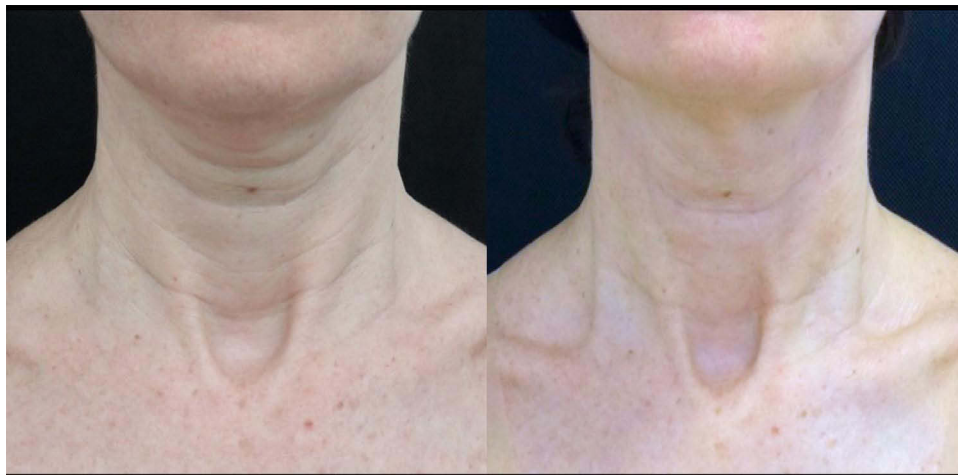### Role of Hyaluronic Acid Fillers in Superficial Fat Layer of the Face

The superficial fat can be a target for filling with HA filler, as the volume within the superficial fat compartments may support and give turgor to the cutaneous structures and gauge the distribution of tension within the collagenous subdermal fibers (RC).<sup>17</sup> It is recommended to inject perpendicular to the skin tension lines when treating this layer.<sup>51</sup>

However, care should be taken as to which superficial fat compartments are injected, as fat compartments behave differently with the injection of filling material. The inferior aspect of the nasolabial, middle cheek and jowl fat compartments descend on filling, deepening the nasolabial and labiomandibular sulci appearance. In contrast, injections of soft-tissue filler into the superficial temporal compartments or the superficial medial cheek compartment were associated with an increase in the local volume and an increase in the soft-tissue projection that induced a lifting effect in the middle or lower face.<sup>55</sup> Filling the lateral temporal-cheek fat can also have an indirect lifting effect on the mid and lower



**Figure 1** Before and after pictures of a patient treated for skin quality fillers. Treatment description: Neck- Juvederm Volite, 1mL per side, in the most superficial layer of skin using a needle. (contributed by Catherine Ellen Porter).



**Figure 2** Before and after pictures of a patient treated for skin quality fillers. Treatment description: Neck- Juvederm Volite, 2mL total, in the superficial subcutaneous layer using a needle; Face- Juvederm Volite, 1mL each side, in the superficial subcutaneous layer using a needle. (contributed by Ligia Colucci).

face that has been shown by using skin displacement vector analysis<sup>56</sup> (Figures 3 and 4). When filling the superficial fat of the temple in a subcutaneous plane, the lifting effect on the lower face was lost if a fanning technique was used, disrupting the binding septae, the temple skin was lax, or more than 1cc was used. Product choice depends on soft tissue coverage and degree of hollowing.

A recent study found that when treating the cheek, if injections were done lateral to the line of ligaments first, the volume injected into the medially located points to achieve an aesthetically pleasing outcome is less.<sup>57</sup> Perhaps this could be extrapolated to treating the lateral temporal cheek fat (now shown to be two separate compartments separated by the zygoma) before treating the midface to minimize the product's volume needed.<sup>58</sup> The lateral temporal cheek fat can be injected inferior to the zygoma to improve pre auricular hollowing and have a lifting effect on the jowl.<sup>59</sup> The stability of the superficial lateral cheek fat may be due to its position on the midfacial SMAS, which is firmly adherent to the underlying parotid-masseteric fascia, limiting inferior displacement on filling.<sup>59</sup> This area is prone to irregularity if large volumes of filler are injected per site. Injection of lower G' and less cohesive products with a blunt cannula is recommended.<sup>60</sup>

Submalar or buccal hollowing can also be addressed in the superficial plane in the lower portion of the medial and middle-fat compartments. Blunt microcannulas are recommended to inject HA with lower cohesivity and good tissue

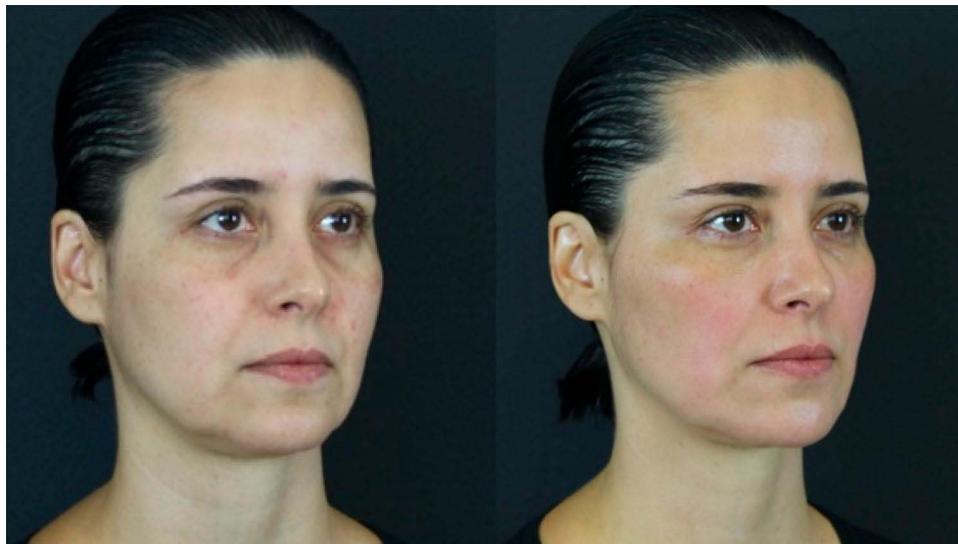integration.<sup>60</sup> However, care needs to be taken with the volumes injected in this area and not inadvertently injecting the NL fat compartment.

There are risks of edema when injecting superficially in the area between the ORL and ZC ligament, as there are minimal lymphatic channels in this area, predisposing to swelling. Damage to these vessels will disrupt drainage from the superficial fat to the deeper lymphatic channels.

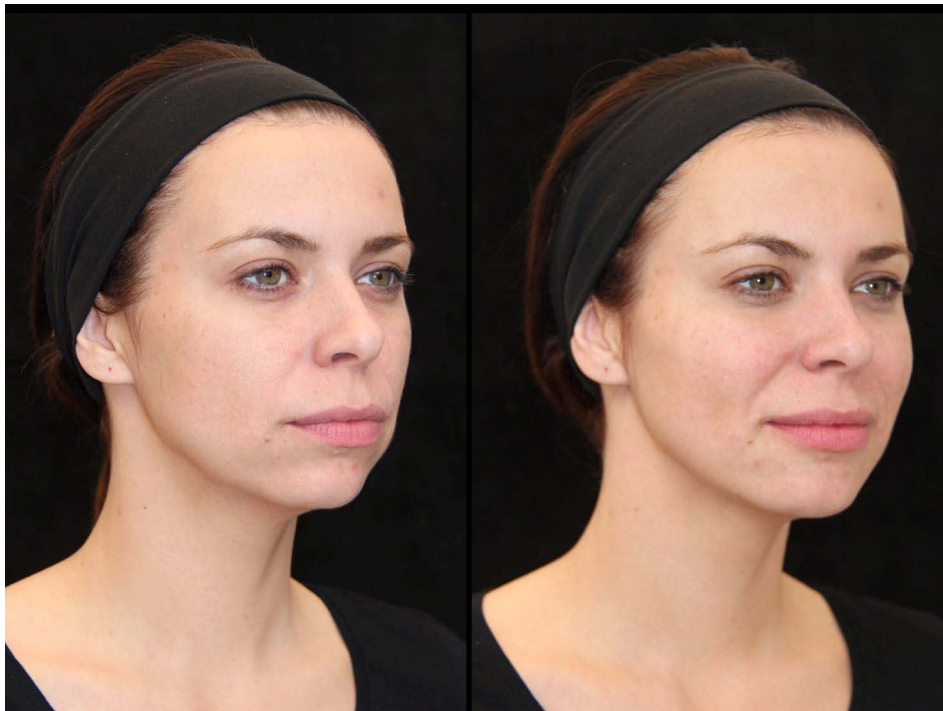The superficial fat of the lower face can be treated with HA filler. Perioral rhytids can be treated in a subcutaneous plane, as can the labiomental crease and marionette lines.<sup>61</sup> This treatment creates a smooth, uninterrupted subcutaneous layer. However, the pre-jowl sulcus and chin should be treated with a dual-plane technique using HA filler, both above and below the muscle,<sup>62,63</sup> using a combination of high G' and softer fillers. All fillers with low G' and low cohesiveness, such as Juvederm Volbella, are less viscous and are likely to spread more in the surrounding tissue after injection, thus allowing for the achievement of a hydro lift effect.<sup>64</sup>

### Role of Hyaluronic Acid Fillers in SMAS/ Facial Muscle Layer of the Face

The SMAS and facial muscle layer is quite a complicated layer with few studies about the use of HA fillers specifically for the aging changes in this layer. Levator and depressor muscles work in the opposite direction, and their interactions affect the facial appearance at rest and in dynamic expression. In youth, levators are usually stronger than depressors. Due to aging processes and fat loss, the levator muscles lose their lifting power, so the depressor muscles act with reduced opposition.<sup>65</sup> HA fillers can work mechanically to



**Figure 3** Treatment description: Lateral Cheekbone area- Juvederm Voluma, 0.1mL at 3 points each side, on periosteum with a needle; Temporal fossa: Juvederm Voluma, 0.5mL each side, on periosteum using a needle; Cheekbone projection: Juvederm Voluma, 0.2mL each side, on periosteum using a needle; Malar region- Juvederm Voluma, 0.5mL each side, in the deep malar fat pad, using a needle; Pre-auricular area- Juvederm Voluma, 0.5mL each side, in the subcutaneous layer using a cannula; Labiomental crease: Juvederm Voluma, 0.7mL each side, in the subcutaneous layer using a cannula; Chin/pogonion- Juvederm Volux, 0.3mL each side on the periosteum, using a needle; Posterior jawline/pre-auricular area- Juvederm Volux, 0.3mL each side in subcutaneous layer using a cannula; Medial to the angle of the jaw: Juvederm Volux, 0.4mL in the subcutaneous layer, cannula; Jawline- Juvederm Voluma, 0.5mL each side, in the subcutaneous layer of the pre-jowl sulcus and medial jawline using a cannula; Malar area- Juvederm Voluma, 0.5mL each side in deep malar fat pad using a cannula; Malar area: Juvederm Volift, 0.5mL each side, in SOOF layer using a cannula; Periorbital region- Juvederm Volbella, 0.5mL each side, in SOOF including tear trough using a cannula; Lips- Juvederm Volift, 0.5mL total, in the subcutaneous layer using a needle. (contributed by Ligia Colucci).



**Figure 4** Treatment description: Lateral Cheekbones area: Juvederm Voluma 0.1mL in 3 points each side on periosteum with a needle. Pre-auricular area: Juvederm Voluma, 0.7mL each side, in the subcutaneous layer using a cannula; Malar area: Juvederm Voluma, 0.5mL each side, in deep malar fat pad using a cannula; Malar area: Juvederm Volift, 0.5mL each side, in SOOF using a cannula; Temporal fossa- Juvederm Voluma, 0.5mL each side, on periosteum using a needle; Labiomental crease- Juvederm Voluma, 0.7mL each side, in the subcutaneous layer using a cannula; Chin apex/pogonion- Juvederm Volux, 0.3mL each side, subcutaneous/intramuscular (mentalis muscle) plane using a needle; Medial to marionette lines- Juvederm Voluma, 0.5mL each side, in the subcutaneous layer using a cannula; Jawline: Juvederm Voluma, 1mL each side, in the subcutaneous layer of the pre-jowl sulcus and medial jawline using a cannula; Nasolabial folds- Juvederm Volift, 0.5mL each side, in the subcutaneous layer using a cannula. (contributed by Elian Elisabeth Anne Brenninkmeijer).



change muscle movement by facilitating their action due to a lever or pulley effect or decreasing contraction by blocking their movement. A bolus of HA filler injected deeper to a muscle can increase its convexity and act as a fulcrum to cause mechanical advantage, causing increased pulling action. Conversely, injecting HA filler more superficially on the muscle may reduce contraction by impeding the muscle movement due to simple mechanical effects. HA filler treatment can help correct the structural deficiency by supporting muscles to facilitate their action and provide an obstacle to extreme muscle excursion and depressor contraction.<sup>65</sup> However, more studies are required to understand the concept of myomodulation with fillers.

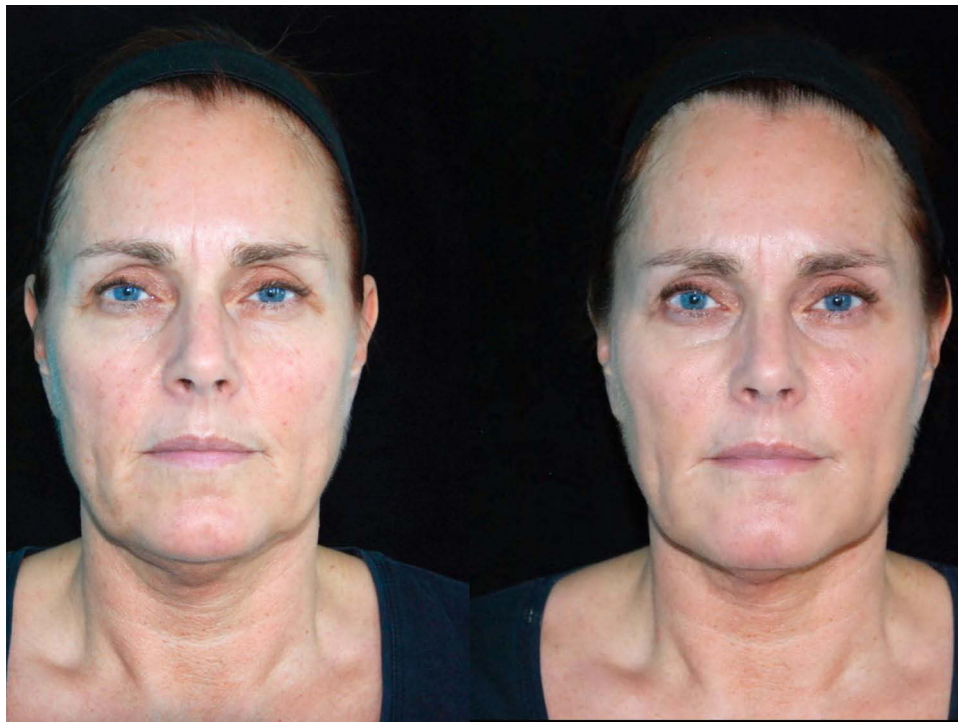A recent review suggests that agents' injection into the perioral and periorbital mimetic muscular layer may produce clumping and displacement of the product, and tendency to late nodularity and swelling. Injecting into facial muscles also risks intravascular injection compared to injection in other layers of the face. Injection in the mimetic muscles, especially the sphincteric muscles, should be avoided to minimize the risk of complications.<sup>66</sup>

### Role of Hyaluronic Acid Fillers in Deep Fat Layer of Face

The deep fat compartments of the face came to the attention of filler injectors when Rohrich and Pessa first demonstrated in their landmark 2008 paper that filling the newly defined “deep medial fat pad” of the face resulted in the recreation of a natural-looking cheek, along with effacement of the nasolabial fold, and improved anterior cheek projection.<sup>23</sup>

For restoring the deep fat pads of the face, the thicker, high G' filler products are recommended, injected on the bone.<sup>24</sup> Filler techniques used in these areas include layering, depot injections, or towering.<sup>24</sup> Replacing deep volume before filling superficially and starting from cranial to caudal is a common approach that is advocated.<sup>24</sup>

A recent study, using contrast materials with similar rheological properties to commonly used fillers, showed that increasing the volume injected did not cause inferior displacement of the injected material, supporting the premise that deep supraperiosteal injection is ideal for improving anterior projection of the midface, with support and “lifting” of the overlying tissues<sup>26</sup> (Figures 4 and 5). For



**Figure 5** Treatment description: Lateral Cheekbones: Juvederm Voluma, 0.1mL in 3 points each side, on periosteum with a needle; Pre-auricular area: Juvederm Voluma, 0.7mL each side, in the subcutaneous layer using a cannula; Malar area- Juvederm Voluma, 0.5mL each side, in the deep malar fat pad, using a cannula; Malar area: Juvederm Volift 0.5mL each side, in SOOF layer, using a cannula; Temporal fossa- Juvederm Voluma, 0.5mL each side, on periosteum using a needle; Labiomental crease- Juvederm Voluma, 0.7mL each side, in the subcutaneous layer using a cannula; Chin apex/pogonion: Juvederm Volux, 0.3mL each side, subcutaneous/intramuscular (mentalis muscle) using a needle; Medial to marionette lines- Juvederm Voluma, 0.5mL each side, in the subcutaneous layer using a cannula; Jawline- Juvederm Voluma, 1mL each side, in the subcutaneous layer of the pre-jowl sulcus and medial jawline using a cannula; Nasolabial folds- Juvederm Volift, 0.5mL each side, in the subcutaneous layer using a cannula. (contributed by Elian Elisabeth Anne Brenninkmeijer).

those familiar with MD Codes filler injection technique, the deep fat compartments relate to CK3 (SOOF) and CK1\* (Sub-SMAS along the zygoma), both of which are accessed with a cannula; while NL1 (Piriform space) and T1 (temple) are accessed with a needle.<sup>67</sup> HA is postulated to have regenerative capacity when injected into the tissues,<sup>40</sup> so it will be interesting to see if future studies show an improvement in DMCFC elasticity after repeated injections of volumizing HA fillers.


### Role of Hyaluronic Acid Fillers for Retaining Ligaments of Face

The retaining ligaments of the face are attached to the periosteum that is firmly adherent to the bone. Reduction of anterior projection and volume of the aging facial skeleton results in ligament origins receding with the bone. Surgical correction can be achieved by restoring the missing volume immediately supra-periosteally, thereby repositioning the ligament origins.

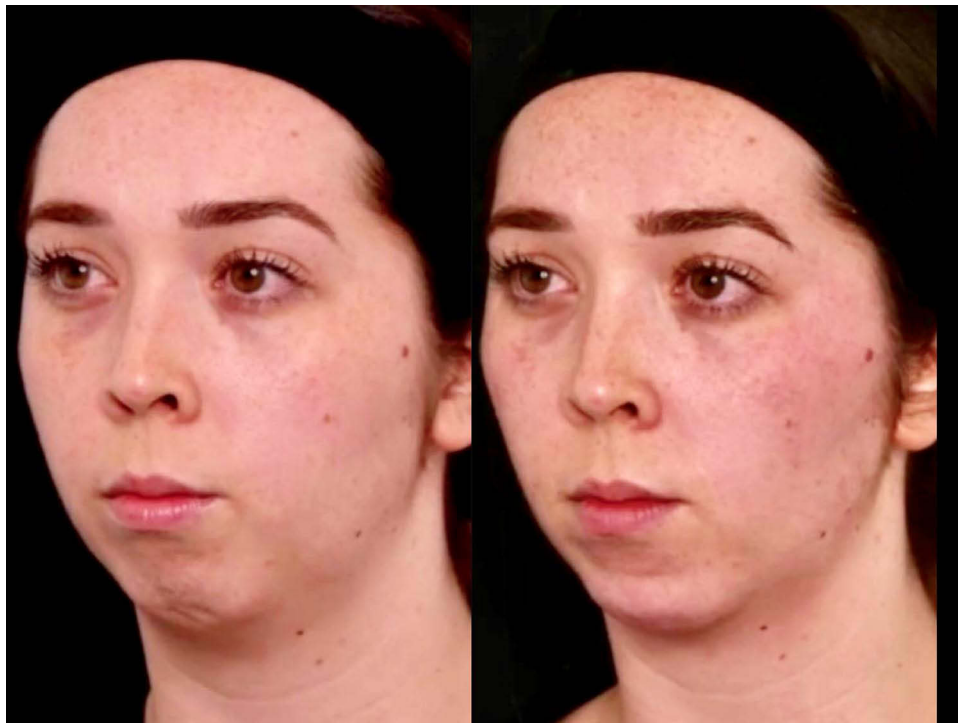A non-surgical solution is to place the HA filler deep in the supraperiosteal plane. This outward positioning provides the benefit of improving facial shape through the

muscle and ligament vectors lower in the face. This explains why deep filler placement, although effective to a degree, does not rejuvenate the way supra-periosteal volume placement does. An example is the tear trough correction, where a small to moderate volume of deep filler inferior to the tear trough ligament improves the soft-tissue projection and effectively reduces sag of the orbicularis inferior to the ligament.

There is a minimal attachment of the soft tissue to the underlying skeleton between the ligaments, and it provides an opportunity for lifting and repositioning of tissue through HA filler treatment. Retightening and stabilization of the ligaments result in repositioning of the fat pads, and this can be achieved using HA fillers with lifting capacity. Since the ligaments serve as a hammock for the fat within each compartment (superficial or deep), correct placement of HA filler can prevent and correct the appearance of sagging of the respective fat compartment. For example, with the malar fat pad injection, the lower lid vertical distance is decreased, and hollowness is eliminated in the infraorbital region.<sup>68</sup> Treating the face with HA filler lateral to the retaining (zygomatic, mandibular, masseteric) ligaments, using its lateral vectors, correction of sagginess can be achieved (Figures 3–5).



**Figure 6** Before and after pictures of a patient given filler treatment in various facial layers. Treatment description: Lateral and medial malar area- Juvederm Voluma, 0.2 and 0.3mL per side, on periosteum using a needle; Labiomental crease: Juvederm Voluma, 0.5mL each side, in the subcutaneous layer using cannula; Chin- Juvederm Volux, 1mL total, on periosteum using a needle; Angle of the jaw- Juvederm Volux, 0.3mL each side, on periosteum using a needle; Posterior jawline/pre-auricular area: Juvederm Volux, 0.3mL each side, in the subcutaneous layer using cannula; Medial to the angle of the jaw- Juvederm Volux, 0.4mL each side, in the subcutaneous layer using a cannula. (contributed by Catherine Ellen Porter).



**Figure 7** Before and after pictures of a patient treated for lower face shaping and contouring. Treatment description: Labiomenal crease- Juvederm Voluma, 0.7mL, each side, in the subcutaneous layer, using a cannula; Chin/pogonion- Juvederm Volux 0.3mL each side, on periosteum using a needle; Jawline- Juvederm Volux, 0.5mL each side, in the subcutaneous layer of the pre-jowl sulcus and medial jawline using a cannula; Angle of the jaw- Juvederm Volux, 0.5mL each side, in the subcutaneous layer using a cannula. (contributed by Jake Sloane).

### Role of Hyaluronic Acid Fillers for the Bony Layer of the Face

For many years, lifting the soft tissue layers of the face formed the mainstay of facial rejuvenation.<sup>69</sup> However, our current understanding of facial bone remodelling and the specific patterns of change with age allows us to target this layer. HA fillers have evolved, and ranges of products exist for use at specific depths or layers of the face. Fillers for bone use typically have specific rheological characteristics and are injected onto the bone to create volume and contour to the face. It is often done in combination with soft tissue filler augmentation.

For fillers to shape the face, create projection from the bone, and have good longevity, they require specific properties, including a high elastic modulus ( $G'$  prime) and a high cohesivity.<sup>70</sup> VYC-25L (Juvederm Volux) has been demonstrated to improve the glabella –subnasale–pogonion facial angle,<sup>70</sup> helping to advance the chin anteriorly forwards (Figures 6 and 7). Deep, supraperiosteal injection is designed to correct bony structural deficiencies in such patients.<sup>61</sup> In another study on 320 young Asian women treated with 0.5–1 mL, Juvederm® Voluma in the chin from periosteal to subcutaneous

layer with a 21 gauge cannula, approximately 95% of physicians and patients reported “very much” or “much” improvement on the GAIS at four weeks.<sup>71</sup> However there is a need to avoid placing big bolus of filler in this area.<sup>72</sup> Deep supra periosteal filler in the upper nasolabial fold aims to correct the maximal maxillary facial bone loss that occurs with age. Fillers with higher HA concentration and  $G'$  are being used as a safe and effective alternative to surgical treatments by restoring facial volume and sculpting, shaping, and contouring the chin jawline and nose’s bony outline areas in particular.<sup>73</sup>

### Conclusions

The age-related changes in the different anatomical layers of the face can be treated with hyaluronic acid fillers. Understanding the aging changes in the different anatomical layers of the face gives the injector the appropriate facial rejuvenation strategies with hyaluronic acid fillers. Knowledge of the hyaluronic acid fillers’ rheological properties can help place the right filler within the correct layer to get more refined and predictable outcomes with minimal side effects.

## Abbreviations

HA, Hyaluronic Acid; SMAS, Superficial Musculoaponeurotic System; NASHA, Non-animal Stabilized Hyaluronic Acid; VYC, Vycross; GAIS, Global Aesthetic Improvement Scale; ECM, Extra Cellular Matrix; GAG, Glycosaminoglycan.

## Author Contributions

All authors contributed to data analysis, drafting or revising the article, have agreed on the journal to which the article will be submitted, gave final approval of the version to be published, and agree to be accountable for all aspects of the work. We also confirm that the people in the figures provided written informed consent for the images to be published.

## Disclosure

Dr Catherine Ellen Porter reports personal fees from Allergan Aesthetics, outside the submitted work. Dr Ligia Colucci is member of Allergan Training Faculty and a consultant for AbbVie Allergan. Dr Catherine Stone reports personal fees from Allergan, outside the submitted work. Dr Jake Sloane reports personal fees from Allergan Aesthetics, outside the submitted work. Dr Karim Sayed reports personal fees from Allergan, personal fees from Teoxane, personal fees from AbbVie, outside the submitted work. No financial disclosure with respect to this paper from all the other authors as no financial support/grant received by any of the authors for writing and publishing this review paper.

## References

- Kahn DM, Shaw RB. Overview of current thoughts on facial volume and aging. *Facial Plast Surg.* 2010;26(5):350–355. doi:10.1055/s-0030-1265024
- Kruglikov I, Trujillo O, Kristen Q, et al. The facial adipose tissue: a revision. *Facial Plast Surg.* 2016;32(6):671–682. doi:10.1055/s-0036-1596046
- Tobin DJ. Introduction to skin aging. *J Tissue Viability.* 2017;26(1):37–46. doi:10.1016/j.jtv.2016.03.002
- Krutmann J, Boulloc A, Sore G, Bernard BA, Passeron T. The skin aging exposome. *J Dermatol Sci.* 2017;85(3):152–161. doi:10.1016/j.jdermsci.2016.09.015
- Anderegg U, Simon JC, Averbeck M. More than just a filler - the role of hyaluronan for skin homeostasis. *Exp Dermatol.* 2014;23(5):295–303. doi:10.1111/exd.12370
- Tzellos TG, Klagas I, Vahtsevanos K, et al. Extrinsic ageing in the human skin is associated with alterations in the expression of hyaluronic acid and its metabolizing enzymes. *Exp Dermatol.* 2009;18(12):1028–1035. doi:10.1111/j.1600-0625.2009.00889.x
- Mellem D, Sattler M, Pagel-Wolff S, et al. Fragmentation of the mitochondrial network in skin in vivo. *PLoS One.* 2017;12:e0174469. doi:10.1371/journal.pone.0174469

- Campiche R, Jackson E, Laurent G, et al. Skin filling and firming activity of a hyaluronic acid inducing synthetic tripeptide. *Int J Pept Res Ther.* 2020;26(1):181–189. doi:10.1007/s10989-019-09827-1
- Barnes L, Kaya G, Rollason V. Topical corticosteroid-induced skin atrophy: a comprehensive review. *Drug Saf.* 2015;38(5):493–509. doi:10.1007/s40264-015-0287-7
- Langton AK, Sherratt MJ, Griffiths CEM, Watson REB. Review article: a new wrinkle on old skin: the role of elastic fibres in skin ageing. *Int J Cosmet Sci.* 2010;32(5):330–339. doi:10.1111/j.1468-2494.2010.00574.x
- Wan D, Amirlak B, Rohrich R, Davis K. The clinical importance of the fat compartments in midfacial aging. *Plast Reconstr Surg.* 2013;1(9):e92. doi:10.1097/GOX.0000000000000035
- Rohrich RJ, Pessa JE. The fat compartments of the face: anatomy and clinical implications for cosmetic surgery. *Plast Reconstr Surg.* 2007;119(7):2219–2227. doi:10.1097/01.prs.0000265403.66886.54
- Gierloff M, Stöhring C, Buder T, Gassling V, Açil Y, Wiltfang J. Aging changes of the midfacial fat compartments: a computed tomographic study. *Plast Reconstr Surg.* 2012;129(1):263–273. doi:10.1097/PRS.0b013e3182362b96
- Cotofana S, Fratila AAM, Schenck TL, Redka-Swoboda W, Zilinsky I, Pavicic T. The anatomy of the aging face: a review. *Facial Plast Surg.* 2016;32(3):253–260. doi:10.1055/s-0036-1582234
- Wan D, Amirlak B, Giessler P, et al. The differing adipocyte morphologies of deep versus superficial midfacial fat compartments: a cadaveric study. *Plast Reconstr Surg.* 2014;133(5):615–622. doi:10.1097/PRS.0000000000000100
- Coleman SR, Grover R. The Anatomy of the Aging Face: Volume Loss and Changes in 3-Dimensional Topography. *Aesthetic Surgery Journal.* 2006;26(1):S4–S9. doi:10.1016/j.asj.2005.09.012
- Surek C, Lamb J. Facial volumization: an anatomic approach. Thieme Publishers. 2017. ISBN: 9781626236943
- Pessa JE. SMAS fusion zones determine the subfacial and subcutaneous anatomy of the human face: fascial spaces, fat compartments, and models of facial aging. *Aesthetic Surg J.* 2016;36(5):515–526. doi:10.1093/asj/sjv139
- Cotofana S, Lachman N. Anatomy of the facial fat compartments and their relevance in aesthetic surgery. *JDDG.* 2019;17(4):399–413. doi:10.1111/ddg.13737
- Surek CC. Facial anatomy for filler injection: the superficial musculoaponeurotic system (SMAS) is not just for facelifting. *Clin Plast Surg.* 2019;46(4):603–612. doi:10.1016/j.cps.2019.06.007
- Ezure T, Hosoi J, Amano S, Tsuchiya T. Sagging of the cheek is related to skin elasticity, fat mass and mimetic muscle function. *Ski Res Technol.* 2009;15(3):299–305. doi:10.1111/j.1600-0846.2009.00364.x
- Tamura BM. Anatomia da face aplicada aos preenchedores e à toxina botulínica - parte I. *Surg Cosmet Dermatol.* 2010;2(3):195–204.
- Rohrich RJ, Pessa JE, Ristow B. The youthful cheek and the deep medial fat compartment. *Plast Reconstr Surg.* 2008;121(6):2107–2112. doi:10.1097/PRS.0b013e31817123c6
- Wilson AJ, Taglienti AJ, Chang CS, Low DW, Percec I. Current applications of facial volumization with fillers. *Plast Reconstr Surg.* 2016;137(5):872e–889e. doi:10.1097/PRS.0000000000002238
- Donofrio LM. Fat distribution: a morphologic study of the aging face. *Dermatologic Surg.* 2000;26(12):1107–1112. doi:10.1046/j.1524-4725.2000.00270.x
- Cotofana S, Gotkin RH, Frank K, et al. The functional anatomy of the deep facial fat compartments: a detailed imaging-based investigation. *Plast Reconstr Surg.* 2019;143(1):53–63. doi:10.1097/PRS.00000000000005080
- Paluch Ł, Pietruski P, Kwiek B, Noszczyk B, Ambroziak M. Age-related changes in elastographically determined strain of the facial fat compartments: a new frontier of research on face aging processes. *Adv Dermatol Allergol.* 2018;37:353. doi:10.5114/ada.2018.79778

28. Ilankovan V. Anatomy of ageing face. *Br J Oral Maxillofac Surg.* 2014;52(3):195–202. doi:10.1016/j.bjoms.2013.11.013
29. Farhadieh RD, Bulstrode NW, Cugno S, Wong C-H, Mendelson BC. *Aesthetic Surgery Part VIII Facial Anatomy and Ageing Chapter 65.* John Wiley & Sons; 2015.
30. Alghoul M, Codner MA. Retaining ligaments of the face: review of anatomy and clinical applications. *Aesthetic Surg J.* 2013;33(6):769–782. doi:10.1177/1090820X13495405
31. Mendelson BC. Anatomic study of the retaining ligaments of the face and applications for facial rejuvenation. *Aesthetic Plast Surg.* 2013;37(3):513–515. doi:10.1007/s00266-013-0066-8
32. Glasgold M, Glasgold R, Kontis T. Introduction to volumetric facial rejuvenation. *Facial Plast Surg.* 2015;31(1):10–14. doi:10.1055/s-0035-1544251
33. Brandt Mg, Hassa A, Roth K, Wehrli B, Moore CC. Biomechanical properties of the facial retaining ligaments. *Arch Facial Plast Surg.* 2012;14(4):289–294. doi:10.1001/archfacial.2011.1533
34. Wong C-H, Mendelson B. Newer understanding of specific anatomic targets in the aging face as applied to injectables: aging changes in the craniofacial skeleton and facial ligaments. *Plast Reconstr Surg.* 2015;136(5):44S–48S. doi:10.1097/PRS.0000000000001752.
35. Shaw RB, Katzel EB, Koltz PF, et al. Aging of the facial skeleton: aesthetic implications and rejuvenation strategies. *Plast Reconstr Surg.* 2011;127(1):374–383. doi:10.1097/PRS.0b013e3181f95b2d
36. Cotofana S, Gotkin RH, Morozov SP, et al. The relationship between bone remodeling and the clockwise rotation of the facial skeleton: a computed tomographic imaging-based evaluation. *Plast Reconstr Surg.* 2018;142(6):1447–1454. doi:10.1097/PRS.0000000000004976
37. Kim JW, Han JW, Kim YK. Difference in midface rejuvenation strategy between east asians and caucasians based on analysis of age-related changes in the orbit and midcheek using computed tomography. *Aesthetic Plast Surg.* 2019;43(6):1547–1552. doi:10.1007/s00266-019-01478-3
38. Vazirmia A, Braz A, Fabi SG. Nonsurgical jawline rejuvenation using injectable fillers. *J Cosmet Dermatol.* 2019;19(8):1–8. doi:10.1111/jocd.13277
39. Shaw RBJ, Kahn DM. Aging of the midface bony elements: a three-dimensional computed tomographic study. *Plast Reconstr Surg.* 2007;119(2):675–681. doi:10.1097/01.prs.0000246596.79795.a8.
40. Vasvani S, Kulkarni P, Rawtani D. Hyaluronic acid: a review on its biology, aspects of drug delivery, route of administrations and a special emphasis on its approved marketed products and recent clinical studies. *Int J Biol Macromol.* 2020;151:1012–1029. doi:10.1016/j.ijbiomac.2019.11.066
41. Kim JE, Sykes JM. Hyaluronic acid fillers: history and overview. *Facial Plast Surg.* 2011;27(6):523–528. doi:10.1055/s-0031-1298785
42. Kablik J, Monheit GD, Yu L, Chang G, Gershkovich J. Comparative physical properties of hyaluronic acid dermal fillers. *Dermatologic Surg.* 2009;35:302–312. doi:10.1111/j.1524-4725.2008.01046.x
43. Pierre S, Liew S, Bernardin A. Basics of dermal filler rheology. *Dermatologic Surg.* 2015;41:S120–S126. doi:10.1097/DSS.0000000000000334
44. Molliard SG, Bétemps JB, Hadjab B, Topchian D, Micheels P, Salomon D. Key rheological properties of hyaluronic acid fillers: from tissue integration to product degradation. *Plast Aesthetic Res.* 2018;5:17. doi:10.20517/2347-9264.2018.10
45. Kessler D, Dethlefsen S, Haase I, et al. Fibroblasts in mechanically stressed collagen lattices assume a “synthetic” phenotype. *J Biol Chem.* 2001;276(39):36575–36585. doi:10.1074/jbc.M101602200
46. Kerscher M, Bayrhammer J, Reuther T. Rejuvenating influence of a stabilized hyaluronic acid-based gel of nonanimal origin on facial skin aging. *Dermatologic Surg.* 2008;34(5):720–726. doi:10.1111/j.1524-4725.2008.34176.x
47. Landau M, Fagien S. Science of hyaluronic acid beyond filling: fibroblasts and their response to the extracellular matrix. *Plast Reconstr Surg.* 2015;136(5):188S–195S. doi:10.1097/PRS.0000000000001823
48. Cavallini M, Gazzola R, Metalla M, Vaienti L. The role of hyaluronidase in the treatment of complications from hyaluronic acid dermal fillers. *Aesthetic Surg J.* 2013;33(8):1167–1174. doi:10.1177/1090820X13511970
49. Niforos F, Ogilvie P, Cavallini M, et al. VYC-12 Injectable gel is safe and effective for improvement of facial skin topography: a prospective study. *Clin Cosmet Investig Dermatol.* 2019;12:791–798. doi:10.2147/CCID.S216222
50. Ogilvie P, Thulesen J, Leys C, et al. Expert consensus on injection technique and area-specific recommendations for the hyaluronic acid dermal filler VYC-12L to treat fine cutaneous lines. *Clin Cosmet Investig Dermatol.* 2020;13:267–274. doi:10.2147/CCID.S239667
51. Surek C, Lamb J. *Facial Volumisation - an Anatomic Approach.* Thieme; 2018.
52. Nakab L, Hee CK, Guetta O. Improvements in skin quality biological markers in skin explants using hyaluronic acid filler VYC-12L. *Plast Reconstr Surg.* 2020;8(3). Available from: [https://journals.lww.com/prsgo/Fulltext/2020/03000/Improvements\\_in\\_Skin\\_Quality\\_Biological\\_Markers\\_in.21.aspx](https://journals.lww.com/prsgo/Fulltext/2020/03000/Improvements_in_Skin_Quality_Biological_Markers_in.21.aspx).
53. Turlier V, Delalleau A, Casas C, et al. Association between collagen production and mechanical stretching in dermal extracellular matrix: in vivo effect of cross-linked hyaluronic acid filler. A randomised, placebo-controlled study. *J Dermatol Sci.* 2013;69(3):187–194. doi:10.1016/j.jdermsci.2012.12.006
54. Quan T, Wang F, Shao Y, et al. Enhancing structural support of the dermal microenvironment activates fibroblasts, endothelial cells, and keratinocytes in aged human skin in vivo. *J Invest Dermatol.* 2013;133(3):658–667. doi:10.1038/jid.2012.364
55. Schenck TL, Koban KC, Schlattau A, et al. The functional anatomy of the superficial fat compartments of the face: a detailed imaging study. *Plast Reconstr Surg.* 2018;141(6):1351–1359. doi:10.1097/PRS.0000000000004364
56. Suwanchinda A, Webb KL, Rudolph C, et al. The posterior temporal supraSMAS minimally invasive lifting technique using soft-tissue fillers. *J Cosmet Dermatol.* 2018;17(4):617–624. doi:10.1111/jocd.12722
57. Casabona G, Frank K, Koban KC, et al. Lifting vs volumizing—the difference in facial minimally invasive procedures when respecting the line of ligaments. *J Cosmet Dermatol.* 2019;18(5):1237–1243. doi:10.1111/jocd.13089
58. Cotofana S, Schenck TL, Trevidic P, et al. Midface. *Plast Reconstr Surg.* 2015;136(August2016):219S–234S. doi:10.1097/PRS.0000000000001837
59. Pirayesh A, Bertossi D, Heydenrych I. *Aesthetic Facial Anatomy Essentials for Injections.* CRC Press; 2020. doi:10.1201/9781315146690
60. De Maio M, DeBouille K, Braz A, Rohrich RJ. Facial assessment and injection guide for botulinum toxin and injectable hyaluronic acid fillers: focus on the midface. *Plast Reconstr Surg.* 2017;140(4):540E–550E. doi:10.1097/PRS.00000000000003716
61. de Maio M. MD Codes™: a methodological approach to facial aesthetic treatment with injectable hyaluronic acid fillers. *Aesthetic Plast Surg.* 2020;45:690–709. doi:10.1007/s00266-020-01762-7
62. Braz AV, Louvain D, Mukamal LV. Combined treatment with botulinum toxin and hyaluronic acid to correct unsightly lateral-chin depression. *An Bras Dermatol.* 2013;88(1):138–140. doi:10.1590/s0365-05962013000100024
63. Braz A, Humphrey S, Weinkle S, et al. Lower face: clinical anatomy and regional approaches with injectable fillers. *Plast Reconstr Surg.* 2015;136(5):235S–257S. doi:10.1097/PRS.0000000000001836
64. Lee W, Hwang S-G, Oh W, Kim C-Y, Lee J-L, Yang E-J. Practical guidelines for hyaluronic acid soft-tissue filler use in facial rejuvenation. *Dermatologic Surg.* 2020;46(1):41–49. doi:10.1097/DSS.0000000000001858.

65. de Maio M. Myomodulation with injectable fillers: an innovative approach to addressing facial muscle movement. *Aesthetic Plast Surg.* 2018;42(3):798–814. doi:10.1007/s00266-018-1116-z
66. Goodman GJ, Al-Niaimi F, McDonald C, Ciconte A, Porter C. Why we should be avoiding periorificial mimetic muscles when injecting tissue fillers. *J Cosmet Dermatol.* 2020;19:1846–1850. doi:10.1111/jocd.13531
67. Bertossi D, Nocini PF, Rahman E, Heydenrych I, Kapoor KM, de Maio M. Non surgical facial reshaping using MD codes. *J Cosmet Dermatol.* 2020;19:2219–2228. doi:10.1111/jocd.13596
68. Levesque AY, de la Torre JI. Midface anatomy, aging, and aesthetic analysis. *Facial Plast Surg Clin North Am.* 2015;23(2):129–136. doi:10.1016/j.fsc.2015.01.002
69. Mendelson B, Wong CH. Changes in the facial skeleton with aging: implications and clinical applications in facial rejuvenation. *Aesthetic Plast Surg.* 2012;36(4):753–760. doi:10.1007/s00266-012-9904-3
70. Ogilvie P, Sattler G, Gaymans F, et al. Safe, effective chin and jaw restoration with VYC-25L hyaluronic acid injectable gel. *Dermatologic Surg.* 2019;45(10):1294–1303. doi:10.1097/DSS.0000000000001960
71. Bae JM, Lee DW. Three-dimensional remodeling of young Asian women's faces using 20-mg/mL smooth, highly cohesive, viscous hyaluronic acid fillers: a retrospective study of 320 patients. *Dermatologic Surg.* 2013;39(9):1370–1375. doi:10.1111/dsu.12239
72. Saputra DI, Kapoor KM. Management of non-inflammatory nodule in chin after a large-volume bolus injection of hyaluronic acid filler. *Dermatol Ther.* 2020;33:e13424. doi:10.1111/dth.13424.
73. Ogilvie P, Benouaiche L, Philipp-Dormston WG, et al. VYC-25L hyaluronic acid injectable gel is safe and effective for long-term restoration and creation of volume of the lower face. *Aesthetic Surg J.* 2020;40:NP499–NP510. doi:10.1093/asj/sjaa013

## Clinical, Cosmetic and Investigational Dermatology

Dovepress

### Publish your work in this journal

Clinical, Cosmetic and Investigational Dermatology is an international, peer-reviewed, open access, online journal that focuses on the latest clinical and experimental research in all aspects of skin disease and cosmetic interventions. This journal is indexed on CAS.

The manuscript management system is completely online and includes a very quick and fair peer-review system, which is all easy to use. Visit <http://www.dovepress.com/testimonials.php> to read real quotes from published authors.

Submit your manuscript here: <https://www.dovepress.com/clinical-cosmetic-and-investigational-dermatology-journal>