

SCLERODERMA: A CASE REPORT*

Skleroderma: Bir Olgu Sunumu

Gülay ALTAN¹, Taha Emre KÖSE¹, Tamer Lütfi ERDEM², İlknur ÖZCAN¹

Received: 25/02/2014

Accepted: 15/07/2014

ABSTRACT

Scleroderma is an autoimmune connective tissue disorder which is characterized by fibrosis of visceral organs, skin and blood vessels. This condition can be localized or systemic. Its estimated prevalence is 250 cases in a million and it is more common in women than in men. Resorption of the mandibular angle and coronoid process can be observed in patients with scleroderma. Pressure of fibrous mucocutaneous tissues is thought to be the cause of the resorption. Decreased number of wrinkles due to sclerosis and distinct facial features because of the atrophy of ala nasi are among common clinical characteristics of this condition. The aim of this case report is to present a 40-year-old female patient with scleroderma who presented with signs of resorption at the angle of mandible, coronoid process, as well as widening of the periodontal space.

Keywords: Scleroderma; bone resorption; lamina dura

ÖZ

Skleroderma, derinin iç organların ve kan damarlarının fibrözleşmesi ile karakterize, genel olarak lokal ve sistemik olmak üzere ikiye ayrılan bir bağ dokusu hastalığıdır. Prevalansı bir milyonda 250 olarak tahmin edilen skleroderma, kadınlarda erkeklere oranla daha sık görülür. Alt çene angulus mandibula ve koronoid çıkıntılarda rezorpsiyonun görülebildiği sklerodermada, buna fibrozise uğrayan mukokütanöz dokuların baskısının neden olduğu düşünülmektedir. Skleroza bağlı olarak kırışıklıkların kaybolması ve burun kıkırdaklarının rezorpsiyonu nedeniyle yüz görünümünün değişmesi bu hastalığın belirgin klinik özelliklerindedir. Bu olgu bildirisinde skleroderma tanısı almış olan 40 yaşındaki kadın hastanın panoramik radyografisinde sağ angulus ve koronoid çıkıntı bölgesinde görülen rezorpsiyonlar ve periodontal membrandaki genişlemeler sunulmuştur.

Anahtar kelimeler: Skleroderma; kemik rezorpsiyonu; lamina dura

¹ Department of Oral and Maxillofacial Radiology Faculty of Dentistry Istanbul University

² Department of Oral and Maxillofacial Radiology Faculty of Dentistry Okan University

* This case report has been presented as a poster in 5th Oral Diagnosis and Maxillofacial Radiology Congress in Erzurum, Turkey, 2013.



Introduction

The word scleroderma originates from Greek words “scleros” meaning hard and “derma” which means skin (1). Scleroderma is a connective tissue disorder which is characterized by fibrosis of the skin, internal organs and blood vessels. It is categorized into two subgroups which are described as systemic and localized. Systemic sclerosis differs from localized scleroderma because it is accompanied by Raynaud’s phenomenon, acrosclerosis and internal organ involvement (2, 3, 4). Normal collagen type I and III are thought to be deposited excessively at various tissues by immunologically over-activated fibroblasts (1).

Although the etiology of scleroderma is not clear, genetic and environmental factors have been held responsible for the onset of this condition. First degree relatives of scleroderma patients have a high probability of developing the disease. Silica powder, vinyl chloride, L-tryptophan, silicone breast implants and organic solvents are among the environmental factors which were suspected to cause this condition (4). Scleroderma is mostly seen in women whose ages are between 30 and 50 and its prevalence is 250 cases in a million (2, 5)

Scleroderma causes various changes at the oral and facial tissues both clinically and radiographically. Radiographic changes in scleroderma patients are the widening of periodontal space, loss of lamina dura, and resorption of the mandibular angle (6). The first specific clinical sign of scleroderma is the swelling on the skin of hands and fingers (5). The aim of this case report is to present some clinical and radiographic characteristics of a patient diagnosed as having scleroderma.

Case report

A 40-year-old female patient was referred to Oral and Maxillofacial Radiology Department, Istanbul University Faculty of Dentistry for dental complaints. Her medical history and the documentation she presented, revealed that the patient was diagnosed with scleroderma and she had been treated in the Department of Rheumatology at Istanbul University Faculty of Medicine, for 20 years. She had goiter and gastric disease. Extra-oral examination showed that the patient was not able to open her hands because of sclerosis (Figure 1) and had a narrow nose because of atrophy of ala nasi (Figure 2).

Decreased number of wrinkles were also observed. Upper lip was insufficient to cover maxillary teeth, which is also known as “mouse-like face”. Anamnesis revealed that the patient had Raynaud phenomenon. She had used cortizone and acetylsalicylic acid for twenty years due to the vascular decomposition. Although Raynaud’s phenomenon and acrosclerosis were present in our case, there was no internal organ involvement. Patient complained about the dryness of her mouth and multiple caries lesions were observed. Trismus and increased overjet were observed in the intra-oral examination.(Figure 3). Panoramic radiography disclosed bone resorption in the right mandibular angle region of the mandible and in both ramus (Figure 4). The patient was referred to the departments for specialized dental treatment.

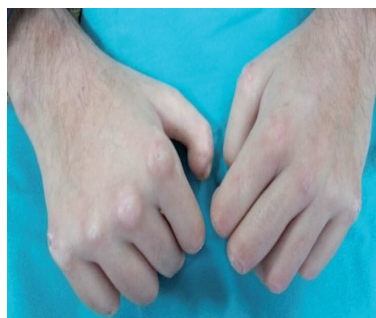

Figure 1. Patient's fingers were fixed at claw-like position.

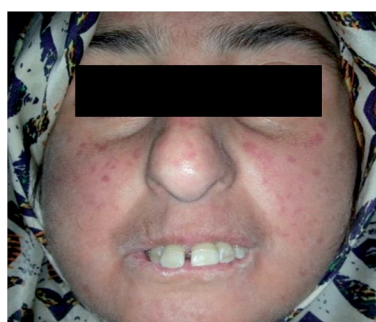

Figure 2. Facial expression and insufficient upper lip cover.

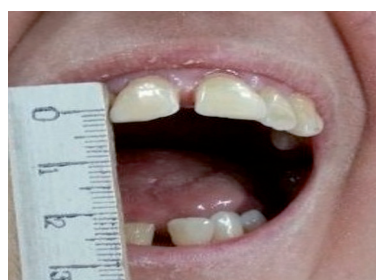

Figure 3. Patient's maximum mouth opening.

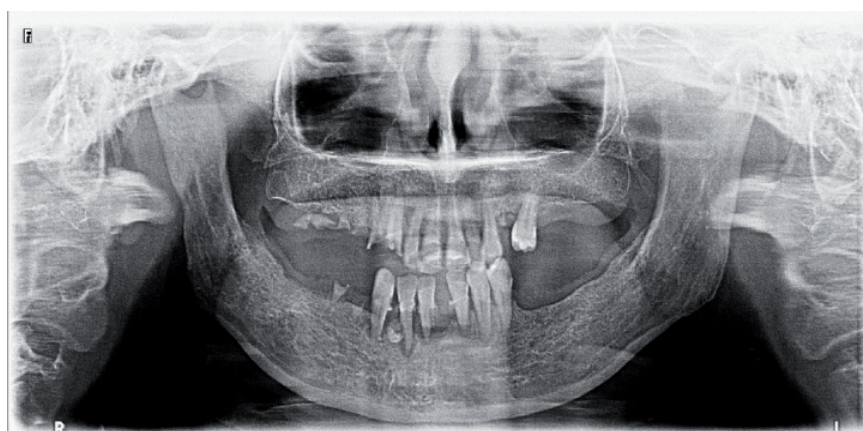


Figure 4. Panoramic radiography of the patient.

Discussion

Scleroderma is an autoimmune disease in which the antibodies target blood vessels and connective tissues (5). There is no consensus on the treatment protocol (2, 4, 5). Although being controversial, penicillamine has been used to inhibit collagen deposition. Corticosteroids have no effect on the progression of the disease (4, 7). Other treatment options are based on controlling the symptoms (7). Treatment for scleroderma is selected and organized according to the affected organs (4).

Resorption of the terminal phalanges, short and claw-like fingers because of acro-osteolysis, ulcers on finger tips are common in patients with scleroderma (7, 8). About 80% of them present with symptoms in the head and neck region (8). Dysphagia and gastroesophageal reflux are frequently reported complaints in this group of patients. Trismus, widening of the periodontal space, decrease in facial wrinkles owing to fibrosis of skin, orofacial telangiectasia, resorption of mandibular angle are some of the changes which may occur in the oral and maxillofacial region. Xerostomia and increased frequency of dental caries might be seen due to the secondary Sjögren syndrome (1, 2, 8). Rarely, mandibular resorption can lead to pathologic fractures (1). Although xerostomia is not present, high frequency of dental caries is attributed to inadequate oral hygiene by virtue of sclerosis of hands. Resorptions at the right mandibular angle, coronoid process and ramus region were present in our case and the patient's oral hygiene was poor.

Excessive collagen deposition in the cutaneous tissues around the mouth causes microstomia which prevents the patient from opening and closing the

mouth. Fibrosis of salivary glands leads to xerostomia, dysphagia, and subsequently periodontal infections (1, 5). Although microstomia and severe periodontitis were present in our case, xerostomia and dysphagia were not observed. Radiographic changes in scleroderma patients are widening of the periodontal space, loss of lamina dura, resorption of the mandibular angle, zygomatic arch, digastric region, caput mandible, and coronoid process. Blunting of mandibular angles leads to radiographic features which are described as "tail of the whale" (1). White *et al.* (6) reported widening of the periodontal space in 37% of the scleroderma patients. Wood *et al.* (9) observed mandibular resorption in 29% of the patients. Excessive deposition of collagen and oxytalan fibers and the resorption of the alveolar crest around tooth roots might cause periodontal widening (9, 10). In our patient, periodontal widening, tail of the whale appearance, and mandibular resorption were present.

Conclusion

Scleroderma is a systemic disease which causes significant radiographic and clinical changes in the oral and maxillofacial structures. Dental professionals must be aware of these changes since xerostomia and limited mouth opening are especially important for the right diagnosis and treatment. Multidisciplinary approach is of utmost importance for the scleroderma patients because of the complications of disease.

Source of funding

None declared

Conflict of interest

None declared

References

1. Albilja JB, Lam DK, Blanas N, Cloakie CM, Sándor GK. Small mouths big problems? a review of scleroderma and its oral health implications. *J Can Dent Assoc* 2007;73(9):831-836.
2. Cazal C, Sobral AP, Neves RF, Freire Filho FW, Cardoso AB, da Silveira MM. Oral complaints in progressive systemic sclerosis: two case reports. *Med Oral Patol Oral Cir Buccal* 2008;13(2):114-118.
3. de Figueiredo MA, de Figueiredo JA, Porter S. Root resorption associated with mandibular bone erosion in a patient with scleroderma. *J Endod* 2008;34(1):102-103.
4. Özgen M, Koca SS. Sklerodermanın etiyopatogenezi ve güncel tedavisi. *Fırat Üniv Sağ Bil Tıp Derg* 2010;24(1):69-76.
5. Dedic A, Pasalic A, Hodzic M, Basovic S, Avdic M, Pasic E. Scleroderma--from the aspect of dental medicine. *Med Arh* 2011;65(6):368-370.
6. White SC, Frey NW, Blaschke DD, Ross MD, Clements PJ, Furst DE, Paulus HE. Oral radiographic changes in patients with progressive systemic sclerosis (scleroderma). *J Am Dent Assoc* 1977; 94(6):1178-1182.
7. Neville BW, Damm DD, Allen CM, Bouquot DE. *Oral and maxillofacial pathology*. 3rd ed, St. Louis, Missouri: Saunders Elsevier, 2009, p.798-801.
8. Yücel ÖÖ, Ercan E. Periodontal conditions and mucogingival surgical treatment of a patient with scleroderma. *Hacettepe Diş Hekim Fak Derg* 2009;33(1):41-46.
9. Wood RE, Lee P. Analysis of the oral manifestations of systemic sclerosis (scleroderma). *Oral Surg Oral Med Oral Pathol* 1988;65(2):172-178.
10. Jung S, Minoux M, Manière MC, Martin T, Schmittbuhl M. Previously undescribed pulpal and periodontal ligament calcifications in systemic sclerosis: a case report. *Oral Surg Oral Med Oral Pathol Oral Radiol* 2013;115(4):47-51.

Corresponding Author:**Gülay ALTAN**

Department of Oral and Maxillofacial Radiology
Faculty of Dentistry Istanbul University
34093 - Capa, Istanbul, TURKEY.
Phone: 0 212 414 20 20 /30292
e-mail: gul_ay_altan@hotmail.com