

Incisionless Knee Synovectomy and Biopsy With Needle Arthroscope and Autologous Tissue Collector



Chad Lavender, M.D., Tyag Patel, M.D., Syed Adil, M.D., Baylor Blickenstaff, M.D., and Ali Oliashirazi, M.D.

Abstract: Knee arthroscopy has evolved greatly from its inception in the 20th century. Arthroscopic synovectomy is performed in the case of infection or significant synovitis. We continue to develop more minimally invasive procedures, and the NanoScope (Arthrex, Naples, FL) has provided a new generation of possibilities. The system does not require the use of a standard incision or portal, and using the GraftNet (Arthrex), we can harvest tissue with a standard shaver for further evaluation. This technique provides an option to perform a synovectomy and biopsy without the use of standard arthroscopy portals through an incisionless approach.

Synovectomy of the knee is a procedure that has multiple indications, of which the most common are septic arthritis, inflammatory arthritis, and synovial tumors. The procedure is performed through either an open or arthroscopic approach; however, in this article, we describe an incisionless method using the NanoScope (Arthrex, Naples, FL). When this is combined with the GraftNet (Arthrex), tissue from the synovium can be collected and evaluated, which can aid in the establishing the diagnosis, as well as defining treatment. Septic arthritis of the knee is a surgical emergency and is one of the more common reasons to perform a synovectomy. Once septic arthritis is diagnosed, urgent surgical debridement along with antibiotic treatment is critical. Surgical decompression reduces the intra-articular burden of bacteria and removes harmful debris released from the host inflammatory response.

Panjwani et al.¹ conducted a systematic review and meta-analysis to compare reoperation rates, length of stay, and functional outcome between arthroscopy and arthrotomy in septic native knees. They found 7 studies comprising 723 patients who underwent arthroscopic irrigation and debridement (I&D) and 366 who underwent open I&D. The relative risk of reoperation was significantly lower in the arthroscopy group, the length of stay was lower in the arthroscopy group in all included studies, and 1 study reported better functional outcomes with arthroscopy. The authors concluded that arthroscopic debridement results in a lower risk of reoperation than open arthrotomy. Furthermore, in a retrospective study of 1 institution, Johns et al.² compared open with arthroscopic I&D of native knees. They included 166 knees: 123 treated with

From Marshall University, Scott Depot, West Virginia, U.S.A.

The authors report the following potential conflicts of interest or sources of funding: C.L. receives personal fees from Arthrex, outside the submitted work. A.O. is a consultant for Zimmer Biomet and DePuy Synthes, outside the submitted work. Full ICMJE author disclosure forms are available for this article online, as [supplementary material](#).

Received February 23, 2020; accepted May 10, 2020.

Address correspondence to Chad Lavender, M.D., Marshall University, 300 Corporate Center Dr, Scott Depot, WV 25560, U.S.A. E-mail: doclav@gmail.com

© 2020 by the Arthroscopy Association of North America. Published by Elsevier. This is an open access article under the CC BY-NC-ND license (<http://creativecommons.org/licenses/by-nc-nd/4.0/>).

2212-6287/20276

<https://doi.org/10.1016/j.eats.2020.05.002>

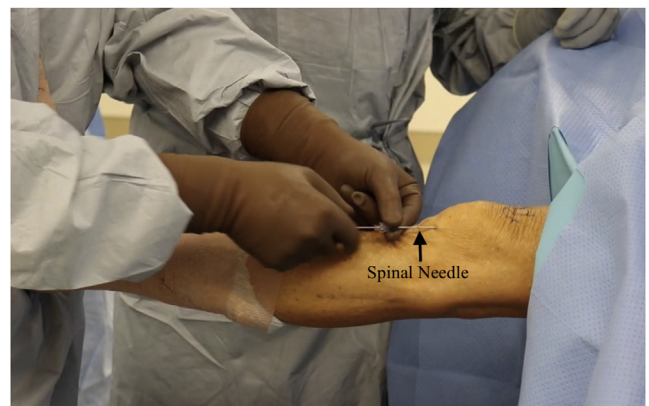

Fig 1. View of a left knee from outside the knee. The spinal needle is seen inserted into the patellofemoral joint while the knee is in full extension.

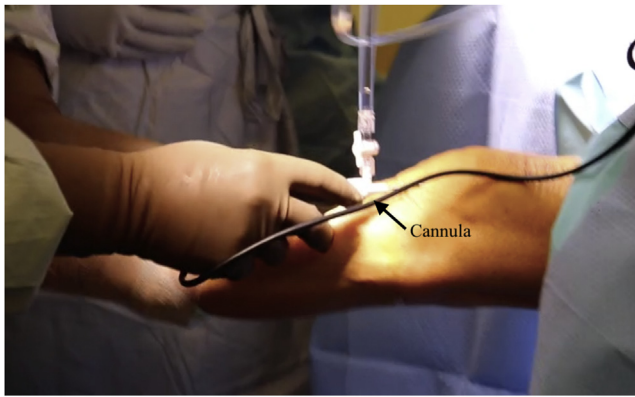


Fig 2. View of a left knee in the extended position from outside the knee. The cannula has been inserted into the knee with the NanoScope inserted.

arthroscopic I&D and 43 treated with open I&D. They found that repeated irrigation was required in 71% of knees that underwent open I&D and 50% of those that underwent arthroscopic I&D. In addition, the arthroscopic group had a lower total number of irrigation procedures and better mean postoperative range of motion ($P < .05$). Regarding pigmented villonodular synovitis, arthroscopy has also been found to have similar recurrence and complication rates to open approaches.^{3,4} This article describes an incisionless approach for synovectomy and biopsy of the knee.

Surgical Technique

Figs 1 through 8 and Video 1 show the surgical technique.

Patient Setup

The patient is placed in the supine position with the operative extremity in a leg holder and a tourniquet applied to the operative thigh. The nonoperative

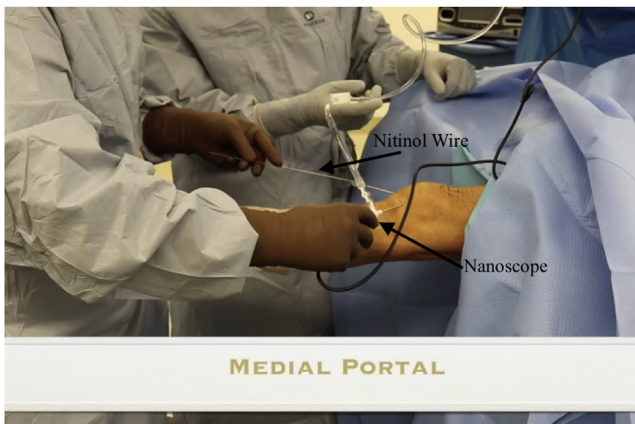


Fig 3. View of a left knee from outside the knee with the knee in full extension. The medial portal has been established with a nitinol wire inserted into a spinal needle while the NanoScope is in the anterolateral portal and the knee is in full extension.




Fig 4. View of a left knee in the extended position with the 0° NanoScope from the anterolateral portal. The shaver has been placed in the medial portal with the knee in full extension. The shaver is harvesting synovial tissue.

extremity is placed over a well-padded pillow, in slight flexion. The operative extremity is exsanguinated, and the tourniquet is inflated.

NanoScope Insertion

A spinal needle is inserted into the anterolateral joint space while the knee is in full extension. The knee may need slight flexion to allow entry into the patellofemoral joint. A nitinol wire is inserted into the needle, and the needle is removed (Fig 1). A small, 2.7-mm cannula is then inserted over the wire, and the wire is removed. Care should be taken during insertion of the 2.7-mm cannula because it can cause cartilage damage (Fig 2). Inflow is then placed onto the cannula, and the NanoScope is inserted for visualization of the joint (Video 1). A standard diagnostic arthroscopy is performed in the patellofemoral joint. The NanoScope is

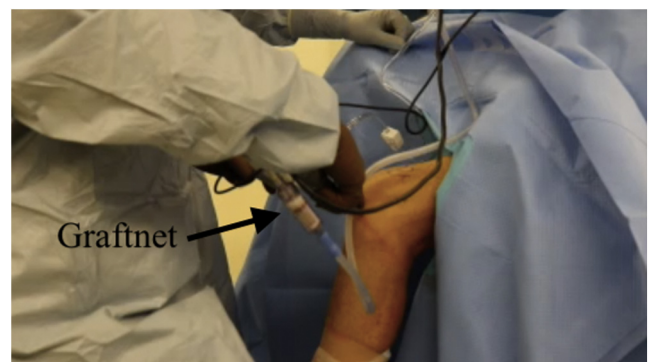


Fig 5. View of a left knee from outside the joint with the knee in 90° of flexion. The GraftNet has been attached to the shaver while the shaver is in the anterolateral portal.

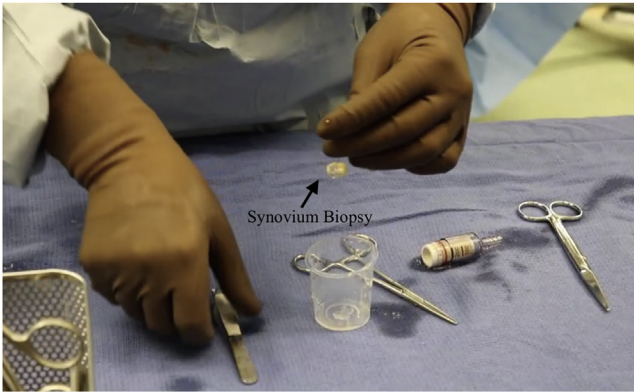

Fig 6. The synovial tissue has been removed from the GraftNet and is being placed into a sterile cup and submitted for pathologic evaluation.

then redirected into the medial joint space. Rather than gliding into the medial joint as one would with standard arthroscopy, it can be helpful to come out slightly and redirect the NanoScope into this space.

Medial Portal

An 18-gauge spinal needle is used to localize the medial portal location in an outside-in fashion. A nitinol wire is inserted into the needle, and the needle is removed (Fig 3). A small, 2.7-mm cannula is then inserted over the wire, and the wire is removed.

Synovectomy

The NanoScope is redirected into the patellofemoral joint, and a Nanoshaver (Arthrex) is used to perform the synovectomy through the medial portal. Alternatively, a 3-mm shaver can be used for a more aggressive option (Fig 4). The GraftNet is applied to the shaver to collect tissue for analysis (Figs 5 and 6). The shaver is then brought to the medial compartment to debride this compartment. The NanoScope is switched to the medial compartment, and the shaver can be brought in laterally to complete the synovectomy. Tissue obtained from

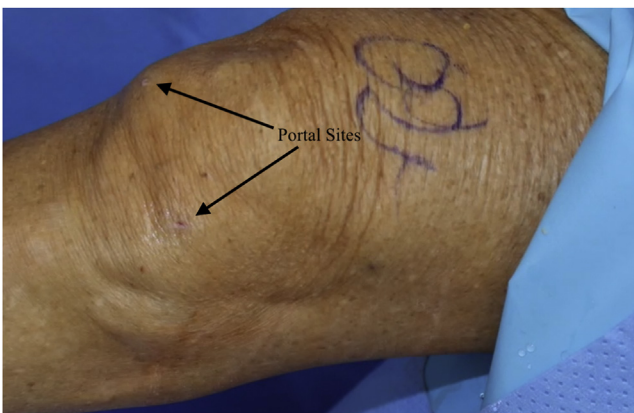


Fig 7. View of a left knee from outside the joint in full extension. The portal sites are seen on the front of the knee.

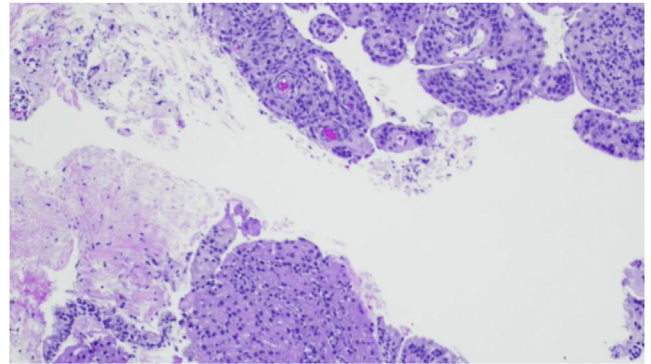


Fig 8. Final pathologic findings showing the synovium and the maintained cellular architecture after biopsy using the GraftNet. Hematoxylin and eosin stain with original magnification $\times 200$.

the GraftNet is then placed into a sterile cup and submitted for pathologic evaluation (Figs 7 and 8).

Discussion

Synovectomy can be performed through an open incision or arthroscopically, and in this article, we describe an incisionless arthroscopic technique using the NanoScope. The NanoScope needle arthroscopy system is both diagnostic and therapeutic. It allows direct visualization of intra-articular pathology, and the GraftNet allows for recovery of tissue for histologic analysis. It eliminates the need for incisions, requiring only a spinal needle to establish access to the joint.

The most common indications for synovectomy include inflammatory arthritis, synovial tumors, and septic arthritis. Traditional arthroscopy in the knee offers several advantages, including a magnified view; better access to and visibility of gutters and harder-to-reach areas; and high flow of normal saline solution in a closed cavity, allowing for dislodgement of any necrotic material or pus.⁵ There are limitations to our technique similar to those previously described for other nanoscopic techniques, which include technical difficulty using the 0° lens, difficult visualization due to flow, and the need for more precise locations of portal sites⁶ (Table 1). Pearls of this technique include redirecting the NanoScope as one changes into different compartments and using a 3-mm shaver to provide

Table 1. Advantages and Disadvantages of Nanoscopic Synovectomy

Advantages	
Decreased swelling and fluid	
Theoretical decrease in postoperative pain	
Smaller portal and incision	
Ability to obtain tissue sample with shaver	
Disadvantages	
Difficult viewing angle	
Decreased flow	

Table 2. Pearls and Pitfalls

Pearls
Redirect the NanoScope when changing compartments.
Use a 3-mm shaver if more suction is needed.
Pitfalls
Carefully place the portal sites.
Handle the instruments less aggressively than standard arthroscopy instruments.

optimal suction and debridement (Table 2). Risks of this technique include articular cartilage damage from the sharper trocar and missing joint pathology because of the decreased visualization due to flow and the size of the arthroscope.

Minimally invasive surgery results in reduced pain, swelling, and complications and a quicker recovery. We believe that the described technique should lead to improved patient results and is a great option in cases in which the diagnosis is questioned or in critically ill patients in whom an incisionless approach is favored.

References

1. Panjwani T, Wong KL, Tan SHS, Liau G, Vaidya N, Krishna L. Arthroscopic debridement has lower re-operation rates than arthrotomy in the treatment of acute septic arthritis of the knee: A meta-analysis. *J ISAKOS* 2019;4:307-312.
2. Johns BP, Loewenthal MR, Dewar DC. Open compared with arthroscopic treatment of acute septic arthritis of the native knee. *J Bone Joint Surg Am* 2017;99:499-505.
3. Rodriguez-Merchan EC. Review article: Open versus arthroscopic synovectomy for pigmented villonodular synovitis of the knee. *J Orthop Surg (Hong Kong)* 2014;22:406-408.
4. Pan X, Zhang X, Liu Z, Wen H, Mao X. Treatment for chronic synovitis of knee: Arthroscopic or open synovectomy. *Rheumatol Int* 2012;32:1733-1736.
5. Lui TH. Complete arthroscopic synovectomy in management of recalcitrant septic arthritis of the knee joint. *Arthrosc Tech* 2017;6:e467-e475.
6. Lavender C, Lycans D, Kopiec A, Sayan A. Nanoscopic single-incision anterior labrum repair. *Arthrosc Tech* 2020;9:e297-e301.