

Therapeutic benefits and side effects of Azathioprine and Aspirin in treatment of childhood primary arterial stroke

Ali A Alhaboob¹, Gamal M Hasan¹, Muhammad A Malik², Muhammad Z Rehman²

¹King Khalid University Hospital and College of Medicine, King Saud University, Riyadh, Saudi Arabia; ²The Children's Hospital and Institute of Child Health, Lahore, PAKISTAN

KEY WORDS

Primary Angiitis
Intra-cerebral Hemorrhage
Central Nervous System
Vasculitis
Children

ABSTRACT

Background: Childhood primary angiitis of central nervous system (cPACNS) is rare idiopathic vasculitis most frequently in adults. Children with this disorder can present with a range of neurological symptoms and signs including decreased consciousness, seizures, hemiparesis, cranial nerve deficits, and cognitive deficits. Delayed diagnosis and treatment may compromise the outcome. Therapeutic modalities including Anti-Platelet agents, Corticosteroids, Azathioprine, Cyclophosphamide and other Immunomodulatory agents have been used with variable success. **Purpose:** We wanted to study a cohort of children with childhood primary angiitis of Central Nervous System (cPACNS); and evaluate efficacy and safety of their management. **Methods:** Current study is an observational cohort study that included 68 patients admitted with acute ischemic strokes (AIS) within 14 days of symptoms onset at Department of Neurosciences at Children's Hospital, Lahore, Pakistan from January 2009 to December 2010 with an age ≤ 16 years. They were subjected to physical examination laboratory and neuroimaging evaluation. They received pulses of intravenous steroids and/or Immunoglobulins for 4 weeks with maintenance dose of Azathioprine and low dose Aspirin for 24 months and kept on follow for 2 years. **Results:** Sixty eight patients were included; 42 (62.76%) boys and 26 (38.23%) girls whose mean age was 8.5 ± 3.5 years. Presenting symptoms and signs included fever (20%), headache (64%), disturbed consciousness (30%), seizures 55%, hemiparesis (60%), and motor deficit (70%). Neuroimaging studies revealed ischemic strokes in 50 patients (73.5%), hemorrhagic strokes in 10 (14.7%) and ischemic-hemorrhagic lesions in 8 (11.8%). Males with, deep coma and raised intracranial pressure were poor prognostic signs. Mortality was encountered in 12 patients (17.64%) with normal outcome in 11 (16.17%), minor disabilities in 14 (20.59%), moderate disabilities in 11 (16.17%) and severe disabilities in 20 (29.41%). **Conclusions:** Characteristic features of cPACNS on presentation may predict later progression and outcome, identify high-risk patients which may guide selection of patients for immunosuppressive therapy. Further studies are required to substantiate our findings regarding immunosuppressive therapy for such patients.

Corresponding Author:

Gamal M Hasan, MD
Tel : +966 14692182/+96614692183
E-mail : gahmed@ksu.edu.sa

doi : 10.5214/ans.0972.7531.210104

Introduction

Childhood primary angiitis of the central nervous system (cPACNS) is a rare idiopathic vasculitis diagnosed most frequently in adults. Increased recognition of PACNS and advances in diagnosis of neurological disorders had led to more diagnostic approaches evident from case reports providing enriched clinical and pathological descriptions for cPACNS. cPACNS is a form of idiopathic vasculitis restricted to the brain and spinal cord with slowly progressive course.¹ The true incidence of cPACNS remains unknown. Symptoms and signs of central nervous system (CNS) vasculitis are frequently subtle, subacute and often non-specific in nature. Children with this disorder can present with a range of neurological symptoms and signs including decreased consciousness, intractable seizures, hemiparesis, cranial nerve deficits, and severe cognitive deficits.² Delayed diagnosis and treatment may compromise the survival and/or outcome. No consistent laboratory investigations diagnostic and neuroimaging studies are therefore necessary for diagnosis. Hence identification and early diagnosis of children with such disorder is crucial because with standardized treatment good neurological outcome is a realistic goal.³ Therapeutic modalities including anti-platelet agents, corticosteroids, azathioprine, cyclophosphamide and other immunomodulatory agents have been used with variable success. Moreover, early immunosuppressive therapy might improve the prognosis.^{4,5}

This study aims to describe the clinical manifestations for a cohort of children presented with cPACNS, report the efficacy and

safety of local treatment protocol and to describe neurological outcomes at hospital discharge and during their follow up.

Methods

This study is a retrospective analysis of prospectively enrolled cohort of children with cPACNS presented to Department of Neuroscience, Children's Hospital, Lahore, Pakistan over a period of 2 years (January 2009 - December 2010). Inclusion criteria were: newly acquired neurological deficit plus angiographic and/or Magnetic Resonance Angiography (MRA) features consistent with CNS vasculitis with absence of other disease conditions that might cause these findings¹⁻⁶ age ≤ 16 years and presentation within 14 days of symptoms onset. A total of 94 patients presented with acute neurological manifestations (sudden loss of consciousness, seizures, acute hemiparesis and speech disturbances) with infarction or hemorrhage on brain neuroimaging studies. They were subjected to thorough history taking, complete clinical examination and neuroimaging studies. Arteriopathies causing stroke were categorized as: non-progressive (non-obliterative) or progressive (obliterative): based on findings of conventional angiography (CA) and/or MRA. Ischemic strokes were treated according to local treatment protocols approved by Pediatric Neurology Consensus at our hospital (Table 1). Strokes were classified based on neuroimaging findings: as ischemic, ischaemic-haemorrhagic or hemorrhagic-infarcts. Short term outcome was measured in terms of mortality and clinical status at hospital discharge determined by presence of neurological motor deficit, visual and/or speech difficulties.

Table 1: Treatment protocol for childhood Arterial Ischemic Strokes at the Children's Hospital Lahore-Pakistan

<p>I- Induction therapy: 5–10 days:</p> <ul style="list-style-type: none"> ➤ Methyl prednisone: 25 mg/kg intravenous over 4 hours daily for three days and/or intravenous immunoglobulin 400 mg/kg/day over 6 hours for five days. ➤ Oral prednisone: 2 mg/kg daily (maximum 60 mg daily) for 30 days, to be tapered over 30 days. ➤ Supplementary calcium and vitamin D is provided during prednisone treatment. ➤ Heparin (for ischemic strokes, infarction size $\leq 50\%$ of cerebral hemisphere size); loading dose 75 units/Kg intravenously followed by 20 units/Kg/hour for children over one year of age (or 28 units/Kg/hour for children below one year of age) for 3–5 days followed by oral anticoagulants for 30 days. ➤ Anticonvulsants and antipsychotics as needed. ➤ Antibiotics, antiviral and antacids along with other supportive care as needed. ➤ Management of raised intracranial pressure as needed <p>II-Maintenance therapy: 24 months:</p> <ul style="list-style-type: none"> ➤ Aspirin 3 mg/kg daily for all ischemic strokes ➤ Aspirin 3 mg/kg and Azathioprine 1 mg/kg daily for progressive arteriopathies. ➤ Anticonvulsants, antipsychotics, nutrients and other supportive care as needed.
--

Follow up of patients after hospital discharge was maintained for 2 years. Ethical approval for study was obtained.

Statistical analysis

Data was recorded and statistically analyzed using the Statistical Package for the Social Sciences (SPSS) version 12.0 (Chicago, IL). Frequencies were calculated for qualitative while mean \pm SD and median were calculated for quantitative data.

Results

Ninety four patients with clinical diagnosis of childhood Arterial Ischemic Stroke (cAIS) were identified from the total admissions to Department of Neuroscience at Lahore Children's Hospital, Pakistan. Sixty eight (72.3%) met inclusion criteria and diagnosed as cPACNS while 26 (27.7%) had strokes secondary to conditions other than primary pathology of cerebral arteries. These patients were 42 boys (61.76%) and 26 girls (38.23%), their mean age was 8.5 ± 3.5 years (Median age 7.4 years, range 1.5–16 years). Forty two patient (61.76%) were < 5 years and 26 (38.23%) > 5 years old. Median time between onset of symptoms and/or signs and diagnosis was 12 days (Range 1–18 day). Headache was found in 64% of patients; hemiplegia in 60%; seizure in 55% (focal 30%, generalized 25%) and decreased level of consciousness in 30% (**Figure 1**). Based on findings of CA and/or MRA 51 patients (75%) had non-progressive and 17 (25%) had progressive arteriopathies. Fifty patient (73.54%) had ischemic strokes and 10 (14.70%) had hemorrhagic strokes while 8 (11.76%) had ischemic-hemorrhagic lesions (**Figure 2**). Out of the recruited patients, 56 patients completed induction and carried on maintenance therapy as per the approved management protocol (**Table 1**); 41 (73.21%) of them with Aspirin alone and 15 (26.79%) with combined Aspirin and Azathioprine. Mortality encountered in 12 patient (17.64%), 11 were normal (16.17%), 14 (20.59%) had minor disabilities, another 11 (16.17%) had moderate disabilities and 20 (29.41%) had severe disabilities. Mortalities included 7 males and 5 females, their neuroimaging studies showed 5 with hemorrhagic stroke, 5 with hemorrhagic infarct stroke and 2 with ischemic stroke with progressive arteriopathy. Eight of them had severe bilateral involvement of major cerebral arteries and/or massive parenchymal bleeding. No statistically significant differences were found for age, localization of Acute Ischemic Stroke (AIS) and occurrence of seizures in

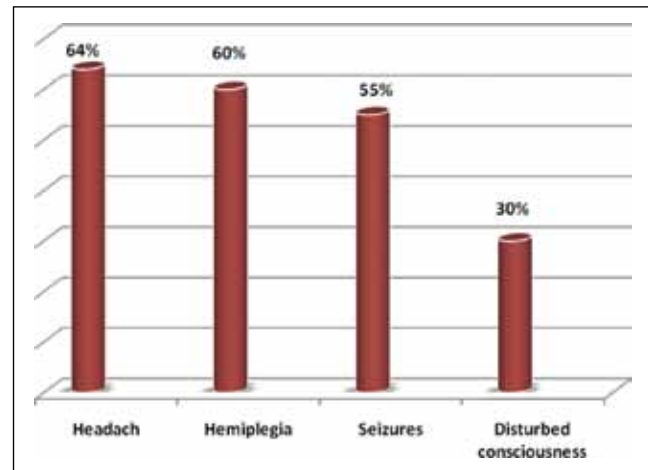


Fig. 1: Common symptoms and signs in studied patients.

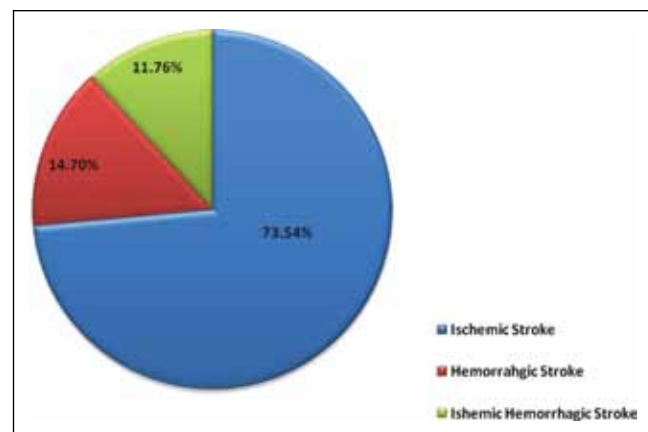


Fig. 2: Stroke variants in studied patients.

relation to morbidity and mortality. No secondary hemorrhages were observed among all the ischemic-infarcts patients who were treated initially with intravenous heparin and continued with oral anticoagulants.

Discussion

Childhood primary angiitis of the central nervous system (cPACNS) is a reversible cause of severe neurological impairment, intractable seizures and cognitive decline. Once clinically suspected, angiography and/or MRA are key imaging modalities.⁷ Epidemiological studies have revealed an annual incidence of 2.5–2.7 pediatric strokes per 100,000 children. This figure comprises of ischemic and hemorrhagic events, and excludes strokes from trauma or birth-related complications.¹ Our study is consistent with retrospective review for cPACNS⁸ but this retrospective review was limited to one Pediatric Neurology Department in Punjab and the frequency of stroke cannot be extrapolated to the whole population. Other studies, based on hospital discharge databases, have found higher incidence.⁹ Similarly, high incidence was reported from two Saudi hospitals based on admission data and it seems that high incidence in these hospitals was attributed to Tertiary Care Centers providing services to several regions of the country.¹⁰ In our study, median age at initial presentation was 8.5 years which consistent with Soman et al. who documented median age of 8.8 years in their study¹¹ while De Veber et al. (1998) and Barnes et al. (2004) reported younger median age for Pediatric strokes.^{12,13} Our finding for male dominance (62.5%) in studied patients with pediatric ischemic strokes comes in agreement with other studies.^{11,12} The exact explanation for the apparent male predominance in our study and other studies is still unknown. However, an Indian study documented equal sex incidence among children with AIS.¹² Febrile illness was preceding presentation to our hospital in 30% of our studied patients and after admission to our hospital in 20% of them that may be attributed to the high prevalence of infections in our society. Comparable findings were reported by Najaraja et al. (1994) who suggested that viral infections could be a triggering factor for a vascular lesion resulting in thrombosis and leading to vascular occlusion.¹⁴ Headache was one of the presenting symptoms in 64% of our patients which is in agreement with Braun et al.¹⁵ The disturbed consciousness in 26.5% of our patients at the time of hospital admission is in agreement with Adam et al. (2004).¹⁶ Comparable reports for presence of seizures in such patients were found in our patients (55%) and other studies.^{7,9,14,17,18} The reported preceding history is suggestive of Transient Ischemic Attacks (TIAs) in 20.6% of our studied patients comes in accordance with Lantheir et al. (2000).¹⁹ In our study neuroimaging studies of the brain showed abnormal findings in 100% of patients and classification of stroke type was found to be; ischemic infarcts in 73.54% of patients; hemorrhagic strokes in 14.70% and hemorrhage-ischemic infarcts in 11.76%. These findings are comparable to Makhija et al. who reported ischemic infarction in 91% of their studied Pediatric patients with strokes.²⁰ Current treatment strategies for Pediatric AIS are mainly anticoagulation and despite the differences in pathophysiology and outcomes from adult AIS, therapeutic management remains similar because of the paucity of evidence from devoted Pediatric observational studies and clinical trials.²¹ In the current study, patients who had hemorrhagic strokes, hemorrhagic-infarct lesions and increased intracranial pressure were treated conservatively and only 4 patients required craniotomy to remove large blood clots in order to lower the intracranial hypertension. On the other hand, 80% of patients with infarct strokes received intravenous Heparin and later on switched to oral Anticoagulants. The remaining 20% of this group had very large infarcts (greater than 50% of

single hemisphere) or they presented late and they were carried on Aspirin. Upon hospital discharge, patients with infarct strokes were kept on Aspirin, 3 mg once daily, and those with progressive arteriopathy were carried on Azathioprine 1mg/kg/day to be commenced on 30th day in addition to aspirin and both drugs were recommended for 2 years with follow up. There is good evidence for the efficacy and tolerability of immunomodulatory therapies in immune mediated neurological disorders such as Guillian Barre Syndrome (GBS), myasthenia gravis, and acute central nervous system demyelination. Despite the data for immunomodulatory therapies, it is limited in cPACNS; Azathioprine has been used successfully in a few case reports of cPACNS.²² Our patients were carried on the local treatment protocol (Table 1) and monitored for 2 years. No side effects were reported, no secondary hemorrhage due to Heparin infusion or oral anticoagulants were observed. Moreover no significant side effects for Azathioprine were reported. These observations are in agreement in with Barnes et al. who didn't report any side effects in their study for 26 patients treated with anticoagulants for similar conditions.¹³ The present study demonstrated an estimated disease related mortality of 17.64% while Barnes et al. reported mortality of 8.4% in such patients with almost 78% of survivors having significant neurological deficits.¹³ The current study had revealed that 80% of survivors had neurological deficit at the time of hospital discharge; hemiparesis (55.5%) followed by seizures, visual disturbances, speech difficulties and swallowing difficulties. These findings are in agreement with Barnes et al. who has reported incidence of hemiplegia/hemiparesis in 42% of their studied patients, developmental delay in 20%, ataxia in 15.9% and seizures in 7%.¹³ Similar outcome was also reported by Cnossen et al. who found severe neurological impairments in 54% of their studied children after a period of 12 months from hospital discharge.²¹ Moreover, other studies have reported that long-term neurologic deficits can occur in 50% to 85% of infants and children after arterial ischemic stroke.^{8–12,19} It was also found that infarcts in both hemispheres have been associated with poor outcome, while hemorrhagic infarction, number of infarcts, and size of the artery involved were not predictive factors.²³ It has been postulated that; seizures at stroke onset, altered mental status and complete middle cerebral artery cortical strokes are negative prognostic factors.¹⁹

We believe that in our study the large number of randomly selected consecutive patients is important because in comparison to individual cases or smaller previous case series, our cohort is likely to provide a wider spectrum of clinical findings relevant to advancement of knowledge in the field. Moreover, our study defined progressive and non-progressive forms of cPACNS. Despite the ability to implement appropriate therapy for such patients, it remains high risk for mortality and morbidity that might reflect the need for early diagnosis and initiation of therapy to improve outcome.

Conclusion

Findings from this study highlight the significant mortality and morbidity of childhood strokes and the impact of early diagnosis and treatment in improving the outcome in such patients. Availability of 24-hour neuroimaging facilities, dedicated acute stroke units for managing childhood stroke are of utmost importance. The use of immunosuppressive therapy in addition to anticoagulants might improve the neurological outcome in children with medium/large vessel childhood primary angiitis

of the CNS. Lastly further studies are required to substantiate our findings.

This article complies with International Committee of Medical Journal Editor's uniform requirements for manuscript.

Competing interests: None, Source of funding: None

Received Date : 8 October 2013; Revised Date : 15 November 2013;

Accepted Date : 3 February 2014

References

- Lie JT. Primary (granulomatous) angiitis of the central nervous system: a clinicopathological analysis of 15 new cases and a review of the literature. *Hum Pathol* 1992; 23(2): 164–71.
- Benseler SM, Silverman E, Aviv RI, et al. Primary central nervous system vasculitis in children. *Arthritis Rheum* 2006; 54(4): 1291–97.
- Bensiler S and Schneider R. Central nervous system vasculitis in children. *Curr Opin Rheumatol* 2003; 16(1): 43–50.
- Hajj Ali RA. Primary angiitis of the central nervous system; differential diagnosis and treatment. *Clinical Rheumatology* 2010; 24(3): 413–26.
- Hutchinson C, Elbers J, Halliday W, et al. Treatment of small vessel primary CNS vasculitis in children: an open-label cohort study. *Lancet Neurol*. 2010; 9(11): 1078.
- Calabrese LH, Furlan AJ, Gragg LA, et al. Primary angiitis of the central nervous system: diagnostic criteria and clinical approach. *Cleve Clin J Med*. 1992; 59(3): 293–306.
- Despina E, Tim C, Dawn S, et al. Investigation of childhood central nervous system vasculitis: magnetic resonance angiography versus catheter cerebral angiography. *Developmental Medicine and Child Neurology*. 2010; 52(9): 863–67.
- Chung B and Wong V. Pediatric stroke among Hong Kong Chinese subjects. *Pediatrics*. 2004; 114(2): 206–12.
- Salih MA, Abdel-Gader AG, Al-Jarallah AA, et al. Stroke in Saudi children: Epidemiology, clinical features and risk factors. *Saudi Med J*. 2006; 27 Suppl 1: S12–20.
- Strater R, Becker S, von Eckardstein A, et al. Prospective assessment of risk factors for recurrent stroke during childhood - a 5-year follow-up study. *Lancet* 2002; 360: 1540–45
- Soman T, Rafay F.M, Hune S, et al. The Risks and Safety of Clopidogrel in Pediatric Arterial Ischemic Stroke. *Stroke*. 2006; 37: 1120–22.
- deVeber G, Monagle P, Chan A, et al. Prothrombotic disorders in infants and children with cerebral thromboembolism. *Arch Neurol*. 1998; 55(12): 1539–43.
- Barnes C, Newall F, Furmedge J, et al. Arterial ischemic stroke in children. *J Paediatr Child Health*. 2004; 40: 384–87.
- Nagaraja D, Verma A, Taly AB, et al. Cerebrovascular disease in children. *Acta Neurol Scand*. 1994; 90(4): 251–55.
- Braun KP, Rafay MF, Uiterwaal CS, et al. Mode of onset predicts etiological diagnosis of arterial ischemic stroke in children. *Stroke* 2007; 38: 298–302.
- Robert JA, Donald JB, Suzanne G, et al. Stroke and conversion to high risk in children screened with transcranial Doppler ultrasound. The STOP study. 2004; 103: 3689–94.
- Siddiqui TS, Rehman A, Ahmed B. Etiology of strokes and hemiplegia in children presenting at Ayub Teaching Hospital, Abbottabad. *J Ayub Med Coll Abbottabad*. 2006; 18(2): 60–63.
- Shi KL, Wang JJ, Li JW, et al. Arterial ischemic stroke: experience in Chinese children. *Pediatr Neurol*. 2008; 38: 186–90.
- Lanthier S, Carmant L, David M et al. Stroke in children: The coexistence of multiple risk factors predicts poor outcome. *Neurology*. 2000; 54: 371–78.
- Makihija S, Aneja S, Tripathi RP, et al. Etiological Profile of Stroke and its relation with pro-thrombotic states. *Indian J Paediatr* 2008; 75(6): 579–84.
- Cnossen MH, Aarsen FK, Akker SLj, et al. Pediatric arterial ischemic stroke: functional outcome and risk factors. *Dev Med Child Neurol* 2010; 52: 394–399.
- Logan M. McD, Jeremy DF, Dennis NB, et al. Immunomodulatory Therapies in Neurologic Critical Care. *Neurocrit Care* 2010; 12(1): 132–43.
- Graeme JH. Secondary prevention of recurrent stroke. *Stroke*; 2005; (36): 218–21.