

# Efficacy of orthobiologic adjuvants to core decompression for hip preservation in avascular necrosis hip

Prasoon Kumar <sup>1</sup>, Vijay D. Shetty<sup>2</sup> and Mandeep Singh Dhillon<sup>1</sup>

<sup>1</sup>Department of Orthopaedics, PGIMER, Chandigarh 160012, India and

<sup>2</sup>Hiranandani Hospital, Mumbai, India.

\*Correspondence to: P. Kumar, Dr LH Hiranandani Hospital, Mumbai- 400076, Maharashtra, India. E-mail: drprasoonksingh@gmail.com

Submitted 14 June 2020; Revised 17 August 2020

## ABSTRACT

Head preserving modalities in avascular necrosis (AVN) hip are variably effective in early stages, and further options that could prevent head distortion and osteoarthritis are needed. Core decompression (CD) is the most commonly used surgery in the early stages of osteonecrosis with variable rates of success. The present review aimed to determine the effectiveness of bone marrow aspirate concentrate (BMAC), platelet-rich plasma (PRP), bone morphogenetic proteins (BMP) or their combination with CD in early stages of AVN hip, prior to collapse of femoral head. Additionally, any newer unexplored modalities were also searched for and ascertained. PubMed and SCOPUS databases were searched for relevant articles in English language describing CD with aforementioned orthobiologics. We analysed a total of 20 studies published between 2011 and 2020. There were 6 retrospective and 14 prospective studies. PRP showed improved survival and functional outcomes; however, with only three studies, there is inconclusive evidence for its routine utilization. BMAC enhances the efficacy of CD which can further be increased by culture and expansion of cells or combining it with PRP to stimulate growth. In conclusion, CD with BMAC works more efficiently than CD alone prior to collapse of femoral head in AVN. However, PRP needs more evidence for extensive application. Addition of PRP to BMAC or culturing the latter could further enhance the potency of CD + BMAC combination. Very limited data is available for the efficacy of BMP-7 and the role of intraosseous bisphosphonates should be evaluated for a cheaper and potential alternative.

## BACKGROUND

Avascular necrosis (AVN) of the femoral head is a common and progressive intra-osseous pathology that leads to functional limitation as the disease progresses, leading to head distortion and terminal arthritic changes [1]. Radiologically, there is structural damage to the subchondral trabeculae, leading to the loss of support for the articular surface of the femoral head; it further leads to collapse of the subchondral bone and head deformation [2–5]. Therefore, to conserve a femoral head affected by AVN, the therapeutic modalities ought to be used in early stages for favourable outcomes. Once the articular cartilage devoid of nutrition collapses, it becomes increasingly challenging to salvage that particular femoral head and

ultimately bony destruction occurs, which affects the hip biomechanics due to shortening of the abductor lever arm; articular changes ultimately creep in, requiring arthroplasty or arthrodesis.

It is increasingly understood from studies in the past decade and a half, that the aetiological causes of non-traumatic AVN hip- steroids, alcohol, coagulopathies etc., result in a reduction of mesenchymal stem cells (MSCs) in the bone marrow while enhancing the number of adipose cells and apoptotic cells [6–8]. This results in a mismatch between bone production and osteolysis with the latter occurring at a relatively faster rate, leading to the death of the bony trabeculae supporting the articular cartilage. Alternatively, intravascular coagulopathy or extravascular compression

due to the increased intraosseous pressure, caused by enhancement in adipose tissue, could lead to decreased blood supply to the bony trabeculae, causing osseous necrosis. This, in turn, leads to diminished subchondral support for the articular cartilage, initiating the cascade of subchondral collapse, femoral head distortion, altered hip biomechanics and osteoarthritis.

Various early therapeutic modalities have been described and modified to enhance survival of the native femoral head and avoid arthroplasty as long as possible. Core decompression (CD) was devised to release the intraosseous pressure and increase the blood flow to the femoral head, so as to prevent progression or reverse the pathology of AVN. It has had promising results in very early stages of AVN, wherein cores of subchondral dead bone are removed by drilling, facilitating blood vessel in-growth and restoration of vascularity. CD alone in FICAT Stage 1 has shown promising results with reversal rates of up to 97% to the normal anatomy of the hip, but as the volume of affected femoral head increases, the success of the same procedure in subsequent stages decreases; in FICAT Stage 2 it goes down to 77% [9–11]. Therefore, lies the need of adjuvants to increase its efficacy in the stages 2 and beyond.

Transtrochanteric rotational or varus/valgus osteotomies move the diseased portion of the head away from the weight-bearing area, so that the uninvolved portion in the early part of the disease process takes its position; they have been previously described to conserve the affected head [12, 13]. These surgeries have shown variable results and their application has somewhat declined in the current times [13].

The addition of fibula and vascularized grafts to CD have shown promising results but are challenging surgeries to perform and have donor site co-morbidities. On the other hand, newer orthobiologics have been increasingly tested in the past decade; bone marrow aspirate concentrate (BMAC), platelet-rich plasma (PRP) and bone morphogenetic protein-7 (BMP-7) have been supplemented with CD to increase the success rates in early AVN [14–17]. A few studies have even assessed these in post-femoral head collapse and distortion stages [18, 19].

The present systematic review was conceptualized to assess the efficacy of the present-day orthobiologic adjuvants to CD for hip preservation in early AVN hips, which have not progressed to head distortion and collapse (up to crescent sign and <50% involvement of the head) and to explore the literature for any newer therapies which would increase the chances of their

survival in the present millennium. We also evaluated any other methods of administration of these adjuvants to optimize the results.

## METHODOLOGY

### Study design

A systematic review of the literature was performed through specified search engines of PubMed and Scopus according to the PRISMA guidelines [20].

### Search methodology

The first search was conducted on the PubMed and SCOPUS databases on 25 April 2020 using specific keywords (Table 1) and relevant articles published in the last 10 years (2011–20) were searched. A total number of 569 results were obtained. A secondary search was done from the reference sections of identified publications for more articles.

### Inclusion and exclusion criteria

Articles on surgical interventions for conserving femoral head affected by AVN were included. The focus was primarily on CD and adjuvants used along with it to enhance survival rates of the femoral heads in pre-femoral head collapse stages of AVN. Studies describing the usage of orthobiologics such as PRP and BMAC were accurately identified and included. Studies that included advanced post-femoral head collapse stages of AVN associated with gross head distortion and arthritic changes were excluded. Cadaveric studies, animal/biomechanical studies, conference abstracts, case reports and any studies published before 2011 were excluded. We also excluded articles in languages other than English.

### Data collection and analysis

The study results were assessed for inclusion independently by two authors (P.K. and M.S.D.). Discrepancies in assessments were resolved by discussions. The data extracted were charted on a pre-specified table, which included names of the authors, year of publishing, relevant demographic parameters, type of studies and outcome measures of interest including functional outcomes, pain relief and hip survival rates/conversion to hip arthroplasties.

For risk of bias, The Cochrane Collaboration's risk of bias tool was used to assess randomized trials, whereas the MINORS tool was used to evaluate non-randomized studies.

**Table I. Search strategy used for systematic review in PubMed and Scopus**

Database	Search No.	Period—2011 to 25 April 2020 with keywords	Results
PubMed	1	('femur head necrosis' [MeSH Terms] OR ('femur' [All Fields] AND 'head' [All Fields] AND 'necrosis' [All Fields]) OR 'femur head necrosis' [All Fields] OR ('avascular' [All Fields] AND 'necrosis' [All Fields] AND 'femoral' [All Fields] AND 'head' [All Fields]) OR 'avascular necrosis femoral head' [All Fields] AND ('platelet-rich plasma' [MeSH Terms] OR ('platelet-rich' [All Fields] AND 'plasma' [All Fields]) OR 'platelet-rich plasma' [All Fields] OR ('platelet' [All Fields] AND 'rich' [All Fields] AND 'plasma' [All Fields]) OR 'platelet rich plasma' [All Fields])	20
	2	('femur head necrosis' [MeSH Terms] OR ('femur' [All Fields] AND 'head' [All Fields] AND 'necrosis' [All Fields]) OR 'femur head necrosis' [All Fields] OR ('avascular' [All Fields] AND 'necrosis' [All Fields] AND 'femoral' [All Fields] AND 'head' [All Fields]) OR 'avascular necrosis femoral head' [All Fields] AND ('stem cells' [MeSH Terms] OR ('stem' [All Fields] AND 'cells' [All Fields]) OR 'stem cells' [All Fields])	228
	3	('femur head necrosis' [MeSH Terms] OR ('femur' [All Fields] AND 'head' [All Fields] AND 'necrosis' [All Fields]) OR 'femur head necrosis' [All Fields] OR ('avascular' [All Fields] AND 'necrosis' [All Fields] AND 'femoral' [All Fields] AND 'head' [All Fields]) OR 'avascular necrosis femoral head' [All Fields] AND ('bone marrow' [MeSH Terms] OR ('bone' [All Fields] AND 'marrow' [All Fields]) OR 'bone marrow' [All Fields]) AND aspirate [All Fields])	20
	4	('femur head necrosis' [MeSH Terms] OR ('femur' [All Fields] AND 'head' [All Fields] AND 'necrosis' [All Fields]) OR 'femur head necrosis' [All Fields] OR ('avascular' [All Fields] AND 'necrosis' [All Fields] AND 'femoral' [All Fields] AND 'head' [All Fields]) OR 'avascular necrosis femoral head' [All Fields] AND core [All Fields] AND ('decompression' [MeSH Terms] OR 'decompression' [All Fields]) AND ('stem cells' [MeSH Terms] OR ('stem' [All Fields] AND 'cells' [All Fields]) OR 'stem cells' [All Fields])	66
Scopus	1	TITLE-ABS-KEY (avascular AND necrosis AND femoral AND head AND platelet-rich AND plasma)	12
	2	TITLE-ABS-KEY (avascular AND necrosis AND femoral AND head AND stem AND cells)	157
	3	TITLE-ABS-KEY (avascular AND necrosis AND femoral AND head AND core AND decompression AND stem AND cells)	50
	4	TITLE-ABS-KEY (avascular AND necrosis AND femoral AND head AND bone AND marrow AND aspirate)	16
Total			<b>569</b>

## RESULTS

### Search and screening results

Using our specified keywords, the total number of hits in both the databases was 569, out of which 288 studies were identified after excluding duplications, for

further evaluation. After screening of titles and abstracts, 46 studies were zeroed upon, and full texts were read. Finally, 20 studies (all published between 2011 and 2020) were identified for inclusion in the review [21–40] (Fig. 1).

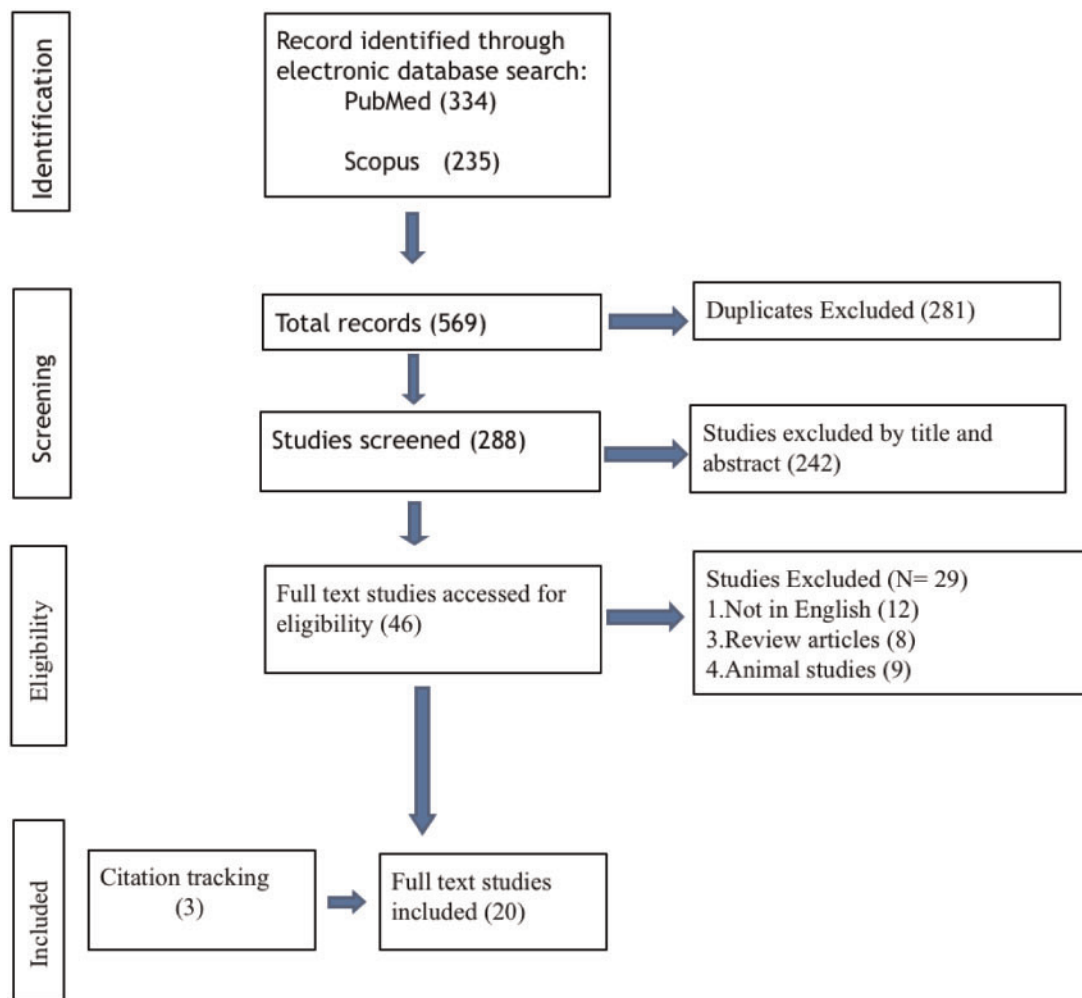


Fig. 1. PRISMA flow chart depicting the selection of articles.

#### Characteristics of studies

A total of 20 studies were included in this review and tabulated [21–40]. Of these, 14 were prospective [33, 39, 21, 22, 23, 24, 27, 28, 29, 30, 31, 35, 36, 37] and 6 were retrospective [25, 26, 32, 34, 38, 40]. Three studies detailed the usage of PRP with CD, among which 1 was a randomized trial [21]. Fourteen studies evaluated the efficacy of BMAC as an adjuvant to CD [24–37], and one study assessed the usage of recombinant BMP-7 [40]. The remaining 2two studies evaluated the results of using both BMAC and PRP with CD [38, 39].

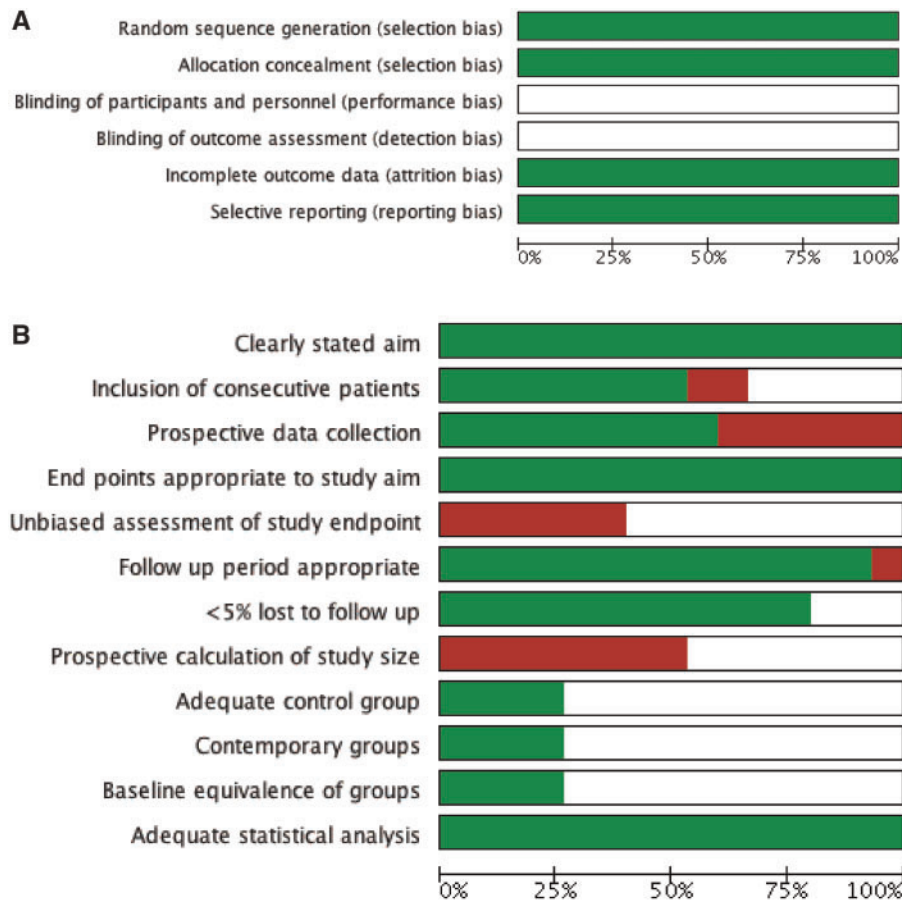
A total of 665 patients with 846 hips affected by AVN, were treated in the included studies, out of this 295 patients were males and 195 were females (60.2% males). Three studies did not mention the division of patients based on gender ( $n = 93$  patients) [23, 31, 38], while three other studies gave the divisions based on the number of hips operated ( $m = 78$ ;  $F = 26$ ) [28, 29, 33]. Overall, there

was a prominent degree of male preponderance in the included studies.

The lowest number of patients in individual studies was 4 [23], while the highest number was 100 [37]. The average age of the included patients was 37.2 years which showcases the prevalence of early AVN in the younger population and the need of interventions to delay progression and arthroplasties. Two studies did not mention the mean age of the included patients [23, 28]. The mean follow-up period in the studies ranged from 9 months to as long as 6 years.

#### Risk of bias

Risk of bias of the included studies was low overall. It was calculated by two authors independently reading each article in terms of randomization, blinding methods and outcome reporting etc., and then RevMan 5.4 software was used to generate the risk of bias (Figs 2 and 3).



**Fig. 2.** Graphs showing the risk of bias in the included studies. (A) Randomized studies; (B) non-randomized studies (green: low risk; white: unclear risk; Red: high risk).

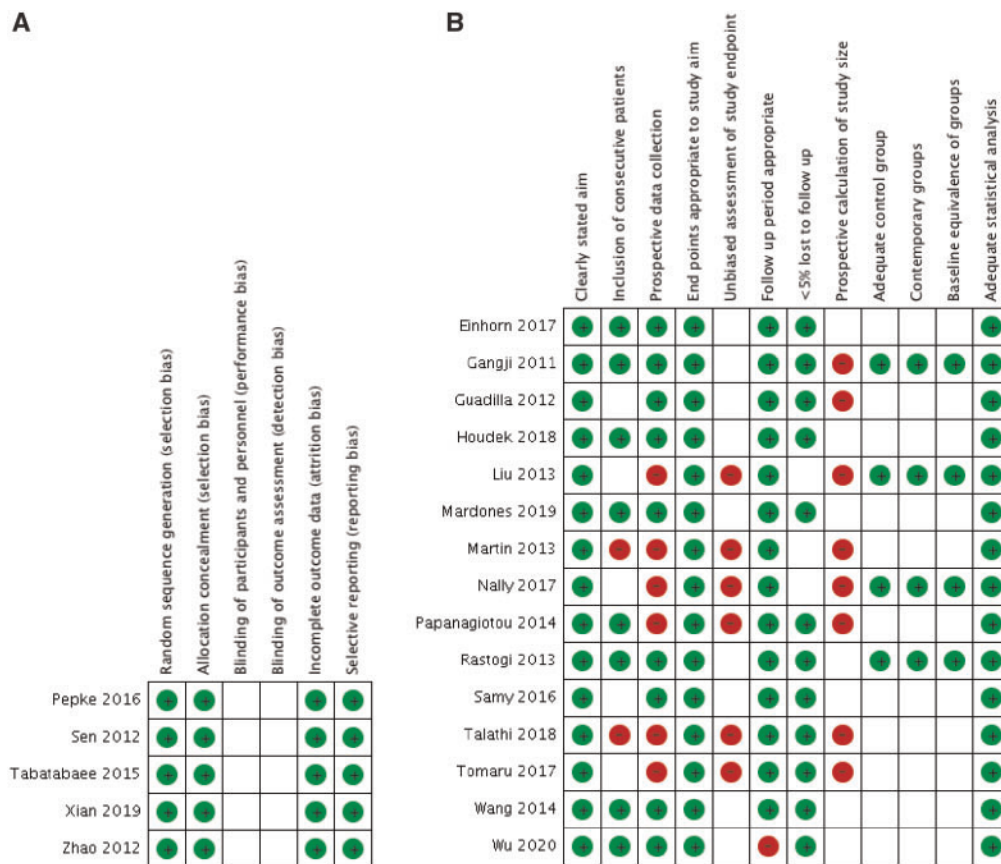
### Core decompression + PRP

PRP is concentrated plasma containing an increased volume of platelets when compared to the normal circulation [41]. These platelets contain several growth factors which after administration, get released and facilitate growth and tissue building. Theoretically, once CD reduces the increased intraosseous pressure and prepares channels for vascular growth, these growth factors could further facilitate that growth and bone formation; thereby improving symptoms and either reversing the pathology or delaying the progression. Three studies in the present review assessed the effect of PRP in combination with CD (Table II). Although the technique of CD varied among the studies, the overall principle of treatment remained the same. Xian *et al.*, in a randomized control trial, treated 24 patients in pre-collapse stages of AVN hip with PRP as an adjuvant to CD. They compared them with 22 patients with CD alone [21]. Autologous bone graft was used in both the groups; the minimum follow-up was 3 years.

Although both the groups showed significantly improved Harris Hip scores (HHS), the PRP group achieved more clinically essential improvements (91.7% versus 68.7%;  $P < 0.05$ ). Additionally, the HHS and Visual analogue scale score also favoured the PRP group at the final follow-up ( $P = 0.024$  and  $0.0125$ ). Only three patients in the PRP group needed hip replacements, while seven patients in the other group required the same due to arthritis. Overall, it was clear from the authors' findings that PRP is an effective adjuvant to CD and bone grafting for pre-collapse stages of AVN.

Samy *et al.* utilized a different method to decompress the femoral head in 40 hips of 30 patients; they dislocated it anteriorly, removed the necrotic area and drilled multiple holes there [22]. Subsequently, they added bone graft mixed with PRP and covered the spot with fibrin glue and collagen to keep the adjuvant in place. The mean HHS significantly improved from pre-operative period to mean of 90.28 with 36 patients reporting good to excellent scores





**Fig. 3.** Authors’ assessment of bias in the individual studies (in alphabetical order). (A) Randomized studies; (B) non-randomized studies.

after a mean follow-up of 41.4 months. The remaining four were offered THR. The VAS score also improved significantly ( $P < 0.0001$ ). The authors concluded that PRP enhances the reparative capacity after drilling the necrotic area in pre-collapse stages of AVN before flattening of the head.

Guadilla *et al.* described CD with arthroscopic and fluoroscopy guidance, and documented their results of CD with grafting and PRP in four patients in pre-collapse stages of AVN hips [23]. All four patients had more than 60% improvement in their pain intensities measured by VAS, and they went back to their routine life by the 5th month post-surgery. The technique described by the authors consisted of accessing the femoral head through its base with the hip flexed to 10°–15° and neutral coronal plane alignment with moderate traction. The necrotic area was reached by manoeuvring the hip into required flexion/extension with rotational movements. Drilling of several holes was done using Steinmann pin (3.2 mm), through the anterior or ancillary portal. PRP was injected through the created channel.

From the literature available for review, PRP as an adjuvant has shown promising results; however, with only 68 treated hips in the data surveyed, there is inconclusive evidence for its routine utilization in AVN hips. Further large scale multicentric studies with an increased number of patients are needed for establishing it as a viable adjuvant.

### Core decompression + BMAC

Bone marrow aspiration concentrate (BMAC) contain mononuclear stem cells that are the building blocks of the structural architecture of the hip. They differentiate into the bone-forming cells and replace the aged, defective cells, thus maintaining the balance and structural integrity [16–19]. Replacing a sufficient amount of stem cells in the hip after decompression and instilling new pool of lineage of cells that could differentiate into cells necessary for the normal physiological function of the hip, seems to be a viable treatment option for pre-collapse stages of AVN. Different nomenclatures have been used for these cells; BMAC, MSCs and bone marrow mononuclear cells

Table II. Studies describing PRP as adjuvant to core decompression

S. No.	Authors, year	Study design	AVN stage	Intervention	No. of patients	Mean age (years)	M and F	Mean follow-up (months)	Final HHS, WOMAC etc.	Final VAS/ pain	Survival/arthroplasty conversion	Inference
1	Guadilla <i>et al.</i> [23], 2012	Prospective case series	Steinberg IIa, IIb	Arthroscopic core decompression + ABG + PRP	4	N/A	N/A	14	N/A	>60% significant improvement in all cases	-	Procedure needs to be explored further
2	Samy <i>et al.</i> [22], 2016	Prospective case series	Modified Ficat IIb, III	Anterior dislocation + Removal of necrotic area + multiple drill holes + ABG mixed with PRP; covered with collagen gel and fibrin glue	30 (40 hips)	36.7	19, 11	41.4 ± 3.5	HHS 90.28 ± 19 (P < 0.0001) Excellent-27 Good-9	35 ± 19 (P < 0.0001)	4 patients with fair HHS-prepared for THR	PRP increases reparable capacity after necrotic segment drilling
3	Xian <i>et al.</i> [21], 2019	RCT	Post-traumatic ARCO II, III	T/t: CD + PRP incorporated ABG. Cntrl: CD + ABG	T/t: 24 Cntrl: 22	T/t: 28.3 Cntrl: 29.6	T/t: 15, 9 Cntrl: 10, 12	T/t: 44.9 Cntrl: 46.2	HHS T/t: 86.5 ± 1.6 Cntrl: 79.3 ± 2.4 (P = 0.0254)	Significantly better in T/t group (P = 0.125)	T/t: 3 THR Cntrl: 7 THR; 2 transtrochanteric osteotomies	PRP is an effective adjuvant to CD + ABG

(BMMCs) [24–28]. Multiple studies have assessed its role as an adjuvant to CD and have shown promising results (Table III). Wang *et al.* treated 20 hips in 15 patients with CD, curettage, bone graft and BMAC combination [24]. After a mean follow-up of 2 years, the average HHS was 85, with 15/20 patients showing good to excellent scores (score >80). Eighty percent of hip survival rates were achieved, and only four hips exhibited worsening of the stage but did not require THR at the final follow-up. The authors described the salvage procedure as an effective one for early stages of AVN.

Tomaru *et al.* evaluated 31 patients of AVN treated by CD and BMAC with a mean follow-up of 5.8 years [25]. The patients showed improvement with increased Japanese Orthopaedic Association score ( $P < 0.05$ ) and decreased pain score ( $P < 0.05$ ). Eleven out of thirty-one hips with larger areas of necrosis went into collapse, and three patients (9.6%) needed hip replacements. The authors reported that their collapse rate in hips with the broader area of necrosis (occupying more than medial two-third of the weight-bearing portion) was lesser than the natural course of similar AVN hips as reported by other studies. Overall, the study showed that in the early stages of AVN, CD with BMAC is a less invasive modality with excellent outcomes.

Talathi *et al.* utilized this technique in 43 hips of 28 patients and achieved a significant decrease in VAS score from 7.8 pre-operatively to 2.5 after surgery ( $P < 0.0001$ ), at an average follow-up of 16 months [26]. Seventy-eight percent of their patients reported more than 50% decrease in their pain, and 40 hips did not show any progression on serial radiographs. There were three cases of femoral head collapse that needed arthroplasty at a mean period of 17 months after surgery. The authors concluded that this method could arrest disease progression and provide significant symptomatic relief.

Einhorn *et al.* used CD with BMAC in 66 hips of 52 patients and at 2 years showed that 63% improvement in total WOMAC scores (from 36 at baseline to 13 at 2 years),  $P < 0.001$  [27]. Symptoms such as pain and joint stiffness significantly improved and score of quality of life (SF-12 and EQ-5D) also improved significantly ( $P < 0.001$ ). Excluding the 11 hips that were lost to follow up, the hip survival was 75% (41/55), with only 14/55 hips needing THR. The overall successful outcome was reported by the authors who described CD + BMAC as a worthy modality in Stage I and II AVN hips. However, since CD alone has been shown to be extremely successful in Stage I cases, for practical purposes BMAC should ideally be used in subsequent stages.

Several Level 1 randomized clinical studies have also been conducted to compare CD and CD + BMAC in early

stages of AVN hips. Sen *et al.* performed CD in 25 hips and used BMAC as an adjuvant in the other 26 hips [28]. After a follow-up of 2 years, their patients showed a significant improvement in the HHS, with the BMAC group showing better outcomes at 1-year follow-up ( $P < 0.016$ ). At 2 years as well, domains of pain and deformity showed more improvement in the BMAC group. The average survival rates evaluated by the Kaplan–Meier survival analysis were 46.72 and 51.85 weeks in two groups ( $P < 0.0351$ ). The authors did not mention the number of subsequent failures and THRs done after 2 years of follow-up. Interestingly, the authors reported that those patients who had relatively lower HHS and worse radiological appearances pre-operatively, showed better hip survival with BMAC.

Tabatabaee *et al.* divided 18 patients (28 hips) into 2 groups of 14 hips each and at 2 years demonstrated better WOMAC scores ( $P < 0.001$ ) and improved pain scores in the BMAC group [29], while the CD alone group had three cases that needed THR. The authors described the combination of CD + BMAC to be better than CD alone for early AVN hips.

Similar results were given previously by Gangji *et al.* with average follow-up of 5 years, comparing CD + BMAC (13 hips) with CD alone (11 hips) in ARCO I and II stages of AVN hips [30]. Although the overall WOMAC scores did not differ, the VAS score ( $P = 0.009$ ) and pain component of WOMAC score ( $P < 0.052$ ) were significantly worse in CD only group. Progression of disease to Stage III was more significant in the CD only group with 8/11 hips, compared with only 3 of 13 hips in the BMAC group ( $P = 0.038$ ). This long-term study also concluded that BMAC implantation as an adjuvant to CD is a more effective treatment than CD alone.

Rastogi *et al.* did a trial where they tweaked the CD only group when compared with previous studies and added unprocessed bone marrow aspirate with CD in one group and BMMCs with CD in the other group ( $n = 30$  hips in both groups) [31]. At a follow-up of 2 years, their results showed an improved HHS in both the group; however, it was much better in the group with BMMCs ( $P = 0.03$ ). There were three THRs in the unprocessed bone marrow group, with no hips needing THR in the BMMCs group. Size of the lesions in the BMMCs group shrank significantly ( $P = 0.03$ ) in the ARCO I and II cases. The authors described the procedure to be safe and effective for early stages of AVN hip.

Liu *et al.* formed two groups of AVN patients and treated them by CD with a nano-hydroxyapatite or polyamide filler in one group (26 hips) and added BMMCs in the second group (27 hips) [32]. After an average



**Table III. Studies describing BMAC ± core decompression**

S. No.	Authors, year	Study design	AVN stage	Intervention	No. of patients	Mean age (years)	M and F	Mean follow-up (months) etc.	Final HHS, WOMAC	Final VAS/Pain	Survival/arthroplasty conversion	Inference
1	Gangji <i>et al.</i> [30], 2011	Prospective Pilot study	ARCO I, II	T/t: CD + BMAC Cntrl: CD	19 (24 hips) 13 hips and 11 hips	42.2 45.7	10, 9	60	Overall WOMAC score did not differ (pain part was significantly worse in cntrl group; $P < 0.05$ )	Lesser VAS in T/t group ( $P = 0.009$ )	Progression to Stage III more in cntrl group ( $P = 0.038$ ) Time to failure better in BMAC group.	Long-term study suggests BMAC implantation in early AVN is effective
2	Sen <i>et al.</i> [28], 2012	RCT	ARCO I, II	Group A: CD; Group B: CD + BMAC (mononuclear)	40 (51 hips) A: 25 hips B: 26 hips	-	A: 18, 7 (hips) B: 19, 7 (hips)	24	HHS A: $77.39 \pm 16.98$ B: $82.4 \pm 9.63$	-	Better survival in B ( $P < 0.0351$ ) Cntrl: 3	More marked improvement with CD+BMAC specially in patients with poor prognostic features
3	Zhao <i>et al.</i> [37], 2012	RCT	ARCO I, II	CD versus CD with trephine + bore graft + BMAC (cultured and expanded)	100 (104 hips) 50 patients in each group (51 and 53 hips)	33.8 32.7	26, 24 27, 23	60	Significantly better HHS in second group	-	10 worsened (5 THR) 2 worsened (no THR) $P < 0.05$	Functional scores and necrotic volume of femoral head had better outcome with BMAC
4	Rastogi <i>et al.</i> [31], 2013	Prospective clinical trial	ARCO I, II, III	Group 1: CD + BMAC (mononuclear cells) Group 2: CD + unprocessed BMA	40 (60 hips) 30 hips in each group	34.67 33	NA	24	Improvement in HHS Group 1: 1-31.85 Group 2: 2-19.72 ( $P = 0.03$ )	-	No THR 3 THR ARCO I, II: showed improved radiology	BMAC is safe and effective with better outcome than unprocessed aspirate in early AVN

(continued)

**Table III. (continued)**

S. No.	Authors, year	Study design	AVN stage	Intervention	No. of patients	Mean age (years)	M and F	Mean follow-up (months)	Final HHS, WOMAC etc.	Final VAS/Pain	Survival/arthroplasty conversion	Inference
5	Liu <i>et al.</i> [32], 2013	Retrospective series	ARCO I, II, IIIA	A: CD + BMMC + filler B: CD + filler	34 (53 hips) A: 26 hips B: 27	38 38.1	13, 4 14, 3	26.7 24.9	Group A had more increase in HHS (28.6); $P < 0.001$	VAS decreased more in Group A ( $P < 0.001$ )	Higher success rate in Group A ( $P = 0.004$ ); 6 hips showed collapse (4 THR) Group B: 16 collapses (5 THR)	Addition of BMMC makes CD + Filler more effective
6	Wang <i>et al.</i> [24], 2014	Prospective case series	ARCO II, III	CD + curettage + ABG + BMAC (mononuclear cells)	15 (20 hips)	35	10, 5	24	HHS 85 Excellent : 7 Good : 8 Fair : 4 Poor : 1	NA	80% survival; 4 hips worsened but no THR	Effective procedure in early stages
7	Tabatabaee <i>et al.</i> [29], 2015	Prospective randomized trial	ARCO I, II, III	A: CD + BMAC B: CD	18 (28 hips) A: 14 B: 14	31 26.8	9, 5 10, 4	24	Better WOMAC in Group A ( $P < 0.001$ )	Mean score significantly lower in Group A	3 THR in group B; none in group A	Combination is more effective in early stages than only CD
8	Pepke <i>et al.</i> [33], 2016	Randomized clinical trial	ARCO II	CD versus CD + BMAC	24 (25 hips) CD-14 CD + BMAC-11	44.5 44.3	12, 2 10, 1	24	Comparable HHS in both groups	VAS decreased in both groups ( $P < 0.05$ )	No difference in survival	No difference with BMAC as an adjunct to CD in short term
9	Nally <i>et al.</i> [34], 2017	Retrospective series	Ficat I, II	1. CD 2. CD + BG 3. CD + BMAC	33 (47 hips) 27 (34 hips) 12 (16 hips)	38 40 41	24, 9 21, 6 8, 4	72 48 72	-	-	Survival- 56% 50% 50% (no significant difference)	No difference in any of the groups
10	Einhorn <i>et al.</i> [27], 2017	Prospective series	ARCO I, II	CD + BMAC	52 (66 hips)	40	29, 23	24	Total score improvement 63% ( $P < 0.001$ ) SF-12 scores and EQ-5D improved ( $P < 0.001$ )	65% improvement in pain (as per WOMAC subcategory score)	11 lost to follow up. Survival of 75% (41/55 hips) 14 cases failed (needed THR)	CD + BMAC is a promising option for early AVN hip.

(continued)

**Table III. (continued)**

S. No.	Authors, year	Study design	AVN stage	Intervention	No. of patients	Mean age (years)	M and F	Mean follow-up (months)	Final HHS, WOMAC etc.	Final VAS/Pain	Survival/arthroplasty conversion	Inference
11	Tomaru <i>et al.</i> [25], 2017	Retrospective series	JOA staging, I, II	CD + BMAC	31	40	19	69.6	JOA walking and quality of life scores improved. ( $P < 0.05$ )	Pain scores decreased significantly ( $P < 0.05$ ); 2 patients had pain on walking	3 THR; 11 hips showed secondary collapse when lesions were large	Long-term outcomes were good with disease progression rate less than natural course
12	Talathi <i>et al.</i> [26], 2018	Retrospective series	ARCO I, II	CD + BMAC	28 (43 hips)	40.1	13, 15	16	-	2.5 (significant decrease, $P < 0.0001$ )	3 THR (after average of 17 months)	CD + BMAC provides significant pain relief and arrests progression
13	Mardones <i>et al.</i> [36], 2019	Prospective cohort	Ficat II, III ( $n = 4$ and 1); <50% head involved	CD + BMAC ( <i>ex vivo</i> expansion)	5	41.2	4, 1	33.8	MHHS: from 73.6 to 98.2	From 4.6 to 0.4	No THR	MSC-based therapy is safe and effective in early stages
14	Wu <i>et al.</i> [35], 2020	Prospective series	ARCO II	CD + BMAC (mononuclear cells) in collagen sponge	30	30.6	19, 11	9	HHS $84.66 \pm 6.97$ ( $P < 0.05$ )	$1.91 \pm 0.53$ ( $P < 0.05$ )	Mean repair ratio better in patients receiving BMAC with better differentiation	Quality of stem cells determine success of the method

follow-up of 26.7 and 24.9 months, respectively, patients in both the groups had significantly improved HHS from the pre-operative values ( $P < 0.06$ ). On comparing the groups, it was shown that the patients who received BMACs, had a more significant increase in the scores ( $28.6 \pm 0.5\%$ ) than the other group ( $18.4 \pm 1.7\%$ ),  $P < 0.001$ . Similar improvements were seen in the overall VAS scores as well, with a more significant decrease in the BMACs group ( $-66.3 \pm 1.4\%$ ), compared with the other group ( $-51.7 \pm 2.9\%$ ) ( $P < 0.001$ ). Clinical success was defined by the authors as a proportion of patients in either group with HHS  $> 80$ , which was also higher in the BMACs group (75.4% versus 37%). Additionally, radiological head collapse or the advent of the osteoarthritic stage were significantly lesser in this group (21.4% versus 59.3% failure). The authors concluded that BMACs as adjuvant might be a more effective treatment for early AVN than CD alone.

There have also been reports that did not show additional benefits of BMAC with CD. Pepke *et al.* did a randomized clinical trial comparing CD with CD + BMAC in 24 patients with 25 hips (14 and 11 hips in both groups, respectively) in ARCO I and II stages [33]. At a follow-up of 2 years, the patients in both groups had comparable HHS and significantly decreased VAS scores from pre-operative values ( $P < 0.05$ ). There was no difference in the survival rates of the operated hips between the groups, with eight and seven cases not progressing or requiring THR in the respective groups. Overall, the authors could not ascertain any added efficacy of BMAC as an adjuvant to CD.

Nally *et al.* compared three groups; CD (47 hips), CD + bone graft (34 hips) and CD + BMAC (16 hips) in Ficat stages I and II [34]. They assessed the difference in conversion to THR in these patients based on the therapy given and found out the rates of conversion to arthroplasty did not differ significantly ( $P = 0.2$ ), with a total of 48 cases needing it (49.5%) at 5.5 years of average follow-up. Fifty percent of patient who received BMAC (MSCs) required THR at average follow-up of 4 years. Overall, there was no utility of adding MSCs or bone graft to CD in increasing survival of affected hips. One possible reason for these studies reporting contrary results could be the quality of BMAC/MSCs itself.

Wu *et al.* treated 30 patients with CD using a 6.5-mm drill, curettage and BMAC soaked in collagen sponge and showed significant improvement in HHS and VAS score after mean follow-up of 9 months (HHS: 84.66, VAS: 1.91;  $P < 0.05$ ) [35]. The necrotic area was evaluated by MRI, and repair ratio was calculated by dividing the difference of this area before and after 9 months of surgery, by the area before surgery and multiplying the value by 100. The

necrotic area ratio showed a significant decrease from 35.51 to 13.74% at 9 months. The mean repair ratio was  $62.2 \pm 27\%$ , and it correlated positively with improvement in HHS, indicating more the radiological repair better is the functional outcome. Additionally, it was demonstrated that the BMAC cells in patients with better repair ratio showed better staining for osteogenic and chondrogenic differentiation, and this probably determines the ultimate result of BMAC therapy in AVN hips.

Given these contrary reports of utility of BMAC/MSCs, interventions to increase the content quality of these cells before instillation into the patients were devised. *Ex vivo* expansion by culturing the cells is a viable and practical option. Mardones *et al.* increased the content of MSCs in BMAC by culturing and expanding them *ex vivo* and injected it through the tract of the CD performed in five cases [36]. After follow-up ranging from 19 to 54 months, the modified HHS scores considerably improved (mean = 98.2) and the VAS scores decreased (from 4.6 to 0.4) in all five patients. Although the number of patients was limited, no case needed arthroplasty. In comparison, the authors stated that in their practice, when the non-expanded stem cells were used with CD, 80% of cases ultimately needed THR. It is interesting to note that expansion of the stem cells increased their numbers, which was quantified before instillation. Minimum of  $40 \times 10^6$  cells were instilled in each hip.

Zhao *et al.* compared CD (50 patients) with CD plus cultured BMAC with expanded MSCs (50 patients) [37]. At a mean follow-up of 5 years, they reported significantly better HHS in the BMAC group. Additionally, 10 hips worsened radiologically (necrotic volume) in the CD only group, with 5 of them undergoing arthroplasty; only 2 hips further exacerbated in the BMAC group. The authors concluded that expanded BMAC provides better functional outcome and lesser disease progression with better survival. Therefore, cultured BMAC, along with CD could be an appealing option in the future.

Autologous stem cells or BMAC with the mesenchymal mononuclear cells have been proved to enhance the efficacy of CD when used as an adjunct. The overwhelming majority of the studies in the literature evaluating this combination gave positive results in the early stages of AVN hip with symptomatic pain relief and improved functional outcomes. Improving the quality and number of these cells before instillation could further aid in achieving these therapeutic goals of hip survival.

#### Core decompression + BMAC + PRP

With the variable results of BMAC, the focus may now be shifting to enhancing the number of bone-forming cells.

Besides the *ex vivo* culturing of the cells discussed above, the addition of growth factors that could improve the number of these cells may be a practical solution. The latter can be done by mixing BMAC with PRP, which contains the essential growth factors (Table IV).

Martin *et al.* utilized CD, BMAC and PRP combination in 49 patients with 77 hips and after an average follow-up of 17 months reported significant pain relief in 86% of their patients [38]. Sixteen of the 77 hips required THR.

Houdek *et al.* included 22 patients with 35 AVN hips due to steroid use and treated them with CD + BMMSC + PRP [39]. Results were evaluated as survivorship free from THR at 2 and 3 years follow-ups, which was 97% and 84%, respectively. Only four hips needed THR, while two bilateral cases needed repeat CDs.

PRP was used as a media which potentially contains all the factors for the growth of the mesenchymal cells, thus increasing the amount of BMMSC *in vivo* after instillation. However, literature includes only short-term follow-up studies with excellent results, and further research in the form of comparative randomized trials on the utility of CD + BMAC + PRP is still needed to establish its edge over the CD + BMAC alone.

**CD + recombinant BMP-7**

Bone morphogenetic proteins (BMP) act on MSCs and aid in proliferation and differentiation to bone-forming cells, in turn leading to bone remodelling. BMP-7 is available commercially and has been tested in cases like non-unions. We found one study in our search; Papanagiotou *et al.* who used recombinant (rh) BMP-7 (Stryker Ltd, Raheen business park, Limerick, Ireland) with CD and non-vascularized fibula graft in 7 hips of 6 patients [40]. After a mean follow-up of 4 years which ranged from 2 to 5.5 years, the authors reported THR in two hips of the bilateral case after 1 year of surgery. The other patients showed marked improvement clinically with both VAS scores and the HHS improving significantly. On X-rays at the final follow-ups, the femoral heads showed no signs of flattening or collapse. Although four hips showed heterotrophic ossification, it had no clinical implications. Overall, the treatment combination came out effective in stopping the progression of the disease and provide significant clinical improvement.

Overall the utilization of recombinant BMP-7 in the past decade as an adjuvant to CD is minimal, probably because of reduced availability and higher cost. Although all the seven hips in the lone study assessing its efficacy showed marked improvements, the data is very limited to recommend it as a valuable adjuvant. Further studies are needed to establish its utility and cost-effectiveness.

**Table IV. Studies describing combination of PRP and BMAC with core decompression**

S. No.	Authors, year	Study design	AVN stage	Intervention	No. of patients	Mean age (years)	M and F	Mean follow-up (months)	Final HHS, WOMAC etc.	Final VAS/ pain	Survival/ arthroplasty conversion	Inference
1	Martin <i>et al.</i> [38], 2013	Retrospective series	Ficat I, II	CD + BMAC + PRP	49 (77 hips)	43	—	17	—	86% had significant pain relief	16 THR	Provides significant pain relief and halts disease progression in early AVN
2	Houdek <i>et al.</i> [39], 2018	Prospective case series	UOP Stage I, II	CD + BMAC + PRP	22 (35 hips)	43	11, 11	36	HHS 85 ± 15 (P < 0.0001) Excellent to good: 77% hips	—	84% survival; collapse in 7%; 4 THR; 2 b/1 patients needed repeat CD	Successful results of >90%; better when necrotic area was smaller at early stages.



### Prospective adjuvants—bisphosphonates

One of the pitfalls of all the adjuvants described above is the cost factor; PRP, BMAC as well as the rh-BMPs being quite expensive. In developing countries with a large percentage of population below the poverty line and the absence of comprehensive insurance covers, such costly treatments become inaccessible. So, there is a need for cost-effective adjuvants that can be provided for a larger patient population. Bisphosphonates act against osteoclast-mediated bone loss by inducing osteoclast apoptosis [42]. Theoretically, their role in osteonecrosis to halt bone death may be crucial, and studies using bisphosphonates have been done with both subcutaneous and oral administration giving positive results in early AVN [43, 44]. However, the need is to localize the drug action specifically to the area where it is needed; the intraosseous route could be a feasible option to enhance bisphosphonate action at the diseased zone. This has never been explored in humans, but few studies have been done in animals, showing bioavailability of these drugs plus maintenance of structural integrity without structural collapse [45–47].

Aya-ay *et al.* evaluated the retention, distribution and effects of intraosseously administered Ibandronate (560  $\mu\text{g}$ ) in piglets and observed that only 5% of the total cumulative systemic dose ( $\sim 12\,000\ \mu\text{g}$ ) was sufficient for effective delivery [45].

To enhance the growth of bone-forming cells, some studies have also used local BMP-2 with intraosseous bisphosphonates. Both Vandermeer *et al.* and Kim *et al.* reported that simultaneous local administration of ibandronate and BMP-2 improved the preservation of the spherical shape of the femoral head and stimulated bone healing in piglets with ischaemic osteonecrosis [46, 47].

Therefore, to conclude there is a likelihood that along with CD which will stimulate new bone formation, a bisphosphonate like Ibandronate if instilled intraosseously will stop the bone resorption, thereby enhancing the overall effect on bone formation. Bisphosphonates are much cheaper than other described adjuvants and therefore, this affordable option if proven effective along with CD can lead to betterment for a large population of patients. The authors of the present review have already started a trial on this therapeutic modality.

### Miscellaneous: combinations and modes of administration

Besides their intraosseous instillation, an intra-arterial administration of BMACs via the femoral artery has been described. Cai *et al.* injected BMACs along with allogenic umbilical cord-derived MSCs in 30 patients (24 males; 6

females) with AVN hip [48]. Forty-nine hips were treated with this method, with AVN at ARCO II or III stages. The technique comprised of Digital subtraction angiography and identification of 1 of the three arteries; MCFA, LCFA or obturator artery was done, and the predominant one in the particular femoral head was cannulated; the cells were infused over 30 min. The patients witnessed improvements in pain and joint function. The HHS increased significantly up to 1 year, and 44 bone lesions improved on CT scan. The authors concluded that this treatment was a safe modality in AVN hip.

Chen *et al.* utilized only cord-derived MSCs for intra-arterial infusions in nine patients (four males and five females) of ARCO II and III stages. Their MRIs showed that the necrotic volumes decreased significantly ( $7.16 \pm 0.73$  to  $5.86 \pm 1.67\ \text{cm}^3$ ) between 12 and 24 months; the method also proved useful in increasing the HHS from the pre-operative value at 1 year [49].

Daltro *et al.* described a modification in instillation of BMAC in the femoral head lesion, utilizing percutaneous approach for injecting it through a single puncture with 3 mm trocar under fluoroscopy guidance [50]. Eighty-nine patients were followed up for 5 years, and they showed significant improvement in symptoms and HHS from 75.7 to 93.1 ( $P = 0.0005$ ). Three patients did not show satisfactory improvement; however, their radiological stages did not progress.

Recombinant BMP-2 was utilized by Sun *et al.* along with 'Light bulb procedure' (bone grafting through a cortical window at the head–neck junction of the femur) [51]. They included 42 patients with 79 affected hips in ARCO I, II and III A stages and the average follow-up was 6.1 years. Thirty-six hips were given BMP-2 along with curettage and grafting, while 43 hips only received curettage and bone grafting. The HHS in first group was  $82.3 \pm 13.2$ , and it was  $78.9 \pm 12.6$  in the non-BMP group. Better results were seen in Stage II than Stage III disease. The survival rates were 81.8 and 71.8 in the two groups, with Stage IIIa having overall rates of only 34.6%. The results suggested that this method of head salvage is suitable for early stages, and rh-BMP 2 could aid in improving the quality of the repair.

The alternative route of intra-arterial administration of BMAC is an exciting option for pre-collapse stages of AVN hip, wherein post-operative mobilization could be faster when compared with its usage as an adjuvant to CD, which requires non-weight bearing for 4–6 weeks. It has added advantage of being a quicker and safe procedure, which has shown promise with favourable outcomes. However, due to the limited number of studies

and short follow-ups, we cannot recommend its extensive usage instead of a proven modality like CD + BMAC.

### CONCLUSION

The prevalence of AVN of the hip in a relatively younger population warrants early interventions that could salvage the affected hip and delay arthroplasty for as long as possible. CD along with the available adjuvants like BMAC, PRP or their combination, work more potently than CD alone, in achieving this therapeutic goal; however, the associated costs mandate assessment of alternative adjuvants and apt patients' selection to determine the best mode of administration of these orthobiologics, to improve overall outcomes.

### CONFLICT OF INTEREST STATEMENT

The authors declare no conflict of interest and nil funding.

### DATA AVAILABILITY STATEMENT

There is no additional data.

### REFERENCES

- Lau RL, Perruccio AV, Evans HM *et al.* Stem cell therapy for the treatment of early-stage avascular necrosis of the femoral head: a systematic review. *BMC Musculoskelet Disord* 2014; **15**:156.
- Bozic KJ, Zurakowski D, Thornhill TS. Survivorship analysis of hips treated with core decompression for nontraumatic osteonecrosis of the femoral head. *JBJS* 1999; **81**:200–9.
- Cheng EY, Thongtrangan I, Laorr A *et al.* Spontaneous resolution of osteonecrosis of the femoral head. *JBJS* 2004; **86**:2594–9.
- Hernigou P, Beaujean F. Treatment of osteonecrosis with autologous bone marrow grafting. *Clin Orthop Relat Res* 2002; **405**:14–23.
- Hernigou P, Beaujean F, Lambotte JC. The decrease in the mesenchymal stem-cell pool in the proximal femur in corticosteroid-induced osteonecrosis. *J Bone Joint Surg Br* 1999; **81-B**: 349–55.
- Gangji V, Hauzeur JP, Matos C *et al.* Treatment of osteonecrosis of the femoral head with implantation of autologous bone-marrow cells: a pilot study. *J Bone Joint Surg Am* 2004; **86**:1153–60.
- Phemister DB. Treatment of the necrotic head of the femur in adults. *J Bone Joint Surg Am* 1949 **1**; **31**:55–66.
- Mutijima E, De Maertelaer V, Deprez M *et al.* The apoptosis of osteoblasts and osteocytes in femoral head osteonecrosis: its specificity and its distribution. *Clin Rheumatol* 2014; **33**:1791–5.
- Fairbank AC, Bhatia D, Jinnah RH *et al.* Long-term results of core decompression for ischaemic necrosis of the femoral head. *J Bone Joint Surg Br* 1995; **77**:42–9.
- Iorio R, Healy WL, Abramowitz AJ *et al.* Clinical outcome and survivorship analysis of core decompression for early osteonecrosis of the femoral head. *J Arthroplasty* 1998; **13**:34–41.
- Yoon TR, Song EK, Rowe SM *et al.* Failure after core decompression in osteonecrosis of the femoral head. *Int Orthop* 2001; **24**: 316–8.
- Sugioka Y, Hotokebuchi T, Tsutsui H. Transtrochanteric anterior rotational osteotomy for idiopathic and steroid-induced necrosis of the femoral head: indications and long-term results. *Clin Orthop* 1992; **277**:111–20.
- Rijnen WH, Gardeniers JW, Westrek BL *et al.* Sugioka's osteotomy for femoral-head necrosis in young Caucasians. *Int Orthop* 2005; **29**:140–4.
- Zhou W, Qu M, Lv Y *et al.* New advances in stem cell therapy for osteonecrosis of the femoral head. *Curr Stem Cell Res Ther* 2019; **14**:226–9.
- Alshameeri Z, McCaskie A. The role of orthobiologics in hip preservation surgery. *J Hip Preserv Surg* 2015; **2**:339–54.
- Piuzzi NS, Chahla J, Schrock JB *et al.* Evidence for the use of cell-based therapy for the treatment of osteonecrosis of the femoral head: a systematic review of the literature. *J Arthroplasty* 2017; **32**:1698–708.
- Papavasiliou AV, Triantafyllopoulos I, Paxinos O *et al.* The role of cell therapies and hip arthroscopy in the management of osteonecrosis: an update. *J Hip Preserv Surg* 2018; **5**:202–8.
- Gagala J, Tarczynska M, Gaweda K *et al.* The use of osteochondral allograft with bone marrow-derived mesenchymal cells and hinge joint distraction in the treatment of post-collapse stage of osteonecrosis of the femoral head. *Med Hypotheses* 2014; **83**:398–400.
- Kang JS, Suh YJ, Moon KH *et al.* Clinical efficiency of bone marrow mesenchymal stem cell implantation for osteonecrosis of the femoral head: a matched pair control study with simple core decompression. *Stem Cell Res Ther* 2018; **9**:274.
- Moher D, Liberati A, Tetzlaff J, Altman DG, PRISMA Group. Preferred reporting items for systematic reviews and meta-analyses: the PRISMA statement. *Int J Surg* 2010; **8**:336–41.
- Xian H, Luo D, Wang L *et al.* Platelet-rich plasma-incorporated autologous granular bone grafts improve outcomes of post-traumatic osteonecrosis of the femoral head. *J Arthroplasty* 2020; **35**:325–30.
- Samy AM. Management of osteonecrosis of the femoral head: a novel technique. *Indian J Orthop* 2016; **50**:359–65.
- Guadilla J, Fiz N, Andia I *et al.* Arthroscopic management and platelet-rich plasma therapy for avascular necrosis of the hip. *Knee Surg Sports Traumatol Arthrosc* 2012; **20**:393–8.
- Wang T, Wang W, Yin ZS. Treatment of osteonecrosis of the femoral head with thorough debridement, bone grafting and bone-marrow mononuclear cells implantation. *Eur J Orthop Surg Traumatol* 2014; **24**:197–202.
- Tomaru Y, Yoshioka T, Sugaya H *et al.* Hip preserving surgery with concentrated autologous bone marrow aspirate transplantation for the treatment of asymptomatic osteonecrosis of the femoral head: a retrospective review of clinical and radiological outcomes at six years postoperatively. *BMC Musculoskelet Disord* 2017; **18**:292.
- Talathi NS, Kamath AF. Autologous stem cell implantation with core decompression for avascular necrosis of the femoral head. *J Clin Orthop Trauma* 2018; **9**:349–52.
- Einhorn TA, Anoushiravani AA, Chen KK *et al.* Treatment of stage I and II osteonecrosis of the femoral head with core decompression and bone marrow aspirate concentrate injection—a 2-year follow-up study. *Sem Arthroplasty* 2017; **28**: 239–45.
- Sen RK, Tripathy SK, Aggarwal S *et al.* Early results of core decompression and autologous bone marrow mononuclear cells

- instillation in femoral head osteonecrosis: a randomised control study. *J Arthroplasty* 2012; **27**:679–86.
29. Tabatabaee RM, Saberi S, Parvizi J *et al.* Combining concentrated autologous bone marrow stem cells injection with core decompression improves outcome for patients with early-stage osteonecrosis of the femoral head: a comparative study. *J Arthroplasty* 2015; **30**:11–5.
  30. Gangji V, De Maertelaer V, Hauzeur JP. Autologous bone marrow cell implantation in the treatment of non-traumatic osteonecrosis of the femoral head: five-year follow-up of a prospective controlled study. *Bone* 2011; **49**:1005–9.
  31. Rastogi S, Sankineani SR, Nag HL *et al.* Intralesional autologous mesenchymal stem cells in management of osteonecrosis of femur: a preliminary study. *Musculoskelet Surg* 2013; **97**:223–8.
  32. Liu Y, Liu S, Su X. Core decompression and implantation of bone marrow mononuclear cells with porous hydroxylapatite composite filler for the treatment of osteonecrosis of the femoral head. *Arch Orthop Trauma Surg* 2013; **133**:125–33.
  33. Pepke W, Kasten P, Beckmann NA *et al.* Core decompression and autologous bone marrow concentrate for treatment of femoral head osteonecrosis: a randomised prospective study. *Orthop Rev (Pavia)* 2016; **8**:6162.
  34. Nally FJ, Zanotti G, Buttarro MA *et al.* THA conversion rate comparing decompression alone, with an autologous bone graft or stem cells in osteonecrosis. *Hip Int* 2018; **28**:189–93.
  35. Wu ZY, Sun Q, Liu M *et al.* Correlation between the efficacy of stem cell therapy for osteonecrosis of the femoral head and cell viability. *BMC Musculoskelet Disord* 2020; **21**:55.
  36. Mardones R, Camacho D, Monsalvo F *et al.* Treatment of osteonecrosis of the femoral head by core decompression and implantation of fully functional ex vivo-expanded bone marrow-derived mesenchymal stem cells: a proof-of-concept study. *Stem Cells Cloning* 2019; **12**:11–6.
  37. Zhao D, Cui D, Wang B *et al.* treatment of early-stage osteonecrosis of the femoral head with autologous implantation of bone marrow-derived and cultured mesenchymal stem cells. *Bone* 2012; **50**:325–30.
  38. Martin JR, Houdek MT, Sierra RJ. Use of concentrated bone marrow aspirate and platelet-rich plasma during minimally invasive decompression of the femoral head in the treatment of osteonecrosis. *Croat Med J* 2013; **54**:219–24.
  39. Houdek MT, Wyles CC, Collins MS *et al.* Stem cells combined with platelet-rich plasma effectively treat corticosteroid-induced osteonecrosis of the hip: a prospective study. *Clin Orthop Relat Res* 2018; **476**:388–97.
  40. Papanagiotou M, Malizos KN, Vlychou M, Dailiana ZH. Autologous (non-vascularised) fibular grafting with recombinant bone morphogenetic protein-7 for the treatment of femoral head osteonecrosis: a preliminary report. *Bone Joint J* 2014; **96-B**: 31–5.
  41. Gato-Calvo L, Magalhaes J, Ruiz-Romero C *et al.* Platelet-rich plasma in osteoarthritis treatment: a review of current evidence. *Ther Adv Chronic Dis* 2019; **10**: 1–18. doi: 10.1177/2040622319825567
  42. Fleisch H. Bisphosphonates: mechanisms of action. *Endocr Rev* 1998; **19**:80–100.
  43. Xie XW, Kang PD, Pei FX. Effect of alendronate and lovastatin in preventing early glucocorticoids-induced osteonecrosis of the femoral head in rats by micro-CT. *Orthopedic J China* 2013; **21**: 82–6.
  44. Fan M, Jiang WX, Wang AY *et al.* Effect and mechanism of zoledronate on prevention of collapse in osteonecrosis of the femoral head. *Zhongguo yi xue ke xue yuan xue bao* 2012; **34**: 330–6.
  45. Aya-ay J, Athavale S, Morgan-Bagley S *et al.* retention, distribution, and effects of intraosseously administered ibandronate in the infarcted femoral head. *J Bone Miner Res* 2006; **22**: 93–100.
  46. Vandermeer JS, Kamiya N, Aya-ay J *et al.* Local administration of ibandronate and bone morphogenetic protein-2 after ischemic osteonecrosis of the immature femoral head: a combined therapy that stimulates bone formation and decreases femoral head deformity. *J Bone Joint Surg Am* 2011; **93**:905–13.
  47. Kim HK, Aruwajoye O, Du J *et al.* Local administration of bone morphogenetic protein-2 and bisphosphonate during non-weight-bearing treatment of ischemic osteonecrosis of the femoral head: an experimental investigation in immature pigs. *J Bone Joint Surg Am* 2014; **96**:1515–24.
  48. Cai J, Wu Z, Huang L *et al.* Cotransplantation of bone marrow mononuclear cells and umbilical cord mesenchymal stem cells in avascular necrosis of the femoral head. *Transplant Proc* 2014; **46**: 151–5.
  49. Chen C, Qu Z, Yin X *et al.* Efficacy of umbilical cord-derived mesenchymal stem cell-based therapy for osteonecrosis of the femoral head: a three-year follow-up study. *Mol Med Rep* 2016; **14**: 4209–15.
  50. Daltro GC, Fortuna V, de Souza ES *et al.* Efficacy of autologous stem cell-based therapy for osteonecrosis of the femoral head in sickle cell disease: a five-year follow-up study. *Stem Cell Res Ther* 2015; **6**:110.
  51. Sun W, Li Z, Gao F *et al.* Recombinant human bone morphogenetic protein-2 in debridement and impacted bone graft for the treatment of femoral head osteonecrosis. *PLoS One* 2014; **9**: e100424.