



Case Report

Osteoid osteoma of the acromion simulating acromioclavicular pain^{☆,☆☆}

Alberto Naoki Miyazaki*, Marcelo Fregoneze, Pedro Doneux Santos, Luciana Andrade da Silva, Guilherme do Val Sella, Douglas Lobato Lopes Neto, Melvis Muchiuti Junior, Sergio Luiz Checchia

Departamento de Ortopedia e Traumatologia, Faculdade de Ciências Médicas da Santa Casa de São Paulo, São Paulo, SP, Brazil

ARTICLE INFO

Article history:

Received 17 March 2013

Accepted 9 April 2013

Keywords:

Osteoid osteoma
Bone neoplasms
Acromion

ABSTRACT

The osteoid osteoma is a benign bone tumour that usually presents with nocturnal pain in young adults, relieved by rest and anti-inflammatories. It can affect any bone; however, their occurrence is rare in the acromion. The authors describe a case of osteoid osteoma located in the acromion, with symptoms that simulated acromion clavicularthrosis. The diagnosis was made by CT scan and treatment was excision of the nidus through arthroscopy. The diagnosis was confirmed by histopathology. In the outpatient segment, the patient remained asymptomatic, with complete recovery of function of the affected limb.

© 2014 Sociedade Brasileira de Ortopedia e Traumatologia. Published by Elsevier Editora Ltda. Este é um artigo Open Access sob a licença de [CC BY-NC-ND](#)

Osteoma osteóide de acrômio que simula dor acrômio-clavicular

RESUMO

O osteoma osteóide é um tumor ósseo benigno que se apresenta geralmente em adultos jovens com dor noturna, aliviada por repouso e anti-inflamatórios. Pode acometer qualquer osso. Entretanto, sua ocorrência no acrômio é rara. Os autores descrevem um caso de osteoma osteóide localizado no acrômio, com sintomas que simulavam artrose acrômio-clavicular. O diagnóstico foi feito por meio de tomografia computadorizada e o tratamento proposto foi a exérese do nidus por meio de artroscopia. O diagnóstico definitivo foi confirmado por exame histopatológico. No segmento ambulatorial, a paciente permaneceu assintomática e com recuperação completa da função do membro acometido.

© 2014 Sociedade Brasileira de Ortopedia e Traumatologia. Publicado por Elsevier Editora Ltda. Este é um artigo Open Access sob a licença de [CC BY-NC-ND](#)

Palavras-chave:

Osteoma osteóide
Neoplasias ósseas
Acrômio

* Please cite this article as: Miyazaki AN, Fregoneze M, Santos PD, da Silva LA, do Val Sella G, Neto DLL, Muchiuti Junior M, Checchia SL. Osteoma osteóide de acrômio que simula dor acrômio-clavicular. Rev Bras Ortop. 2014;49:82-85.

** Work conducted at Shoulder and Elbow Group, Department of Orthopaedics and Traumatology, Medical Sciences School, Santa Casa de São Paulo, São Paulo, SP, Brazil.

* Corresponding author.

E-mail: ombro@ombro.med.br (A.N. Miyazaki).

Introduction

Osteoid osteoma is a benign osteoblastic lesion, and constitutes approximately 11% of all benign bone tumours that usually occur in young men. This neoplasm is found in the second or third decade of life. However, it can be seen in other age groups.¹ Any bone can be involved. However, there is a predilection for lower extremities: half of the cases involve the femur or tibia.² The scapula is a bone rarely affected and few cases have been reported in the literature. Mosheiff et al.,³ in a review of the literature, reported the involvement of 12 scapulae in 1236 cases of osteoid osteoma.

Case report

A female patient, aged 46 years, right-handed, complained of right shoulder pain for three months, especially at night, with worsening during physical activities, and improved with the use of NSAIDs. She denied any history of trauma or previous disease in the joint. She has been diagnosed previously as having impingement syndrome and treated with two sub-acromial corticosteroid injections and physical therapy, with partial improvement of symptoms.

On physical examination, her shoulders had no deformities, tumours or skin lesions, and muscle tropism was preserved. The range of active movement of the affected limb was slightly limited by pain and the passive movement was normal. Provocative manoeuvres for acromioclavicular joint (O'Brien, forced adduction and pain on palpation) were strongly positive and the other tests to evaluate the rotator cuff and instability of the shoulder joint resulted negative.

The Zanca view radiographs revealed changes in the acromioclavicular joint (Fig. 1). A magnetic resonance imaging study showed an acromioclavicular arthrosis with intense inflammatory process in the joint region with a cyst on the acromion, initially interpreted as a geode. However, our attention was drawn by the fact that there was an intense inflammatory process around the lesion, which was very regular and larger than usual; in addition, the images

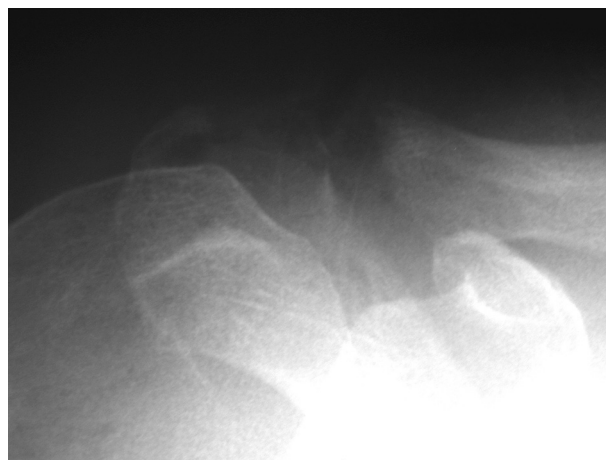


Fig. 1 – Radiograph of the right shoulder, Zanca view, showing arthrosis of acromioclavicular joint.

suggested the existence of some solid content inside it (Fig. 2A and B).

The diagnosis hypothesis of osteoid osteoma was proposed and then we requested a CT scan for confirmation; the nidus inside the cyst could be easily evidenced (Fig. 3).

All the complementary laboratory tests were normal.

We chose arthroscopic surgery and resection of the nidus (Fig. 4), complemented with a broader than usual acromioplasty, until the removal of the entire tumour, and resection of the distal end of the clavicle (Mumford procedure) was taken (Fig. 5). The diagnosis was confirmed by pathological study.

The patient had rapid regression of symptoms, with complete recovery of the functional range of motion of the affected limb, and remained asymptomatic until her last return, by occasion of the postoperative examination of seven years.

Discussion

The scapula is a rare site of osteoid osteoma location and, therefore, is often failed to be included in the differential

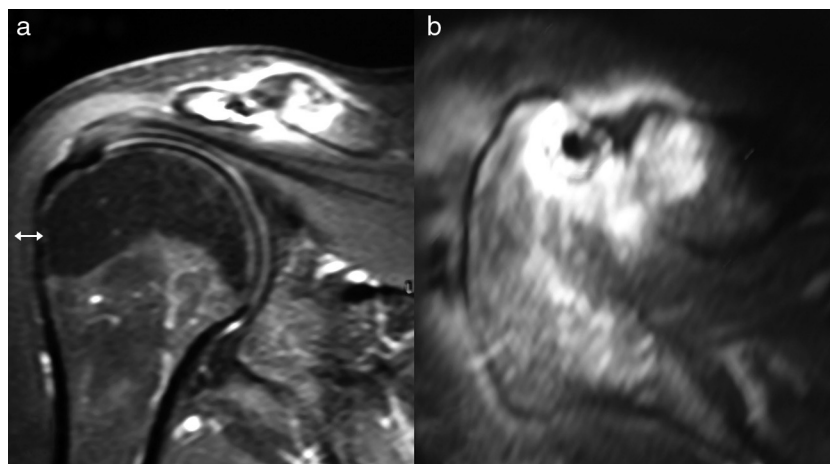


Fig. 2 – Magnetic resonance images of the right shoulder, coronal (a) and axial (b) section, showing acromioclavicular arthrosis with severe swelling in the joint and a cyst (nidus) into the acromion, next to the joint.

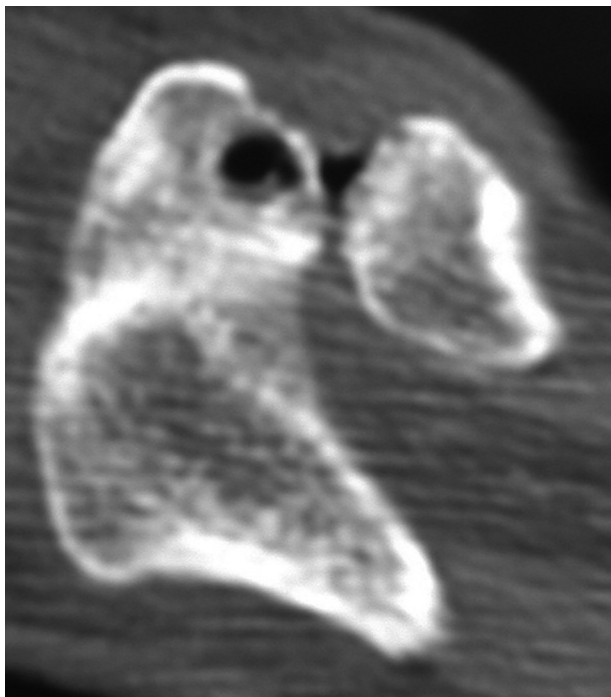


Fig. 3 – Axial CT image of the right shoulder showing osteoid osteoma in the acromion, next to the acromioclavicular joint.

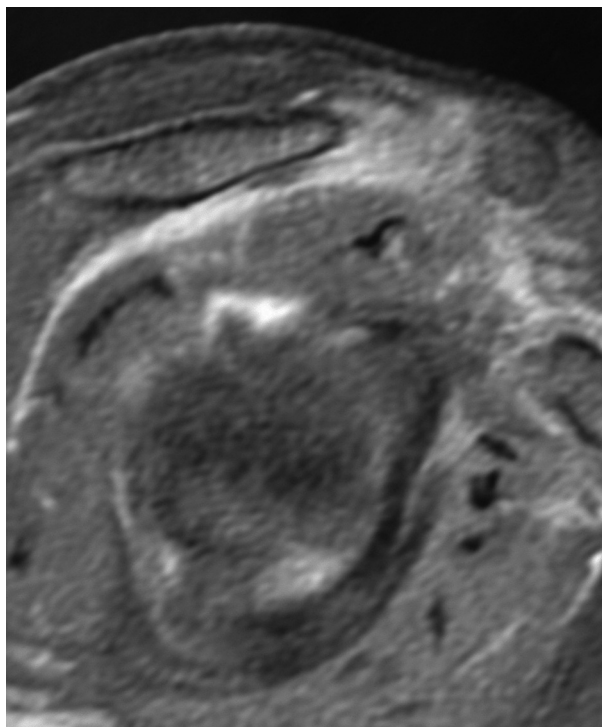


Fig. 5 – Magnetic resonance imaging, right shoulder, sagittal view, showing complete resection of the lesion (acromioplasty) and resection of the lateral end of the clavicle.

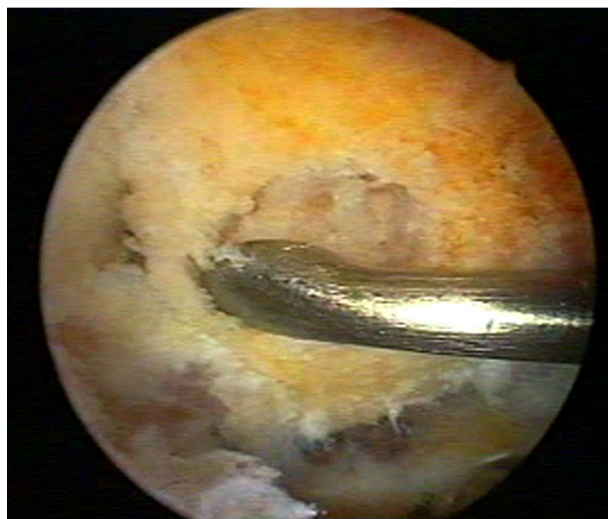


Fig. 4 – Surgical arthroscopic image, subacromial view, showing the resection of the tumour with a curette.

diagnosis of chronic shoulder pain.⁴ The patient with an osteoid osteoma is characterized by pain that occurs predominantly at night and is relieved by aspirin or anti-inflammatory drugs.⁵ Often the nocturnal pain is attributed to rotator cuff disease. However, the age range of patients with osteoid osteoma would imply in lower probability of a rotator cuff disease.

Multiple treatment options for this tumour are available: drug therapy, percutaneous ablation by radiofrequency and

surgical procedures involving the complete removal of the nidus, which can be achieved by curettage, en bloc resection and, more recently, by arthroscopic route, with good results.^{6,7} If the patient's symptoms are adequately controlled, anti-inflammatory medication can be used as a final treatment. Patients treated in this manner usually experience spontaneous healing of the lesion in three to four years.⁸

Degreef et al.⁷ first described the occurrence of an osteoid osteoma in the acromion in a female patient aged 56, whose treatment was open resection of the lesion. Kelly et al.⁶ described a case of arthroscopic resection of an osteoid osteoma located at the anterior border of the glenoid of a male patient aged 30 years, who had undergone two surgeries for treatment of a SLAP lesion. The authors also reported an arthroscopic resection of an osteoid osteoma located at the base of the coracoid process of a male patient aged 12 years.

Our choice was the arthroscopic treatment, as in the cases described above, because the patient's was a benign lesion and we had a possibility to resect the entire lesion with minimal tissue damage. This option proved to be effective, and can be applied in similar cases.

Conflicts of interest

The authors declare no conflicts of interest.

REFERENCES

1. Lee BG, Cho NS, Rhee YG. Unusual shoulder synovitis secondary to an osteoid osteoma without a nidus in the coracoid process: delayed appearance of a nidus. *J Orthop Sci.* 2010;15(6):825-8.
2. Mitsui Y, Gotoh M, Yoshida T, Hirai Y, Shinozaki T, Nakama K, et al. Osteoid osteoma of the proximal humerus: a misleading case. *J Shoulder Elbow Surg.* 2008;17(1):e13-5.
3. Mosheiff R, Liebergall M, Ziv I, Amir G, Segal D. Osteoid osteoma of the scapula. A case report and review of the literature. *Clin Orthop Relat Res.* 1991;262:129-31.
4. Glanzmann MC, Hinterwimmer S, Woertler K, Imhoff AB. Osteoid osteoma of the coracoid masked as localized capsulitis of the shoulder. *J Shoulder Elbow Surg.* 2011;20(8):e4-7.
5. Gracia IA, Itarte JI, Majo JB, Salo GB, Proubasta IR. Osteoid osteoma of the coracoid process. *J Southern Orthop Assoc.* 2001;10(1):49-52.
6. Kelly AM, Selby RM, Lumsden E, O'Brien SJ, Drakos MC. Arthroscopic removal of an osteoid osteoma of the shoulder. *Arthroscopy.* 2002;18(7):801-6.
7. Degreef I, Verduyck J, Debeer P, De Smet L. An unusual cause of shoulder pain: osteoid osteoma of the acromion – a case report. *J Shoulder Elbow Surg.* 2005;14(6):643-4.
8. Heck Jr RK. Bone-forming tumors. In: Canale T, Beaty JH, editors. *Campbell's operative orthopaedics.* 11th ed. Philadelphia: Saunders Elsevier; 2007. p. 855-7.