

Case Report

Microvascular decompression of the posterior inferior cerebellar artery for intermediate nerve neuralgia

Humberto Kluge Schroeder, Iuri Santana Neville, Daniel Ciampi de Andrade, Guilherme Alves Lepski, Manoel Jacobsen Teixeira, Kleber Paiva Duarte

Division of Functional Neurosurgery, Department of Neurology, Hospital das Clinicas, University of São Paulo Medical School, São Paulo, Brazil

E-mail: Humberto Kluge Schroeder - humbertoks@gmail.com; *Iuri Santana Neville - iurineville@yahoo.com.br; Daniel Ciampi de Andrade - ciampi@usp.br; Guilherme Alves Lepski - lepski@usp.br; Manoel Jacobsen Teixeira - manoeljacobsen@gmail.com; Kleber Paiva Duarte - kleberduarte@uol.com.br

*Corresponding author

Received: 30 June 14 Accepted: 14 January 15 Published: 01 April 15

This article may be cited as:

Schroeder HK, Neville IS, de Andrade DC, Lepski GA, Teixeira MJ, Duarte KP. Microvascular decompression of the posterior inferior cerebellar artery for intermediate nerve neuralgia. *Surg Neurol Int* 2015;6:52.

Available FREE in open access from: <http://www.surgicalneurologyint.com/text.asp?2015/6/1/52/154452>

Copyright © 2015 Schroeder HK. This is an open-access article distributed under the terms of the Creative Commons Attribution License, which permits unrestricted use, distribution, and reproduction in any medium, provided the original author and source are credited.

Abstract

Background: Intermediate nerve neuralgia (INN) is an extremely rare craniofacial pain disorder mainly caused by neurovascular compression.

Case Description: We present the case of a 48-year-old female with a 20-month history of intractable paroxysmal INN on the right side. The patient described feeling paroxysmal pain in her auditory canal, pinna, deep in the jaw, and adjacent retromastoid area on the right side. She described the pain as being like a burning sensation. Magnetic resonance imaging showed the right posterior cerebellar artery crossing the cerebellopontine cistern in close contact with the right VII and VIII nerves. Surgical exploration via retromastoid craniotomy revealed vascular compression of the intermediate nerve by the posterior cerebellar artery. We therefore performed microvascular nerve decompression to relieve pain, and the patient remained pain-free at the 6-month follow-up visit.

Conclusion: INN should be considered as a differential diagnosis in cases with atypical facial neuralgia, and microvascular decompression is an effective treatment option that can provide optimal pain relief.

Key Words: Cranial neuralgia, intermediate nerve neuralgia, microvascular decompression surgery, neuropathic pain, neuralgia, posterior inferior cerebellar artery, paroxysmal nerve pain

Access this article online**Website:**

www.surgicalneurologyint.com

DOI:

10.4103/2152-7806.154452

Quick Response Code:

INTRODUCTION

Intermediate nerve neuralgia (INN) is an extremely rare craniofacial pain disorder, which tends to affect middle-aged patients and can be a debilitating pathology due to its refractoriness to medical treatment and its negative impact on quality of life. INN always manifests unilaterally and is characterized by severe paroxysms of stabbing electric shock-like and lancinating pain felt deep in the auditory canal, the external structures of the ear,

the palate, tongue, or deeply in the facial musculature. The pain is usually intermittent and may last seconds to minutes.^[2,8,12] Rarely, the anterior two-thirds of the tongue and soft palate are also involved as triggers and/or sites of pain because of the afferent fibers of the facial nerve from these areas. The presence of triggering factors is typical. The trigger may be swallowing, talking, or stimulation of the ear canal. Pain crises usually last from seconds to a few minutes and can be associated with tearing, salivation, bitter taste, tinnitus, or vertigo on the

side of pain.^[8] INN is similar to trigeminal neuralgia in every way except for its location, which is deep within the ear.^[12,20]

There are several theories aimed at explaining the cause of this and other cranial neuralgias. Often, the nerve can be compressed by a nearby blood vessel, and this condition is called nerve–vessel conflict or neurovascular conflict.^[8] Magnetic resonance imaging (MRI) with MRI angiography can aid the diagnosis.

Pharmacotherapy is the first line of treatment for INN as well as other cranial neuralgias. However, medications are not always fully effective, and their effectiveness may even decrease over time, with long-term use causing resistance. Furthermore, some of these medications may cause disabling side effects. In patients who do not respond favorably to pharmacotherapy or who have nerve–vessel conflicts, surgical treatment may be necessary.^[8]

Since the first case report of INN by Clark and Taylor^[5] in 1909, several papers have addressed aspects related to its diagnosis and treatment. Most of the cases were treated with sectioning the neural structures, which generally lead to neurological side effects such as decreased salivation, lacrimation, and taste.^[10,15] However, there is very little experience of a patient successfully treated with microvascular decompression (MVD) alone.^[4,15-17,20]

Here we report an unusual case of compression of the nervus intermedius by the posterior inferior cerebellar artery (PICA). The patient experienced immediate pain relief after MVD.

CASE REPORT

The patient was a 48-year-old female with a 20-month history of right-sided orofacial pain. Her main complaint was paroxysmal pain in her auditory canal, pinna, deep in the jaw, and adjacent retromastoid area on the right side. The pain was described as a burning sensation in an area located in the posterior external auditory canal wall and was elicited by chewing, touch, or contact with objects or warm water. It usually lasted for a few seconds to 1–2 min and would remit spontaneously and abruptly. The patient ranked it 10 on the numeric rating scale. She had no odynophagia and was treated with carbamazepine (maximum 1200 mg/day), which proved to be ineffective. Other medications (Sertraline, Amitriptyline, and Pregabalin) also failed to provide clinically significant pain relief. The patient's otoscopic examination was unremarkable bilaterally. There was no sensory loss, facial palsy, or other neurological signs.

The patient underwent preoperative MRI and MRI angiography, including 3D T2-weighted fast

spin echo and 3D constructive interference in the steady-state (CISS) sequences. Images showed the right posterior cerebellar artery crossing the cerebello-pontine cistern [arrow in Figure 1] in close contact with the right VII and VIII nerves [arrow in Figure 2], near the internal auditory canal.

A right-sided suboccipital retrosigmoid craniotomy was performed. The patient was put in a left lateral decubitus position, with the head well rotated and fixed in a Mayfield clamp. The dura was opened. Minimal retraction of the cerebellum was performed to achieve cerebrospinal fluid (CSF) drainage. In the cerebello-pontine angle, as shown in Figure 3, the loop [arrow-head in Figure 3] of the PICA was visualized, as well as the close contact between the vascular structure and the VII-VIII nerves complex [* in Figure 3]. Additional exploration did not reveal other areas of neurovascular conflict at the roots of the trigeminal nerve or the lower cranial nerves. The artery's arachnoid attachment was dissected, the artery mobilized, and a small Teflon felt was placed to separate the artery from the nerve. Sectioning of the intermediate nerve or excision of the geniculate ganglion (GG) was not necessary.

Following the decompression, the patient had an uneventful postoperative recovery and the pain resolved immediately with no additional neurological deficits, demonstrating that the compression was the only cause of pain. Postoperative CT scans were unremarkable. Medication was tapered off in the first few weeks after surgery. At 6-months' follow-up, no further paroxysmal pain had occurred.

DISCUSSION

The nervus intermedius, also known as the intermediary nerve, intermediate nerve or Wrisberg's nerve, was first identified in 1563, but was described in great detail

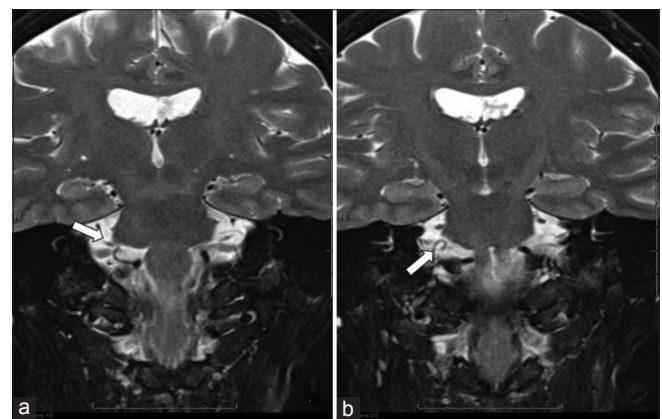


Figure 1: (a and b) T2-weighted Brain MRI (coronal plane). T2 Coronal MRI thin-section 3D CISS images showing the right PICA crossing the cerebello-pontine cistern in close contact with the right VII and VIII nerves. The arrow indicates the PICA loop

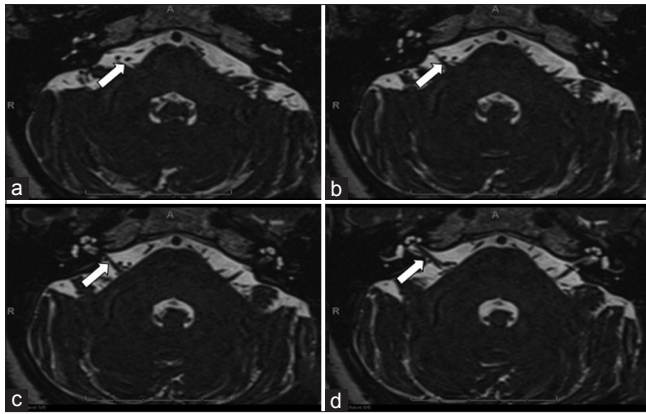


Figure 2: (a-c) Axial MRI thin-section 3D CISS images: the right PICA makes a loop in the cerebello-pontine cistern.(d) Close contact of the PICA and VII nerve. The arrow indicates the close contact between the vessel and the VII-VIII nerve complex

and named by Heinrich August Wrisberg in 1777 as “*portio media inter comunicantem faciei et nervum auditorium.*”^[1,18] It is the sensory branch of the facial nerve that innervates the external auditory meatus, pinna of the ear, and some of the skin below the ear lobe.^[8] In 1857, John Nottingham introduced the term “tic douloureux of the ear” to describe sudden paroxysms of ear pain accompanied by flushing of the auricle. In 1909, Orbison observed a case of herpes zoster of the tympanic membrane with ear pain, tinnitus, and deafness, without facial nerve paralysis. Finally, systematic work carried out by James Ramsay Hunt from 1907 to 1937 described the involvement of the nervus intermedius in tic douloureux of the ear.^[1]

In 2004, the International Headache Society (IHS) classification set out obligatory requirements for the diagnosis of intermedius neuralgia: The presence of paroxysmal pain with a trigger area in the posterior external auditory canal wall. In fact, the clinical diagnosis is based on pain description and classified as nervus intermedius neuralgia.^[7]

Rhoton *et al.* classified the course of the nervus intermedius into three segments. The medial segment adheres closely to the vestibule-cochlear nerve, whereas the intermediate segment runs separately between the VII and VIII cranial nerves. Finally, the lateral segment joins the motor root of the facial nerve within the internal acoustic meatus.^[14]

There are various types of chronic pain that can affect the ear canal, and the term geniculate neuralgia (GN), or Hunt’s neuralgia, has been used extensively to describe them. The nomenclature in the literature is often confusing. GN can follow viral herpes zoster infection at the GG,^[3] and this entity is also known as Ramsay Hunt syndrome, in which in addition to the already described neuralgia, the patient has characteristic vesicles of herpes infection located in the

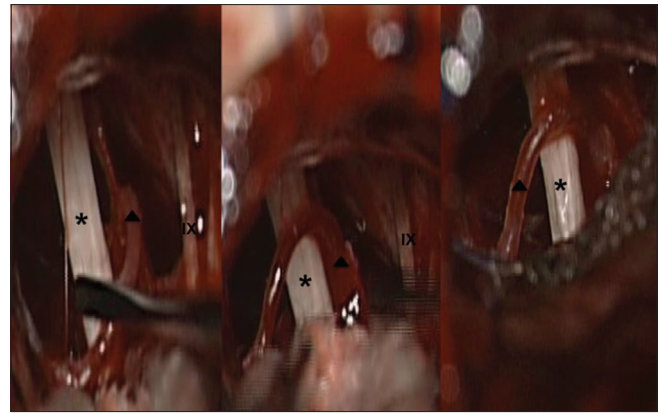


Figure 3: Intraoperative views during microvascular decompression. We observed close contact between vascular structures and the facial nerve, which could explain the irritative symptoms presented by the patient. *VII-VIII nerve complex; arrow-head – loop of PICA; IX – glossopharyngeal nerve

external auditory canal.^[6] INN, in our opinion, is a variant of GN, a form of neurovascular conflict.^[17]

MRI with MRI angiography can help with diagnosis, as it can help identify the causal mechanism of the pain (due to vascular compression of the intermediate nerve) and thus distinguish INN from other pain syndromes that are designated as GN.^[17]

Much has been studied about the current etiology of INN and other cranial neuralgias, but its physiopathology is still poorly understood. Neurovascular compression is INN’s main etiology. In this form of neurovascular conflict, the cranial nerve can be compressed by an aberrant loop of artery or vein that is in close proximity to the nerve.^[8,9] This conflict can only take place in a precise and fragile area of the nerve called the root entry zone (REZ), or transition zone, which is the transition zone between central myelin (oligodendroglia) and peripheral myelin (Schwann cells). Repeated microtraumas linked to vascular pulsation may induce a focal demyelination zone with aberrant remyelination and the creation of neoreceptors, which can generate ectopic discharges and ephaptic transmission between axons. It has been suggested that damaged neurons may heal with alterations to the myelin, leading to extra sodium channels in the axonal cell membranes.

The close anatomical connection between the anterior inferior cerebellar artery (AICA) and the facial and acoustic nerve complex at its emergence from the brainstem has been confirmed by several clinical reports.^[2] Neurovascular proximity may be present at birth, but it may not become clinically evident until the development of atherosclerosis and ectatic distortion of vascular loops that compress the adjacent nerves.^[9] Vascular compression of the nervus intermedius by a vascular loop – usually a

loop of the AICA – a dolichoectatic artery, an aneurysm or persistent primitive artery is recognized cause in patients with GN.^[12] In a case described by Sakas *et al.*, an AICA loop compressing the intermediate nerve in the VII/VIII cranial nerve complex inside the internal auditory canal was the exclusive cause of paroxysmal otalgia, and the pain resolved completely after MVD.^[17] However, an unusual and redundant loop of the superior cerebellar artery (SUCA) or PICA may also cause nervus intermedius neuralgia. The vascular compression of the VII nerve causes hemifacial spasm – a paroxysmal, involuntary, synchronous contraction of the muscles innervated by the facial nerve – but our patient did not have this condition.

Drugs may relieve symptoms in many patients, especially in the early stages. Over time, however, drugs may lose their efficacy.^[20] Surgical treatment may be necessary for patients for whom pharmacotherapy is unsuccessful and for patients who have nerve–vessel conflicts.^[8] In case reports and small series, long-term pain control has been observed after nerve sectioning or MVD, but no prospective studies on these methods exist.^[11,18] The choice of surgical treatment was apparently based on the surgeon's personal experience and interpretation of the intraoperative findings, rather than on a firm preoperative diagnosis.^[17] Because combined techniques were used rather arbitrarily, it is difficult to compare outcomes in and between studies.^[20]

Sectioning of the nervus intermedius has been used quite extensively. While MVD alone has been demonstrated to be effective in anecdotal reports of good to excellent pain relief, experience with MVD is quite limited.^[20] In 2002, Pulec proposed that part of the facial nerve along with the intermediate nerve and the GG should be excised to offer an effective treatment for intractable INN.^[13] In 2007, Lovely and Jannetta performed excision of the nervus intermedius and GG on 10 patients and reported 'excellent' pain relief in 72% and partial pain relief in 21% of patients at the 1-year follow-up.^[10]

INN should be distinguished from the numerous other ear and facial pain syndromes that make up the broader clinical entity of GN. This distinction can guide surgical decision-making toward selective MVD of the intermediate nerve, and thus prevent the untoward effects of ablative and resective procedures on other cranial nerves.^[17] Resection of the nervus intermedius is often associated with neurological side effects such as decreased salivation, lacrimation, and taste.^[20]

Because the compressed nervus intermedius can be cured with MVD, we believe INN should be included among the cranial nerve syndromes caused by vascular compression at the REZ of the nerves.^[2] MRI imaging sequences are crucial for confirming the anatomical relationship between a vessel and a nerve.^[17] In our case, the diagnosis of INN due to vascular compression of the intermediate nerve was well established. MVD for INN can be a great treatment option that has low comorbidity, when performed in specialized centers. However, one must advise patients that neurological deficits such as transient facial nerve palsy or partial hearing loss may result from this surgery, as is the case for other CPA surgeries.

Table 1 summarizes all the case reports of patients with INN treated by MVD. Most of them are case reports and some are small case series, which may have included patients treated with MVD and neurectomy. Despite sectioning of the intermediate nerve, which has been used in several instances, the experience with MVD without sectioning neural structures is very limited.^[4,10,15-17,20] We believe that this case report will contribute to the literature regarding the syndrome description and reinforcing this successful and specific management.

In conclusion, INN should be considered as a differential diagnosis in cases with atypical facial neuralgia, and MVD is an effective treatment option that can provide optimal pain relief.

Table 1: Case reports of patients with INN treated by MVD

Author	Year	Patients' characteristics	Intraoperative findings/other comments
Yeh <i>et al.</i> ^[19]	1984	Symptoms of otalgia and intractable unilateral facial spasm	A dolicho-ectatic AICA compressed the VII and VIII nerves
Rupa <i>et al.</i> ^[15]	1991	9 patients	In some cases, neural structures were <i>sectioned</i> . Vascular loops from AICA, PICA, or SUCA
Lovely and Janetta ^[10]	1997	14 patients	MVD of cranial nerves V, IX, and X with <i>section</i> of the intermediate nerve in most cases
Sakas <i>et al.</i> ^[17]	2007	52 years, female	Loop from AICA
Younes <i>et al.</i> ^[20]	2010	63 years, female, intractable paroxysmal 'atypical' otofacial pain	Vascular compression of the nerve by a vascular loop of the AICA
Saers <i>et al.</i> ^[16]	2011	24 years, female	Found several blood vessels together with thin strings of arachnoidal connective tissue layered over the nerve
Chen <i>et al.</i> ^[4]	2014	55 years, female, with hemifacial spasm and otalgia	Loop from AICA

AICA: Anterior inferior cerebellar artery, PICA: Posterior inferior cerebellar artery, SUCA: Superior cerebellar artery, MVD: Microvascular decompression

REFERENCES

1. Alfieri A, Strauss C, Prell J, Peschke E. History of the nervus intermedius of Wrisberg. *Ann Anat* 2010;192:139-44.
2. Bellotti C, Medina M, Oliveri G, Ettorre F, Barrale S, Sturiale C, et al. Neuralgia of the intermediate nerve combined with trigeminal neuralgia: Case report. *Acta Neurochir (Wien)* 1988;91:142-3.
3. Chavin JM. Cranial neuralgias and headaches associated with cranial vascular disorders. *Otolaryngol Clin North Am* 2003;36:1079-93, vi.
4. Chen Y, Song Z, Wan Y, Lin W, Hu X, Wang Y, et al. Intermediate nerve neuralgia can be diagnosed and cured by microvascular decompression. *J Craniofac Surg* 2014;25:1187-9.
5. Clark LP, Taylor AS. True tic douloureux of the sensory filaments of the facial nerve. I. Clinical report of a case in which cure was effected by physiological extirpation of the geniculate ganglion. II. Report of surgical treatment. *JAMA* 1909;LIII:2144-6. doi:10.1001/jama.1909.92550260001001a.
6. Guinto G, Guinto Y. Nervus intermedius. *World Neurosurg* 2013;79:653-4.
7. Headache Classification Subcommittee of the International Headache Society. The International Classification of Headache Disorders: 2nd edition. *Cephalalgia* 2004;24 Suppl 1:9-160.
8. Hupp WS, Firriolo FJ. Cranial neuralgias. *Dent Clin North Am* 2013;57:481-95.
9. Jannetta PJ. Neurovascular compression in cranial nerves and systemic disease. *Ann Surg* 1980;192:510-24.
10. Lovely T, Jannetta P. Surgical management of geniculate neuralgia. *Am J Otol* 1997;18:512-7.
11. Nanda A, Khan IS. Nervus intermedius and geniculate neuralgia. *World Neurosurg* 2013;79:651-2.
12. Özer FD, Duransoy YK, Camlar M. Atypic geniculate neuralgia: Atypic anatomic correlation of cranial nerve roots and AICA. *Acta Neurochir (Wien)* 2009;151:1003-4.
13. Pulec JL. Geniculate neuralgia: Long-term results of surgical treatment. *Ear Nose Throat J* 2002;81:30-3.
14. Rhoton AL Jr, Kobayashi S, Hollinshead WH. Nervus intermedius. *J Neurosurg* 1968;29:609-18.
15. Rupa V, Saunders RL, Weider DJ. Geniculate neuralgia: The surgical management of primary otalgia. *J Neurosurg* 1991;75:505-11.
16. Saers SJ, Han KS, de Ru JA. Microvascular decompression may be an effective treatment for nervus intermedius neuralgia. *J Laryngol Otol* 2011;125:520-2.
17. Sakas DE, Panourias IG, Stranjalis G, Stefanatou MP, Maratheftis N, Bontozoglou N. Paroxysmal otalgia due to compression of the intermediate nerve: A distinct syndrome of neurovascular conflict confirmed by neuroimaging. Case report. *J Neurosurg* 2007;107:1228-30.
18. Tubbs RS, Steck DT, Mortazavi MM, Cohen-Gadol AA. The nervus intermedius: A review of its anatomy, function, pathology, and role in neurosurgery. *World Neurosurg* 2013;79:763-7.
19. Yeh HS, Tew JM Jr. Tic convulsif, the combination of geniculate neuralgia and hemifacial spasm relieved by vascular decompression. *Neurology* 1984;34:682-3.
20. Younes WM, Capelle HH, Krauss JK. Microvascular decompression of the anterior inferior cerebellar artery for intermediate nerve neuralgia. *Stereotact Funct Neurosurg* 2010;88:193-5.