

Anesthetic Management of a Patient With an Anterior Mediastinal Mass Undergoing Endoscopic Retrograde Cholangiopancreatography in the Prone Position: A Case Report

Alfredo Armas, MD, and Aaron N. Primm, MD

Patients with anterior mediastinal masses pose a significant challenge to anesthesiologists. Catastrophic outcomes have been described in patients with mediastinal masses undergoing anesthesia. However, despite an abundance of literature discussing anesthetic management of these patients, there is a lack of reports detailing the management of this population undergoing advanced endoscopic procedures under sedation. We report on a 28-year-old man with a large anterior mediastinal mass who underwent endoscopic retrograde cholangiopancreatography in the prone position under moderate to deep sedation without complication. (A&A Practice. 2020;14:25–7.)

GLOSSARY

AMM = anterior mediastinal mass; **CT** = computed tomography; **ERCP** = endoscopic retrograde cholangiopancreatography; **GETA** = general endotracheal anesthesia; **GI** = gastrointestinal; **MRCP** = magnetic resonance cholangiopancreatography; **PFTs** = pulmonary function tests; **SVC** = superior vena cava

Anterior mediastinal masses (AMMs) present a significant threat to patients. These masses may compress vital structures in the patient's thorax and can lead to signs and symptoms that range from cough, dyspnea on exertion, pain, orthopnea, venous congestion and syncope to respiratory failure, hemodynamic collapse, and death.^{1,3} General anesthesia increases the risk of these complications and should be avoided when possible.^{2,4} As a result, when presented with a patient requiring anesthesia for endoscopic retrograde cholangiopancreatography (ERCP) due to biliary obstruction, it is prudent to avoid general anesthesia, maintain spontaneous ventilation, and avoid positioning that increases risk of complications. We report a 28-year-old man with a large AMM who underwent prone ERCP under moderate to deep sedation. Written consent was obtained from the patient to write this case report.

CASE DESCRIPTION

A 28-year-old man without significant medical history presented to the emergency department with epigastric pain.

A few weeks before presentation, the pain had become constant, radiating to the chest and shoulders and was associated with nausea, anorexia, 20-pound weight loss, and orthopnea. Initial laboratory results revealed a lipase of 691 U/L and an alanine aminotransferase of 82 U/L; remaining laboratory studies were unremarkable. The working diagnosis was acute pancreatitis.

An ultrasound showed an enlarged pancreas with multiple ill-defined hypoechoic nodules, probable retroperitoneal lymphadenopathy, and a 5.0 cm right adrenal nodule. Subsequent magnetic resonance cholangiopancreatography (MRCP) confirmed the ultrasound findings, but also revealed pancreatic ductal narrowing, mild dilation of the common bile duct and intrahepatic biliary tree, bilateral renal masses, and a partially visualized AMM (>11 cm). These findings prompted a computed tomography (CT) of the chest, which demonstrated a 14.1 × 6.4 × 14.6 cm infiltrative anterior mediastinal soft tissue mass (Figure 1) with encasement of the ascending aorta, aortic arch, isthmus and arch vessels, as well as encasement and narrowing of the pulmonary trunk (1.4 cm in diameter) and bilateral main pulmonary arteries. The superior vena cava (SVC) was diffusely encased, and markedly narrowed distally, measuring 4 mm in the anteroposterior diameter. The left main bronchus was compressed to 5.7 mm (Figure 2). Of note, there was no pericardial effusion and no tracheal compression. Transthoracic echocardiogram revealed paradoxical septal motion, left ventricular ejection fraction of 70%, elevated right atrial pressure of 11–20 mm Hg, and compression of the right ventricular outflow tract and main pulmonary artery.

Over the next 48 hours, the patient developed worsening transaminitis, bilirubinemia, and right upper quadrant pain. A subsequent local biopsy confirmed a diagnosis of diffuse large B-cell lymphoma. The consulting oncology team stated that they could not begin chemotherapy in this

From the Department of Anesthesiology, Perioperative Care, and Pain Medicine, NYU Langone Medical Center, New York, New York.

Accepted for publication October 17, 2019.

Funding: None.

The authors declare no conflicts of interest.

Address correspondence to Aaron N. Primm, MD, Department of Anesthesiology, Perioperative Care, and Pain Medicine, NYU Langone Medical Center, 550 First Ave, New York, NY 10016. Address e-mail to aaron.primm@nyulangone.org.

Copyright © 2019 International Anesthesia Research Society. This is an open-access article distributed under the terms of the Creative Commons Attribution-Non Commercial-No Derivatives License 4.0 (CCBY-NC-ND), where it is permissible to download and share the work provided it is properly cited. The work cannot be changed in any way or used commercially without permission from the journal.

DOI: 10.1213/XAA.0000000000001142

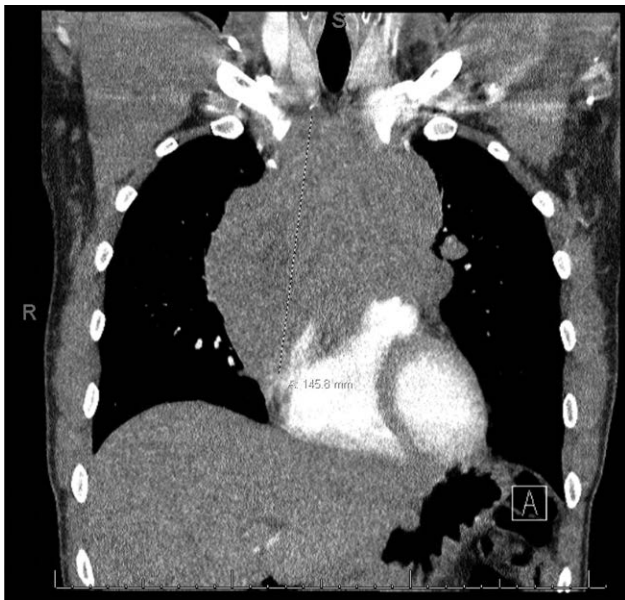


Figure 1. Computed tomography of the chest with intravenous contrast in the coronal plane with largest dimension (14.6 cm) of the mass delineated.

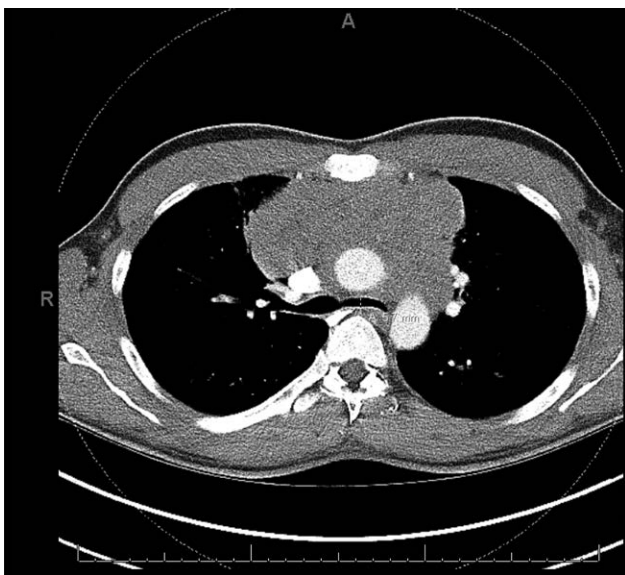


Figure 2. Computed tomography of the chest with intravenous contrast in the axial plane demonstrating narrowing of the left main bronchus to 5.7 mm.

patient with an active biliary obstruction. As a result, he was scheduled for ERCP with possible biliary stenting to relieve the obstruction.

The patient was evaluated by the anesthesiologist in the medical intensive care unit. He reported orthopnea after lying supine for 10 minutes during the MRCP but denied any discomfort in the prone position. Physical examination demonstrated abdominal tenderness, but no signs of SVC syndrome or discomfort in the prone position. Airway examination demonstrated a beard and a Mallampati score of 1. The patient was scheduled for ERCP and transferred to the inpatient endoscopy suite. A right-hand 20-gauge peripheral intravenous line was in situ, and an additional

18-gauge peripheral intravenous line was placed in the right antecubital vein. Standard monitors were applied, and a preinduction radial arterial line was placed. Supplemental oxygen was provided via nasal cannula at 4L/min with positive end-tidal carbon dioxide monitoring. Initial vital signs were notable for sinus tachycardia of 107 beats per minute. The oropharynx was topicalized with 10mL of atomized 2% lidocaine, as well as viscous 2% lidocaine to the bilateral tonsillar pillars. A 100-mm oral airway was passed and removed to confirm adequate topicalization.

The patient was placed in the prone position, where he reported feeling comfortable, breathing spontaneously with lactated Ringer's infusing. A loading bolus of 37 µg of dexmedetomidine was injected, followed by an infusion at 0.5 µg/kg/h. The ERCP scope passed without difficulty. He maintained spontaneous ventilation, and was given intermittent ketamine boluses (20–30 mg at a time for a total of 70 mg) throughout the procedure to maintain comfort. A sphincterotomy, followed by placement of a 9-cm common bile duct stent into an intrapancreatic stricture, was performed without incident. He emerged in the endoscopy suite and was transported to recovery in stable condition.

The patient was discharged 3 days after the ERCP and has since completed 5 cycles of chemotherapy with significant improvement in symptoms. His most recent study showed a significant decrease in the size of the AMM to 5.1 × 1.1 cm, as well as complete resolution of pulmonary, pancreatic, renal, and adrenal masses.

DISCUSSION

Patients with AMMs present a challenge to anesthesiologists, who are often consulted to make clinical care, diagnostic procedures, and definitive treatments possible. The mediastinum is divided into 3 clinically relevant portions. The anterior mediastinum is bordered anteriorly by the sternum, posteriorly by the middle mediastinum (heart and great vessels), superiorly by the thoracic inlet, and inferiorly by the diaphragm.⁵ The etiology of AMMs varies, but most commonly includes lymphoma, thymoma, germ cell tumors, metastatic lesions, bronchogenic masses, and thyroid anomalies.⁵ Due to the invasive nature of many of these tumors, as well as the proximity to numerous vital structures (great vessels, heart, esophagus, airways), the risk of cardiopulmonary collapse is significant. Life-threatening anesthetic complication rates of up to 20% have been described in the literature.¹

There are several parameters used to risk stratify this patient population. In particular, presenting with cardiopulmonary signs and symptoms, pericardial effusion, tracheal narrowing >50%, and mixed restrictive/obstructive patterns on pulmonary function tests (PFTs) confer an increased risk.¹ PFTs were not obtained before administration of the anesthetic. In fact, there is conflicting evidence regarding the utility of PFTs when risk stratifying patients with AMMs who are to undergo anesthesia.^{1,6} The patient described did not have tracheal stenosis or pericardial effusion. He did, however, report cardiorespiratory signs and symptoms on presentation (dyspnea on exertion and orthopnea). In addition, his echocardiogram demonstrated right ventricular outflow tract obstruction (a common finding in AMMs),⁵ and a CT scan showed a narrowing

of the SVC and left main bronchus. Using a combination of dexmedetomidine, ketamine, and topical pharyngeal anesthesia, this vulnerable patient with an AMM was able to be safely anesthetized. These agents were selected to avoid respiratory depression and airway compromise, yet maintain an adequate level of sedation for an uncomfortable procedure.

The literature shows that anesthetized patients with AMMs have better outcomes when general anesthesia, neuromuscular blockade, and positive pressure ventilation are avoided.^{4,5} General anesthesia in the AMM patient exacerbates extrinsic airway compression by reducing lung volumes, relaxing bronchial smooth muscle (thus facilitating collapse and decreasing expiratory flow rates), and reducing transpleural pressure gradients during forfeiture of spontaneous ventilation.² The patient should be positioned in such a way as to minimize discomfort and reproduction of symptoms. In this case, the patient demonstrated no symptoms while prone. In addition, it has been documented that ERCP can be successfully performed under moderate to deep sedation, with certain patient characteristics, without significant differences in adverse events as compared to general anesthesia.^{7,8} Important factors for sedation without an endotracheal tube include body mass index, patient airway, procedure complexity, and American Society of Anesthesiologists' physical status. This patient was an appropriate candidate for moderate to deep sedation, particularly because spontaneous ventilation was desired. Patients with AMMs requiring anesthesia for procedures that do not alleviate the compression of the mass, as in this case, are particularly risky because the underlying threat remains after emergence. This patient's tumor burden could not be diminished by chemotherapy before anesthetic management due to an active biliary obstruction. This aspect makes this case unique.

In the case of inability to tolerate sedation or hemodynamic instability, our anesthetic backup plan was to convert to general endotracheal anesthesia (GETA). We would also convert to GETA if the patient became apneic and airway maneuvers were unsuccessful. ERCP can be aborted quickly with careful removal of the endoscope while turning the patient supine to a stretcher. Because complications can arise suddenly, the arterial line was placed preinduction in the supine position. GETA would be achieved with the avoidance of neuromuscular blockers and a titrated, stepwise induction to maintain spontaneous ventilation. If airway collapse were to occur, rigid bronchoscopy to bypass the obstruction was immediately available. This gastrointestinal (GI) suite is adjacent to the main operating rooms, with full resources available to the patient at all times. In the event of complete cardiovascular collapse, cardiopulmonary bypass would be an option; however, we did not place femoral cannulas or have a perfusionist in the GI suite.

While the literature is rich with reports of anesthetic management of AMMs in the pediatric population, there is much less describing that in the adult population. There is particularly less published describing anesthetic management of AMM patients undergoing ERCP or advanced endoscopic procedures. However, there are case reports

describing success using moderate to deep sedation, such as percutaneous AMM biopsy using CT control.⁹

Although selected for our patient, maintenance of spontaneous ventilation does not eliminate the risk of cardiopulmonary collapse, because there have also been cases of catastrophic outcomes in spontaneously breathing patients with AMMs.¹⁰ Monitored anesthesia care lacks the benefits of patient immobility and a secured airway, which could prove undesirable if the patient became uncomfortable. Ketamine and dexmedetomidine may be insufficient in particularly painful procedures or be contraindicated in certain patients due to their side-effect profile.

CONCLUSIONS

Using a combination of anesthetic agents to maintain comfort and spontaneous ventilation, this vulnerable adult patient with an AMM was able to safely undergo ERCP in the prone position while avoiding the risks of general anesthesia. This patient was in a unique situation requiring invasive intervention before treatment of the mass. This anesthetic avoided pain, dysphoria, hemodynamic instability, awareness, or airway compromise. We believe this case report will facilitate anesthetic management in similar scenarios. ■■

DISCLOSURES

Name: Alfredo Armas, MD.

Contribution: This author helped prepare the text of the manuscript and figures.

Name: Aaron N. Primm, MD.

Contribution: This author helped select case for report, editing, and mentoring.

This manuscript was handled by: Mark C. Phillips, MD.

REFERENCES

1. Béchar P, Létourneau L, Lacasse Y, Côté D, Bussi eres JS. Perioperative cardiorespiratory complications in adults with mediastinal mass: incidence and risk factors. *Anesthesiology*. 2004;100:826–834.
2. Neuman GG, Weingarten AE, Abramowitz RM, Kushins LG, Abramson AL, Ladner W. The anesthetic management of the patient with an anterior mediastinal mass. *Anesthesiology*. 1984;60:144–147.
3. Victory RA, Casey W, Doherty P, Breatnach F. Cardiac and respiratory complications of mediastinal lymphomas. *Anaesth Intensive Care*. 1993;21:366–369.
4. Gothard JW. Anesthetic considerations for patients with anterior mediastinal masses. *Anesthesiol Clin*. 2008;26:305,vi–314, vi.
5. Blank RS, de Souza DG. Anesthetic management of patients with an anterior mediastinal mass: continuing professional development. *Can J Anaesth*. 2011;58:853–859, 860–867.
6. Slinger P, Karsli C. Management of the patient with a large anterior mediastinal mass: recurring myths. *Curr Opin Anaesthesiol*. 2007;20:1–3.
7. Patel RJ, Nelsen EM, Akhter A, et al. 939 general anesthesia versus moderate conscious sedation: a prospective study on outcomes with selective sedation in ERCP. *Gastrointest Endosc*. 2018;87:AB136–AB137.
8. Barnett SR, Berzin T, Sanaka S, Pleskow D, Sawhney M, Chuttani R. Deep sedation without intubation for ERCP is appropriate in healthier, non-obese patients. *Dig Dis Sci*. 2013;58:3287–3292.
9. Frawley G, Low J, Brown TC. Anaesthesia for an anterior mediastinal mass with ketamine and midazolam infusion. *Anaesth Intensive Care*. 1995;23:610–612.
10. Gardner JC, Royster RL. Airway collapse with an anterior mediastinal mass despite spontaneous ventilation in an adult. *Anesth Analg*. 2011;113:239–242.