

Laparoscopy-assisted endoscopic full-thickness resection of upper gastrointestinal subepithelial tumors: A single-center early experience

PRASIT MAHAWONGKAJIT and PAKKAVUTH CHANSWANGPHUVANA

Department of Surgery, Faculty of Medicine, Thammasat University, Pathumthani 12120, Thailand

Received September 10, 2018; Accepted February 24, 2020

DOI: 10.3892/mco.2020.2011

Abstract. Recently, there have been important developments in minimally invasive full-thickness resection of subepithelial tumors (SETs) of the upper gastrointestinal tract. However, there remain challenges with techniques such as laparoscopy-endoscopy cooperative surgery (LECS) and non-exposed endoscopic wall-inversion surgery (NEWS). The aim of the present study was to further investigate the feasibility, efficacy and safety of laparoscopy-assisted endoscopic full-thickness resection (EFTR) of SETs and to evaluate the clinical outcomes. This retrospective study included 16 patients with upper gastrointestinal SETs who underwent laparoscopy-assisted EFTR between July 2016 and December 2017. The patient characteristics, surgical outcomes, postoperative course, results of the histopathological examination and short-term outcomes were reviewed and analyzed. A total of 10 patients in the LECS group and 6 patients in the NEWS group presented with SETs in the stomach (15 cases) or duodenum (1 case). The mean tumor size in the LECS group (5.6 cm) was larger compared with that in the NEWS group (2.1 cm). R0 resection was achieved in all patients, without adverse events or tumor recurrence. The NEWS group exhibited a lower white blood cell count and C-reactive protein level on the first postoperative day, reflecting the less prominent inflammatory response, less bleeding and shorter hospitalization. Therefore, laparoscopy-assisted EFTR by LECS and NEWS is a feasible and safe minimally invasive treatment option for upper gastrointestinal SETs in selected patients.

Introduction

The term subepithelial tumor (SET) is clinically used for protuberant lesions covered by an intact mucosa (1). The distribution of SETs in the upper gastrointestinal tract varies among different reports, with the stomach being the organ most frequently involved (2-4). SETs were previously referred to as submucosal tumors (SMTs). SETs are classified into non-neoplastic and neoplastic lesions. The majority of the lesions are asymptomatic. However, carcinoid tumors, lymphomas, glomus tumors and gastrointestinal stromal tumors (GISTs) may be malignant or have malignant potential (5,6).

Recently, there have been important developments in minimally invasive full-thickness resection for SETs of the upper gastrointestinal tract, but there remain certain challenges. Laparoscopy-assisted endoscopic full-thickness resection (EFTR) techniques, such as laparoscopic-endoscopic cooperative surgery (LECS) and non-exposed endoscopic wall-inversion surgery (NEWS), are the most common procedures, but their applicability remains a matter of debate. LECS is a safe procedure that allows for very precise resection, preventing unnecessary and excessive resection (7-11). NEWS carries the major advantage of being highly accurate in determining the resection line with no risk of peritoneal contamination, and avoids exposure of the tumor into the peritoneal cavity, and it is feasible for SETs <3 cm in greatest diameter (8-17). To the best of our knowledge, our group reported the first case on NEWS of the stomach (18) and first part of the duodenum in Thailand (19). The aim of the present study was to further investigate the feasibility, efficacy and safety of laparoscopy-assisted EFTR for upper gastrointestinal SETs and to evaluate the clinical outcome.

Patients and methods

Patients. Patients with upper gastrointestinal SETs who were referred to the Department of Surgery, Faculty of Medicine, Thammasat University (Pathumthani, Thailand) between July 2016 and December 2017 and were identified in our electronic documentation system, were included in this retrospective study. The study protocol was approved by the Human Ethics Committee of Thammasat University (Faculty of Medicine); reference no. MTU-EC-SU-1-170/60. All patients

Correspondence to: Dr Prasit Mahawongkajit, Department of Surgery, Faculty of Medicine, Thammasat University (Rangsit Campus), 95 Moo 8, Paholyothin Road, Amphur Klongluang, Pathumthani 12120, Thailand
E-mail: prasit_md@yahoo.com

Key words: submucosal tumor, subepithelial tumor, laparoscopy-assisted endoscopic full-thickness resection, stomach, duodenum

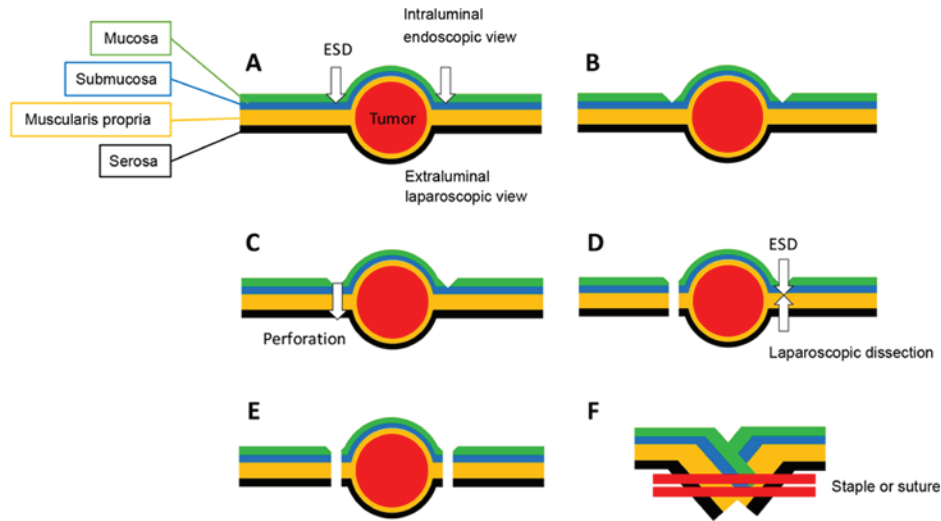


Figure 1. Laparoscopic-endoscopic cooperative surgery (LECS) procedure. (A) Endoscopic submucosal dissection (ESD) was performed after evaluating the resection margin by endoscopic and laparoscopic views. A circumferential marking was made followed by mucosal incision. (B) ESD was performed with mucosal and submucosal incision around the tumor. (C) ESD was advanced to the muscularis propria and serosa to create the luminal perforation. The circumferential resection was performed with endoscopic resection and laparoscopic surgery. (D and E) The complete seromuscular incision was performed using ESD and laparoscopic dissection. (F) The lesion was removed via the abdominal incision. The resection defect was closed by full-thickness suturing with a laparoscopic linear stapling device or the hand-sewn technique.

included in this study provided their consent to the use of their clinical data for scientific and academic purposes.

Inclusion and exclusion criteria. The SETs were treated according to the National Comprehensive Cancer Network (20), the European Society for Medical Oncology (21) and the Asian consensus guidelines for the diagnosis and management of gastrointestinal stromal tumors (22). The inclusion criteria for laparoscopy-assisted EFTR were SETs ≥ 2 cm and SETs < 2 cm with high-risk endoscopic ultrasound characteristics, including irregular border, cystic spaces, ulceration, echogenic foci and heterogeneity. Patients who were not deemed suitable for laparoscopy and endoscopic resection were excluded.

Preoperative assessment and treatment selection. The location and local invasion of tumors were evaluated with upper gastrointestinal endoscopy and abdominal computed tomography. The patients were informed of multiple treatment options and consented to undergo endoscopy and laparoscopic surgery. The patients who had SET without evidence of lymph node and/or distant metastasis and who underwent laparoscopy-assisted EFTR (LECS and NEWS) were enrolled in the present study. LECS was conducted for tumors > 3 cm in diameter on preoperative imaging, whereas NEWS was performed for tumors < 3 cm, as the tumors were removed perorally using an endoscopic retrieval device (9,13,14).

LECS. Briefly, the LECS procedure was performed as follows: The lesion was identified and the mucosal markings created using endoscopy. Next, the laparoscopic outer serosal markings opposite to the previously created inner mucosal markings were incised. The lesion was circumferentially resected by endoscopic mucosal and submucosal dissection, followed by laparoscopic seromuscular resection. The lesion was removed through the abdominal incision. The resection defect was closed by full-thickness suturing with the hand-sewn technique in the lesser curvature close to the

esophagogastric junction and the pylorus. In other areas, it was closed using a laparoscopic linear stapling device (Fig. 1).

NEWS. Briefly, NEWS was performed as follows: Several endoscopic mucosal markings were created around the subepithelial mass, and several serosal markings were made using a laparoscopic technique on the opposite side. The injection solution was prepared with Glyceol and a small amount of indigo carmine dye. The solution was endoscopically injected into the submucosal layer. A circumferential seromuscular incision was carefully performed, and was continuously sutured to invert the lesion into the lumen. During suturing, a sponge was cut to approximately the size of the lesion and was inserted between the serosal layer of the inverted lesion and the continuous serosal suture line. The lesion was removed by careful endoscopic mucosal dissection. The resected lesion and sponge were removed perorally. Finally, the mucosal edges were closed with several endoscopic clips (Fig. 2).

Statistical analysis. The patient characteristics, surgical outcomes, postoperative courses, results of the histopathological examination and short-term outcomes were analyzed in LECS and NEWS. Data are expressed as mean \pm standard error of the mean. Statistical analysis was performed using the χ^2 test and Fisher's test for categorical data and the Mann-Whitney U test for continuous data. All data were analyzed with SPSS 22.0 (IBM Corp.). $P < 0.005$ was considered to indicate statistically significant differences.

Results

Patient characteristics. A total of 16 SET patients without evidence of lymph node and distant metastasis, who consented to undergo laparoscopy-assisted EFTR (LECS and NEWS) after being informed on all treatment options, were included in this study (Table I). A total of 10 patients in the LECS group and

Table I. Characteristics of patients and tumors treated by laparoscopy-assisted endoscopic full-thickness resection.

Characteristics	Procedure, n		P-value
	LECS (n=10)	NEWS (n=6)	
Age, mean \pm SD, years	68.3 \pm 14.7	52.0 \pm 19.0	0.106
Sex, male/female	4/6	2/4	0.807
BMI, kg/m ²	23.8 \pm 3.8	28.9 \pm 11.6	0.339
Location, n			
Stomach	10	5	
Upper third	6	1	
Middle third	3	1	
Lower third	1	3	
Duodenum	0	1	
Position, n			
Stomach	10	5	
Anterior wall	1	1	
Greater curvature	4	1	
Posterior wall	1	3	
Lesser curvature	4	0	
1st part of the duodenum, anterior wall	0	1	
Tumor size, mean \pm SD, cm	5.6 \pm 1.9	2.1 \pm 0.5	<0.001
Tumors with ulceration, n	6	0	

BMI, body mass index; SD, standard deviation; LECS, laparoscopy-endoscopy cooperative surgery; NEWS, non-exposed endoscopic wall-inversion surgery.

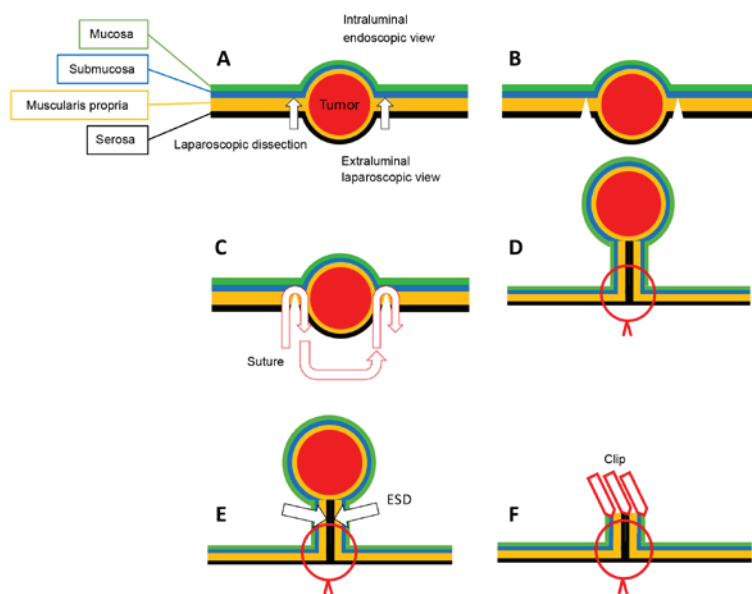


Figure 2. Non-exposed endoscopic wall inversion surgery (NEWS) procedure. (A) After evaluating the resection margin by endoscopic and laparoscopic views, the serosal margin was marked and the laparoscopic serosal incision was performed. (B) The complete circumferential serosal incision was performed. (C) The serosal incision was continuously sutured. (D) Following complete seromuscular suturing, the lesion was inverted into the lumen. (E) The lesion was removed by ESD. (F) The mucosal incision was closed with endoscopic clips.

6 patients in the NEWS group, with no significant differences by age and BMI, were selected. All patients in the LECS group received surgery on the stomach. SETs were treated by gastric NEWS in 5 patients and duodenal NEWS in one. The mean

tumor size in the LECS group was larger compared with that in the NEWS group (LECS, 5.6 \pm 1.9 cm; NEWS, 2.1 \pm 0.5 cm; P<0.001); 6 tumors in the LECS group had ulceration, with potential risk of tumor seeding into the abdominal cavity.

Table II. Outcome of laparoscopic-assisted endoscopic full-thickness resection for upper gastrointestinal subepithelial tumors.

Variables	Procedure		P-value
	LECS (n=10)	NEWS (n=6)	
Operative duration, mean \pm SD, min	211.1 \pm 36.6	207.5 \pm 30.7	0.836
Blood loss, ml	23.0 \pm 13.5	1.5 \pm 0.8	<0.001
R0 resection, n (%)	10 (100.0)	6 (100.0)	
Area of tumor (cm ²)	25.8 \pm 14.3	3.6 \pm 1.5	<0.001
Area of resection specimen (cm ²)	40.7 \pm 20.2	5.9 \pm 1.7	<0.001
Specimen area/tumor area (%)	165.6 \pm 43.9	171.6 \pm 32.6	0.756
Postoperative hospitalization, mean \pm SD, days	6.2 \pm 0.4	5.3 \pm 0.8	0.048
Body temperature and laboratory data on 1st postoperative day			
Body temperature ($^{\circ}$ C)	37.0 \pm 0.2	37.1 \pm 0.3	0.469
Preoperative WBC, mean \pm SD, $\times 10^3/\mu$ l	5.9 \pm 1.2	6.1 \pm 2.3	0.851
Postoperative day 1 WBC, mean \pm SD, $\times 10^3/\mu$ l	10.1 \pm 1.0	6.6 \pm 2.5	0.018
Postoperative day 1 WBC/preoperative WBC (%)	174.9 \pm 31.6	107.8 \pm 5.6	<0.001
CRP, mean \pm SD, mg/l	84.9 \pm 18.4	24.1 \pm 8.9	<0.001
Adverse events, n (%)	0 (0.0)	0 (0.0)	
Pathological diagnosis, n (%)			
GIST	9 (90.0)	3 (50.0)	
Schwannoma	0 (0.0)	1 (16.7)	
Leiomyoma	1 (10.0)	0 (0.0)	
Pancreatic ectopia	0 (0.0)	1 (16.7)	
Neuroendocrine tumor	0 (0.0)	1 (16.7)	
Recurrence, n (%)	0 (0.0)	0 (0.0)	
Survival, n (%)	10 (100.0)	6 (100.0)	
Mean follow-up, days	333.2 \pm 167.4	345.7 \pm 132.4	0.793

CRP, C-reactive protein; SD, standard deviation; WBC, white blood cell count; GIST, gastrointestinal stromal tumor; LECS, laparoscopy-endoscopy cooperative surgery; NEWS, non-exposed endoscopic wall-inversion surgery.

The duration of the surgery did not differ significantly between the two groups (LECS, 211.1 \pm 36.6 min; NEWS, 207.5 \pm 30.7 min; $P=0.836$), with R0 resection in both. The intraoperative blood loss was higher in the LECS group compared with that in the NEWS group (LECS, 23.0 \pm 13.5 ml; NEWS, 1.5 \pm 0.8 ml; $P<0.001$). The mean resected specimen area/tumor area ratio did not differ significantly between the two groups. On the first postoperative day, all the patients were stable; however, the white blood cell count (WBC), the mean first postoperative day WBC/preoperative WBC ratio and the level of C-reactive protein (CRP) were higher in the LECS group compared with those in the NEWS group (first postoperative day WBC: LECS, 10.1 \pm 1.0 $\times 10^3/\mu$ l; NEWS, 6.6 \pm 2.5 $\times 10^3/\mu$ l, $P=0.018$; 1st postoperative day WBC/preoperative WBC: LECS, 174.9 \pm 31.6%; NEWS, 107.8 \pm 5.6%, $P<0.001$; and CRP: LECS, 84.9 \pm 18.4 mg/l; NEWS, 24.1 \pm 8.9 mg/l, $P<0.001$). The final pathological diagnosis of the SETs was gastrointestinal stromal tumor (n=9) and leiomyoma (n=1) in the LECS group, and gastrointestinal stromal tumor (n=3), schwannoma (n=1), pancreatic ectopia (n=1) and neuroendocrine tumor (n=1) in the NEWS group. The postoperative hospitalization was shorter in the NEWS group compared with that in the LECS group (LECS, 6.2 \pm 0.4 days; NEWS, 5.3 \pm 0.8 days; $P<0.048$). Both

patients undergoing LECS and those undergoing NEWS were in a good overall condition, without adverse events, rehospitalization or tumor recurrence. The mean follow-up period for patients in the LECS group was 333.2 days and in the NEWS group 345.7 days (range, 1-537 days) (Tables II and III).

Discussion

Several studies on the R0 resection of SETs without evidence of lymph node and distant metastasis using the endoscopic and laparoscopic approaches to reduce morbidity report these methods as challenging and under development. The advantages of performing intraluminal and intraperitoneal procedures during the same operation are minimal invasion and precise resection at the tumor margin. Hiki *et al* (7) first reported LECS as a safe minimally invasive procedure that maintained the patients' quality of life by resecting a lesion with minimal margins and preserving gastric function. NEWS is a novel technique developed and published by Goto *et al* (17), which includes a minimally invasive procedure that removes the tumor perorally with full-thickness resection of the gastric wall, thereby avoiding the risk of intraperitoneal seeding. In our institute, LECS was performed for upper SETs >3 cm in

Table III. Details of 16 patients with upper gastrointestinal subepithelial tumors treated by laparoscopic-assisted endoscopic full-thickness resection.

Patient number	Age, years	Sex	Site	Location	Tumor size, mm	Ulceration	Procedure Type	Procedure time, min	Pathological diagnosis	R0 resection	Adverse events	Recurrence	Survival
1	61	Female	Stomach	Upper body, posterior wall	2.2	No	NEWS	219	GIST	Yes	No	No	Alive
2	44	Female	Stomach	Cardia	3.5	No	LECS	246	GIST	Yes	No	No	Alive
3	84	Female	Stomach	Middle body, lesser curvature	7	Yes	LECS	260	GIST	Yes	No	No	Alive
4	67	Male	Stomach	Middle body, posterior wall	3.5	No	LECS	186	GIST	Yes	No	No	Alive
5	85	Male	Stomach	Fundus	8	Yes	LECS	186	GIST	Yes	No	No	Alive
6	79	Female	Stomach	Antrum, greater curvature	6.5	Yes	LECS	171	GIST	Yes	No	No	Alive
7	75	Female	Stomach	Middle body, posterior wall	3	No	NEWS	192	GIST	Yes	No	No	Alive
8	18	Male	Stomach	Antrum, greater curvature	2	No	NEWS	209	Pancreatic ectopia	Yes	No	No	Alive
9	63	Female	Stomach	Fundus	5.5	No	LECS	218	GIST	Yes	No	No	Alive
10	75	Male	Stomach	Middle body, anterior wall	4.5	Yes	LECS	188	GIST	Yes	No	No	Alive
11	51	Female	Duodenum	1st part	1.3	No	NEWS	261	Neuroendocrine tumor	Yes	No	No	Alive
12	80	Male	Stomach	Cardia	9	Yes	LECS	268	GIST	Yes	No	No	Alive
13	50	Female	Stomach	Antrum, posterior wall	2.1	No	NEWS	178	Schwannoma	Yes	No	No	Alive
14	57	Male	Stomach	Antrum, anterior wall	2.2	No	NEWS	185	GIST	Yes	No	No	Alive
15	49	Female	Stomach	Fundus	4.5	Yes	LECS	170	GIST	Yes	No	No	Alive
16	57	Female	Stomach	Cardia	4.3	No	LECS	218	Leiomyoma	Yes	No	No	Alive

GIST, gastrointestinal stromal tumor; LECS, laparoscopy-endoscopy cooperative surgery; NEWS, non-exposed endoscopic wall-inversion surgery.

diameter, and NEWS was employed for SETs <3 cm due to the peroral removal, as previously reported (9,13,14).

The mean specimen area/tumor area ratio did not differ significantly between the two groups, reflecting the avoidance of excessive, unnecessary resection and precise cutting of the lesion. The operative duration of both techniques was also not significantly different, but the intraoperative blood loss was higher in the LECS group compared with that in the NEWS group, which was attributed to the tumor size and area of resection. Both techniques are effective and minimally invasive, and achieved R0 resection without recurrence, a short length of hospital stay and lack of adverse events. However, the LECS group had higher WBC compared with the NEWS group on the 1st postoperative day, as well as higher mean 1st postoperative day WBC/preoperative WBC ratio and CRP levels, reflecting the inflammatory process. The procedure of LECS includes dissecting the lesion and removing the resected specimen via the abdominal incision. The process of LECS also involves a step of transmural communication, meaning that the intraperitoneal cavity may be exposed to the gastrointestinal fluid. The cautious and delicate handling of the tissues during surgery is crucial for minimizing the contamination risk of the LECS procedure. The NEWS technique involves resecting a non-exposed tumor and removing it via the oral route, which prevents activation of the inflammatory process by peritoneal contamination. The patients in the NEWS group had lower levels of inflammatory markers and shorter postoperative hospitalization. The limitation of this study lies with its inability to draw definitive conclusions on the advantages of each technique in terms of patient characteristics, surgical outcomes and postoperative course, due to the limited number of cases in the LECS and NEWS groups. The aim of the present study was to report our early experience with laparoscopy-assisted EFTR in Thailand, and the results were in accordance with the first reports of this technique in previous studies (11,14,23).

In conclusion, the present study successfully demonstrated that laparoscopy-assisted EFTR by LECS and NEWS may be a feasible and safe minimally invasive treatment option for upper gastrointestinal SETs. NEWS is the non-exposed technique, which is preferred if the lesion is sized <3 cm. This study describes early findings and its main limitation is the small patient sample. Further studies are required to verify that LECS and NEWS can be introduced as the standard treatment for small gastric and duodenal tumors in Thailand.

Acknowledgements

Not applicable.

Funding

No funding was received.

Availability of data and materials

The datasets used and/or analyzed during the present study are available from the corresponding author on reasonable request.

Authors' contributions

PM conceived and designed the present study, performed the experiments, and analyzed and interpreted the data. PM and PC collected the data and performed the experiments. All the authors read and approved the final version of the manuscript.

Ethics approval and consent to participate

The present study was approved by the Human Ethics Committee of Thammasat University (Faculty of Medicine) (Pathumthani, Thailand); reference no. MTU-EC-SU-1-170/60. All the patients in this study provided consent to the use of their clinical data for scientific and academic purposes.

Patient consent for publication

Not applicable.

Competing interests

The authors declare that they have no competing interests.

References

1. Wiech T, Walch A and Werner M: Histopathological classification of nonneoplastic and neoplastic gastrointestinal submucosal lesions. *Endoscopy* 37: 630-634, 2005.
2. Rösch T, Lorenz R, Dancygier H, von Wickert A and Classen M: Endosonographic diagnosis of submucosal upper gastrointestinal tract tumors. *Scand J Gastroenterol* 27: 1-8, 1992.
3. Polkowski M: Endoscopic ultrasound and endoscopic ultrasound-guided fine-needle biopsy for the diagnosis of malignant submucosal tumors. *Endoscopy* 37: 635-645, 2005.
4. Kawamoto K, Yamada Y, Utsunomiya T, Okamura H, Mizuguchi M, Motooka M, Hirata N, Watanabe H, Sakai K, Kitagawa S, *et al*: Gastrointestinal submucosal tumors: Evaluation with endoscopic US. *Radiology* 205: 733-740, 1997.
5. Cho JW; Korean ESD Study Group: Current guidelines in the management of upper gastrointestinal subepithelial tumors. *Clin Endosc* 49: 235-240, 2016.
6. Nishida T, Goto O, Raut CP and Yahagi N: Diagnostic and treatment strategy for small gastrointestinal stromal tumors. *Cancer* 122: 3110-3118, 2016.
7. Hiki N, Yamamoto Y, Fukunaga T, Yamaguchi T, Nunobe S, Tokunaga M, Miki A, Ohyama S and Seto Y: Laparoscopic and endoscopic cooperative surgery for gastrointestinal stromal tumor dissection. *Surg Endosc* 22: 1729-1735, 2008.
8. Matsuda T, Hiki N, Nunobe S, Aikou S, Hirasawa T, Yamamoto Y, Kumagai K, Ohashi M, Sano T and Yamaguchi T: Feasibility of laparoscopic and endoscopic cooperative surgery for gastric submucosal tumors (with video). *Gastrointest Endosc* 84: 47-52, 2016.
9. Hiki N, Nunobe S, Matsuda T, Hirasawa T, Yamamoto Y and Yamaguchi T: Laparoscopic endoscopic cooperative surgery. *Dig Endosc* 27: 197-204, 2015.
10. Matsuda T, Nunobe S, Ohashi M and Hiki N: Laparoscopic endoscopic cooperative surgery (LECS) for the upper gastrointestinal tract. *Transl Gastroenterol Hepatol* 2: 40, 2017.
11. Shoji Y, Takeuchi H, Goto O, Tokizawa K, Nakamura R, Takahashi T, Wada N, Kawakubo H, Yahagi N and Kitagawa Y: Optimal minimally invasive surgical procedure for gastric submucosal tumors. *Gastric Cancer* 21: 508-515, 2018.
12. Mitsui T, Nimi K, Yamashita H, Goto O, Aikou S, Hatao F, Wada I, Shimizu N, Fujishiro M, Koike K and Seto Y: Non-exposed endoscopic wall-inversion surgery as a novel partial gastrectomy technique. *Gastric Cancer* 17: 594-599, 2014.
13. Maehata T, Goto O, Takeuchi H, Kitagawa Y and Yahagi N: Cutting edge of endoscopic full-thickness resection for gastric tumor. *World J Gastrointest Endosc* 7: 1208-1215, 2015.

14. Goto O, Takeuchi H, Sasaki M, Kawakubo H, Akimoto T, Fujimoto A, Ochiai Y, Maehata T, Nishizawa T, Kitagawa Y and Yahagi N: Laparoscopy-assisted endoscopic full-thickness resection of gastric subepithelial tumors using a nonexposure technique. *Endoscopy* 48: 1010-1015, 2016.
15. Goto O, Takeuchi H, Kawakubo H, Matsuda S, Kato F, Sasaki M, Fujimoto A, Ochiai Y, Horii J, Uraoka T, *et al*: Feasibility of non-exposed endoscopic wall-inversion surgery with sentinel node basin dissection as a new surgical method for early gastric cancer: A porcine survival study. *Gastric Cancer* 18: 440-445, 2015.
16. Goto O, Takeuchi H, Kawakubo H, Sasaki M, Matsuda T, Matsuda S, Kigasawa Y, Kadota Y, Fujimoto A, Ochiai Y, *et al*: First case of non-exposed endoscopic wall-inversion surgery with sentinel node basin dissection for early gastric cancer. *Gastric Cancer* 18: 434-439, 2015.
17. Goto O, Mitsui T, Fujishiro M, Wada I, Shimizu N, Seto Y and Koike K: New method of endoscopic full-thickness resection: A pilot study of non-exposed endoscopic wall-inversion surgery in an ex vivo porcine model. *Gastric Cancer* 14: 183-187, 2011.
18. Mahawongkajit P, Techagumpuch A and Suthiwartnarueput W: Non-exposed endoscopic wall-inversion surgery for a gastrointestinal stromal tumor of the stomach: A case report. *Oncol Lett* 14: 4746-4750, 2017.
19. Mahawongkajit P, Techakumpuch A and Chanswangphuvana P: Non-exposed endoscopic wall-inversion surgery for submucosal tumor of the duodenum: Novel case report. *Dig Endosc* 29: 818-819, 2017.
20. National Comprehensive Cancer Network: NCCN clinical practice guidelines in oncology: Soft tissue sarcoma, version 1.1[Internet]. Fort Washington, PA: National Comprehensive Cancer Network, 2018 (cited 2018 Jan 5). Available from: http://www.nccn.org/professionals/physician_gls/pdf/sarcoma.pdf.
21. ESMO/European Sarcoma Network Working Group: Gastrointestinal stromal tumours: ESMO clinical practice guidelines for diagnosis, treatment and follow-up. *Ann Oncol* 25 (Suppl 3): iii21-iii26, 2014.
22. Koo DH, Ryu MH, Kim KM, Yang HK, Sawaki A, Hirota S, Zheng J, Zhang B, Tzen CY, Yeh CN, *et al*: Asian consensus guidelines for the diagnosis and management of gastrointestinal stromal tumor. *Cancer Res Treat* 48: 1155-1166, 2016.
23. Mitsui T, Yamashita H, Aikou S, Niimi K, Fujishiro M and Seto Y: Non-exposed endoscopic wall-inversion surgery for gastrointestinal stromal tumor. *Transl Gastroenterol Hepatol* 3: 17, 2018.



This work is licensed under a Creative Commons Attribution-NonCommercial-NoDerivatives 4.0 International (CC BY-NC-ND 4.0) License.